

CRITICAL CARE

Comparison between single-step and balloon dilatational tracheostomy in intensive care unit: a single-centre, randomized controlled study

G. Cianchi¹, G. Zagli^{1*}, M. Bonizzoli¹, S. Batacchi¹, R. Cammelli¹, S. Biondi², R. Spina¹ and A. Peris¹

¹Anesthesia and Intensive Care Unit of Emergency Department, Careggi Teaching Hospital, Florence, Italy.

²Faculty of Medicine, Postgraduate School of Anesthesia and Intensive Care, University of Florence, Florence, Italy

*Corresponding author. E-mail: giovanni.zagli@unifi.it

Background. Balloon dilatational tracheostomy using the Ciaglia Blue Dolphin device has recently been introduced as a modification of the Ciaglia technique. The aim of this study was to compare the new Dolphin system with the single-step dilatational tracheostomy (Ciaglia Blue Rhino) in intensive care unit (ICU) patients.

Methods. Consecutive patients admitted to the ICU of the Emergency Department (Careggi Teaching Hospital, Florence, Italy) from January 2009 to October 2009, aged >18 years and with an indication for percutaneous dilatational tracheostomy (PDT), were enrolled. Exclusion criteria were infection/injury/malignancy of the neck, thyroid gland hypertrophy, severe head injury with uncontrolled intracranial hypertension, and coagulopathy. Patients were randomly assigned to undergo PDT using either the Ciaglia Blue Rhino ($n=35$) or the Ciaglia Blue Dolphin technique ($n=35$). Groups were compared according to tracheal puncture, tracheal tube placement time, procedure-related complications, and bleeding.

Results. Baseline clinical data were comparable between the two groups. Median procedure time was significantly shorter in the Rhino group compared with the Dolphin group (1.5 vs 4 min, $P=0.035$). The presence of limited intra-tracheal bleeding at bronchoscopy examination after 6 h from PDT was more frequent in the Dolphin group than in the Rhino group patients (68.6% vs 34.3%, respectively, $P=0.008$). No major bleeding occurred in either group.

Conclusions. PDT using the Ciaglia Blue Dolphin technique is a feasible and viable option in ICU patients, but the Rhino technique had a shorter execution time and seemed to be associated with fewer tracheal injuries.

Br J Anaesth 2010; **104**: 728–32

Keywords: Ciaglia Blue Dolphin; Ciaglia Blue Rhino; intensive care; percutaneous dilatational tracheostomy

Accepted for publication: March 11, 2010

Tracheostomy using a percutaneous dilatational tracheostomy (PDT) technique is recommended for use in critically ill patients by the European Association of Cardio-Thoracic Surgery.^{1,2} The Ciaglia Blue Rhino PDT technique was introduced in 1998 as a modification of the first procedure described in 1985.³ Since then, several studies have demonstrated the safety and feasibility of the single-dilator step PDT,^{1,4} and it has been recently indicated as the dilatational technique of choice (level of

evidence 2C) for its simplicity and short execution time.^{1,5} Recently, a new modification of the Ciaglia Blue Rhino technique has been introduced: the Ciaglia Blue Dolphin, which uses an inflatable balloon dilation system instead of the single-step cone dilator. Initial experiences have evidenced that this new technique is feasible, easy to perform, and safe,⁶ but no comparative studies are available in the literature. The aim of this study was to compare the new Ciaglia Blue Dolphin system with the

previous one in a mixed population of intensive care unit (ICU) critically ill patients regarding procedure stay, peri-operative complications, and easy performance.

Methods

Patient selection and randomization

All patients consecutively admitted to our 10-bed medical and trauma ICU of a tertiary care referral centre (Careggi Teaching Hospital, Florence, Italy) from January 2009 to October 2009, aged >18 years and with an indication for PDT following the international guidelines indications,¹ were screened for eligibility. Exclusion criteria were: (i) infection/injury/malignancies of the anterior part of the neck; (ii) patients with severe head injury and intracranial hypertension in which cerebral perfusion pressure (CPP) [defined as the difference between intracranial pressure (ICP) and mean arterial pressure] was <60 mm Hg, despite therapy; (iii) the presence of thyroid gland hypertrophy at ultrasonography/computed tomography scan that could interfere with PDT; and (iv) an international

normalized ratio (INR) value ≥ 1.2 and a platelet count $\leq 100\,000\text{ mm}^{-3}$.

The study was designed as a prospective randomized-controlled trial. We considered a 9-month enrolment period appropriate to obtain a sample of 70 patients, with regard to the mean number of PDTs performed in our ICU over a 1-year period. A computer-based random allocation sequence was generated to assign 35 patients to the Ciaglia Blue Rhino technique (Rhino group) and 35 patients to the Ciaglia Blue Dolphin technique (Dolphin group) (Fig. 1). This study, supported by institutional funds only, followed the principles of the Helsinki declaration and was approved by the Internal Review Board. Informed consent was obtained from patients or their relatives if patients were unable to consent before the procedure: in these cases (43 in total), a retrospective assent was obtained.

Data collection

Patients' baseline and clinical characteristics were retrieved from the ICU database (FileMaker Pro 5.5v2, FileMaker, Inc., USA). Duration of mechanical ventilation,

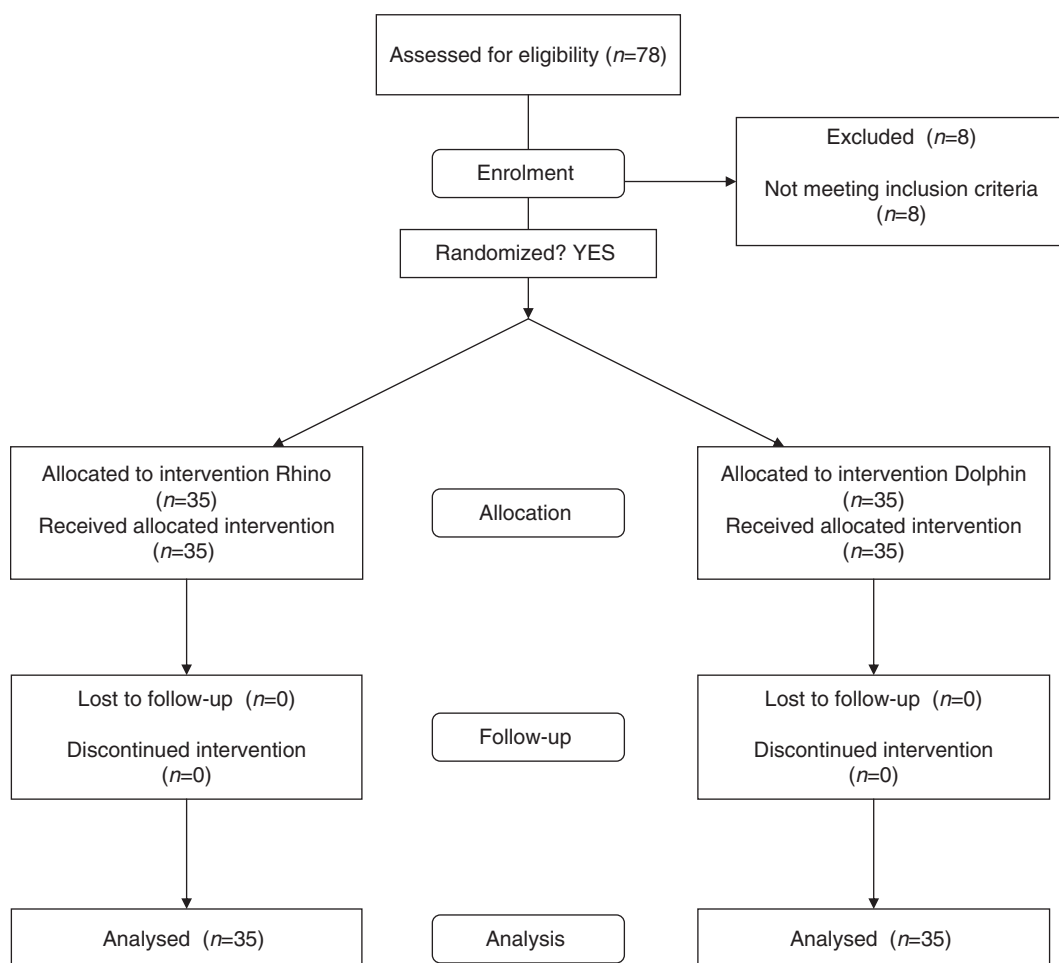


Fig 1 The consort flowchart.

ICU and hospital length of stay (LOS), and intra-ICU and hospital mortality were examined.

In order to compare both the techniques regarding the feasibility and occurrence of side-effects, we analysed the following data: physiological parameters during the intervention, time between tracheal puncture and placement of the tracheal tube, difficulties in insertion of the tracheal tube requiring more than one attempt, the appearance of tracheal ring injury, technical complications, the presence of unusual bleeding of tracheal mucosa (evaluated by fiberoptic bronchoscopy at 6 h after procedure), cutaneous bleeding (defined as blood loss from the skin needing more than two changes of tracheostoma dressing within 3 h after PDT), hypoxia (defined as a pulse-oximetry oxygen saturation below 90%, even transiently confirmed by arterial blood gas analysis), and pneumothorax. Coagulation status was evaluated using platelet count, activated partial thromboplastin time (aPTT), INR, and antithrombin.

Tracheostomy procedure

All PDTs (Ciaglia Blue Rhino and Ciaglia Blue Dolphin Percutaneous Tracheotomy Introducer Kit; Cook Critical Care Inc., Bloomington, IN, USA) were performed by the same three intensivists. All of them had experience of performing at least 50 PDTs using the Blue Rhino since 2002; they were also skilled in PDT using the Ciaglia Blue Dolphin (five, four, and four procedures each), as the new technique was already available and used in clinical practice in our unit since October 2008.

Procedures were carried out under direct fiberoptic bronchoscopic video guidance.^{7,8} General anaesthesia was achieved using propofol, midazolam, or ketamine, followed by a continuous infusion of propofol; analgesia was provided using fentanyl, and neuromuscular block maintained with atracurium. Arterial pressure was controlled, if necessary, using an infusion of norepinephrine. Inspiratory fraction of oxygen was set between 0.5 and 1.0 as required. Physiological parameters and expiratory CO₂ were monitored continuously, and ICP (in the case of head-injured patients) in order to maintain a CPP >60 mm Hg and ICP <20 mm Hg.

Patients were positioned supine with 25°–30° head-up inclination. A volume-inflatable pillow was positioned under the shoulders of the patient to provide adequate neck hyperextension and to optimize the distance between the cricoid cartilage and the jugular notch. Asepsis was assured with chlorhexidine 2% and lidocaine 2% with epinephrine 1:10 000 infiltrated locally. A camera was mounted on the fibrescope to allow video control of the procedure.

Choice of the puncture site was determined by manual examination of relevant landmarks (cricoid cartilage, tracheal rings, and jugular notch) and transillumination (in order to prevent vascular punctures). Fiberoptic video

guidance allowed the control of the correct position of needle insertion and prevented unintentional punctures of the posterior tracheal wall.

After subsequent steps (needle puncture, wire introduction, and incision on neck cutis), the first dilatation was achieved using a 14 Fr dilator in both systems.

In Ciaglia Blue Rhino technique, the operator performed a second dilatation with the single cone dilator, then removed the dilator and eventually inserted the tracheal tube over the guide wire. Following the manufacturer's instructions, in the Ciaglia Blue Dolphin PDT, the second dilatation was made filling the balloon with saline solution using the provided inflation pump to reach a pressure of 11 atm. The inflated balloon was kept in place for 10 s, and then completely deflated. A tracheostomy tube, previously assembled over the balloon catheter, was advanced into the trachea, and both the balloon catheter and the guide wire were finally removed. To limit study bias, Shiley[®] tracheostomy tubes suggested for the Dolphin technique by the producer were used in both groups. All patients underwent post-procedure bronchoscopy immediately after tracheal tube positioning and at 6 h. The presence of bleeding was quantified using a bronchial lavage kit. A chest radiograph was always obtained 6 h after the procedure.

Statistical analysis

Data were analysed with GraphPad Prism 5 (GraphPad Software Inc., San Diego, CA, USA).

The ANOVA test was used to compare continuous variables, and results expressed as medians with 25th to 75th inter-quartile range (IQR). Categorical variables and mortality rate were compared using Fisher's exact test. A value of $P < 0.05$ was considered statistically significant.

Results

During the study period, a total of 382 patients were admitted to ICU. Admission diagnosis was trauma in 158 patients (41.4%), medical in 147 (38.5%), and surgical in 77 (20.6%). Tracheostomy was indicated in 78 (20.4%) patients, 70 of whom were eligible for the study and were randomly assigned to the Rhino or Dolphin group. Reasons for exclusion were age <18 years in two cases and severe, non-responsive intracranial hypertension in six cases.

There were no differences in baseline characteristics, admission diagnoses, duration of mechanical ventilation, ICU and hospital LOS, and in-ICU and total hospital mortality between the study groups (Table 1). The predominance of males in both groups reflects the pattern in all our ICU admissions during the study period.

Procedural data are presented in Table 2. Median procedure length (minutes between tracheal puncture and tracheal tube placement) was significantly shorter in the Rhino group than in the Dolphin group (1.5 vs 4 min,

Table 1 Baseline characteristics, ICU, and hospital outcome. Data are expressed as medians with 25th to 75th IQR. Percentages refer to the total population of each group. Statistical analysis: one-way ANOVA and two-tailed Fisher's exact test ($P < 0.05$)

	Rhino group	Dolphin group
Number	35	35
Male gender [% (<i>n</i>)]	71.4 (25)	77.1 (27)
Age (years)	55 (32.5–74.5)	66 (45.5–76.2)
Body mass index (kg m ⁻²)	26.8 (24.5–29.3)	26 (23.8–27.3)
aPTT (s)	30.9 (27.8–34)	30.2 (28.2–33.4)
INR	1.2 (1.1–1.3)	1.2 (1.1–1.3)
Antithrombin (%)	72.5 (58.5–79.8)	68.5 (61–78.3)
Platelet count ($\times 10^3 \mu\text{l}^{-1}$)	152 (93–214)	125 (70–143)
Duration of mechanical ventilation (days)	9 (6–12)	9 (6–12.5)
ICU length of stay (days)	13 (9–18)	12 (9–15.5)
Hospital length of stay (days)	25 (18.5–39)	28 (19–35)
ICU mortality [% (<i>n</i>)]	17.1 (6)	21.9 (8)
Hospital mortality [% (<i>n</i>)]	25.7 (9)	34.3 (12)

Table 2 Procedural data and main procedures-related complications. Duration of procedure represents the time (min) elapsed from tracheal puncture to tracheal tube insertion. The presence of blood drain on tracheal mucosa was evaluated with bronchoscopy 6 h after the procedure. Cutaneous bleeding was defined as blood loss from the skin needing more than two changes of tracheostoma dressing within 3 h after PDT. Data are expressed as medians with 25th to 75th IQR. Percentage data refer to the total population in each group. Statistical analysis was performed using one-way ANOVA and two-tailed Fisher's exact test (Rhino vs Dolphin group). * $P < 0.05$; ** $P < 0.01$

	Rhino group	Dolphin group
Number	35	35
Time from admission to tracheostomy (days)	2 (1–4)	2.5 (2–4.8)
Duration of procedure (min)	1.5 (1–4)*	4 (2–7)
Operative complications [% (<i>n</i>)]		
Tracheal ring buckling	2.9 (1)	8.6 (3)
Tracheal ring injury	5.7 (2)	8.6 (3)
Presence of blood drain on tracheal and bronchial mucosa	34.3 (12)**	68.6 (24)
Cutaneous bleeding	42.9 (15)	57.1 (20)
Resistance to tracheal tube passage	5.7 (2)*	28.6 (10)

$P=0.035$). At bronchoscopic examination performed after 6 h from PDT, unapparent bleeding was reported in 24 patients (68.6%) of the Dolphin group and in 12 patients (34.3%) in the Rhino group ($P=0.008$). In all cases, the bleeding was minimal (few millilitres) and not clinically relevant. No difference was reported regarding external bleeding from cutaneous stoma (Table 2) and there were no differences in markers of haemostasis between the groups (Table 1).

Tracheal ring injury during dilatation occurred in five patients in total: two patients in the Rhino group (5.7%) and in three patients in the Dolphin group (8.6%), whereas ring buckling was observed in one patient in the Rhino group (2.9%) and three patients in the Dolphin group (8.6%). Operators experienced difficulties in inserting the tracheal tube in 10 patients in the Dolphin group (28.6%) and three patients (5.7%) in the Rhino group ($P=0.023$) (Table 2), requiring a second dilatational manoeuvre.

No hypoxia (defined as a pulse-oximetry oxygen saturation below 90%, even transiently) or procedure-related

major complications (pneumothorax, lesion of posterior tracheal wall, and mal-positioning of the tracheal tube) occurred. No complications during the next tracheal tube change were referred to in either group. During subsequent ongoing follow-up, one case requiring a surgical intervention for non-critical tracheal stenosis (Rhino group) has occurred.

Discussion

To our knowledge, this is the first randomized study aimed at formally comparing the new Ciaglia Blue Dolphin PDT technique with the Ciaglia Blue Rhino technique. One of the main reasons reported for the Dolphin method development is the avoidance of posterior tracheal wall perforation during insertion of the dilatation device.⁹ In this regard, as previously suggested,⁷ we have recently shown that the use of fiberoptic bronchoscopic video guidance can effectively prevent the occurrence of such a complication in the Rhino technique.^{4 8} Also, video-assisted bronchoscopy was used in 70 PDTs in the present study, and no posterior tracheal wall injury occurred. Therefore, we believe that direct video guidance allows the enhancement of the safety of the procedure, regardless of the chosen technique.

In this study, we found a significantly shorter execution time using the Ciaglia Blue Rhino PDT in comparison with the Ciaglia Blue Dolphin system (Table 2). Both the techniques were already in use in our department before starting the study; however, it is of course possible that the longer execution time of the Dolphin method may be related to the operators' lesser familiarity with the more recent technique. Also the limited sample size may have influenced our result. Considering these two important limitations, no definitive conclusion can be drawn regarding which technique is easier to perform, although we found that inflating the balloon with the provided syringe while keeping it in place during dilatation can sometimes be difficult and requires appropriate manual skills and training.

Gromann and colleagues⁶ reported a procedural time for insertion of Blue Dolphin PDTs of 3 min, shorter than what we have experienced (4 min). Despite the shorter mean time, a wider range (1.5–9 min) in a smaller sample size was evident, in contrast with our results (2–7 min). Furthermore, their study was not specifically designed to compare the velocity of execution of the two techniques.

Bleeding from the tracheal stoma is relatively common (6%),⁵ with reported incidences ranging from 2% to 27%.^{10–13} Usually, this has no clinical consequences and rarely requires intervention,^{11 14} although intra-tracheal bleeding could be related to pulmonary complications such as atelectasis and infection. In our sample, we found minimal bleeding, described either as ‘oozing’ or as tracheal wall stained with blood at bronchoscopy 6 h later, with a higher percentage in the Dolphin group (Table 2). This observation might be ascribed to the non-progressive dilatation movement applied by the balloon catheter and to the final ‘blast effect’ produced by balloon inflation, compared with the progressive dilatation obtained with the single-step dilator in the Rhino method. However, all bleeding events were minor, and we did not note any case of major bleeding requiring surgical treatment or blood transfusion.

In our experience, operators reported more difficulties in the introduction of a tracheostomy tube using the Dolphin rather than the Rhino technique (Table 2). The main mechanical difference between the two techniques is that the single-step dilator creates the right diameter using both radial and coaxial forces, facilitating the tracheostomy tube insertion. In our opinion, the outward radial pressure generated by the balloon catheter is enough to create a diameter in structure, but it seems not to be sufficient to allow a smooth tracheal tube placement.

We conclude that the Ciaglia Blue Dolphin technique is a feasible and viable option in ICU patients, although our findings encourage the use of Ciaglia Blue Rhino technique as it had a shorter execution time. These findings require confirmation in a larger sample of patients and by operators with more experience with the new technique. As Ciaglia Blue Dolphin is the more recently introduced technique, studies are also needed to assess the advantages and limits of this new method. In particular, it is possible to hypothesize that the outward radial forces created by the balloon dilator instead of the coaxial forces might be indicated in the presence of special conditions of trachea and oesophagus (i.e. recent cervical surgery, cervical spine injuries, and the presence of pre-existent pars membranaea injury).

Conflict of interest

None declared.

Funding

This work was supported by institutional funds only.

References

- 1 De Leyn P, Bedert L, Delcroix M, et al. Tracheostomy: clinical review and guidelines. *Eur J Cardiothorac Surg* 2007; **32**: 412–21
- 2 Bhatti N, Tatlipinar A, Mirski M, Koch WM, Goldenberg D. Percutaneous dilation tracheostomy in intensive care unit patients. *Otolaryngol Head Neck Surg* 2007; **136**: 938–41
- 3 Ciaglia P, Firsching R, Syniec C. Elective percutaneous dilatational tracheostomy. A new simple bedside procedure; preliminary report. *Chest* 1985; **87**: 715–9
- 4 Zagli G, Linden M, Spina R, et al. Early tracheostomy in intensive care unit: a retrospective study of 506 cases of video-guided ciaglia blue rhino tracheostomies. *J Trauma* 2010; **68**: 367–72
- 5 Delaney A, Bagshaw SM, Nalos M. Percutaneous dilatational tracheostomy versus surgical tracheostomy in critically ill patients: a systematic review and meta-analysis. *Crit Care* 2006; **10**: R55
- 6 Gromann TW, Birkelbach O, Hetzer R. Balloon dilatational tracheostomy: initial experience with the Ciaglia Blue Dolphin method. *Anesth Analg* 2009; **108**: 1862–6
- 7 Gardiner Q, White PS, Carson D, Shearer A, Frizelle F, Dunkley P. Technique training: endoscopic percutaneous tracheostomy. *Br J Anaesth* 1998; **81**: 401–3
- 8 Peris A, Linden M, Pellegrini G, Anichini V, Di Filippo A. Percutaneous dilatational tracheostomy: a self-drive control technique with video fiberoptic bronchoscopy reduces perioperative complications. *Minerva Anestesiol* 2009; **75**: 21–5
- 9 Zgoda MA, Berger R. Balloon-facilitated percutaneous dilatational tracheostomy tube placement: preliminary report of a novel technique. *Chest* 2005; **128**: 3688–90
- 10 Kost KM. Endoscopic percutaneous dilatational tracheostomy: a prospective evaluation of 500 consecutive cases. *Laryngoscope* 2005; **115**: 1–30
- 11 Heikkinen M, Aarnio P, Hannukainen J. Percutaneous dilatational tracheostomy or conventional surgical tracheostomy? *Crit Care Med* 2000; **28**: 1399–402
- 12 Bacchetta MD, Girardi LN, Southard EJ, et al. Comparison of open versus bedside percutaneous dilatational tracheostomy in the cardiothoracic surgical patient: outcomes and financial analysis. *Ann Thorac Surg* 2005; **79**: 1879–85
- 13 Byhahn C, Wilke HJ, Halbig S, Lischke V, Westphal K. Percutaneous tracheostomy: ciaglia blue rhino versus the basic ciaglia technique of percutaneous dilatational tracheostomy. *Anesth Analg* 2000; **91**: 882–6
- 14 Bowen CP, Whitney LR, Truwit JD, Durbin CG, Moore MM. Comparison of safety and cost of percutaneous versus surgical tracheostomy. *Am Surg* 2001; **67**: 54–60