Osteomyelitis with a twist: *Streptococcus pneumoniae* causing sternoclavicular septic arthritis

Ruchi Murthy MD[1], Dan Petrescu MD FRCPC[2], Irving E Salit MD FRCPC[2]

CASE PRESENTATION

An 80-year-old woman of Caribbean descent with a history of type 2 diabetes mellitus, gout, osteoarthritis, gastrointestinal reflux and atrial fibrillation, presented with a 12 h history of left-sided shoulder, neck and back pain. Her temperature was 38.0°C and her white blood cell count was 15×10^9 cells/L. She experienced tenderness in the left sternoclavicular and sternomanubrial regions associated with warmth and erythema, but without an effusion. Her neck range of motion was restricted by pain on the left side, including neck deviation to the right, which was compatible with torticollis. She could not abduct her shoulder beyond 60 degrees. She had a III/VI systolic ejection murmur at the left upper sternal border, but no stigmata of infectious endocarditis. Her gastrointestinal, dermatological and respiratory examinations were within normal limits.

On admission, she was empirically started on ceftriaxone for suspected shoulder joint septic arthritis. An unsuccessful attempt was made to aspirate the left shoulder joint. The pain progressed toward her anterior chest wall and within 72 h C-reactive protein levels had increased from 11 mg/L to 240 mg/L. Blood cultures were positive in three of three sets for penicillin-susceptible *Streptococcus pneumoniae*.

Aspiration of the sternoclavicular joint (SCJ) was unsuccessful. Transesophageal echocardiography did not reveal evidence of endocarditis. The chest radiograph did not reveal evidence of pneumonia.

Despite prolonged antibiotic therapy, the patient never experienced full recovery of function, primarily with respect to arm adduction, which was limited by pain at the SCJ. Repeat computed tomography (CT) scan after therapy revealed arthritic changes related to her treated infection. Avoidance of pain led to the patient's torticollis, which was the most distressing clinical feature for her. This persisted for months despite regular physiotherapy sessions.

DISCUSSION

SCJ septic arthritis accounts for 0.5% to 1% of all bone and joint infections (1). The most common organism, responsible for 50% of SCJ arthritis, is *Staphylococcus aureus* (1,2). Other common bacteria include *Pseudomonas aeruginosa*, *Brucella melitensis*, *Escherichia coli*, group B *Streptococcus*, *Mycobacterium tuberculosis*, *Haemophilus influenzae*, *Salmonella* and *Serratia marcescens* (3). In the present case, *S pneumoniae* was the bacteria responsible for the septic SCJ arthritis. It accounts for 3% to 10% of all septic arthritis cases, primarily involving

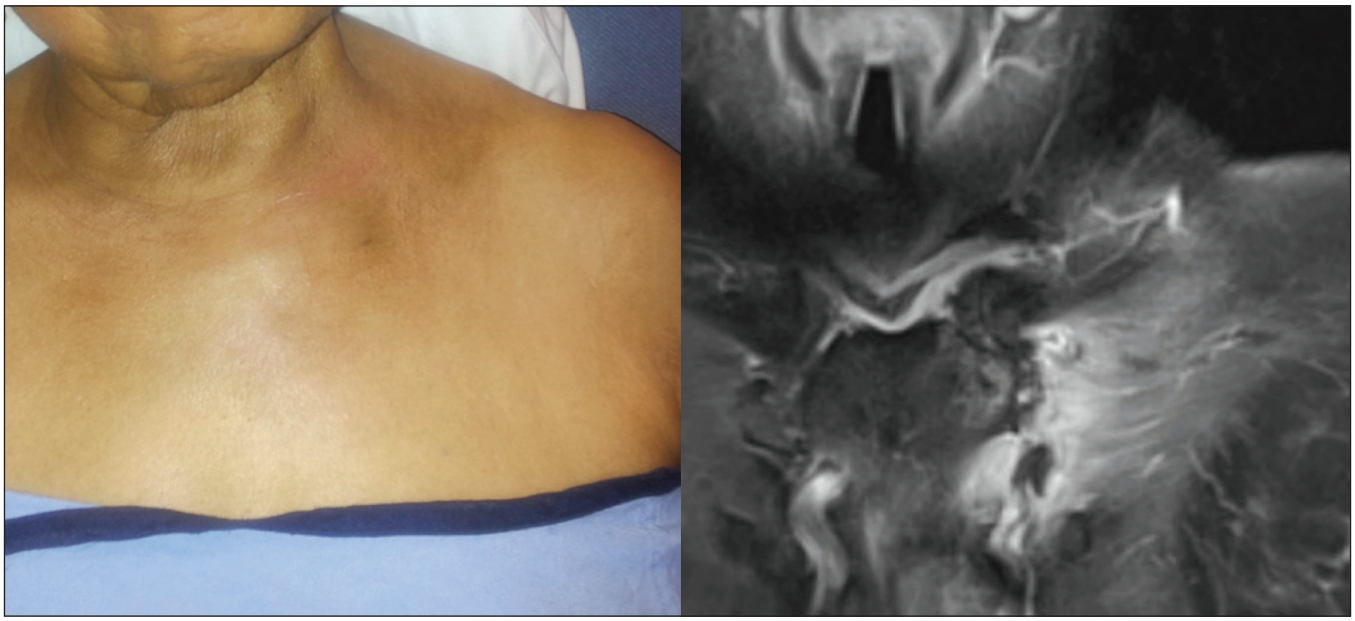

Figure 1) *Left: physical examination findings of edema, erythema and torticollis; right: corresponding magnetic resonance image displaying soft tissue and manubrium signal uptake, as well as joint space effusion*

[1]*Department of Internal Medicine, The University of Ottawa, Ottawa;* [2]*Division of Infectious Diseases, The University of Toronto, Toronto, Ontario*
Correspondence: Dr Ruchi Murthy, Department of Internal Medicine, The Ottawa Hospital, 501 Smyth Road, Box 210, Ottawa, Ontario K1H 8L6. Telephone 613-737-8999, e-mail rmurthy@toh.on.ca

the knee joint (2). Due to its relative rarity as a causative pathogen, culture positivity for *S pneumoniae* should prompt further investigation into other risk factors, such as concomitant pneumonia or infective endocarditis, leading to bacteremia.

In a review of 180 cases of septic arthritis of the SCJ, risk factors included intravenous drug use (IVDU) (21%), a distant site of infection (15%), diabetes mellitus (13%), trauma (12%) and an infected central venous line (9%) (3). SCJ septic arthritis accounted for 17% of all septic joint infections in the IVDU group, and these were more commonly associated with Gram-negative organisms (3). Risk factors for *S pneumoniae*-associated septic arthritis also included rheumatoid arthritis and alcoholism (4). The proposed pathophysiology of infection in patients with IVDU involves either chronic endovascular colonization with bacteria leading to embolization and bony infection (similar to septic embolus phenomena in endocarditis), or contiguous spread from a proximal infected vessel (4).

SCJ septic arthritis usually presents unilaterally (5). Given the superficial location of the joint, swelling is often the most obvious clinical finding (1); 78% of patients present with chest pain, 24% with shoulder pain. Bacteremia was present in 62%, fever in 65% and 56% experienced leukocytosis (3). Our patient had all of the aforementioned findings.

Because standard x-rays often reveal nonspecific age-related changes, magnetic resonance imaging is the imaging modality of choice for investigating SCJ infections and its complications, although CT scanning can also be used (5). Typical radiographic features include joint effusion, widening of the joint space or mild cortical irregularity (5). CT- or ultrasound-guided aspiration may provide fluid for diagnosis, which often displays, as in other cases of septic arthritis, an elevated white blood cell count, and positive Gram stain and/or bacterial/fungal cultures. Unfortunately, SCJ effusions are often small and difficult to aspirate due to the presence of the SCJ intra-articular disc. Definitive diagnosis can be obtained through surgical intervention using samples sent for culture.

SCJ septic arthritis should be treated with antibiotics for four weeks, or longer if osteomyelitis or other complications are present. In some cases, surgical intervention may be required to achieve adequate source control (1,5). If possible, antibiotic regimens should be based on Gram stain and cultures. Empirical regimens should include agents that are effective against methicillin-resistant *S aureus* if risk factors are present (1,3). This patient's regimen consisted of appropriate empirical *S pneumoniae* treatment.

Untreated septic arthritis has a 10% mortality risk (1). Complications of SCJ septic arthritis includes osteomyelitis (50%) (3) and mediastinitis (15%) (1). In septic joint infections secondary to *S pneumoniae*, there is permanent loss of joint function in 25% to 50% of cases (2). Physicians and patients should be aware of such potentially long-term sequelae, including the torticollis observed in the present case. Patient counselling is important for managing expectations regarding recovery. Appropriate pain medication regimens are also necessary in facilitating recovery, and potential risks and benefits of both opioid and nonopioid medications should be discussed.

CONCLUSION

S pneumoniae is an unusual cause of septic arthritis. In the present case it caused SCJ septic arthritis and osteomyelitis, resulting in the patient's presentation with fever, pain and torticollis. Important considerations include early initiation of appropriate empirical antibiotic therapy, and identification of precipitants, risk factors and/or potential complications, such as osteomyelitis or mediastinitis that may require longer treatment duration or surgical intervention. The present case highlights the significant morbidity of SCJ infection, even in the absence of such complications. Despite therapy, joint infections, such as in the present case, often lead to permanent damage, loss of function and chronic pain.

REFERENCES

1. Womack J. Septic arthritis of the sternoclavicular joint. J Am Board Fam Med 2012;25:908-91.
2. Belkhir L, Rodrigues-Villalobos H, Vandercam JC, et al. Pneumococcal septic arthritis in adults: Clinical analysis and review. Acta Clin Belg 2014;69:40-6.
3. Ross JJ, Shamsuddin H. Sternoclavicular septic arthritis: Review of 180 cases. Medicine (Baltimore) 2004;83:139-48.
4. Ross JJ, Saltzman CL, Carling P, Shapiro DS. Pneumococcal septic arthritis: Review of 190 cases. Clin Infectious Disease 2003;136:319-27.
5. Gallucci F, Esposito P, Carnovale A, et al. Primary sternoclavicular septic arthritis in patients without predisposing risk factors. Adv Med Sci 2007;52:125-8.