

CASE REPORTS

CLINICAL ASPECTS OF DIAGNOSIS AND TREATMENT OF ELONGATED STYLOID PROCESS SYNDROME

PIOTR ARKUSZEWSKI, ALEKSANDER PRZYGOŃSKI, MARTA TYNDORF

Department of Cranial, Maxillofacial and Oncological Surgery in Łódź
Kierownik: prof. dr hab. *P. Arkuszewski*

Eagle's syndrome is a rare cause of chronic cervical and throat pain connected with styloid process elongation. The etiology of this disorder remains unclear. The authors presented four cases of symptomatic, one-sided and both-sided elongation of the styloid process. Moreover, the study presented aspects of diagnosis and treatment of Eagle's syndrome. The Authors especially focused on surgical techniques.

Key words: styloid process, Eagle's syndrome, surgical treatment

In 1937, Watt W. Eagle was the first to describe the case of cervical and throat pain connected with styloid process elongation (1-10). Twenty-five millimeters was considered as the borderline value of a normal styloid process, although literature data mentioned values ranging between 20 and 50 mm (6, 11-14).

The etiology of Eagle's syndrome remains unclear. Considering the classical case of the syndrome characterized by chronic throat pain, intensifying during the swallowing process, as well as the feeling of a foreign body in the throat, which develops after the excision of the palatine tonsils, one may observe the development of a scar, being responsible for the above-mentioned. The connective tissue which develops during the healing process adheres to the apex of the elongated styloid process. The tightening connective tissue can compress the V, VII, IX, X, XI and XII cranial nerves. In case of stylohyoid ligament calcification contracture of the stylohyoid muscle leads towards latero-superior displacement of the wall of the throat during swallowing, yawning and mastication. This in turn leads towards glossopharyngeal nerve traction responsible for pain (2, 8, 12, 15, 16).

The second type of Eagle's syndrome (not connected with tonsillectomy) is characterized by cervical pain, especially when rotating the head, radiating to the ear. This is connected with the localization of the styloid process between the external and internal carotid arteries. Every change in the angle of the styloid process, its elongation or mineralization of the stylohyoid ligament can lead towards compression of the sympathetic plexus and carotid vessels (4, 6, 9, 12). The cause of styloid process elongation remains unclear. The following hypotheses are considered: congenital elongation connected with persistent cartilage analogue (stylohyal) presence during embryogenesis, calcification following trauma, the process of aging, and inflammatory reasons (6, 7, 16).

The diagnosis of Eagle's syndrome is based on the clinical presentation and X-ray examinations. During the physical examination of the oral cavity and throat, pain is often observed during the palpation of the palatine tonsil. The styloid process can be palpated when it exceeds 75 mm. The anatomy, length and angle of the styloid process are best determined by means of computer tomography, especially 3D reconstruction. Lateral cranium X-rays, PA mandibular X-rays (Town's projec-

tion), and orthopantomograms are also helpful. In case of the latter, one should bear in mind its enlargement, in comparison to the actual size. 28 mm is considered as the borderline size of the styloid process. In order to confirm the diagnosis, one should place a local anesthetic agent in the fundus of the palatine tonsil (4, 5, 11, 12, 13).

Treatment of Eagle's syndrome consists in conservative therapy, such as local anesthesia and steroid injections to the styloid process. Radical methods include the excision of the styloid process or stylohyoid complex.

CASE REPORTS

During the past years four patients were treated at the Department of Cranial, Maxillary, Facial, and Oncological Surgery with diagnosis of Eagle's syndrome. The study group comprised three male and one female patient, aged between 53 and 71 years. The first female patient (62 years old) was admitted to the Department of Neurosurgery, due to left-sided cranial and cervical pain. Symptoms intensified when rotating the head and neck, laterally. Computer tomography of the head and neck showed degenerative changes of the cervical spine and a significantly elongated left styloid process. Other possibilities responsible for the above-mentioned symptoms were excluded and the patient was referred to our department. We proposed the resection of the styloid process from the intraoral approach. Surgery was performed under general, tracheal anesthesia. The postoperative period proved uneventful. Thirty-six months after the procedure recurrence of symptoms was not observed.

The second 71-year old male patient was referred by an otolaryngologist, who excluded all possible causes of right-sided throat pain, and feeling of a foreign body „bulge” in the throat. The patient underwent surgery of the palatine tonsils thirty years before. Computer tomography showed an elongated right styloid process. As in case of the previous patient we proposed the resection of the styloid process from the intraoral approach. Surgery was performed under general anesthesia. Symptoms completely regressed and did not recur during the 29-month observation period.

The third 57-year old patient was referred to our department after a neurological consul-

tation. The patient presented with an elongated right styloid process observed on a screening pantomogram during the course of dental prosthetic treatment. The patient complained of right-sided cervical and cranial pain. The patient did not agree to the proposed surgical treatment. Conservative therapy was initiated, consisting in the injection of a 1% lidocaine solution into the area of the styloid process. The patient remained under our control, although he has not showed up recently for control visits.

The fourth, 53 year old male patient was admitted to our department, due to cervical pain radiating to the right ear, intensifying during the rotation of the head. Vegetative symptoms, such as nausea and dizziness were absent. The patients' history showed no laryngological or neurological diseases, except for the fracture of the right styloid process, ten years before. Additionally, the patient had a history of cerebral stroke (10 and 12 years ago) and hypertension. The only abnormality observed during the physical examination was the weakening of the left muscular force (5/6). The bimanual palpation examination showed a solid mass in the right parapharyngeal area. The pantomogram showed an elongated right styloid process and mineralization of the stylohyoid ligament with the presence of pseudarthrosis. A round shadow in the left styloid process was also observed suggesting the presence of an osteoma (fig. 1). In order to precisely determine the anatomical localization of both styloid processes, 3D reconstruction computer tomography was performed (fig. 2, 3, 4). We decided to perform a two-staged operation. During the first stage of the procedure the incision was performed in the retromandibular area, reaching the styloid process tumor, which was signifi-

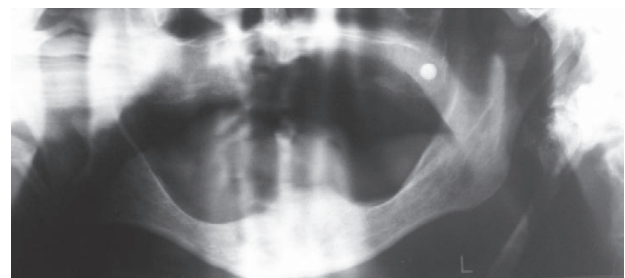


Fig. 1. Orthopantomogram— visible elongation of both styloid processes and round shadow suggesting the possibility of an osteoma of the left stylohyoid ligament

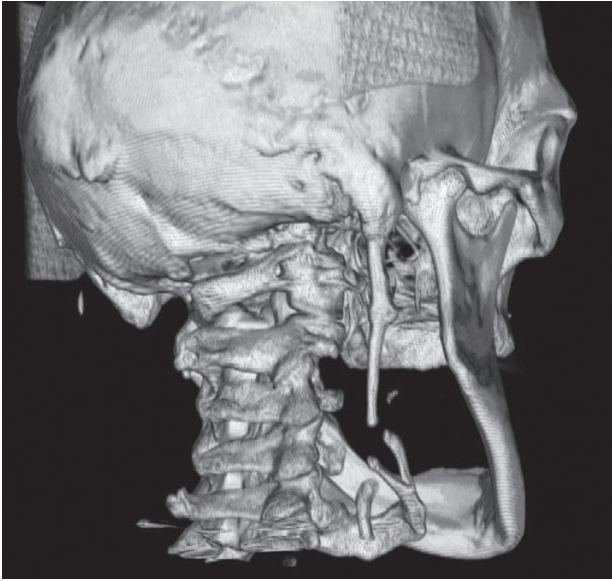


Fig. 2. 3D reconstruction computer tomography- visible elongated styloid process and mineralization of the right stylohyoid ligament

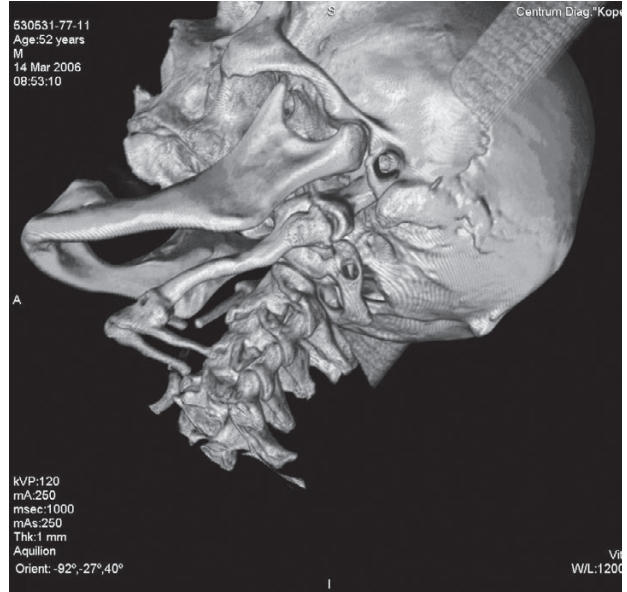


Fig. 3. 3D reconstruction computer tomography – calcification of the stylohyoid ligament, pseudarthrosis of the left elongated styloid process

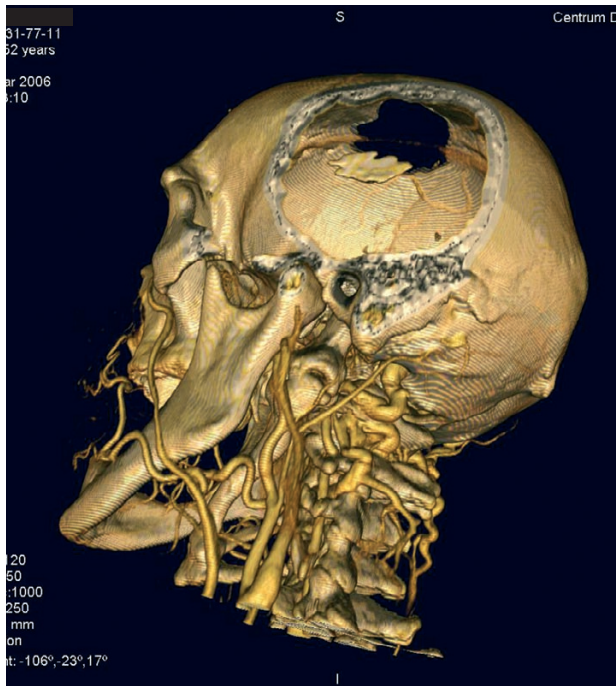


Fig. 4. 3D reconstruction computer tomography – styloid process in relationship to the carotid arteries on the left side

cantly deformed. The stylohyoid ligament formed a solid osseous structure, 5mm in diameter. In the center of the tumor we observed cartilage-connective tissue adhesions, corresponding to pseudarthrosis. The described structure was excised at the level of the hyoid bone and base of the styloid process.

The postoperative period proved uneventful. Due to the patients' general condition the second part of the operation was postponed for a period of 1.5 years. Under general anesthesia by means of the extraoral approach the styloid process was excised. The patient remains under outpatient control. During the 2.5 year observation period recurrence was not diagnosed.

DISCUSSION

The only effective method of treatment in case of Eagle's syndrome is the surgical excision of the styloid process. Both the intraoral and extraoral approach methods are effective (1, 11, 15, 17-20). In case of the intraoral approach local anesthesia might prove sufficient. Surgery is shorter and scars are absent. The incision is performed in the vicinity of the fundus of the palatine tonsil, followed by the separation of the muscle and ligament attachments from the styloid process. The next stage of the operation consists in the elevation of the periosteum followed by the excision of the elongated styloid process. The wound is closed layer by layer (7, 10, 17). According to Pereira and co-authors (6), if the palatine tonsil is localized in its pouch the first stage of the operation consists in its excision. However, the extraoral approach is connected with the risk of complications, such as deep cervical

infections connected with the translocation of bacteria colonizing the mucous membrane of the oral cavity. Poor visualization of the operative field is also a problem, which might lead towards damage of the external carotid artery, and V, VII, IX, X, XI cranial nerves. Additionally, postoperative cerebral edema is also a problem, being responsible for breathing, swallowing, and speech disturbances (4, 6, 7, 10, 15). The extraoral approach is preferred in case of patients without previous palatine tonsil surgery (5). The above-mentioned procedure is performed under general, tracheal anesthesia. The patient is in the supine position with slightly elevated shoulders and the head turned towards the healthy side (6). The following skin incisions are proposed: parallel to the sternocleidomastoid muscle, low submandibular, and modified incision used in case of facial elevation (1, 5, 6). The extraoral approach enables better visualization of the operative field, especially in the area of the bifurcation of the carotid artery. Unfortunately, a visible scar is observed, its

intensification depending on the approach method used. Each time the use of a neurostimulator is recommended, in order to prevent damage of the cranial nerves (1, 6, 7, 10, 12, 16).

Eagle's syndrome is a rare disease entity, although should always be considered during differential diagnosis of cervical, facial, and throat pain. Precise clinical examination and history of the disease might lead towards suspicion of elongated styloid process syndrome. Initial diagnosis can be supplemented by the cheap and easily accessible diagnostic imaging method, the pantomogram. In order to plan treatment, imaging of the styloid processes is a necessity, with the determination of the degree of their elongation and localization, in relationship to significant anatomical structures observed in 3D reconstruction computer tomography. The therapeutic method should be chosen, according to individual needs bearing in mind that regression of symptoms is only possible after surgical treatment.

REFERENCES

1. Buono U, Mangone GM, Michelotti A et al.: Surgical approach to stylohyoid process in Eagle's syndrome. *J Oral Maxillofac Surg* 2005; 63: 714-16.
2. Cernea CR, Hojaij CH, Carlucci D et al.: First bite syndrome after resection of the styloid process. *Laryngoscope* 2007; 117: 181-82.
3. Chuang WC, Short JH, McKinney AM et al.: Reversible left hemispheric ischemia secondary to carotid compression in Eagle syndrome: surgical and CT angiographic correlation. *Am J Neuroradiol* 2007; 28: 143-45.
4. Fini G, Gasparini G, Filippini F et al.: The long styloid process syndrome or Eagle's syndrome. *J Cranio Maxillofac Surg* 2000; 28: 123-27.
5. Mendelsohn AH, Berke GS, Chhetri DK: Heterogeneity in the clinical presentation of Eagle's syndrome. *Otolaryngol Head Neck Surg* 2006; 134: 389-93.
6. Pereira FL, Filho LI, Pavan AJ et al.: Styloid-stylohyoid syndrome: literature review and case report. *J Oral Maxillofac Surg* 2007; 65: 1346-53.
7. Qureshy FA, Gold ES, Arnold J et al.: Eagle's syndrome in an 11-year-old patient. *J Oral Maxillofac Surg* 2001; 59: 94-97.
8. Rizzatti Barbosa C, Lopes EB, Albergaria Barbosa JR et al.: Eagle's syndrome associated with temporomandibular disorder: a clinical report. *J Prosthet Dent* 1999; 81: 649-51.
9. Setubal Andrade MG, Teixeira Marchionni AM, Crusoe Rebelo I et al.: Three-dimensional identification of vascular compression in Eagle's syndrome using computed tomography: case report. *J Oral Maxillofac Surg* 2008; 66: 169-76.
10. Westhuijzen AJ, Merwe J, Grotelpass FW: Eagle's syndrome: lesser cornu amputation: an alternative surgical solution? *J Oral Maxillofac Surg* 1999; 28: 335-37.
11. Albrquerque RF, Muller K, Hotta TH et al.: Temporomandibular disorder or Eagle's syndrome? A clinical report. *J Proshet Dent* 2003; 90: 317-20.
12. Ghosh LM, Dubey SP: The syndrome of long-gated styloid process. *Auris Nasus Larynx* 1999; 26: 169-75.
13. Lee S, Hillel A: Three-dimensional computed tomography imaging of Eagle's syndrome. *Am J Otolaryngol* 2004; 25: 109.
14. Lorman JG, Biggs JR: The Eagle syndrome. *AJR* 1983; 140: 881-82.
15. Bafaqeh SA: Eagle syndrome: classic and carotid artery types. *J Otolaryngol* 2000; 29: 88-94.
16. Murtagh RD, Caracciolo JT, Fernandez G: CT findings associated with Eagle syndrome. *Am J Neuroradiol* 2001; 22: 1401-02.
17. Beder E, Ozgursoy OB, Ozgursoy SK: Current diagnosis and transoral surgical treatment of Ea-

gle's syndrome. *J Oral Maxillofac Surg* 2005; 63: 1742-45.

18. *Salomone FN, Falcigilla M, Steward DL*: Eagle's syndrome reconsidered as cervical manifestation of heterotopic ossification: Woman presenting with a neck mass. *Otolaryngol Head Neck Surg* 2004, 4: 501-03.

19. *Stavin KV*: Eagle syndrome: entrapment of glossopharyngeal nerve? Case report and review of the literature. *J Neurosurg* 2002; 97: 216-18.

20. *Thun-Szretter K, Jankowska M, Małkal N i wsp.*: Ocena wyrostków rylcowatych na zdjęciach pantomograficznych – doniesienie wstępne. *Czas Stomatol* 2006; 59: 670-78.

Received: 8.06.2010 r.

Adress correspondence: 90-153 Łódź, ul. Kopcińskiego 22