IMAGES IN CARDIOVASCULAR MEDICINE
DOI 10.4070/kcj.2010.40.5.251

Print ISSN 1738-5520 / On-line ISSN 1738-5555

Open Access

Multidetector Computed Tomography for Evaluation of Ischemic Etiology and a Post-Unroofing Procedure for an Anomalous Origin of the Right Coronary Artery From the Left Sinus of Valsalva

Man Zhang, MD[1,2], Woong Chol Kang, MD[2], Tae Hoon Ahn, MD[2] and Eak Kyun Shin, MD[2]

[1]*Department of Cardiology, Fengtian Hospital Affiliated to Shenyang Medical College, Shenyang, Liaoning Province, China*
[2]*Department of Cardiology, Gil Medical Center, Gachon University of Medicine and Science, Incheon, Korea*

An anomalous origin of the right coronary artery (RCA) is a rare congenital anomaly. If it runs between the pulmonary artery and aorta, it may cause acute myocardial infarction (AMI) and sudden death.[1-4] Identification of coronary anomalies is sometimes difficult by coronary angiography because of the lack of three-dimensional information. A 34-year old male patient presented with an inferior wall AMI. Coronary angiography showed that the RCA originated from the left sinus of Valsalva close to the left main coronary artery (Fig. 1). Coronary spasm was considered as the etiology of the AMI. Ten months after the first attack, the patient was readmitted due to an inferior wall AMI. Multidetector computed tomography (MDCT) showed that the RCA originated from the left sinus of Valsalva, and ran between the aortic root and the main pulmonary trunk (Fig. 2A). The axial image showed an acute-angled takeoff of the RCA from the ascending aorta and a small orifice of the RCA which was thought to be the main mechanism for the ischemia (Fig. 2B). Findings during surgery showed the RCA ostium with a small slit-like orifice that originated at the left sinus of Valsalva with an acute angle and the proximal portion of the RCA was located beside the commissure, between the right and left cusps, which were embedded in the aortic wall (Fig. 2C). After the operation, MDCT and coronary angiogra-

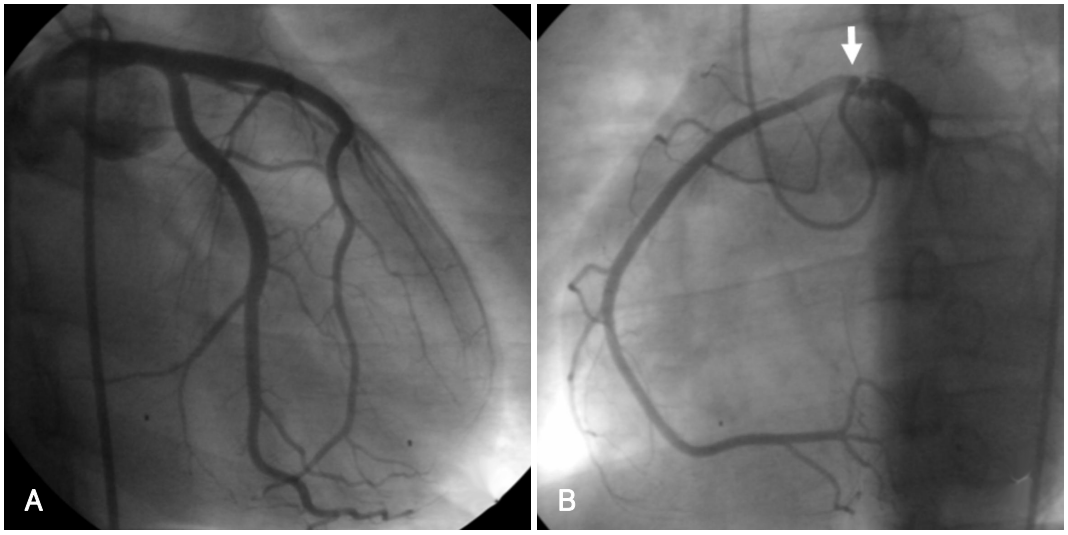

Fig. 1. Coronary angiography showed there were no significant lesions at LAD and LCX (A). However, RCA could not be found at its usual location. It originated from left sinus of Valsarva (white arrow) close to the left main coronary artery with diffuse minimal stenosis at its proximal segment (B). But there was no significant stenosis at ostium of RCA. LAD: left anterior descending coronary artery, LCX: left circumflex artery, RCA: right coronary artery.

Received: August 11, 2009 / **Revision Received**: October 21, 2009 / **Accepted**: October 21, 2009
Correspondence: Woong Chol Kang, MD, Department of Cardiology, Gil Medical Center, Gachon University of Medicine and Science, 1198 Guwol-dong, Namdong-gu, Incheon 405-760, Korea
Tel: 82-32-460-3046, 3674, Fax: 82-32-460-3117, E-mail: kangwch@gilhospital.com

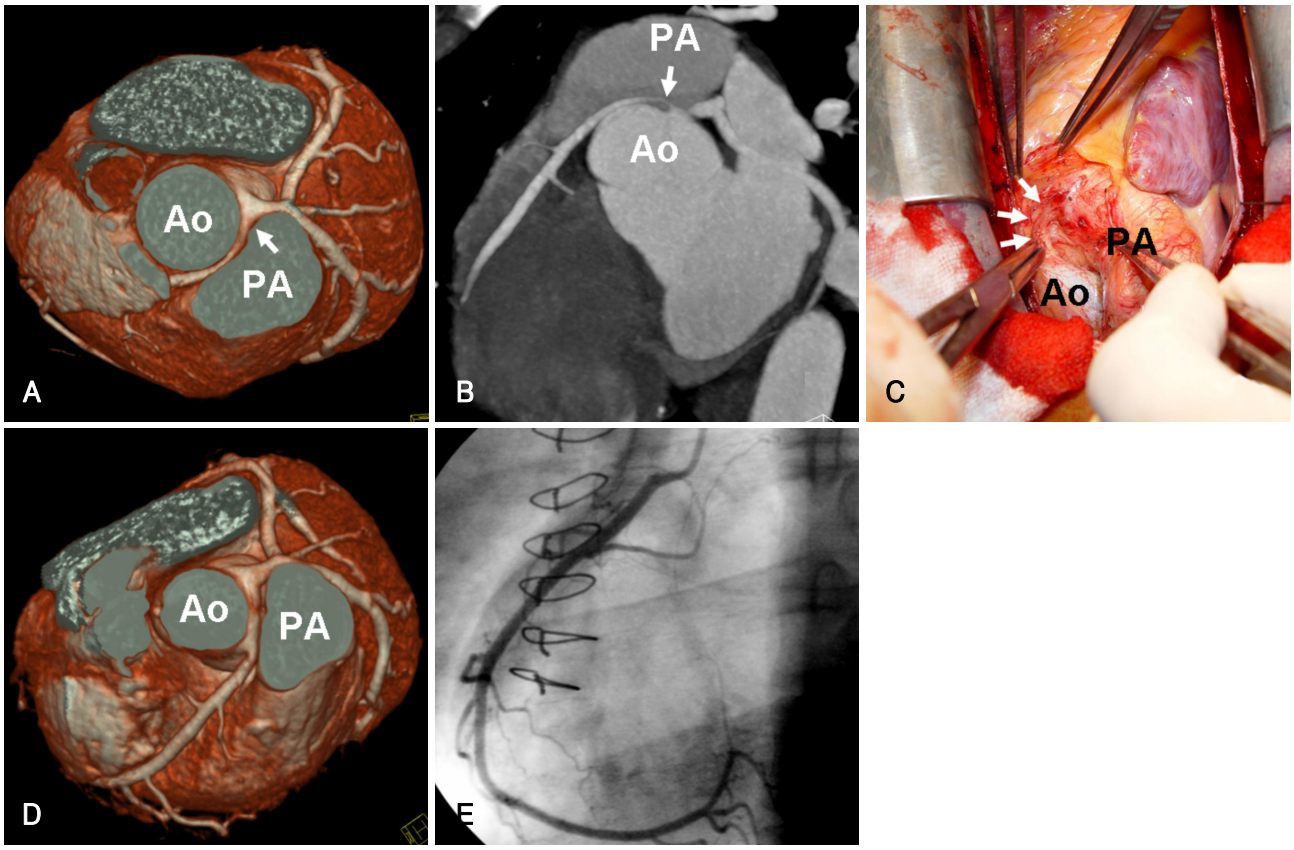

Fig. 2. MDCT showed RCA originated from left sinus of Valsalva (white arrow), separate from the left main coronary artery, and courses anteriorly between aortic root and main pulmonary trunk (A). The maximum intensity projection image showed an acute-angled takeoff of the RCA (white arrow) from the ascending aorta and small orifice of RCA (B). Operative findings showed RCA ostium with small slit-like orifice was originated left sinus of Valsalva with acute angle and proximal portion of RCA (white arrows) was located beside the commissure between the right and left cusps which is embedded in aortic wall (C). After operation (unroofing procedure), follow-up MDCT and coronary angiography showed good patency of RCA (D and E).

phy showed good patency of the RCA and the patient was doing well and was free of symptoms (Fig. 2D and E). Our case showed that when a coronary anomaly, especially an anomalous origin of the RCA, is noted on coronary angiography, MDCT may provide important information about ischemic mechanisms.

REFERENCES

1) Basso C, Maron BJ, Corrado D, Thiene G. *Clinical profile of congenital coronary artery anomalies with origin from the wrong aortic sinus leading to sudden death in young competitive athletes. J Am Coll Cardiol 2000;35:1493-501.*
2) Moon JY, Jeong HC, Cho JY, et al. *Anomalous origin of a right coronary artery with extrinsic compression between the great vessels: the intravascular ultrasound images. Korean Circ J 2008;38:390-2.*
3) Cheitlin MD, De Castro CM, McAllister HA. *Sudden death as a complication of anomalous left coronary origin from the anterior sinus of Valsalva, a not-so-minor congenital anomaly. Circulation 1974;50:780-7.*
4) Virmani R, Chun PK, Goldstein RE, Rabinowitz M, McAllister HA. *Acute take-off of the coronary arteries along the aortic wall and congenital coronary ostial ridges: association with sudden death. J Am Coll Cardiol 1984;3:766-71.*