10.5005/jp-journals-10011-1254

REVIEW ARTICLE

Classification System for Oral Submucous Fibrosis

Chandramani Bhagvan More, Swati Gupta, Jigar Joshi, Saurabh N Varma

ABSTRACT

Oral submucous fibrosis (OSMF) is a potentially malignant disorder (PMD) and crippling condition of oral mucosa. It is a chronic insidious scarring disease of oral cavity, pharynx and upper digestive tract, characterized by progressive inability to open the mouth due to loss of elasticity and development of vertical fibrous bands in labial and buccal tissues. OSMF is a debilitating but preventable oral disease. It predominantly affects people of Southeast Asia and Indian subcontinent, where chewing of arecanut and its commercial preparation is high. Presence of fibrous bands is the main characteristic feature of OSMF. The present literature review provides the compilation of various classification system based on clinical and/or histopathological features of OSMF from several databases. The advantages and drawbacks of these classifications supersede each other, leading to perplexity. An attempt is made to provide and update the knowledge about this potentially malignant disorder to health care providers in order to help in early detection and treatment, thus reducing the mortality of oral cancer.

Keywords: Classification of oral submucous fibrosis, Fibrous bands, Gutkha, OSMF, Potentially malignant disorder.

How to cite this article: More CB, Gupta S, Joshi J, Varma SN. Classification System for Oral Submucous Fibrosis. J Indian Aca Oral Med Radiol 2012;24(1):24-29.

Source of support: Nil

Conflict of interest: None declared

INTRODUCTION

Oral submucous fibrosis (OSMF) is also called as 'diffuse oral submucous fibrosis', 'idiopathic scleroderma of mouth', 'idiopathic palatal fibrosis', 'sclerosing stomatitis', 'juxta-epithelial fibrosis', etc. It is a potentially malignant disorder (PMD) and crippling condition of oral mucosa.[1] OSMF is a chronic insidious scarring disease of oral cavity, pharynx and upper digestive tract, characterized by sunken cheeks (Fig. 1A) progressive inability to open the mouth (Fig. 1B) due to loss of elasticity and development of vertical fibrous bands in labial and buccal tissues and shrunken uvula (Figs 2A and B).[2-5] OSMF is a debilitating but preventable oral disease.[2] It was first reported by Schwartz in 1952 among five Indian females from Kenya and he designated the term 'Atropica Idiopathica Mucosae Oris' to this condition. In 1953, Joshi described this condition as 'Submucous fibrosis'.[6-8] A condition resembling OSMF was described as early as 600 BC by Sushruta and it was named as 'VIDARI' having features of progressive narrowing of mouth, depigmentation of oral mucosa and pain on taking food.[3]

Oral submucous fibrosis is preceded by symptoms like burning sensation of the oral mucosa, ulceration and pain.[3] The characteristic features of OSMF are reduced movement and depapillation of tongue (Fig. 2C), blanching and leathery texture of oral mucosa (Fig. 2D), loss of pigmentation of oral mucosa (Fig. 2E), and progressive reduction of mouth opening.[7,9,10] In advanced cases, nasal twang due to fibrosis of nasopharynx and hearing impairment due stenosis of eustachian tube is significantly observed.[11] Most patients with OSMF present with irreversible moderate-to-severe condition. The changes of OSMF are similar to those of systemic sclerosis (scleroderma) but are limited to oral tissues.[7]

OSMF occurs at any age but is most commonly seen in adolescents and adults especially between 16 and 35 years. It is predominantly seen in Southeast Asia and Indian subcontinent with few cases reported from South Africa, Greece and United Kingdom.[12] It may be associated with oral leukoplakia (Fig. 3A) and other potentially malignant disorders or with oral malignancy (Fig. 3B).[7] The prevalence rate of OSMF in India is about 0.2 to 0.5%.[7,13] The reasons for the rapid increase in the prevalence is due to an upsurge in the popularity of commercially prepared arecanut and tobacco preparations—gutkha, pan masala, mawa, flavored supari, etc.[7]

The etiology of OSMF is multifactorial but arecanut chewing is the main causative agent.[3,7] Unlike other PMDs, OSMF is insidious in origin and is not amenable to reverse at any stage of the disease process, either spontaneously or with cessation of habit.[3] The condition may remain either stationary or become severe, leaving an individual handicapped, both physically and psychologically.[3,7] Diagnosis and staging thus becomes very important as it affects the treatment.[7,14] Medical treatment is symptomatic

Figs 1A and B: Extraoral view showing: (A) Sunken cheeks and prominent malar bone, (B) reduced mouth opening

JAYPEE

Figs 2A to E: Intraoral view showing: (A) Marble-like appearance of soft palate, faucial pillars and upper pharyngeal mucosa, (B) shrunken uvula, blanching of left buccal mucosa and retromolar region, (C) fibrosis and depapillation of tongue, (D) blanching of right buccal mucosa and (E) fibrosis and pigmentation of lower lip

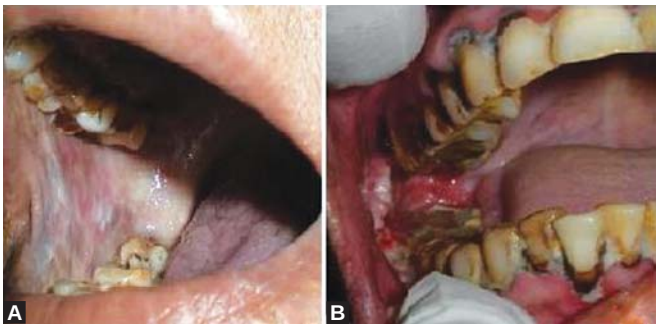

Figs 3A and B: Oral submucous fibrosis associated with (A) oral leukoplakia, (B) oral malignancy

and predominantly aimed at improving mouth movements. But each treatment has its own limitations.

Several classifications based on clinical and histological features, have been put forth by various researchers, based on different aspects of OSMF. The advantages and disadvantages of these classifications supersede the other leading to confusion. The purpose of the present literature review was to compile and analyze several classifications of OSMF available at various databases so as to assist the clinician, researchers and academicians in the categorization of this potentially malignant disorder according to its biological behavior and hence its subsequent medical and surgical management. The details of our search is as under:

A. Classifications based on clinical features of OSMF are as follows:
   - JV Desa (1957)
   - Pindborg JJ (1989)
   - SK Katharia et al (1992)
   - Lai DR et al (1995)
   - R Maher et al (1996)
   - Ranganathan K et al (2001)
   - Rajendran R (2003)
   - Nagesh and Bailoor (2005)
   - Tinky Bose and Anita Balan (2007)
   - Kiran Kumar et al (2007)
   - Chandramani More et al (2011)

B. Classifications based on histopathological features:
   - Pindborg JJ and Sirsat SM (1966)
   - Utsunomiya H et al (2005)
   - Kiran Kumar et al (2007)

C. Classification based on clinical and histopathological features:
   - Khanna JN et al (1995)

1. Classification based on clinical features of OSMF:
   - JV Desa (1957) divided OSMF into three stages as follows:[15]
     – *Stage I:* Stomatitis and vesiculation
     – *Stage II:* Fibrosis
     – *Stage III:* As its sequelae
   - Pindborg JJ in 1989 divided OSMF into three stages as follows:[16]
     – *Stage I:* Stomatitis includes erythematous mucosa, vesicles, mucosal ulcers, melanotic mucosal pigmentation and mucosal petechiae.
     – *Stage II:* Fibrosis occurs in healing vesicles and ulcers, which is the hallmark of this stage.
       - Early lesions show blanching of the oral mucosa.
       - Older lesions include vertical and circular palpable fibrous bands in the buccal mucosa and around the mouth opening or lips.
       - This results in a mottled marble like appearance of the mucosa because of the vertical thick, fibrous bands in association with a blanched mucosa.
       - Specific findings include reduction of mouth opening, stiff and small tongue, blanched and leathery floor of the mouth, fibrotic and de-pigmented gingiva, rubbery soft palate with decreased mobility, blanched and atrophic tonsils, shrunken bud like uvula and sunken cheeks, not commensurate with age or nutritional status.
     – *Stage III:* Sequelae of OSMF are as follows:
       - Leukoplakia is found in more than 25% of individuals with OSMF.
       - Speech and hearing deficit may occur because of involvement of tongue and the eustachian tube.
   - SK Katharia et al (1992) have given different scores assigned to the patients on the basis of mouth opening

between upper and lower central incisors as follows:[13]
- *Score 0:* Mouth opening is 41mm or more
- *Score 1:* Mouth opening is 37 to 40 mm
- *Score 2:* Mouth opening is 33 to 36 mm
- *Score 3:* Mouth opening is 29 to 32 mm
- *Score 4:* Mouth opening is 25 to 28 mm
- *Score 5:* Mouth opening is 21 to 24 mm
- *Score 6:* Mouth opening is 17 to 20 mm
- *Score 7:* Mouth opening is 13 to 16 mm
- *Score 8:* Mouth opening is 09 to 12 mm
- *Score 9:* Mouth opening is 05 to 08 mm
- *Score 10:* Mouth opening is 0 to 04 mm.

- Lai DR (1995) divided OSMF based on the inter-incisal distance as follows:[16]
  - *Group A:* >35 mm
  - *Group B:* Between 30 and 35 mm
  - *Group C:* Between 20 and 30 mm
  - *Group D:* <20 mm
- R Maher et al (1996) had given criteria for evaluation of interincisal distance as an objective criterion of the severity of OSMF in Karachi, Pakistan. In his study, he divided intraoral regions into eight anatomical subregions *viz* palate, posterior one-third of buccal mucosa, mid one-third of the buccal mucosa, anterior one-third of buccal mucosa, upper labial mucosa, tongue and floor of mouth and looked for disease involvement in each to assess the extent of clinical disease. This was further grouped into three categories as follows:[17]
  - Involvement of one-third or less of the oral cavity (if three or less of the above sites are involved).
  - Involvement of one to two-thirds of the oral cavity (if four to six intraoral sited are involved).
  - Involvement of more than two-thirds of the oral cavity (if more than six intraoral sites are involved).
- Ranganathan K et al (2001) divided OSMF based on mouth opening as follows:[16,18]
  - *Group I:* Only symptoms, with no demonstrable restriction of mouth opening.
  - *Group II:* Limited mouth opening 20 mm and above.
  - *Group III:* Mouth opening less than 20 mm.
  - *Group IV:* OSMF advanced with limited mouth opening. Precancerous or cancerous changes seen throughout the mucosa.
- Rajendran R (2003) reported the clinical features of OSMF as follows:[16]
  - *Early OSF:* Burning sensation in the mouth. Blisters especially on the palate, ulceration or recurrent generalized inflammation of oral mucosa, excessive salivation, defective gustatory sensation and dryness of mouth.
  - *Advanced OSF:* Blanched and slightly opaque mucosa, fibrous bands in buccal mucosa running in vertical direction. Palate and faucial pillars are the areas first involved. Gradual impairment of tongue movement and difficulty in mouth opening.
- Nagesh and Bailoor (1993):[19]
  - *Stage I early OSMF:* Mild blanching, no restriction in mouth opening (normal distance between central incisor tips: Males 35 to 45 mm, females 30 to 42 mm), no restriction in tongue protrusion (normal mesioincisal angle of upper central incisor to the tip of the tongue when maximally extended with the mouth wide open: Males 5 to 6 cm, females 4.5 to 5.5 cm. Cheek flexibility CF = V1-V2, two points measured between; V2 = is marked at 1/3rd the distance from the angle of the mouth on a line joining the tragus of the ear and the angle of the mouth and V1 = the subject is then asked to blow his cheeks fully, and the distance measured between the two points marked on the cheek. Mean value for males = 1.2 cm, females = 1.08 cm. Burning sensation on taking spicy food or hot beverages.
  - *Stage II moderate OSMF:* Moderate to severe blanching, mouth opening reduced by 33%, cheek flexibility also demonstrably reduced, burning sensation also in absence of stimuli, palpable bands felt. Lymphadenopathy either unilateral or bilateral and demonstrable anemia on hematological examination.
  - *Stage III severe OSMF:* Burning sensation is very severe patient unable to do day-to-day work, more than 66% reduction in the mouth opening, cheek flexibility and tongue protrusion. Tongue may appear fixed. Ulcerative lesions may appear on the cheek, thick palpable bands and lymphadenopathy bilaterally evident.
- Tinky Bose and Anita Balan (2007) had given clinical classification, categorized the patients into three groups based on their clinical presentations:[20]
  - *Group A—mild cases:* Only occasional symptoms, pallor, vesicle formation, presence of one or two solitary palpable bands, loss of elasticity of mucosa, variable tongue involvement with protrusion beyond vermillion border. Mouth opening >3 cm.
  - *Group B—moderate cases:* Symptoms of soreness of mucosa or increased sensitivity to

chilies, diffuse involvement of the mucosa, blanched appearance, buccal mucosa tough and inelastic fibrous bands palpable, considerable restriction of mouth opening (1.5 to 3 cm) and variable tongue movement.

– *Group C—severe cases:* Symptoms more severe, broad fibrous bands palpable, blanched opaque mucosa, rigidity of mucosa, very little opening of mouth (less than 1.5 cm), depapillated tongue and protrusion of tongue very much restricted.

- Kiran Kumar et al (2007) categorized three clinical stages of OSMF on the basis of mouth opening as follows:[1]
  – *Stage I:* Mouth opening >45 mm
  – *Stage II:* Restricted mouth opening 20 to 44 mm
  – *Stage III:* Mouth opening <20 mm
- Chandramani More et al (2011):[7]
  – *Clinical staging:*
    - *Stage 1 (S1):* Stomatitis and/or blanching of oral mucosa.
    - *Stage 2 (S2):* Presence of palpable fibrous bands in buccal mucosa and/or oropharynx, with /without stomatitis.
    - *Stage 3 (S3):* Presence of palpable fibrous bands in buccal mucosa and/or oropharynx, and in any other parts of oral cavity, with/ without stomatitis.
    - *Stage 4 (S4) as follows:*
      a. Any one of the above stage along with other potentially malignant disorders, e.g. oral leukoplakia, oral erythroplakia, etc.
      b. Any one of the above stage along with oral carcinoma.
  – *Functional staging:*
    - *M1:* Interincisal mouth opening up to or greater than 35 mm.
    - *M2:* Interincisal mouth opening between 25 and 35 mm.
    - *M3:* Interincisal mouth opening between 15 and 25 mm.
    - *M4:* Interincisal mouth opening less than 15 mm.

2. Classifications based on histopathological features of OSMF:
   - Pindborg JJ and Sirsat SM (1966) were the first to divide OSMF depending only on histopathological features alone are as follows:[16]
     – *Very early stage:* Finely fibrillar collagen dispersed with marked edema. Plump young fibroblast containing abundant cytoplasm. Blood vessels are dilated and congested. Inflammatory cells, mainly polymorphonuclear leukocytes with occasional eosinophils are found.
     – *Early stage:* Juxta-epithelial area shows early hyalinization. Collagen still in separate thick bundles. Moderate number of plump young fibroblasts is present. Dilated and congested blood vessels. Inflammatory cells are primarily lymphocytes, eosinophils and occasional plasma cells.
     – *Moderately advanced stage:* Collagen is moderately hyalinized. Thickened collagen bundles are separated by slight residual edema. Fibroblastic response is less marked. Blood vessels are either normal or compressed. Inflammatory exudate consists of lymphocytes and plasma cells.
     – *Advanced stage:* Collagen is completely hyalinized. Smooth sheets with no separate bundles of collagen is seen. Edema is absent. Hyalinized area is devoid of fibroblasts. Blood vessels are completely obliterated or narrowed. Inflammatory cells are lymphocytes and plasma cells.
   - Utsunomiya H, Tilakratne WM, Oshiro K et al (2005) histologically divided OSMF based on the concept of Pindborg and Sirsat and modified it as follows:[16]
     – *Early stage:* Large number of lymphocytes in subepithelial, connective tissue, zone along with myxedematous changes.
     – *Intermediate stage:* Granulation changes close to the muscle layer and hyalinization appears in subepithelial zone where blood vessels are compressed by fibrous bundles. Reduced inflammatory cells in subepithelial layer.
     – *Advanced stage:* Inflammatory cell infiltrate hardly seen. Number of blood vessels dramatically small in subepithelial zone. Marked fibrous areas with hyaline changes extending from subepithelial to superficial muscle layers. Atrophic, degenerative changes start in muscle fibers.
   - Kiran Kumar et al (2007) proposed histological grading as follows:[1]
     – *Grade I:* Loose, thick and thin fibers
     – *Grade II:* Loose or thick fibers with partial hyalinization
     – *Grade III:* Complete hyalinization

3. Classification based on clinical and histopathological features:
   - Khanna JN and Andrade NN (1995) developed a group classification system for the surgical management of OSMF.[16]
     - *Group I:*
       - *Very early cases:* Common symptom is burning sensation in the mouth, acute ulceration and recurrent stomatitis and not associated with mouth opening limitation.
       - *Histology:* Fine fibrillar collagen network interspersed with marked edema, blood vessels dilated and congested, large aggregate of plump young fibroblasts present with abundant cytoplasm, inflammatory cells mainly consist of polymorphonuclear leukocytes with few eosinophils. The epithelium is normal.
     - *Group II:* Early cases—Buccal mucosa appears mottled and marble like, widespread sheets of fibrosis palpable, interincisal distance of 26 to 35 mm.
       - *Histology:* Juxta-epithelial hyalinization present, collagen present as thickened but separate bundles, blood vessels dilated and congested, young fibroblasts seen in moderate number, inflammatory cells mainly consist of polymorphonuclear leukocytes with few eosinophils and occasional plasma cells, flattening or shortening of epithelial rete-pegs evident with varying degree of keratinization.
     - *Group III:* Moderately advanced cases—Trismus, interincisal distance of 15 to 25 mm, buccal mucosa appears pale firmly attached to underlying tissues, atrophy of vermilion border, vertical fibrous bands palpable at the soft palate, pterygomandibular raphe and anterior faucial pillars.
       - *Histology:* Juxta-epithelial hyalinization present, thickened collagen bundles, residual edema, constricted blood vessels, mature fibroblasts with scanty cytoplasm and spindle-shaped nuclei, inflammatory exudate which consists of lymphocytes and plasma cells, epithelium markedly atrophic with loss of rete pegs, muscle fibers seen with thickened and dense collagen fibers.
     - *Group IVA:* Advanced cases—severe trismus, interincisal distance of less than 15 mm, thickened faucial pillars, shrunken uvula, restricted tongue movement, presence of circular band around entire lip and mouth.
     - *Group IVB:* Advanced cases—presence of hyperkeratotic leukoplakia and/or squamous cell carcinoma.
       - *Histology:* Collagen hyalinized smooth sheet, extensive fibrosis, obliterated the mucosal blood vessels, eliminated melanocytes, absent fibroblasts within the hyalinized zones, total loss of epithelial rete pegs, presence of mild to moderate atypia and extensive degeneration of muscle fibers.

CONCLUSION

An attempt is made to provide and update the knowledge of classification system on OSMF so as to assist the clinician, researchers and academicians in the categorization of this potentially malignant disorder in order to help in early detection and its subsequent management thus reducing the mortality of oral cancer.

REFERENCES

1. Kumar Kiran, Saraswathi TR, Rangnathan K, Devi Uma M, Elizabeth Joshua. Oral submucous fibrosis: A clinico-histopathological study in Chennai. Indian Journal of Dental Research 2007;18(3):106-11.
2. Aziz Shahid R. Coming to America: Betel nut and oral submucous fibrosis. J Am Dent Assoc 2010;141:423-28.
3. More C, Asrani M, Patel H, Adalja C. Oral submucous fibrosis-A hospital-based retrospective study. Pearldent 2010;1(4): 25-31.
4. Kerr AR, Warnakulasuriya S, Mighell AJ, et al. A systematic review of medical interventions for oral submucous fibrosis and future research opportunities. Oral Diseases 2011;17(1): 42-57.
5. Warnakulasuriya S, Johnson Newell W, Waal I van der. Nomenclature and classification of potentially malignant disorders of the oral mucosa. J Oral Pathol Med 2007;36:575-80.
6. Mohammad Sami Ahmad, SA Ali, AS Ali, KK Chaubey. Epidemiological and etiological study of oral submucous fibrosis among gutkha chewers of Patna, Bihar, India. Journal of indian society of pedodontics and preventive dentistry 2006;24(2); 84-89.
7. More Chandramani, Das Sunanda, Patel Hetul, et al. Proposed clinical classification for oral submucous fibrosis. Oral Oncology; In Press.
8. Moger Ganapathi, Shashikanth MC. Oral submucous fibrosis in a 12-year-old boy-A rare case report. JIDA 2011;5(1);124-25.
9. Dyavanagoudar Sunita N. Oral submucous fibrosis: Review on etiopathogenesis. J Cancer Sci Ther 2009;1(2):72-77.
10. Lee Cheng-Kuang, Tsai Meng-Tsan, Lee Hsiang-Chieh, et al. Diagnosis of oral submucous fibrosis with optical coherence tomography. Journal of Biomedical Optics 2009;14(5);1-7.
11. Gnanam A, Kannadasan Kamal, Venkatachalapathy S, David Jasline. Multimodal treatment options for oral submucous fibrosis, SRM University. Journal of Dental Sciences 2010;1(1): 26-29.

12. Sabarinath B, Sriram G, Saraswathi TR, Sivapathasundharam B. Immunohistochemical evaluation of mast cells and vascular endothelial proliferation in oral submucous fibrosis. Indian Journal of Dental Research 2011;22(1):116-21.
13. Katharia SK, Singh SP, Kulshreshtha VK. The effects of placenta extract in management of oral submucous fibrosis. Indian Journal of Pharmacology 1992;24;181-83.
14. More C, Thakkar K. Oral submucous fibrosis-An insight. Journal of Pearldent 2010;1(3).
15. Tupkari JV, Bhavthankar JD, Mandale MS. Oral submucous fibrosis (OSMF). A study of 101 cases. Journal of Indian Academy of Oral Medicine and Radiology 2007;19(2): 311-18.
16. Rangnathan K, Gauri Mishra. An overview of classification schemes for oral submucous fibrosis. Journal of Oral and Maxillofacial Pathology, 2006 Jul-Dec;10(2):55-58.
17. Maher R, Sankaranarayanan R, Johnson NW, et al. Evaluation of inter-incisor distance as an objective criteion of the severity of oral submucous fibrosis in Karachi, Pakistan. Oral Oncology Eur Journal of Cancer 1996;32(5):362-64.
18. George Antony, Sreenivasan BS, S Sunil, et al. Potentially malignant disorders of oral cavity. Journal of Oral and Maxillofacial Pathology 2011;2(1):95-100.
19. Bailoor D, Nagesh KS. Fundamentals of oral medicine and radiology (1st ed), Year 2005.
20. Bose Tinky, Balan Anita. Oral submucous fibrosis-A changing scenario. Journal of Indian Academy of Oral Medicine and Radiology 2007;19(2):334-40.

ABOUT THE AUTHORS

Chandramani Bhagvan More (Corresponding Author)

Head, Department of Oral Medicine, KM Shah Dental College Vadodara, Gujarat, India, e-mail: drchandramanimore@rediffmail.com

Swati Gupta

Postgraduate Student, Department of Oral Medicine and Radiology KM Shah Dental College, Vadodara, Gujarat, India

Jigar Joshi

Postgraduate Student, Department of Oral Medicine and Radiology KM Shah Dental College, Vadodara, Gujarat, India

Saurabh N Varma

Postgraduate Student, Department of Oral Medicine and Radiology KM Shah Dental College, Vadodara, Gujarat, India