

Prevalence of Symptomatic Lumbar Spondylolysis in Pediatric Patients

AKIHIRO NITTA, MD; TOSHINORI SAKAI, MD, PHD; YUICHIRO GODA, MD; YOICHIRO TAKATA, MD, PHD; KOSAKU HIGASHINO, MD, PHD; TADANORI SAKAMAKI, MD, PHD; KOICHI SAIRYO, MD, PHD

abstract

Lumbar spondylolysis, a stress fracture of the pars interarticularis, is prevalent in adolescent athletes. Recent advances in diagnostic tools and techniques enable early diagnosis before these fractures progress to complete fractures through the pars. However, because patients often consult family physicians for primary care of low back pain and these physicians may not have access to diagnostic modalities such as magnetic resonance imaging (MRI) and computed tomography, stress fractures can be missed. This study surveyed the prevalence of symptomatic spondylolysis in pediatric patients who consulted an orthopedic clinic for primary care and investigated whether such acute stress fractures may be overlooked without MRI. The prospective study investigated 264 patients who were younger than 19 years and had low back pain. Of the 153 patients (58.0%) with low back pain persisting for longer than 2 weeks, 136 who agreed to undergo MRI were included in the study. This group included 11 elementary school students, 71 junior high school students, and 54 high school students. The overall prevalence of lumbar spondylolysis was 39.7% (54 of 136) and was 9.3% in elementary school students (5 of 11, 45.5%), 59.3% in junior high school students (32 of 71, 45.1%), and 31.5% in high school students (17 of 54, 31.5%). All 54 patients with spondylolysis had a history of athletic activity. Primary care physicians should recognize that approximately 40% of pediatric patients presenting with low back pain persisting for longer than 2 weeks may have spondylolysis and should consider MRI in those with a history of athletic activity. Because the spine is immature in this age group, almost half of affected elementary school and junior high school students may have lumbar spondylolysis. [*Orthopedics*. 2016; 39(3):e434-e437.]

dylolisthesis are the most common causes of low back pain in children older than 10 years.^{2,3} Spondylolysis, a stress fracture of the pars interarticularis that can progress to spondylolisthesis, has a prevalence of approximately 6% in the general adult population, but the prevalence is higher in adolescent athletes.⁴⁻⁸ Recent advances in diagnostic tools and techniques, such as magnetic resonance imaging (MRI) and computed tomography (CT), enable early diagnosis of stress fractures before they progress to complete fractures through the pars interarticularis.⁹ Early diagnosis can allow bony healing of the pars, affecting the prognosis in pediatric patients.¹⁰ However, because patients initially tend to consult family physicians for primary care of low back pain and these physicians may lack access to diagnostic modalities

The authors are from the Department of Orthopaedic Surgery (AN, TSakai, YG, YT, KH, KS), Tokushima University, Tokushima City, and Sakamaki Orthopedic Clinic (TSakamaki), Awa City, Japan.

The authors have no relevant financial relationships to disclose.

Correspondence should be addressed to: Toshinori Sakai, MD, PhD, Department of Orthopaedic Surgery, Tokushima University, 3-18-15 Kuramoto, Tokushima City, Japan (norinoridowluck@yahoo.co.jp).

Received: May 12, 2015; Accepted: October 19, 2015.

doi: 10.3928/01477447-20160404-07

Low back pain is much less common in childhood than it is in adulthood. Nevertheless, in recent years, there has been increasing awareness of low back pain in children and adolescents.¹ Lumbar spondylolysis and spon-

such as MRI or CT, such acute stress fractures can be missed.

This prospective study surveyed the prevalence of symptomatic spondylolysis in pediatric patients who consulted an orthopedic clinic for primary care. In addition, the authors investigated the possibility that acute stress fractures may be overlooked in patients who do not undergo MRI examination.

MATERIALS AND METHODS

This study was performed at a single primary care orthopedic clinic located in central Tokushima Prefecture, Japan, and focused on pediatric patients (younger than 19 years). All patients can consult the clinic without referral. In this study, in accordance with Japan's educational system, children younger than 13 years were classified as elementary school students, those younger than 16 years were classified as junior high school students, and those younger than 19 years were classified as high school students. Because patients do not need to pay medical fees until they graduate from high school, they can easily access the clinic.

This study assessed all patients younger than 19 years who had low back pain and presented to the study clinic for primary care between April 2007 and March 2010. For all patients with low back pain persisting for longer than 2 weeks, MRI examination was ordered.

RESULTS

From a total of 264 patients younger than 19 years who presented to the clinic for primary care of low back pain, 153 (58.0%) had low back pain that had persisted for longer than 2 weeks, and MRI examination was recommended for these patients (Figure 1). Of this group, 136 agreed to undergo MRI for further examination and were included in this study. This group included 11 elementary school students, 71 junior high school students, and 54 high school students.

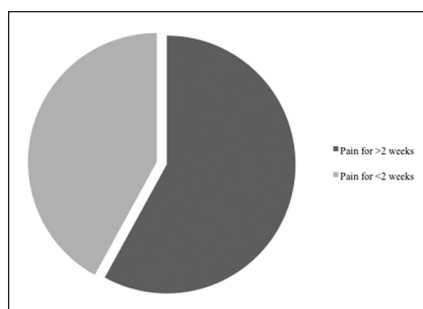


Figure 1: Proportion of pediatric patients (younger than 19 years) with persistent low back pain lasting longer than 2 weeks. More than 50% of patients were identified as having persistent back pain.

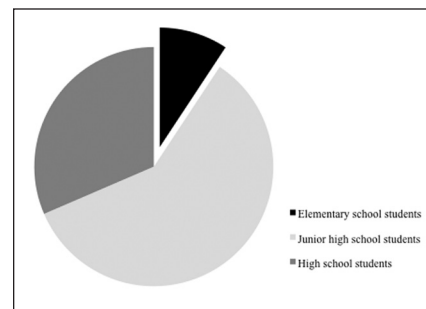


Figure 2: A diagnosis of spondylolysis was made in 39.7% of patients who underwent further examination by magnetic resonance imaging. Of these, 9.3% were elementary school students, 59.3% were junior high school students, and 31.5% were high school students.

A diagnosis of spondylolysis was made in 54 of the 136 patients (39.7%). This group included 5 elementary school students (9.3%), 32 junior high school students (59.3%), and 17 high school students (31.5%) (Figure 2). Specifically, spondylolysis was diagnosed in 5 of 11 (45.5%) elementary school students, 32 of 71 (45.1%) junior high school students, and 17 of 54 (31.5%) high school students (Figure 3). All 54 patients with spondylolysis had a history of athletic activity.

Further, among the 54 patients who were diagnosed with spondylolysis, in 4 of the 5 (80.0%) elementary school stu-

dents, 22 of the 32 (68.8%) junior high school students, and 9 of the 17 (52.9%) high school students, MRI showed high signal changes in the pedicle (Figure 4). These changes were indicative of acute stress fracture.

DISCUSSION

In this study, a diagnosis of lumbar spondylolysis was made in approximately 40% of pediatric patients presenting with low back pain. Of these patients, approximately 10% were elementary school students, 60% were junior high school students, and 30% were high

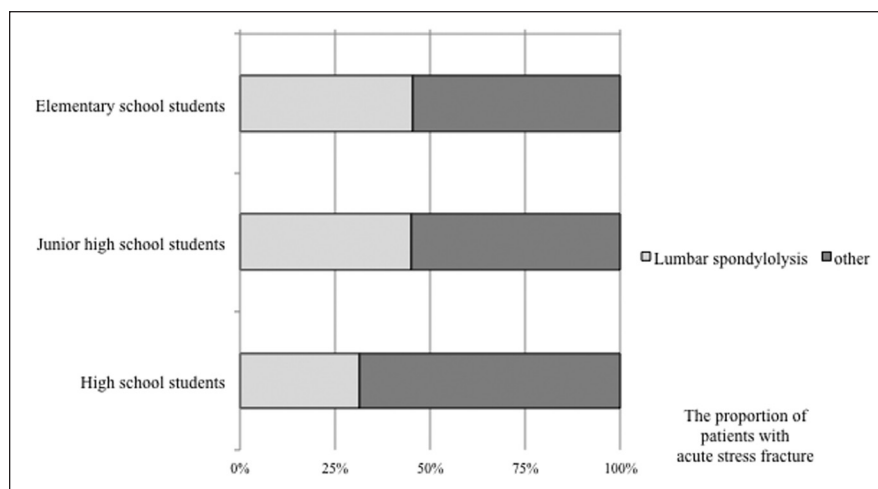


Figure 3: Proportion of cases of symptomatic lumbar spondylolysis vs other diagnoses by age group. In pediatric patients with persistent low back pain, lumbar spondylolysis was identified in 45.5% of elementary school students, 45.1% of junior high school students, and 31.5% of high school students.

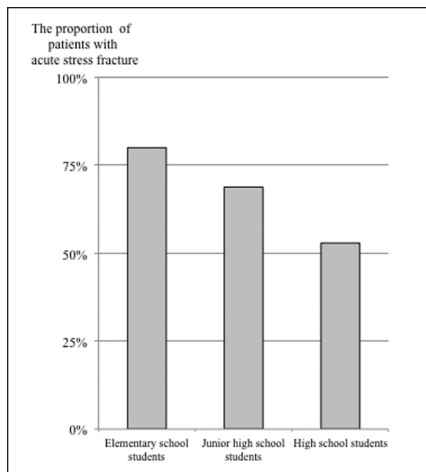


Figure 4: Proportion of patients with acute stress fracture showing high signal changes in the pedicle on magnetic resonance imaging. High signal changes were detected in 80.0% of elementary school students, 68.8% of junior high school students, and 52.9% of high school students.

school students. These findings differed from those of Fredrickson et al,⁵ who reported a 4.4% incidence of spondylolysis at 6 years and a 6% incidence in adulthood, which would indicate that 73% of all patients with spondylolysis could be identified at 6 years. There are several reasons for this difference in findings. An important reason is the choice of subjects. The current study included only symptomatic patients, but the study of Fredrickson et al⁵ included all children, regardless of whether they had low back pain. Another reason is the difference in the diagnostic modality used. The current study used MRI findings, whereas Fredrickson et al⁵ used plain radiographs. The use of radiographs improves the early diagnosis of lumbar spondylolysis.^{9,11,12} In addition, differences in the ethnic groups of the subjects may have affected the results.¹³

The prevalence of lumbar spondylolysis in the 3 age groups included in the current study showed that approximately half of elementary school and junior high school students and one third of high school students had a positive diagnosis, and all of those with spondylolysis had

a history of athletic activity. Thus, physicians should strongly suspect lumbar spondylolysis in pediatric patients who have low back pain persisting for longer than 2 weeks, particularly those with a history of athletic activity. Moreover, these results indicate that spondylolysis is likely to occur in young patients with immature spines.

In 1975, Wiltse et al⁶ proposed that the pathomechanism of spondylolysis involved a fatigue fracture of the pars interarticularis that had a strong hereditary basis. Although some reports support a hereditary predisposition to spondylolysis, hereditary factors have not been proven.¹⁴ The high incidence of lumbar spondylolysis in patients before spinal maturation may imply developmental problems during bone growth. A positive association between spina bifida occulta and lumbar spondylolysis was reported by Sakai et al,⁴ who observed a significantly higher incidence of spondylolysis in patients with spina bifida occulta than in those without this condition (odds ratio, 3.7-fold). Thus, certain genetic factors may affect spondylolysis.

In this study, MRI showed high signal changes in the pedicle in many patients who were diagnosed with spondylolysis: 80.0% of elementary school students, approximately 70% of junior high school students, and approximately 50% of high school students. These results suggest that spondylolysis in children may be missed without further MRI examination. Moreover, this study did not include patients who had low back pain that resolved within 2 weeks. Therefore, more cases of stress fractures (very early-, early-, or progressive-stage spondylolysis) may be overlooked without MRI, or some cases may heal spontaneously.

Limitations

This study had certain limitations. No CT data were available. Lumbar spondylolysis is conventionally diagnosed by CT, which shows pars defects clearly. Further,

there may be a risk of bias because this was a single-center clinic study.

CONCLUSION

Primary care physicians should recognize that approximately 40% of children with low back pain persisting for longer than 2 weeks may have spondylolysis. They should consider obtaining MRI images for confirmation in patients with low back pain persisting for longer than 2 weeks and a history of athletic activity. In particular, almost half of elementary school and junior high school students, who have an immature spine, may have lumbar spondylolysis.

REFERENCES

- Balagué F, Dudler J, Nordin M. Low-back pain in children. *Lancet*. 2003; 361(9367):1403-1404.
- Turner PG, Green JH, Galasko CS. Back pain in childhood. *Spine (Phila Pa 1976)*. 1989; 14(8):812-814.
- King HA. Back pain in children. *Pediatr Clin North Am*. 1984; 31(5):1083-1095.
- Sakai T, Sairyo K, Takao S, Nishitani H, Yasui N. Incidence of lumbar spondylolysis in the general population in Japan based on multidetector computed tomography scans from two thousand subjects. *Spine (Phila Pa 1976)*. 2009; 34(21):2346-2350.
- Fredrickson BE, Baker D, McHolick WJ, Yuan HA, Lubicky JP. The natural history of spondylolysis and spondylolisthesis. *J Bone Joint Surg Am*. 1984; 66(5):699-707.
- Wiltse LL, Widell EH Jr, Jackson DW. Fatigue fracture: the basic lesion is isthmic spondylolisthesis. *J Bone Joint Surg Am*. 1975; 57(1):17-22.
- Wiltse LL. The etiology of spondylolisthesis. *J Bone Joint Surg Am*. 1962; 44:539-560.
- Sairyo K, Katoh S, Sakamaki T, Komatsubara S, Endo K, Yasui N. Three successive stress fractures at the same level in an adolescent baseball player. *Am J Sports Med*. 2003; 31(4):606-610.
- Sairyo K, Katoh S, Takata Y, et al. MRI signal changes of the pedicle as an indicator for early diagnosis of spondylolysis in children and adolescents: a clinical and biomechanical study. *Spine (Phila Pa 1976)*. 2006; 31(2):206-211.
- Fujii K, Katoh S, Sairyo K, Ikata T, Yasui N. Union of defects in the pars interarticularis of the lumbar spine in children and adolescents: the radiological outcome after conservative treatment. *J Bone Joint Surg Br*. 2004;

- 86(2):225-231.
11. Sakai T, Sairyo K, Mima S, Yasui N. Significance of magnetic resonance imaging signal change in the pedicle in the management of pediatric lumbar spondylolysis. *Spine (Phila Pa 1976)*. 2010; 35(14):E641-E645.
 12. Goda Y, Sakai T, Sakamaki T, Takata Y, Higashino K, Sairyo K. Analysis of MRI signal changes in the adjacent pedicle of adolescent patients with fresh lumbar spondylolysis. *Eur Spine J*. 2014; 23(9):1892-1895.
 13. Sakai T, Sairyo K, Suzue N, Kosaka H, Yasui N. Incidence and etiology of lumbar spondylolysis: review of the literature. *J Orthop Sci*. 2010; 15(3):281-288.
 14. Yamada A, Sairyo K, Shibuya I, Kato K, Dezawa A, Sakai T. Lumbar spondylolysis in juveniles from the same family: a report of three cases and a review of the literature. *Case Rep Orthop*. 2013; 2013:272514.
 15. Sairyo K, Katoh S, Sasa T, et al. Athletes with unilateral spondylolysis are at risk of stress fracture at the contralateral pedicle and pars interarticularis: a clinical and biomechanical study. *Am J Sports Med*. 2005; 33(4):583-590.