

AMIODARONE - INDUCED SKIN PIGMENTATION: TWO CLINICAL CASES

TOXIDERMIE LA AMIODARONĂ - DOUĂ CAZURI CLINICE

Virgil Pătrașcu¹, Florentina Delcea¹, Raluca Niculina Ciurea², Tchernev Georgi³, Corneliu Cristian Georgescu⁴,
Anastasiya Atanasova Chokoeva⁵, Andreea-Oana Enache¹

¹Dermatology Department, University of Medicine and Pharmacy of Craiova, Romania

²Pathology Department, University of Medicine and Pharmacy of Craiova, Romania

³Dermatology Department, University Hospital Lozenetz, Sofia, Bulgaria,

⁴Department of Anaesthesia and Intensive Care, University of Medicine and Pharmacy of Craiova, Romania

⁵Onkoderma-Policlinic for Dermatology and Dermatologic Surgery, Sofia, Bulgaria

Corresponding author:

Virgil Pătrașcu, Professor, MD, PhD,
University of Medicine and Pharmacy,
Petru Rareș Street, No 2-4, 200345, Craiova, Romania,
phone: 004-0724273676, e-mail: vm.patrascu@gmail.com

Conflict of interest: The authors do not have any conflict of interest to declare.

Open Access Article

Abstract

Keywords:

toxidermia,
amiodarone, blue-grey
hyperpigmentation.

Introduction: Worldwide increased consumption of pharmaceuticals products have led to the registration of more and more iatrogenic reactions, 50% of these being cutaneous. Amiodarone-induced skin pigmentation is frequently found in dermatology, with an incidence of 75%, mostly being revealed by photosensitivity and hyperpigmentation. In most cases, these symptoms are reversible, disappearing when the treatment is stopped; the vital prognosis is not affected, though there is a high impact on the patient's quality of life.

Patients and Method: We report two patients who presented with blue-gray hyperpigmentation of the face, without other symptoms. We performed clinical examination along with serum biochemical tests and histopathological examination for both patients.

Results: The patients' history revealed amiodarone administration for cardiovascular conditions, in both cases, for approximately four years. Laboratory exams were normal. Histopathological exams confirmed the diagnosis of amiodarone-induced skin pigmentation in both cases. Daily sunscreen and local depigmentation treatment was prescribed at hospital discharge for both patients. Amiodarone was replaced with another antiarrhythmic agent. In a follow-up visit two months later, the blue-gray facial hyperpigmentation had faded significantly in both cases.

Conclusions: These cases correspond clinically and histologically with typical amiodarone-induced skin pigmentation, which occurred after 48 months of continuous therapy and a cumulative dose of 584 g for the first case, respectively 48 months and a cumulative dose of 365 g for the second case. Amiodarone-induced toxidermia may cause severe aesthetic problems and it may also increase the occurrence of other diseases in the context of skin aging.

Cite this article:

Virgil Pătrașcu, Florentina Delcea, Raluca Niculina Ciurea, Tchernev Georgi, Corneliu Cristian Georgescu, Anastasiya Atanasova Chokoeva, Andreea-Oana Enache. Amiodarone - induced skin pigmentation: two clinical cases. RoJCED 2016; 3(2):128 - 134

Rezumat

Cuvinte-cheie:

toxidermie, amiodaronă, hiperpigmentare gri-albăstruie.

Introducere: Consumul crescut de produse farmaceutice pe plan mondial face să se înregistreze tot mai multe reacții iatrogene, mai mult de jumătate dintre acestea fiind cele cutanate. Toxidermia la amiodaronă este frecvent întâlnită în practica dermatologică, având o incidență de 75 %, manifestată cel mai adesea prin fotosensibilitate și hiperpigmentări. În majoritatea cazurilor, aceste manifestări sunt reversibile și dispar la întreruperea tratamentului; ele nu pun în joc prognosticul vital, însă au un impact major asupra calității vieții pacienților.

Bolnavi și metodă: Prezentăm doi pacienți care au solicitat consult dermatologic pentru hiperpigmentarea gri-albăstruie asimptomatică a faciesului. Pentru fiecare bolnav am efectuat examene clinice și paraclinice, acestea din urmă constând în investigații de laborator și examen histopatologic.

Rezultate: Din anamneză reținem administrarea în cazul ambilor pacienți a amiodaronei, de aproximativ patru ani, pentru patologia cardio-vasculară. Examenele de laborator au fost în limite normale. Examenul histopatologic a confirmat în ambele cazuri diagnosticul de toxidermie la amiodaronă. La externare, pacienților li s-a recomandat utilizarea cremelor fotoprotectoare și a celor depigmentante. Amiodarona a fost înlocuită cu un alt antiaritmie. Bolnavii au fost evaluați la două luni de la externare, hiperpigmentarea a scăzut în intensitate în ambele cazuri.

Concluzii: Cazurile prezentate corespund clinic și histopatologic cu hiperpigmentarea tipică post amiodaronă apărută după 48 luni de terapie continuă și o doză cumulativă de 584 g pentru primul caz, respectiv 365 g după 48 de luni în cel de-al doilea caz. Toxidermia la amiodaronă ridică probleme atât din punct de vedere estetic cât și prin favorizarea apariției altor afecțiuni în contextul accentuării îmbătrânirii cutanate.

Introduction

Worldwide increased consumption of pharmaceuticals products have led to the registration of more and more iatrogenic reactions, 50% of these being cutaneous⁽¹⁾.

Amiodarone has been used for over 50 years for the treatment of cardiac ventricular and supraventricular arrhythmias, with a high efficiency^(2,3), but, when used for long periods of time, in high doses, it can cause a series of side effects, such as: ocular, pulmonary, thyroid disease, hepatic, neurological and cutaneous manifestations^(4,5).

In order to cause cutaneous side effects, amiodarone must be administered for a period of at least 20 months, with a minimum cumulative dose of 160g for hyperpigmentation, and for at least four months and a minimum cumulative dose of 40g for photosensitivity⁽⁶⁾.

The slow clearance rate, as well as a high absorption in adipose tissue, explains the late photosensitivity and hyperpigmentation remission (months-years)⁽⁷⁾.

In most of the cases, these disorders are reversible, disappearing when the treatment is stopped; they do not affect the vital prognosis, but they have a major impact on the patient's quality of life.

Patients and method

We report two patients who presented to the dermatologist for the asymptomatic blue-gray hyperpigmentation of the face. The patients' history revealed amiodarone administration for cardiovascular conditions in both cases for approximately four years. We performed clinical examination along with serum biochemical tests and histopathological examination for both patients. The patients were also evaluated by a cardiologist to set a clear cardiovascular diagnosis and to replace amiodarone with another antiarrhythmic agent.

Results

Case 1. A 75-year-old female skin photo type III, rural environment, presented with a 1 year history of asymptomatic blue-gray hyperpigmentation of the face. She had a past history of ischemic cardiomyopathy and atrial fibrillation and was taking amiodarone 200 mg/day (commenced over 4 years ago). She also mentioned that she had sun exposure without photoprotection.

We also noticed pronounced wrinkling in sun-exposed areas and brown to gray-brown patches on the face and dorsal part of hands. (Figs 1, 2).

A skin biopsy was performed on the left zygomatic

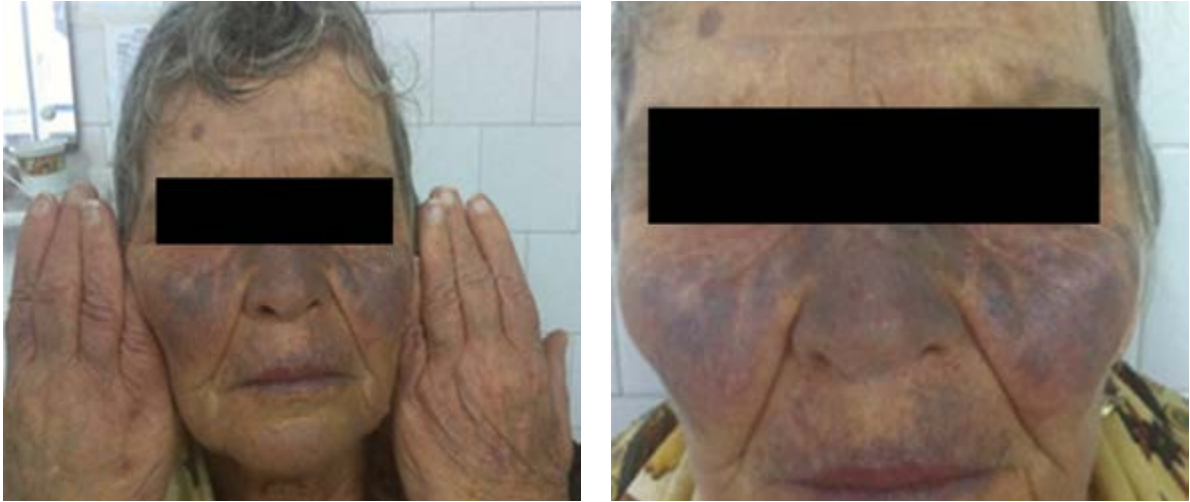

Figure 1, 2. Asymptomatic blue-gray amiodarone hyperpigmentation of the face, sparing the periocular area and the deep skin folds; thickened skin, pronounced wrinkling in sun-exposed areas and brown to gray-brown patches on the face.

region. Histopathological examination revealed parakeratosis, acanthosis and discrete spongiosis; intense chronic inflammatory infiltrate in papillary dermis, capillary ectasia and numerous macrophages with hemosiderin and melanophages (Figs 3, 4).

The final diagnosis was Amiodarone-induced skin pigmentation in a patient with actinic elastosis.

Case II. A 78-year-old male, skin phototype III, rural environment, presented with progressive, asymptomatic blue-gray hyperpigmentation of the face (Figs 5, 6). The lesions occurred four months before admission, following intense sun exposure.

He had a past history of stage 3 arterial hypertension and chronic ischemic cardiomyopathy, and was taking aspacardin 2 tablets/day and amiodarone over the last 4 years. The patient recounted that he took 400 mg amiodarone daily in the first year and 200 mg daily thereafter.

This pigmentation was not observed on other parts of the body. Laboratory blood tests were normal. The final diagnosis was Amiodarone-induced skin pigmentation.

Daily sunscreen and local depigmentation treatment was prescribed at hospital discharge for both patients. Amiodarone was replaced with another antiarrhythmic agent.

In a follow-up visit two months later, the blue-gray facial hyperpigmentation had faded significantly in both of the cases.

Discussion

Toxidermia (drug- induced skin disorders) represents cutaneous or mucocutaneous lesions induced by a drug or its metabolites. Drug-induced skin reactions can result from both allergic (20% of cases) and nonallergic (80% of cases) mechanisms^(1,8).

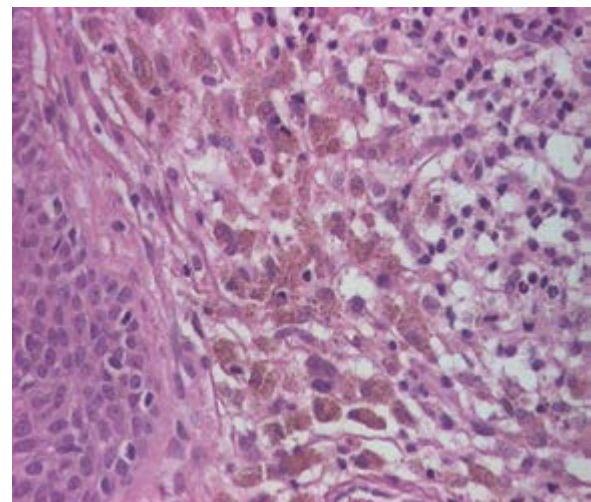
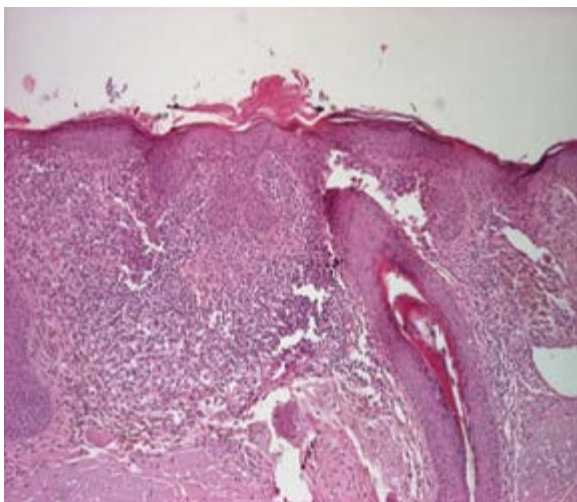


Figure 3, 4. Skin biopsy: the epidermis shows variable parakeratosis, acanthosis and discrete spongiosis; papillary dermis presented intense chronic inflammatory infiltrate, capillary ectasia and numerous macrophages with hemosiderin and melanophages (col HE X40; col HE X 200).

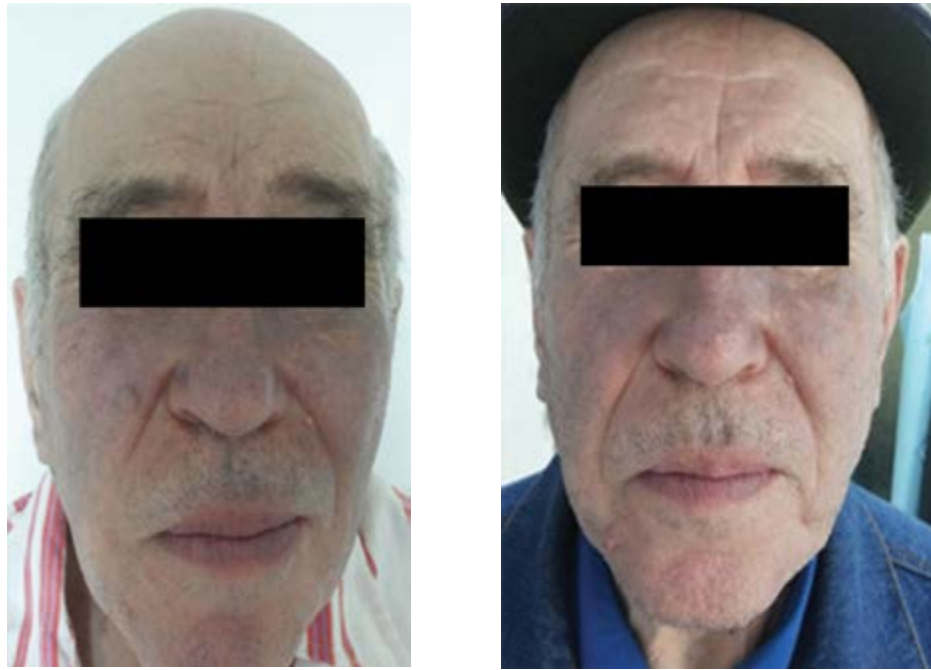

Figure 5, 6. Asymptomatic blue-gray amiodarone hyperpigmentation of the face; thickened skin, pronounced wrinkling in sun-exposed areas.

Iatrogenic hyperpigmentation represents 10 to 20% of all cases of acquired hyperpigmentation, and the diagnosis should be suspected in cases of inexplicable hyperpigmentation, especially in elderly patients.

The pathogenesis of the iatrogenic hyperpigmentations is not fully understood and depends on the implicated medication.

Four mechanisms have been proposed to explain these manifestations⁽⁹⁾:

- an accumulation of melanin in dermal macrophages, following a nonspecific cutaneous inflammation and frequently worsened by sun exposure;
- an accumulation of the triggering drug itself without any association with melanin, giving the appearance of free granules scattered along extracellular matrix components or in dermal macrophages that are unable to eliminate these foreign bodies. The drug may have to undergo chemical changes, causing visible hyperpigmentations (chemical sun-induced transformation of large granules into more numerous, visible and smaller granules);
- the synthesis of special pigments, such as lipofuscin, probably under the direct influence of the drug;
- the iron storage with destruction of the dermal vessels and extravasation of red blood cells.

The main drugs implicated in causing skin pigmentation are: amiodarone, clofazimine (red-brown color), antimalarials (blue-gray or purple color), minocycline (brown skin color), tetracyclines, chlorpromazine (brown color), imipramine, cytostatic drugs, contraceptives, diltiazem, amlodipine, heavy metals (gold, silver, lead)⁽¹⁰⁾.

Amiodarone Hydrochloride (2-Butyl-3-benzofuran-4-[2-(diethylamino) ethoxy]-3,5-diiodophenyl Ketone Hydrochloride) is a member of a class of antiarrhythmic drugs with predominantly Class III (Vaughan Williams' classification) effects. Amiodarone is one of the most widely prescribed antiarrhythmic drugs, due to its widely recognized efficacy⁽¹¹⁾. Being highly lipid-soluble, amiodarone is particularly concentrated in adipose tissue, muscle, as well as lungs and thyroid, and less often in kidney and brain. The half-life for amiodarone is estimated at 100 days, and an excessive quantity may persist in tissue deposits more than 9 months after cessation of therapy⁽⁷⁾.

Amiodarone has multiple side effects and in order of frequency we mention^(4,5):

- ocular side effects: corneal microdeposits that may cause visual disturbances, photophobia, eye dryness;
- pulmonary manifestations: interstitial pneumonia or diffuse alveolar damage, bronchiolitis obliterans with irreversible lesions, pleurisy, acute respiratory distress syndrome;
- hepatic manifestations - elevated serum transaminases (1,5-3 times normal), during prolonged treatment with amiodarone. Chronic hepatitis can occur which is similar histologically to alcoholic hepatitis;
- neurological manifestations - peripheral sensorimotor polyneuropathy and/or myopathy, extrapyramidal tremor, cerebellar ataxia, and exceptionally, benign intracranial hypertension;
- thyroid disease - hypothyroidism and hyperthyroidism;
- the most common types of adverse cutaneous reactions are hyperpigmentation and phototoxic reactions.

Hyperpigmentation occurs in approximately 4% - 9% of amiodarone treated patients, and it is usually observed in men with I and II Fitzpatrick phototypes. The most commonly affected areas are the face, ear pavilions and palms⁽⁴⁾.

The pathogenesis is not fully understood.

Amiodarone binds to phospholipids and makes insoluble compounds that don't follow the regular degradation pathways, which leads to their accumulation in lysosomes.

Histopathology highlights the lipofuscin deposits and the inflammatory cells around small vessels⁽¹²⁾. Skin changes (hyperpigmentation) usually occur after at least 20 months of continuous therapy with amiodarone and a total cumulative dose of more than 160 g⁽⁶⁾.

The cutaneous manifestations are represented by blue-gray pigmentation (pseudocyanotic skin pigmentation) on sun-exposed surfaces (face, ear pavilions, dorsal part of hands) in people with excessive sun exposure.

The discontinuation of the treatment leads to a slow disappearance of the lesions, but complete remission is achieved after months-years, being the consequence of slow elimination of amiodarone and its metabolites from tissues.

Phototoxic reactions are the most common dermatological side effect of the treatment with amiodarone, being encountered in 25-75% of patients, whereas photoallergic reactions occur in fewer patients, but the risk increases greatly with the duration of therapy⁽⁴⁾.

The pathogenesis of phototoxic reactions is realized in three sequences: in the first stage, the drug or one of its active metabolites should get in viable skin cells, after that, an adequate UV radiation which should penetrate into skin and, in the final phase, the photons are absorbed by the respectively chemical agent⁽¹³⁾.

Amiodarone and its active metabolite, mono-N-desethylamiodarone, can cause a significant decrease, by up to 50 % of minimal erythema dose (MED) in UV radiation spectrum after 12 months of treatment (MED < 300mJ / cm² it's pathological) [14]. The responsible mechanism appears to be related to the production of active metabolites due to the radiation such as oxygen free radicals, which results in damage to DNA, cellular membranes and oxygenation of lipids⁽¹²⁾. Phototoxic reactions can be experimentally elicited with UVA exposure.

Skin lesions occur after at least four months of therapy and with a minimum cumulative dose of 40 g⁽⁶⁾.

From a clinical point of view, itchy erythematous and eczematous lesions in sun-exposed areas may appear, usually within several minutes of exposure to sunlight and may persist for up to 48-72 hours⁽¹⁵⁾. The intensity of photoallergic and phototoxic reactions is correlated with the individual

sensitivity of the person to UV and with the duration of sun exposure.

Other cutaneous manifestations that may arise or are exacerbated during the treatment with amiodarone are: pseudoporphyria, linear IgA bullous dermatosis, dermatitis herpetiformis or psoriasis. Less common dermatological manifestations include urticaria, pruritus, purpura, erythema nodosum and toxic epidermal necrolysis⁽¹⁶⁾.

Some studies indicate the possible carcinogenic effects of amiodarone, with some cases of basal cell carcinoma associated with chronic use of this drug being reported⁽¹⁷⁾.

We have made the *differential diagnosis* with: Kaposi's sarcoma, discoid lupus erythematosus, Riehl melanosis, erythema dyschromicum perstans (ashy dermatosis), lichen planus pigmentosus, acrocyanosis, contact dermatitis, postinflammatory hyperpigmentation, hemochromatosis, leukemia cutis.

Evolution and prognosis

The slow rate of elimination of amiodarone, as well as the increased rate of absorption in adipose tissue may explain the delayed disappearance of cutaneous photosensitivity and hyperpigmentation (months -years).

Prophylaxis includes avoidance of sun exposure and use of sunscreen products.

Treatment


The basis of therapy consists in amiodarone withdrawal and favoring its elimination. Also, a switch from amiodarone to a different antiarrhythmic drug is recommended. Some authors have reported the efficacy of vitamin B6 at 300 mg per day⁽¹⁵⁾. Additional therapeutic options include Q-switched ruby laser or the chemical peels. Good results have been obtained using UVB therapy, which results in increased tolerance to sunlight and prolongs the time of exposure without side effects⁽¹⁸⁾.

Sun protection and avoidance of sun exposure is necessary during treatment and several months after amiodarone withdrawal.

Conclusions

These cases correspond clinically and histologically with typical amiodarone-induced skin pigmentation, which occurred after 48 months of continuous therapy and a cumulative dose of 584 g for the first case, respectively 48 months and a cumulative dose of 365 g for the second case.

Amiodarone-induced toxidermia may cause severe aesthetic problems and also may increase the occurrence of other diseases in the context of skin aging.

 This work is licensed under a Creative Commons Attribution 4.0 Unported License. The images or other third party material in this article are included in the article's Creative Commons license, unless indicated otherwise in the credit line; if the material is not included under the Creative Commons license, users will need to obtain permission from the license holder to reproduce the material. To view a copy of this license, visit <http://creativecommons.org/licenses/by-nc/4.0/>

Bibliography

1. Roujeau JC, Bonnetblanc JM, Schmutz JL, Crickx B. Iatrogenie. Diagnostic et prevention. Toxidermies medicamenteuses. *Ann Dermatol Venereol* 2002; 129 :2S163-2S9.
2. Smith W. Guidelines for the diagnosis and management of arrhythmogenic right ventricular cardiomyopathy. *Heart Lung Circ*. 2011;20(12):757-760.
3. Van Herendael H, Dorian P. Amiodarone for the treatment and prevention of ventricular fibrillation and ventricular tachycardia. *Vasc Health Risk Manag*. 2010; 6:465-472.
4. Vassallo P, Trohman RG. Prescribing amiodarone: an evidence-based review of clinical indications. *JAMA*. 2007;298(11):1312-22.
5. Hidefuminaba, Satoru Suzuki, Teiji Takeda, Satoshi Kobayashi, Takashi Akamizu, Mitsuhiisa Komatsu. Amiodarone-Induced Thyrotoxicosis with Thyroid Papillary Cancer in Multinodular Goiter: Case Report. *Med Princ Pract* 2012;21:190-192.
6. Rappersberger K, Honigsman H, Ortel B, et al. Photosensitivity and hyperpigmentation in amiodarone-treated patients: incidence, time course, and recovery. *J Invest Dermatol*. 1989;93:201-9.
7. Blackshear JL, Randle HW. Reversibility of blue-gray cutaneous discoloration from amiodarone. *Mayo Clin Proc* 1991;66 (7) 721-726.
8. Carmen Sorina Martin, Cristina Șerbănescu, Alexandra Nilă, Liliana Popa, Călin Giurcăneanu, Simona Fica, Antithyroid drugs - A necessary risk. *RoJCED* 2014; 1(1):20-23.
9. Olivier Dereure. Drug-Induced Skin Pigmentation: Epidemiology, Diagnosis and Treatment. *American Journal of Clinical Dermatology*. 2001; 2(4), 253-262.
10. Ioannides MA, Moutiris JA, Zambartas C. A case of pseudocyanotic coloring of skin after prolonged use of amiodarone. *Int J Cardiol*. 2003;90(2-3):8345-346
11. Sohns C, Zabel M. Current role of amiodarone in antiarrhythmic therapy. 2010;21(4):239-243.
12. Ammoury A, Michaud S, Paul C, et al. Photodistribution of blue-gray hyperpigmentation after amiodarone treatment: molecular characterization of amiodarone in the skin. *Arch Dermatol*. 2008;144(1):92-96.
13. Reid L, Khammo N, Clothier RH. An evaluation of the effects of photoactivation of bithionol, amiodarone and chlorpromazine on human keratinocytes in vitro. *Altern Lab Anim*. 2007;35(5):471-85.
14. Ferguson J, Addo HA, Jones S, Johnson BE, Frain-Bell W. A study of cutaneous photosensitivity induced by amiodarone. *Br J Dermatol* 1985;113 (5) 537-549.
15. Drucker AM, Rosen CF. Drug-induced photosensitivity: culprit drugs, management and prevention. *Drug Saf*. 2011;34(10):821-37.
16. Krzysztof Jaworski, Irena Walecka, Lidia Rudnicka, Maciej Gnatowski. Cutaneous Adverse Reactions of Amiodarone. *Med Sci Monit*. 2014; 20: 2369-2372.
17. Maoz KB, Dvash S, Brenner S, Brenner S. Amiodarone-induced skin pigmentation and multiple basal-cell carcinomas. *Int J Dermatol*. 2009;48(12):1398-400.
18. Collins P, Ferguson J. Narrow-band UVB (TL-01) phototherapy: an effective preventative treatment for the photodermatoses. *Br J Dermatol*. 1995;132(6):956-63.