JSCR
Journal of Surgical Case Reports
http://jscr.co.uk

Schistosomiasis: a rare cause of acute appendicitis

Authors: ND Cox and PJ Yates
Location: University Hospital Coventry and Warwick, Coventry, UK
Citation: Cox ND, Yates PJ. Schistosomiasis: a rare cause of acute appendicitis. JSCR. 2010 4:4

ABSTRACT

Schistosomiasis is a parasitic infection in humans, which is prevalent in developing countries. The infection manifests itself as a variety of different pathologies, depending on the location of the parasite and its eggs. A rare manifestation is that of a common surgical presentation, acute appendicitis. We present a case of a young male who underwent appendicectomy for acute appendicitis caused by a schistosomiasis infection, proven on pathological examination of the resected appendix.

INTRODUCTION

Schistosomiasis is one of the most prevalent parasitic diseases and infects over 200 million people worldwide. It is endemic to many developing countries in the World, and 80% of those affected are in Sub-Saharan Africa (1) . We present a case of acute appendicitis caused by schistosomiasis, a rare effect of the parasitic infection.

CASE PRESENTATION

A 31 year-old male from Zimbabwe presented with sudden onset severe abdominal pain of twelve hours' duration, beginning centrally then moving to the right iliac fossa and associated with several episodes of vomiting. He was tachycardic, apyrexial and abdominal examination revealed tenderness in the right iliac fossa. The white cell count was raised at 12.8 x 10^9/l and neutrophils raised at 11.2 x10^9/l. Other blood results were within normal range. A diagnosis of acute appendicitis was made and the patient taken straight to theatre for open appendicectomy. The appendix was found to have perforated and there were copious amounts of pus in the pelvis. Pathological examination described the macroscopic appearance of a swollen, congested appendix measuring 7.5 x 1.5cm with faeces in the lumen, and microscopic findings of active inflammation in transmural sections, and schistosomal colonisation of the mucosal and serosal surfaces. A detailed history revealed that the patient had lived in both rural and urban Zimbabwe where he had swum in lakes, and had experienced episodes of abdominal pain 10 years earlier. An abdominal ultrasound was performed to assess for complications of chronic infection including hepatosplenic disease and urinary obstruction, which was normal. Schistosomal serology was weakly positive and there was no evidence of schistosomiasis in the faeces or urine. The patient was prescribed Praziquantel, an antihelmintic drug used in the treatment of Schistosomiasis.

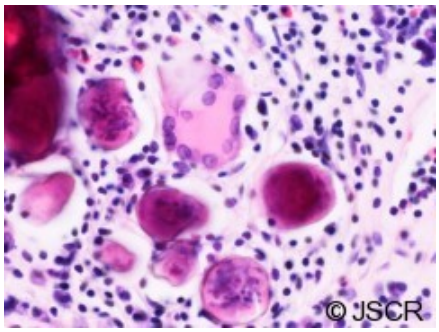

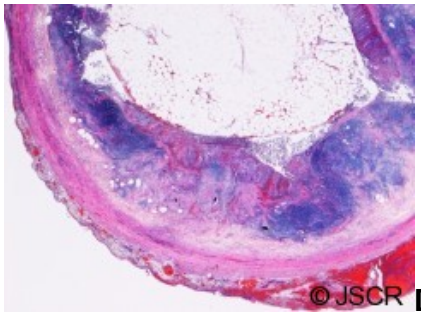

DISCUSSION Appendicitis is the commonest abdominal surgical emergency in the UK; the lifetime risk of appendicectomy in the US has been reported at 12.0% for males and 23.1% for females (2). The exact aetiology is uncertain, although the most common hypothesis is of obstruction to the appendiceal lumen with secondary infection. The obstruction leads to the accumulation of mucosal secretions and multiplying resident bacteria, thus raising intra-luminal and intra-mural pressure. Eventually the pressure causes venous obstruction and thrombosis of the appendicular vasculature, resulting in ischaemia. Bacteria enter the damaged mucosa, and pus forms inside and around the appendix. Ultimately, infarction and perforation occur which can lead to peritonitis, septicaemia and death. Some of the common causes of the obstruction are thought to be a faecolith, lymphoid hyperplasia and adhesions. In older patients, the obstruction is more likely to be a neoplasm. Schistosomiasis itself does not frequently cause appendicitis thus the condition is uncommon even in endemic regions. One study reported an incidence of 6.2% in Nigeria, an endemic country (3). In a non-endemic region a recent study reported 6 cases in 5,100 patients, an incidence of 0.001% (4). Schistosomiasis is contracted by exposure to contaminated freshwater; schistosome eggs in the water enter a snail intermediate host where they mature then are released back into water. Here they penetrate through the skin of a human host and enter the systemic circulation through the pulmonary capillaries. In the portal vein they multiply and travel to veins draining the intestine or bladder where they lay eggs that either stay in the circulation or are shed in the faeces or urine. The eggs stimulate an intense granulomatous inflammatory response, forming granulomata and tissue fibrosis. The pathological manifestations depend on the location of this inflammatory response, for example colonic polyposis due to inflammation in the bowel wall, liver fibrosis causing portal hypertension and haematuria or obstructive uropathy caused by bladder involvement. The acute infection is often asymptomatic, although there may be fever, nausea and bloody diarrhoea, or urticaria in response to the parasite penetrating the skin. Chronic infection can also be asymptomatic. There are five species of the family Schistosomatoidae that infect humans, which are endemic to different countries. The species *S. haematobium* is most commonly associated with appendicitis and is most prevalent in Africa, the Eastern Mediterranean and the Middle East. The exact pathogenesis of appendicitis secondary to schistosomiasis is uncertain. The most common hypothesis is that eggs in the appendix wall

stimulate inflammation and thus fibrosis and narrowing of the appendiceal lumen (5). Other hypotheses include schistosomal egg emboli causing ischaemia, and granulomatous inflammation of the peri-appendicular intestine, causing fibrosis and disruption of the intestinal wall leading to obstruction of the appendix and acute appendicitis. Diagnosis of schistosomiasis appendicitis is histological, by discovery of eggs in the appendix. There are no clinical or laboratory features that can point to the diagnosis pre-operatively. Schistosomiasis is confirmed by egg detection in urine and faeces, and serology can be used to detect mild infections. Treatment is appendicectomy and an antihelmintic drug. Chronic Schistosomiasis can lead to life-limiting complications, yet a simple treatment can eradicate the parasite and prevent the sequelae. Schistosomal-appendicitis may be the only presentation of the infection, and diagnosis allows investigation of long-term effects and treatment. This highlights the importance of awareness of unusual causes of common surgical presentations particularly in view of increased immigration of people from endemic areas and increased travel to these areas. It also reminds us of the importance of a thorough history including foreign travel and other risk factors.

REFERENCES

1. Vennervald BJ, Dunne DW. Morbidity in schistosomiasis: an update. Curr Opin Infect Dis. Oct 2004;17(5):439-47
2. Addiss DG, Shaffer N, Fowler BS, Tauxe RV. The epidemiology of appendicitis and appendicectomy in the United States. Am J Epidem. 1990;132:910-925
3. Duvie SO, Diffang C, Guirguis MN. The effects of Schistosoma haematobium infestation on the vermiform appendix: the Nigerian experience. J Trop Med Hyg. 1987 Feb;90(1):13-8
4. Karatepe O, Adas G, Tukenmez M, Battal M, Altiok M, Karahan S. Parasitic infestation as cause of acute appendicitis. G Chir. 2009 Oct;30(10):426-8
5. Badmos KB, Komolafe AO, Rotimi O. Schistosomiasis presenting as acute appendicitis. East Afr Med J. 2006 Oct;83(10):528-32