Surgical Neurology International

OPEN ACCESS

For entire Editorial Board visit : http://www.surgicalneurologyint.com

Editor-in-Chief: James I. Ausman, MD, PhD University of California, Los Angeles, CA, USA

Case Report

Intracerebral bullet removal through an endoscopic transnasal craniectomy

Andrea Bolzoni Villaret, Francesco Zenga[1], Isabella Esposito[1], Frank Rasulo[2], Marco Fontanella[1], Piero Nicolai

Departments of Otorhinolaryngology, [1]Neurosurgery, [2]Neuroanesthesia-Neurointensive Care University of Brescia, Brescia, Italy

E-mail: *Andrea Bolzoni Villaret - dr.bolton@libero.it; Francesco Zenga - f.zenga@gmail.com; Isabella Esposito - isaespo@tiscali.it; Frank Rasulo – rasulo@med.unibs.it; Marco Fontanella - marcofontanella@tin.it; Piero Nicolai - pieronicolai@virgilio.it
*Corresponding author

Received: 27 August 2012 Accepted: 25 September 12 Published: 14 December 12

This article may be cited as:
Villaret AB, Zenga F, Esposito I, Rasulo F, Fontanella M, Nicolai P. Intracerebral bullet removal through an endoscopic transnasal craniectomy. Surg Neurol Int 2012;3:155.
Available FREE in open access from: http://www.surgicalneurologyint.com/text.asp?2012/3/1/155/104749

Abstract

Background: In the past decade, the endoscopic transnasal technique has been broadly applied as a feasible and less invasive approach to the skull base. The adaptability of the endoscopic technique allows a case-specific approach in order to minimize both endonasal and cranio-cerebral manipulation; therefore it can be also used in patients complaining exceptional skull base lesions and in weak patients. The objective of this paper is to present the first case of intracerebral bullet removal using a pure endoscopic transnasal route through a custom made unilateral craniectomy.

Case Description: A 59-year-old patient was admitted to the emergency department after a gunshot injury to the head, thorax, abdomen, and pelvis. Admission Glasgow Coma Scale was 7. Brain computed tomography (CT) scan highlighted a right occipital hole defect due to perforative impact, intracerebral dislocations of bone fragments, right intracerebral and subdural hematoma, and midline shift to the left side; the bullet was localized in the right frontal lobe and its tip was in contact with the ethmoid roof.

The patient underwent emergency decompressive craniectomy and evacuation of the subdural hematoma and abdominal explorative laparotomy, ileum resection, and gastrorrhaphy. After 1 month, the patient underwent endoscopic transnasal removal of the bullet and skull base reconstruction due to cerebrospinal fluid infection. The postoperative course was uneventful and he has done well in follow-up with no evidence of cerebrospinal fluid leak and preservation of olfaction.

Conclusion: The adaptability of the endoscopic transnasal technique offers patients complaining exceptional skull base lesions a case-specific strategy minimizing morbidity and postoperative stay.

Key Words: Bullet removal, endoscopic, intracerebral, transnasal

Access this article online
Website: www.surgicalneurologyint.com
DOI: 10.4103/2152-7806.104749
Quick Response Code:

INTRODUCTION

Small-caliber low velocity bullets may intersect skull base, causing significant damage to the brain and a communication between endocranium and paranasal sinuses. They are usually associated with a significant morbidity and mortality. Computed tomography (CT) scan with multiplanar reformats is the radiologic gold

standard to evaluate cerebral injury and demonstrate the bullet trajectory. Poor admission Glasgow Coma Scale (GCS) score correlates with poor outcome; associated space-occupying and extracerebral hematomas as well as intraventricular hemorrhage may require an emergency operation to preserve and/or restore neurologic functions. During management of hemorrhagic complications bullet and bone fragments removal is indicated when feasible. Intracranial bullets have been usually removed through conventional microsurgical transcranial approaches, after confirmation of their position since spontaneus dislocation has been reported in the literature.[10]

Long-term complications (i.e., cerebrospinal fluid (CSF) leakage, infections, pseudoaneurism, carotid-cavernous fistula formation) should be considered and prevented after patient's stabilization.

Endoscopic transnasal removal of bullet and foreign body from the paranasal sinuses and orbit has been reported in the literature.[6,8,16,17,20-25] To our knowledge, intracranial bullet extraction through an endoscopic transnasal craniectomy (ETC) has never been reported before, which is also related to the low frequency of favorable positioning of the bullet and to the high mortality rate. This report details the operative technique for a unilateral keyhole craniectomy of the anterior skull base with subsequent multilayer reconstruction. The position of the target as well as its relationships with surrounding neurovascular structures (olfactory bulb and anterior ethmoidal artery) guided the creation of a patient-specific roadmap.

Traditional transcranial approaches to the midline anterior skull base (i.e., subfrontal, transfacial, and craniofacial) may include complications related to brain retraction, contusions, CSF leak, meningitis, and cosmetic deformity. The endoscopic endonasal technique allows more direct approach with minimal morbidity; it is versatile and suitable for managing a variety of pathological entities. The advantages of the endoscopic approach increase its appeal in the management of traumatic skull base pathology in weak and/or critical patients.

The choice of the endoscopic technique was guided by the following goals: A short operative time and postoperative stay, reduced risk of infection, olfactory function preservation, effective closure of the communication between the intracranial cavity and the sinonasal tract. A watertight dural repair is essential to avoid complications such as meningitis or brain abscess. Since the early 1980s, endonasal duraplasty of anterior skull base has been applied with a success rate of more than 90%.[5,9,15,18] In our experience with endoscopic management of skull base diseases, autologous materials such as fascia lata or iliotibial tract (ITT) are the first choice.[26]

CASE REPORT

A 59-year-old patient was admitted to the emergency department after a gunshot injury to the head, thorax, abdomen, and pelvis. Admission GCS was 7. Physical examination revealed two entry wounds: one in the buttock and one in the right occipital area.

Brain CT scan highlighted a right occipital hole defect due to perforative impact, intracerebral dislocations of bone fragments, right intracerebral and subdural hematomas, and midline shift to the left side; the bullet was localized in the right frontal lobe and its tip was set in the ethmoid roof [Figure 1].

Thoraco-abdominal CT scan studied the effects of the bullet entered through the buttock, which was located in the left inferior lobar bronchus. Free blood in the abdomen and pelvis was underlined.

The patient underwent emergency decompressive craniectomy and evacuation of the subdural hematoma followed by initial neurological improvement; abdominal injury required explorative laparotomy, ileum resection, and gastrorrhaphy. On the fourth postoperative day respiratory distress required percutaneous tracheostomy; the presentation of fever required refinement of the antibiotic therapy, adapted to cultures obtained by CSF and serial tracheal aspirates. One CSF culture was positive for *Enterococcus faecalis* and tracheal aspirate cultures were positive for *Pseudomonas aeruginosa* and Candida. After 35 days the patient was considered clinically stable, GCS was 15, with left hemiplegia. The antibiotic therapy (meropenem plus linezolid and fluconazole) was withdrawn and, 1 week later, he underwent endoscopic endonasal removal of the bullet and skull base reconstruction [Figures 2 and 3].

Preoperative workup included a high resolution CT scan with coronal and sagittal reconstructions and both soft tissues and bone algorithms. It ruled out bullet dislocation, assessing the following issues: Anatomic configuration of the paranasal sinuses, that is, morphology of the olfactory cleft, insertion of the basal lamella, and of the uncinate process. Measurement software (OsiriX DICOM viewer;© Pixmeo SARL, Switzerland) was used to estimate the trajectory, osteodural window, and work out a vascularized flap for reconstruction.

Perioperative antibiotic prophylaxis with a third generation cephalosporin was administered half an hour before surgery and continued for 1 week. The patient's postoperative course was uneventful and he has done well in follow-up, with no evidence of CSF leak and preservation of olfaction. Early postoperative CT scan ruled out intracranial complications and confirmed proper skull base reconstruction [Figure 4a]. After 5 days the patient was discharged and followed in a rehabilitation center. One month postoperative endoscopic control

[Figure 4b] and CT imaging after 3 months of follow-up showed no evidence of intracranial complications. After 14 months no evidence of CSF leak has been referred.

Operative technique

Rigid 4 mm endoscopes with 0° and 45° lenses (Karl Storz, Tuttlingen, Germany) were used. The patient's head was hyperextended and the thorax was slightly elevated. The surgical plan consisted in a unilateral ETC, resection of the overlying dura, bullet removal, and multilayer skull base reconstruction.

In this specific case the extent of the surgical corridor favored the use of the contralateral mucoperiosteal septal flap as the last layer for the reconstruction. It was harvested at the beginning of the procedure through two vertical incisions, extended toward the skull base, anteriorly and posteriorly to the left olfactory niche; the former was about 2 cm posterior to the nasal spine and the latter was at the level of the rostro–septal junction. This technical choice was dictated by several reasons: Harvesting the flap in the early phase of the operation allows to perform a two-nostrils four-hands technique; the wide vascular supply of the flap, based on the left ethmoidal arteries, contributes to reduce the risk of CSF leak and to fasten the healing process; finally the positioning of the flap over the contralateral anterior skull base opens the residual left olfactory niche with reasonable improvement of residual olfaction.

After the posterior septectomy, the unilateral ETC included: Middle turbinectomy, uncinectomy, middle meatotomy, total ethmoidectomy, and standard sphenoidotomy. After dissection of the suprabullar recess, the right anterior ethmoidal artery was clearly highlighted travelling in its canal along a bony mesentery; the artery had been spared by the bullet since it was located in the first foveola, in contact with the vessel and surrounded by yellow-whitish inflammatory tissue.

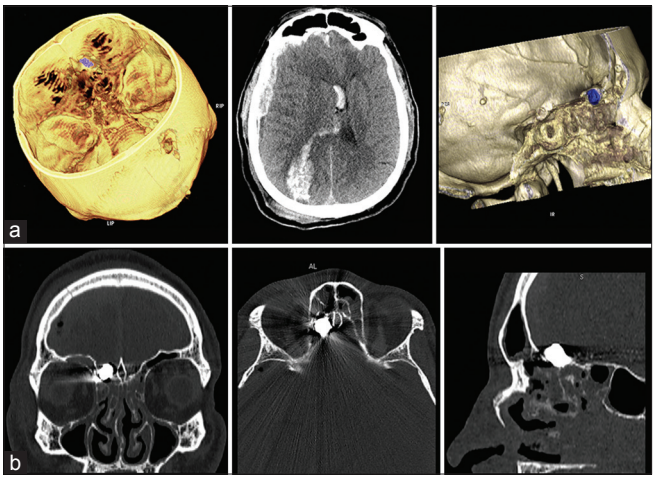

Figure 1: Preoperative CT scan: (a) three-dimensional reconstructions highlight the bullet (blue dot) and its trajectory. (b) multiplanar slices confirmed the proximity of the bullet to the anterior skull base

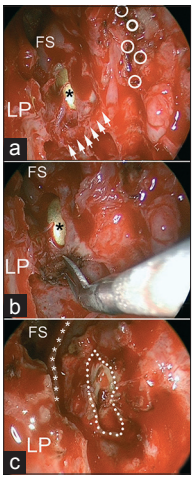

Figure 2: Intraoperative images showing the bullet (black asterisk), the olfactory fibers (°), the anterior ethmoidal artery (white arrows), the durotomy (dotted line) and the craniectomy (white asterisks). FS: Frontal Sinus, LP: Lamina Papyracea

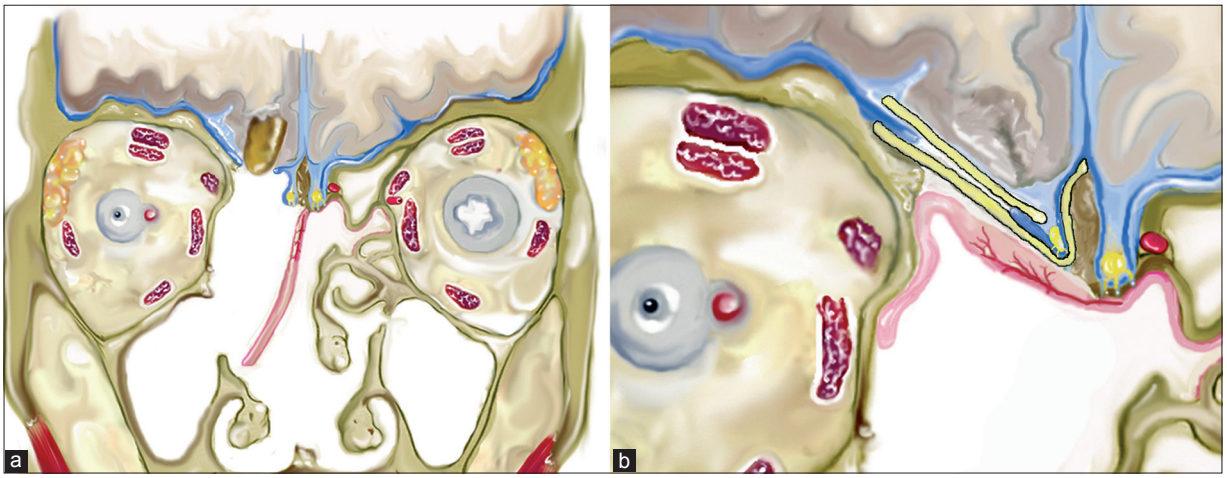

Figure 3: Schematic drawings show the extension of the craniectomy along the coronal plane (a) and the multilayer reconstruction (b) with iliotibial tract (yellow) and the septal flap (pink)

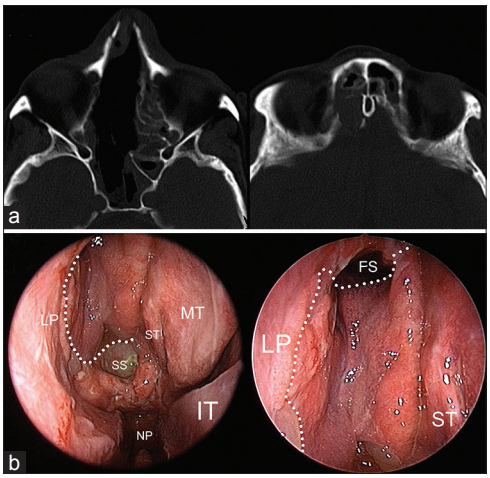

Figure 4: (a) Postoperative CT scan. (b) Endoscopic examination 1 month after the operation with 0° telescope (left) and 70° telescope (right). White dotted line depicts the right pedicled septal flap. LP: Lamina papyracea, SS: Sphenoid sinus, NP: Nasopharynx, IT: Inferior turbinate, MT: Middle turbinate, ST: Superior turbinate, FS: Frontal sinus

The exposure was further expanded anteriorly, toward the frontal sinus. After identification of the first olfactory fiber, drilling of the most anterosuperior nasal septum and the floor of the frontal sinus completed the exposure of the surgical target.

The extended frontal sinusotomy, with clear identification of the whole posterior wall of the frontal sinus, provided a regular anterior bony margin of the skull base defect for the multilayer reconstruction and allowed easier identification of the crista galli on the midline.

Bone surrounding the bullet was removed using a high-speed microdrill under direct vision. The ETC extended from the posterior wall of the frontal sinus to the posterior ethmoidal artery in the anteroposterior plane, and from the right lamina papyracea, to the insertion of the crista galli on the right cribriform plate in the coronal plane.

After coagulation and section of the right anterior ethmoidal artery, dural tearing surrounding the bullet was resected and the bullet was isolated and removed; gliotic brain tissue was removed using gentle suction and no bleeding was observed.

The ITT was harvested in the middle third of the thigh (5 × 10 cm) by a traditional approach. A double layer of ITT – intradural and epidural – was used; the intradural graft was about 30% larger than the dural defect; the epidural graft was 5 mm larger than the bony defect and modeled to shape as nearly as possible the exact contour of the craniectomy, whose pattern had been drawn on a silastic sheet template. At the end of the procedure, the left nasoseptal flap was put in place onlay. Natural surface tension and a few drops of fibrin glue along the margins of the flap kept it in place while silastic frontal stent, collagen sponge, and nasal packing were positioned.

DISCUSSION

In the past 10 years, a new paradigm in skull base surgery has been created: As in other specialties the endoscopic technique became a complement to standard surgical approaches.

Since the 1980s, ENT surgeons prepared the way for "pure" endoscopic transnasal approaches starting from the functional endoscopic sinus surgery, passing through endoscopic reparation of CSF leaks, resection of selected benign and malignant lesions, and arriving to extended endoscopic skull base and intracranial procedures.[1-4,7,11,13,14,19,26,27]

Actually midline skull base pathologies can be managed through two approaches: The microscopic transcranic, more familiar to neurosurgeons, and the endoscopic transnasal, more familiar to otolaryngologists. Therefore a modern skull base team must be able to offer the best surgical option on a case-specific base. In selected cases the endoscopic transnasal technique allows lower complication rate, less morbidity, and mortality compared with conventional transcranial and transfacial approaches.

Decision making is guided by encouraging early outcome data concerning the management of both benign and malign skull base pathologies such as CSF leaks, meningoencephaloceles, selected sinonasal malignant tumors, meningiomas, although a consensus is far from being achieved.[7,12,19,26] Furthermore, since the introduction of vascularized reconstruction techniques, reduction of postoperative CSF leak rate, which is one of the major obstacles to endonasal brain surgery, contributed to increase the reproducibility of the technique.[5,11]

Gunshot wounds to the head are often associated with a significant morbidity and mortality; brain damage may lead to permanent disability, which can be limited by timely treatment of related acute complications such as hemorrhage, edema, and epilepsy. Besides surgical management of hemorragic complications, debridement, and removal of the bone fragments and bullet is reserved to those that can be reached without damaging eloquent areas. People can survive with bullet and bone fragments in the brain, but it is preferable to remove them, if possible, since the retained bullet and the traumatic breakthrough of the skull base lead to a high risk of life threatening complications such as recurrent meningitis or brain abscess.

Endoscopic removal of bullets and foreign bodies from the paranasal sinuses and orbit have been reported in the literature.[6,16,17,21-25] Since 2004, endoscopic transnasal removal of intracranial foreign bodies has been reported.[8,20]

After stabilization of patient's global conditions and improvement of his neurological status, although

he was still weak, his consciousness was intact and his interactivity was pretty normal except for the left hemiplegia and the tracheostomy. Successful therapeutic management required only to prevent further complications and reduce the risk of brain infection through a minimally invasive surgical strategy. The position of the bullet close to the right ethmoidal fovea tailored the approach for its removal. Preoperative CT scan provided the roadmap for safe and precise endoscopic identification and removal of the bullet through an ETC [Figure 1]. Reconstruction strategy with exclusive autologous materials such as ITT and contralateral pedicled septal flap, was scheduled to reduce complications, speed up the healing process and optimize the residual olfaction.

Image guidance was not deemed necessary due to the clear relationships between the bullet and surrounding intracranial and sinonasal structures such as the fovea ethmoidalis and the anterior ethmoidal artery. However, a possible craniotomic approach has been taken into consideration in case of unespected intracranial bleeding during bullet removal.

CONCLUSIONS

The crosspollination between subspecialties and teamwork encourage the use of the endoscopic transnasal techniques also in patient complaining exceptional skull base lesions. Significantly lower associated morbidity, compared with conventional approaches, makes the transnasal corridor a valuable alternate line of management in properly selected cases.

REFERENCES

1. Bolzoni Villaret A, Schreiber A, Battaglia P, Bignami P. Endoscopy-assisted iliotibial tract harvesting for skullbase reconstructin: Feasibility on a cadaveric model. Skull Base 2011;21:185-8.
2. Cappabianca P, Alfieri A, de Divitiis E. Endoscopic endonasal transsphenoidal approach to the sella: Towards functional endoscopic pituitary surgery (FEPS). Minim Invasive Neurosurg 1998;41:66-73.
3. Carrau RL, Jho HD, Ko Y. Transnasal-transsphenoidal endoscopic surgery of the pituitary gland, Laryngoscope 1996;106:914-8.
4. Castelnuovo P, Dallan I, Bignami M, Battaglia P, Mauri S, Bolzoni Villaret A, *et al.* Nasopharyngeal endoscopic resection in the management of selected malignancies: Ten-year experience. Rhinology 2010;48:84-9.
5. Cavallo LM, Messina A, Esposito F, de Divitiis O, Dal Fabbro M, de Divitiis E, *et al.* Skull base reconstruction in the extended endoscopic transsphenoidal approach for suprasellar lesions. J Neurosurg 2007;107:713-20.
6. Cetinkaya EA, Okan C, Pelin K. Transnasal, intracranial penetrating injury treated endoscopically. J Laryngol Otol 2006;120:325-6.
7. de Divitiis E, Esposito F, Cappabianca P, Cavallo LM, de Divitiis O, Esposito I. Endoscopic transnasal resection of anterior cranial fossa meningiomas. Neurosurg Focus 2008;25:E8.
8. Dodson KM, Bridges MA, Reiter ER. Endoscopic transnasal management of intracranial foreign bodies. Arch Otolaryngol Head Neck Surg 2004;130:985-8.
9. Draf W, Schick B. How I do it: Endoscopic-microscopic anterior skull base reconstruction. Skull Base 2007;17:53-8.
10. Griva F, Cossandi C, Zullo N, Fontanella MM, Sales S, Pagni CA, *et al.* Spontaneous movement of a metallic intracranial foreign body: Case report. Surg Neurol 2000;54:267-9; discussion 269.
11. Kassam AB, Prevedello DM, Carrau RL, Snyderman CH, Thomas A, Gardner P, *et al.* Endoscopic endonasal skull base surgery: Analysis of complications in the authors' initial 800 patients. J Neurosurg 2011;114:1544-68.
12. Kassam AB, Prevedello DM, Carrau RL, Snyderman CH, Gardner P, Osawa S, *et al.* The front door to meckel's cave: An anteromedial corridor via expanded endoscopic endonasal approach-technical considerations and clinical series. Neurosurgery 2009;64:71-82; discussion 82-3.
13. Kennedy DW. Functional endoscopic sinus surgery. Technique. Arch Otolaryngol 1985;111:643-9.
14. Ketcham AS, Chretien PB, Van Buren JM, Hoye RC, Beazley RM, Herdt JR. The ethmoid sinuses: A re-evaluation of surgical resection. Am J Surg 1973;126:469-76.
15. Locatelli D, Rampa F, Acchiardi I, Bignami M, De Bernardi F, Castelnuovo P. Endoscopic endonasal approaches for repair of cerebrospinal fluid leaks: Nine-year experience. Neurosurgery 2006;58:ONS-246-56;discussion ONS-256-7.
16. Mohanty A, Manwaring K. Endoscopically assisted retrieval of an intracranial air gun pellet Pediatr Neurosurg 2002;37:52-5.
17. Muhammad Khyani IA, Hafeez A, Farooq MU, Alam J. Endoscopic removal of bullet from orbital apex. J Coll Physicians Surg Pak 2008;18:646-8.
18. Nicolai P, Castelnuovo P, Bolzoni Villaret A. Endoscopic resection of sinonasal malignancies. Curr Oncol Rep 2011;13:138-44.
19. Nicolai P, Villaret AB, Bottazzoli M, Rossi E, Valsecchi MG. Ethmoid adenocarcinoma--from craniofacial to endoscopic resections: A single-institution experience over 25 years. Otolaryngol Head Neck Surg 2011;145:330-7.
20. Perakis H, Woodard TD. Endoscopic management of transnasal intracranial penetrating foreign bodies. Laryngoscope 2010;120:S242.
21. Presutti L, Marchioni D, Trani M, Ghidini A. Endoscopic removal of ethmoido-sphenoidal foreign body with intracranial extension. Minim Invasive Neurosurg 2006;49:244-6.
22. Raik SM. An unusual foreign body in the frontal sinus. Int J Otolaryngol Head Neck Surg 1995;1:38-9.
23. Ramdas T, Prabhakaran M, Kumar VS. Air riffle bullet in the sphenoid sinus. Int J Otolaryngol Head Neck Surg 1996;1:51-2.
24. Sepehr A, Karam AM, Wong BJ. Novel endoscopic management of penetrating intracranial trauma, Annals of Otology. Ann Otol Rhinol Laryngol 2010;119:786-8.
25. Thomas S, Daudia A, Jones NS. Endoscopic removal of foreign body from the anterior cranial fossa. J Laryngol Otol 2007;121:794-5.
26. Villaret AB, Yakirevitch A, Bizzoni A, Bosio R, Bignami M, Pistochini A, *et al.* Endoscopic transnasal craniectomy in the management of selected sinonasal malignancies. Am J Rhinol Allergy 2010;24:60-5.
27. Wigand ME, Hosemann WG. Results of endoscopic surgery of the paranasal sinuses and anterior skull base. J Otolaryngol 1991;20:385-90.