

association with defective vision and retinal dystrophy has been frequently recognized (Senior, 1973; Betts and Forrest-Hay, 1973). There was no evidence of retinal changes in the present case, but there were two additional features which have only recently been found in association with juvenile nephronophthisis.

A family described by Boichis *et al.* (1973) showed hepatic portal fibrosis in addition to nephronophthisis. The liver changes, confirmed at necropsy in 2 children, were similar to those in our patient, and were regarded as a form of congenital hepatic fibrosis by the authors. We have reservations about this terminology as there is no evidence that either the hepatic or renal changes are present at birth.

Renal osteodystrophy is a common complication of juvenile nephronophthisis (Betts and Forrest-Hay, 1973) but dysostosis appears to be rare. The cone-shaped phalangeal epiphyses and metaphyseal chondrodysplasia of the femoral necks in our case are quite distinct from renal osteodystrophy and appear identical with those described in association with nephronophthisis by Mainzer *et al.* (1970, Case 2).

It seems, therefore, that there are at least three conditions which may occur in conjunction with juvenile nephronophthisis—retinal dystrophy, dysostosis, and portal fibrosis. The retinal changes appear to be the commonest. The 2 children described by Mainzer *et al.* (1970) showed all but the portal fibrosis, while in our case only the retinal dystrophy was lacking.

Summary

A case of juvenile nephronophthisis with hepatic portal fibrosis and dysostosis of the phalanges and femoral necks is described.

We thank Dr. F. C. Leyland for referring the patient, and Drs. R. H. R. White, A. H. Cameron, and R. Astley for guidance.

REFERENCES

- Bernstein, J., and Kissane, J. M. (1973). Hereditary disorders of the kidney. *Perspectives in Pediatric Pathology*, Vol. 1, p. 117. Ed. by H. S. Rosenberg, and R. P. Boland. Yearbook Medical Publishers, Chicago.
- Betts, P. R., and Forrest-Hay, I. (1973). Juvenile nephronophthisis. *Lancet*, **2**, 475.
- Blyth, H., and Ockenden, B. G. (1971). Polycystic disease of kidneys and liver presenting in childhood. *Journal of Medical Genetics*, **8**, 257.
- Boichis, H., Passwell, J., David, R., and Miller, H. (1973). Congenital hepatic fibrosis and nephronophthisis. *Quarterly Journal of Medicine*, **42**, 221.
- Chakera, T. M. H. (1975). Peripheral dysostosis associated with juvenile nephronophthisis. *British Journal of Radiology*, **48**, 765.
- Fanconi, G., Hanhart, E., Albertini, A. V., Ühlinger, E., Dolivo, G., and Prader, A. (1951). Die familiäre juvenile Nephronophthise (die idiopathische parenchymatöse Schrumpfnieren). *Helvetica Paediatrica Acta*, **6**, 1.
- Mainzer, F., Saldino, R. M., Ozonoff, M. B., and Minagi, H. (1970). Familial nephropathy associated with retinitis pigmentosa, cerebellar ataxia and skeletal abnormalities. *American Journal of Medicine*, **49**, 556.
- Senior, B. (1973). Familial renal-retinal dystrophy. *American Journal of Diseases of Children*, **125**, 442.
- D. G. ROBINS,* T. A. FRENCH, and T. M. H. CHAKERA
Departments of Nephrology, Pathology, and Diagnostic Radiology, Children's Hospital, Ladywood Middleway, Birmingham B16 8ET.

*Correspondence to Dr. D. G. Robins, Frimley Park Hospital, Frimley, Surrey, GU16 5UJ.

Juvenile nephronophthisis associated with retinal pigmentary dystrophy, cerebellar ataxia, and skeletal abnormalities

Juvenile nephronophthisis associated with retinitis pigmentosa was first described by Senior, Friedmann, and Braudo in 1961, and a number of cases have been reported since (Meier and Hess, 1965; Betts and Forrest-Hay, 1973; Senior, 1973). Besides the renal and ocular abnormalities, mental retardation, chromosomal defects, and skeletal abnormalities have been observed in some patients (Fontaine *et al.*, 1970; Sarles *et al.*, 1968; Antoine *et al.*, 1963), but the association of interstitial nephritis, retinitis pigmentosa, cerebellar ataxia, and endochondral dysostosis was first recorded by Mainzer *et al.* (1970). This paper describes another patient with the latter findings.

Case report

A male, born on 6 July 1961, was admitted in March 1971 with a 2-year history of renal disease.

Family history. After a complete examination (laboratory, ophthalmological, electroretinographic, audiometric, and x-ray findings) his mother, father, and only sister were found to be in good health except for abnormalities of pelvic endochondral ossification revealed by the father's x-ray examination.

He was the second child. Pregnancy and delivery were normal. By the end of the first year of life, failure to thrive was noted, together with some skeletal abnormalities. In the fifth year of life, poor adaptation to dark, unstable gait (he frequently fell), and polydipsia were noted. In 1969, when he was 8, he was hospitalized for the first time because of convulsions. He was then noted to be of short stature, slightly azotaemic, with serum creatinine 1 mg/100 ml (88.4 μ mol/l). Blood pressure was normal.

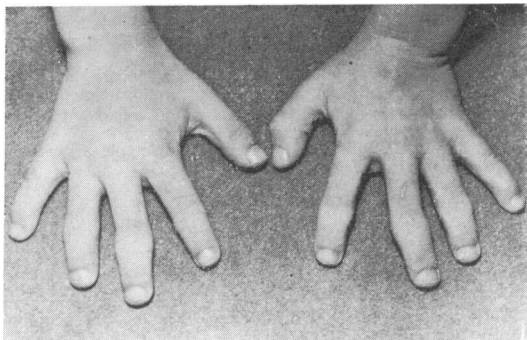


FIG.—Short and broad hands with short and stubby fingers.

Aged 9½ he was reinvestigated. He was then active but only 113 cm in height, and with obvious skeletal abnormalities. He had a prominent forehead and small face with hypoplastic mandible, high arched palate, pigeon chest, lateral narrowing of the thorax, Harrison's groove, and lumbar lordosis, short and broad hands, and short and stubby fingers (Fig.). On admission blood pressure was 110/80 mmHg, but subsequently rose to 200/150.

Neurologically there was poor co-ordination, hypotonia of upper and lower extremities, positive Romberg sign, abnormal finger-to-nose test. The gait was stiff and ataxic.

Ophthalmological examination showed markedly reduced visual acuity, convergent strabismus, and coarse horizontal nystagmus. The fundi showed pallor of both optic discs, narrowed blood vessels, fine 'pigment dusting' in the peripheral region, and white spots in the retina. Electroretinogram showed complete extinction of a and b waves. Audiometric tests suggested a peripheral and central vestibular localization of the lesions.

X-ray findings.* Osseous changes of uraemic osteodystrophy were absent, but the skeletal survey showed findings consistent with abnormal endochondral ossification. Prominent cone-shaped epiphyses with recess in the metaphyseal region were evident in the phalanges of the fingers and toes. The femoral capital epiphyses were small, with abnormalities in bone modeling. The femoral neck was short and stubby.* Other skeletal changes included widening of the ribs, characteristic quadrangular vertebral bodies, and short spinous process.

Renal biopsy showed diffuse changes of all structures, but predominantly in renal tubules and interstitium. None of the renal tubules was normal, some being only dilated and containing hypertrophic tubular cells and others with atrophic cells. Some dilated tubules looked like a pseudocyst, none of the typical cystic formations

having been observed. Most of the tubules were collapsed or obstructed by hyaline casts and the cells could not be differentiated. There was dense interstitial fibrosis with round cell infiltration. Most glomeruli showed complete hyalinization while in others some loops were preserved. Bowman's capsule was much thickened. Arterioles all showed fibrous arteritis.

Laboratory findings. Blood urea ranged from 120–330 mg/100 ml (19·9–54·8 mmol/l), serum creatinine from 4·5–9 mg/100 ml (397·8–795 μmol/l), endogenous creatinine clearance from 10–3 ml/min per 1·73 m². Serum protein electrophoresis and cholesterol were normal. Proteinuria ranged from 910–1670 mg/24 h and urine pH from 5·5–7·1. The highest urine specific gravity was 1010. Urinary sediment contained very few formed elements. Repeated urine cultures were clear. Karyotype was normal.

In spite of conservative therapy and peritoneal dialysis his clinical condition further deteriorated and he was taken home where he died within a few days. Necropsy examination was not done, but renal biopsy had been performed a few weeks after admission.

Discussion

Association of nephronophthisis and retinal pigmentary dystrophy is now a well recognized hereditary disorder. In our patient's family history there is no evidence of hereditary renal or ocular disease but the father was found to have minor skeletal changes indicating a disturbance of endochondral ossification, this being one of the symptoms in our patient. Skeletal abnormalities in patients with nephronophthisis were noted as early as 1963 by Antoine *et al.*, among whose patients was one with bony sclerosis due to chronic uraemia. Most patients with nephronophthisis are described as being of short stature, and this might suggest that abnormalities of endochondral ossification have existed in some but passed unnoticed.

Our patient also had cerebellar ataxia. Symptoms of cerebellar dysfunction were noted by Fontaine *et al.* (1970) in a patient who also showed serious mental retardation and symptoms of pyramidal disease. Our patient is almost identical with the 2 patients described by Mainzer *et al.* (1970). Besides interstitial nephritis and retinal pigmentary dystrophy, all 3 patients had symptoms of disturbed endochondral ossification and cerebellar ataxia. Whether these patients represent cases of pleiotrophic gene operation, a new genetic disorder, or simply a coincidental association of symptoms is an open question.

Summary

A boy aged 9½ years with interstitial nephritis, retinal pigmentary dystrophy, cerebellar ataxia,

*X-rays of fingers and femora supplied by the authors showed changes identical with those illustrating the accompanying paper by Robins, French, and Chakera (p. 799). (Editor)

and skeletal abnormalities is described. The association may be due to a new genetic disorder, since 2 similar cases have been reported.

We thank Dr. Rénee Habib for the histological study, and Drs. M. Blagojević and Lj. Pištelić for ophthalmological examination.

REFERENCES

- Antoine, M. B., Braun-Vallon, S., d'Anglejeau, M. G., Perrin, D., Dunod, J. P., and Ryckewaert, A. (1963). Néphropathie familiale avec atteintes osseuses et chorio-rétinienne. *Journal d'Urologie et de Néphrologie*, 1-2, 69.
- Betts, P. R., and Forrest-Hay J. (1973). Juvenile nephronophthisis. *Lancet*, 2, 475.
- Fontaine, J. L., Boulesteix, J., Saraux, H., Lasfargues, G., Grenet, P., Ghiem-Minh-Dung, N., Dhemy, P., Roy, C., and Laplane, R. (1970). Néphropathie tubulo-interstitielle de l'enfant avec dégénérescence tapéto-rétinienne. *Archives Françaises de Pédiatrie*, 27, 459.
- Mainzer, R., Saldino, R. M., Ozonoff, M. B., and Minagi, H., (1970). Familial nephropathy associated with retinitis pigmentosa, cerebellar ataxia and skeletal abnormalities. *American Journal of Medicine*, 49, 556.
- Meier, D. A., and Hess, J. W. (1965). Familial nephropathy with retinitis pigmentosa. *American Journal of Medicine*, 39, 58.
- Sarles, H. E., Rodin, A. E., Poduska, P. R., Smith, G. H., Fish, J. C., and Remmers, A. R., Jr. (1968). Hereditary nephritis, retinitis pigmentosa and chromosomal abnormalities. *American Journal of Medicine*, 45, 312.
- Senior, B. (1973). Familial renal-retinal dystrophy. *American Journal of Diseases of Children*, 125, 442.
- Senior, B., Friedmann, A. I., and Braudo J. L. (1961). Juvenile familial nephropathy with tapetoretinal degeneration. A new oculorenal dystrophy. *American Journal of Ophthalmology*, 52, 625.

M. POPOVIĆ-ROLOVIĆ,* N. ČALIĆ-PERIŠTIĆ, G. BUNJEVAČKI, and D. NEGOVANOVIĆ
Department of Nephrology, Children's University Hospital, Belgrade, Yugoslavia.

*Correspondence to Dr. Milana Popović-Rolović, Dečja klinika, 10 Tiršova, 11 000 Beograd, Yugoslavia.

Abnormal renal functions in cyanotic congenital heart disease

Hypoxaemia, secondary polycythemia, and abnormal venous arterial shunts are responsible for several well recognized complications in patients with cyanotic congenital heart disease. These include arterial and venous thromboses, cerebral abscess, bleeding tendency, and growth failure. Giant glomeruli are another well known but as yet unexplained pathological finding in some patients with cyanotic congenital heart disease (Spear, 1960). Since these changes may affect the normal function of the kidney, we have studied several renal functions in children with cyanotic congenital heart disease. This is particularly relevant seeing that major cardiac surgery is now frequently per-

formed on young infants who normally have immature renal function and limited homeostatic reserve (Edelmann and Spitzer, 1969). Also instances of acute renal failure postoperatively are not uncommon (Ogg and Cameron, 1969; Chesney *et al.*, 1975).

Materials and methods

All patients were seen regularly in the cardiac clinic by one of us (A.S.). Diagnosis of the cardiac lesions was confirmed by cardiac catheterization and angiocardiography. None of the patients studied were in congestive heart failure.

Four groups of patients were studied. Group I consisted of 21 patients with Fallot's tetralogy, and one with transposition of the great vessels and atrial septal defect. 3 patients had had a previous palliative shunt operation. The average age was 5.8 years. Group II consisted of 7 patients, who were studied at least 3 months after complete surgical correction of Fallot's tetralogy. 3 of them had been examined before operation. The average age was 7.2 years.

Group III consisted of 5 children with noncyanotic congenital heart disease. The diagnoses in this group were isolated pulmonic stenosis in 2 patients, aortic stenosis in 2, and ventricular septal defect in 1. The average age was 8.0 years. Group IV. The normal controls were 48 children referred to the renal clinic in whom no evidence of disease was found. The average age of this group was 8.8 years.

Renal studies. All the patients studied were on a regular diet. A routine urinalysis was performed on an early morning specimen, which was also examined for the presence of glucose by Clinitest strips and for aminoaciduria by paper chromatography. A 24-hour urine collection was obtained from each patient. The next day timed urine specimens were collected during a forced diuresis producing more than 2 ml of urine per minute. Blood chemistries were determined from a sample of venous blood obtained at the end of the short-term urine collections and the creatinine clearance was calculated from these specimens. Blood and urine creatinine concentrations were determined by the alkaline picrate method (Bonsnes and Tausky, 1945). Phosphate, sodium, and uric acid levels in the serum and urine were determined by standard laboratory procedure. The 24-hour urine specimen was used for determining the daily sodium excretion as well as for the calculation of the fractional excretion of uric acid and phosphate. Haemoglobin and haematocrit levels were determined in a Coulter counter.

Results

None of the patients had albuminuria, glucosuria, or aminoaciduria. The urine sediments were normal. The results of the renal functions examined are summarized in the Table. The group with cyanotic congenital heart disease differed signifi-

ADC

Juvenile nephronophthisis associated with retinal pigmentary dystrophy, cerebellar ataxia, and skeletal abnormalities.

M Popovic-Rolovic, N Calic-Perisic, G Bunjevacki and D Negovanovic

Arch Dis Child 1976 51: 801-803

doi: 10.1136/adc.51.10.801

Updated information and services can be found at:

<http://adc.bmj.com/content/51/10/801>

These include:

Email alerting service

Receive free email alerts when new articles cite this article. Sign up in the box at the top right corner of the online article.

Notes

To request permissions go to:

<http://group.bmj.com/group/rights-licensing/permissions>

To order reprints go to:

<http://journals.bmj.com/cgi/reprintform>

To subscribe to BMJ go to:

<http://group.bmj.com/subscribe/>