SCIENTIFIC PAPER JSLS

Laparoscopic "Dome-Down" Cholecystectomy With the LCS-5 Harmonic Scalpel

Terrence M. Fullum, MD, Sung Kim, MD, Dilip Dan, MD, Patricia L. Turner, MD

ABSTRACT

Objective: Misidentification of ductal anatomy and electrocautery injuries are complications associated with laparoscopic cholecystectomy (LC). Dome-down LC creates a 360-degree view of the gallbladder-cystic duct junction, reducing the risk for anatomy misidentification. In addition, ultrasonic instrumentation eliminates the risk for electrocautery injuries. This study assessed the feasibility and safety of dome-down LC combined with ultrasound technology.

Methods: Patients with noncancerous gallbladder disease were enrolled consecutively. Gallbladders were classified by clarity (Class I to IV) of anatomy and pathology (acute, chronic, or acalculous). The gallbladder was dissected from the gallbladder bed using a dome-down technique, and the cystic artery was coagulated and transected with the LCS-5 Harmonic scalpel (Ethicon Endo-Surgery Inc., Cincinnati, Ohio). The cystic duct was ligated with 2-polydioxanone Endoloops size 2–0 and sharply divided, leaving one Endoloop on the cystic duct stump.

Results: LC was successfully completed in 105 patients (mean age, 44 years; range, 18 to 91 years) in whom the anatomy was classified as Class I in 30 (29%) patients, Class II in 42 (38%), Class III in 25 (24%), and Class IV in 8 (8%). Gallbladder dissection time ranged from 8 to 42 minutes (mean, 18 min). The operating room time ranged from 32 to 128 minutes (mean, 55 min). Two gallbladder perforations occurred, but no complications were associated with the extrahepatic biliary tree, viscera, or major blood vessels. Elective conversion occurred in 8 (7.6%) patients due to poor visualization of anatomy because of inflammation and adhesions. Patient blood loss was minimal in all cases. No postoperative complications were observed after a 6-month follow-up.

Conclusion: Dome-down laparoscopic cholecystectomy with the LCS-5 Harmonic scalpel decreases the potential for misidentification of ductal anatomy, has minimal complications, and eliminates electrocautery risks. Conversion is related to poor visualization of anatomy due to inflammation and adhesions.

Key Words: Laparoscopy, Dome-down, Cholecystectomy, Laparoscopic coagulating shears, Ultrasound.

Howard University Hospital, Washington, District of Columbia, USA (Drs Kim, Turner).

Providence Hospital, Washington, District of Columbia, USA (Drs Dan, Fullum).

This study was supported by an educational grant from Ethicon Endo-Surgery, Inc., Cincinnati, Ohio, USA.

Address reprint requests to: Terrence M. Fullum, MD, 1160 Varnum St NE, Ste 212, Washington, DC 20017, USA. Telephone: 202 529 6801, Fax: 202 529 6808, E-mail: robotdoc2k@aol.com

INTRODUCTION

Laparoscopic cholecystectomy (LC) was popularized in the late 1980s by Mouret and Dubois in Europe and Reddick in the United States.[1] As a result of this pioneering work, a dramatic increase in the use of laparoscopic techniques for cholecystectomy occurred during the 1990s. For example, in Ontario, Canada, the proportion of cholecystectomy procedures performed laparoscopically increased from 1% from 1990 to 1991 to 85.6% from 1993 to 1994.[2] Furthermore, LC is now considered the standard of care in the treatment of noncancerous gallbladder disease.[3,4]

Although LC has become the standard of care and is often offered in an outpatient setting,[5] complications may occur. Two surgical complications, common bile duct (CBD) injury and collateral injury to surrounding tissue, occur more frequently in laparoscopic compared with open cholecystectomy (OC).[6–8] Common bile duct injury has been reported to occur 2 to 3 times more often in LC than in OC.[9,10] Although LC is preferred over OC, a need exists to modify and refine the technique to provide increased safety for patients.

LC has classically been initiated from the Triangle of Calot upward to the fundus of the gallbladder. Initial dissection in the Triangle of Calot presents important difficulties for the surgeon because of the potential for misidentification of ductal structures, increasing the potential for injury.[9] Visualization of anatomical structures may be substantially

impaired by numerous factors, including difficult anatomy secondary to severe inflammation or scar tissue, a short cystic duct, tenting of the ductal structures, anomalous right hepatic artery or duct, or Mirizzi's syndrome. In one study,[9] 71% (126 of 177 cases) of LC bile duct injuries were due to misidentification of anatomy. Therefore, surgical techniques to better define intraoperative anatomy are desirable.

One technique to reduce the risk for surgical complications in LC has been the development of an alternative gallbladder dissection sequence. Removing the gallbladder from the gallbladder bed first (dome-down) is a technique frequently used during an OC prior to the advent of LC and is commonly used when surgeons now convert to the open technique. Dissecting the gallbladder from the gallbladder bed first, and subsequently following the gallbladder to the cystic duct, allows utilization of the preferred surgical principle of dissecting from known anatomy (gallbladder wall) to unknown anatomy (potentially difficult anatomy in the Triangle of Calot).

In addition to complications associated with anatomy misidentification, LC has also been associated with collateral injury. In laparoscopic surgery, instruments using a variety of energy sources to cut and coagulate tissue have been used, including mono- and bipolar cautery, CO_2 laser, and the ultrasonic scalpel. The exact incidence of collateral injury is difficult to ascertain; however, 18% of physicians responding to a survey from the Society of American Gastroendoscopic Surgeons (SAGES) reported that they had personally experienced a patient receiving an electrosurgical burn during a laparoscopic procedure.[8] Furthermore, monopolar electrocautery use has been directly associated with 90% of visceral injuries and 15% of biliary tract injuries during LC.[11,12] In animal studies, monopolar cautery devices exhibited an increased lateral spread of thermal energy compared with that in ultrasonic devices resulting in increased tissue injury.[13,14] Electrosurgical devices can also cause injury due to insulation failure of the active electrode, direct coupling between the active electrode and metal instruments or tissue, and stray electrical currents.[15] Because of these risks for patient injury, alternative devices such as ultrasonic scalpels have been investigated further.

Ultrasonic instruments were developed to eliminate the collateral damage associated with electrosurgery.[16,17] The Laparoscopic Coagulating Shears (LCS-5) Harmonic scalpel (Ethicon Endo-Surgery Inc., Cincinnati, Ohio) utilizes ultrasonic energy, has minimal lateral spread of energy, and has minimal smoke production. The instrument can be used to dissect, grasp, coagulate, and cut at a lower temperature (<100°C) than occurs during electrosurgery (150°C) or laser surgery (200°C). With ultrasonic devices, no electrical current flows through the patient, eliminating the potential for injuries due to insulation defects, spark gaps, and stray current.

We hypothesized that combining an alternative gallbladder dissection sequence (dome-down) with an alternative dissection tool (Harmonic scalpel) would reduce complications associated with LC. This study was designed to assess the feasibility and safety of dome-down LC (DDLC) combined with use of the LCS-5 Harmonic scalpel.

METHODS

Patients

Consecutive patients with varying degrees of gallbladder disease, excluding cancer, were eligible for the study. All patients were evaluated by routine patient history, laboratory testing, physical examination, and radiographic or ultrasonic examination to determine the clinical need for a cholecystectomy.

Surgical Preparation

The patient was placed in the supine position and general endotracheal anesthesia was administered. The patient was prepped and draped in the usual fashion. A 10-mm Hassan cannula was placed at the umbilicus by using the open technique. A 10-mm 0-degree laparoscope was placed, and three 5-mm trocars were placed under direct visualization in the appropriate locations as shown in **Figure 1**. The patient was repositioned in a 30° reverse Trendelenburg position with a 10° tilt to the left.

Figure 1. DDLC setup with three 5-mm lever retractors.

After trocar placement, a 5-mm fan retractor was inserted through the right upper quadrant port, and the right lobe of the liver was retracted in a cephalad direction. The gallbladder, the areas of the CBD, and the cystic duct junction were assessed. The gallbladder was categorized as Class I, II, III, or IV depending on the difficulty of defining the gallbladder and associated anatomy. Definitions for each category are presented in **Table 1**.

Operative Procedure

After the gallbladder was classified, the DDLC procedure **(Figure 2)** was conducted in the following sequence:

1. The gallbladder was dissected away from the gallbladder bed from the fundus down toward the cystic duct using the LCS-5 Harmonic scalpel.
2. Once the gallbladder was free from the gallbladder bed, dissection continued along the gallbladder. The cystic artery was identified, isolated, ligated, and transected using the Harmonic scalpel **(Figure 3)**.
3. The cystic duct was positively identified and isolated, creating a 360-degree view of the gallbladder–cystic duct junction **(Figure 4A)**. No attempt was made to dissect or isolate the CBD, right hepatic duct, or left hepatic duct.
4. The cystic duct was ligated using two 2–0 PDS Endoloops (Ethicon Endo-Surgery) and divided using scissors **(Figure 4B)**.

During surgery, conversion to an OC occurred in patients if anatomy could not be safely visualized during dissection due to inflammation, edema, or adhesions.

Pathology

The gallbladder was classified according to pathology (acute, chronic, or acalculous).

Table 1.
Classification of Gallbladder and Associated Anatomy

Category	Definition
Class I	Clear anatomy
Class II	Anatomy discernible after initial dissection
Class III	Anatomy discernible after assiduous dissection
Class IV	Unclear anatomy—Triangle of Calot and associated structures may be impossible to identify; may need to convert to open structure

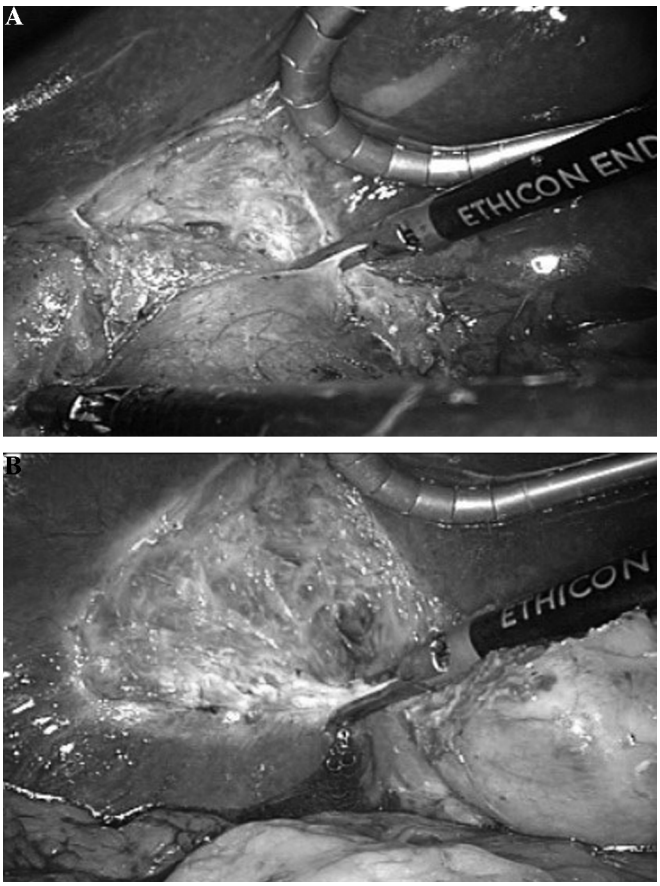

Figure 2. Example of DDLC at beginning (A), during (B) gallbladder dissection.

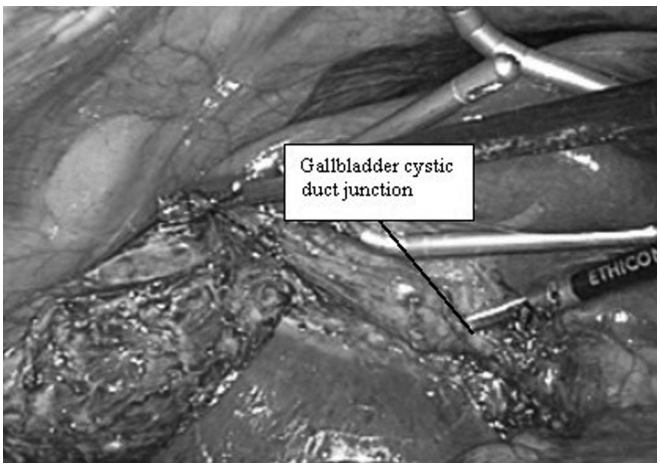

Figure 3. Identification of gallbladder-cystic duct junction.

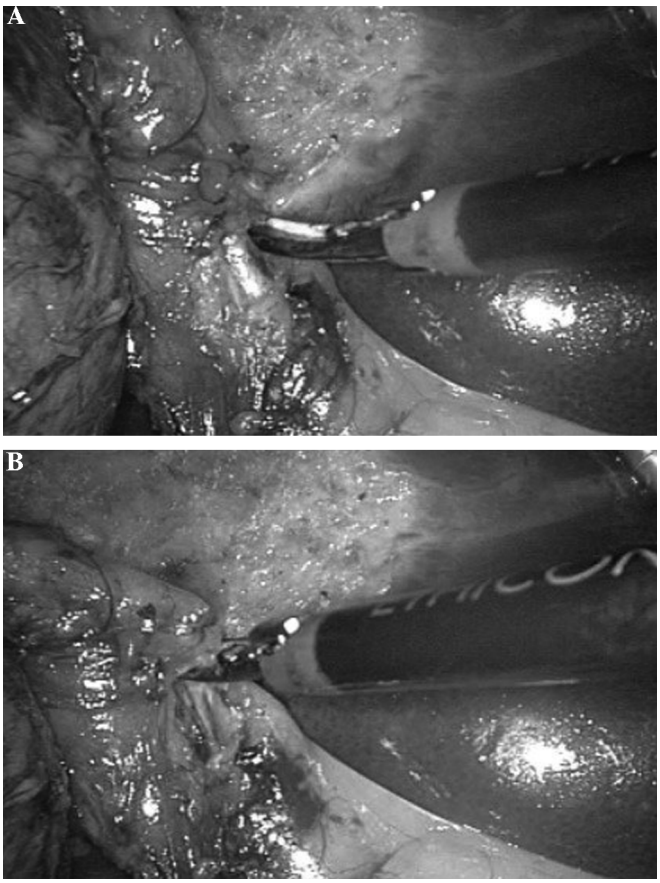

Figure 4. Isolation of cystic artery using LCS-5 Harmonic scalpel (A) and ligation of cystic duct by 2 2–0 PDS Endoloops (B).

Table 2.
Patient Characteristics

Variable	Number	Percent
Total number of patients	105	
Age in years: median (range)	44 (18–91)	
Sex, M:F	24:81	23:77
Class		
I	30	29
II	42	40
III	25	24
IV	8	8
Pathology		
Acute	22	21
Chronic	80	76
Acalculous	3	3

Table 3.
Gallbladder Dissection Time by Class or Pathology

Category	Median Time (min)
Class I	10
Class II	12
Class III	15
Class IV	22
Acute	24
Chronic	14
Acalculous	10

RESULTS

Patient Demographics

LC was performed as an outpatient procedure in 105 consecutive patients from June 1999 to June 2001. Patient demographics are summarized in **Table 2**. Gallbladders were identified as Class I or II in 72 (69%) patients and as Class III in 25 (24%) patients **(Table 2)**. Gallbladders were identified as Class IV in 8 patients, 2 of which had Mirizzi's syndrome.

Operative Procedure

The operating room time ranged from 32 to 128 minutes (mean, 55 min). Gallbladder dissection time ranged from 8 to 42 minutes (mean, 18 min) and is summarized in **Table 3**. The median gallbladder dissection time starting with Class I increased slightly for each class. There was a 12-minute increase in gallbladder dissection time between Class I and Class IV. Patients with acute pathology had a longer median operating time than did patients with chronic or acalculous pathologies. A 10-minute difference occurred between acute and chronic median gallbladder dissection times, and a 14-minute difference occurred between acute and acalculous pathology median gallbladder dissection times.

Patient blood loss during surgery was <50 mL in all cases. Two gallbladder perforations occurred during dissection, but no injury occurred to other tissues.

Intraoperative cholangiography was selectively performed during surgery in 2 patients to clarify anatomy in patients with Mirizzi's syndrome. The cholangiogram was negative for 1 patient, and 1 patient presented with a dilated CBD, but was negative for cystic duct stones.

During the operation, conversions to an OC were ob-

served in 8 (8%) patients (6 classified as acute and 2 as chronic), and data are summarized in **Table 4**. The 8 patients were converted due to poor visualization of anatomy or adhesions.

Clinical Outcomes

All patients were evaluated at 1 week, 3 weeks, and 6 months postoperatively. No postoperative complications were observed.

DISCUSSION

This study focused on minimizing LC surgical and postoperative complications by combining the use of DDLC and ultrasonic instrumentation. The main advantage of the DDLC technique is improved ability to visualize and identify anatomy. Although the efficacy and safety of DDLC has only been reported in a limited number of published studies,[18–21] the majority of data indicate that compared with standard LC, lower conversion rates, decreased complications, and shorter duration of surgery were observed.

The low rate of complications and conversions in this clinical trial were similar to those of other published DDLC studies. In 1994, DDLC was performed on 28 patients with an average operation time of 72.5 minutes in which no complications were observed.[18] This operating time was longer than that observed during our study, in which the mean operating time was 55 minutes. The authors in the 1994 study concluded that the DDLC approach allowed better visualization of the gallbladder, cystic duct, and common duct prior to ligation of the cystic duct thereby reducing the risk of CBD injury. Subsequently, in 1996, a study was published in which DDL C was performed in 81 patients who had difficult anatomy at the cystic-CBD junction.[19] The authors noted that DDLC reduced the requirement for intraoperative cholangiography because the anatomy of the gallbladder and the cystic duct were clearly identified. In 2001, a small study of 50 patients determined that the average operation time and the rate of complications with the DDLC was similar to that observed for standard LC.[20]

In a comparative study, DDLC was compared with standard LC in patients with severe gallbladder inflammation.[21] None of the 15 patients who had a DDLC had a conversion to OC or postoperative complications. However, 3 of 9 (33%) patients who received a standard LC had a conversion to laparotomy and 1 of 6 (17%) patients had major postoperative complications.[21]

The identification of the ductal anatomy in patients who have Mirizzi's syndrome has been problematic for many surgeons. However, DDLC makes the laparoscopic approach feasible in these patients, and therefore conversion to an OC is not always necessary. A review of 878 LC procedures from 1991 to 1996 found 6 cases of Mirizzi's syndrome that were approached using DDLC.[22] Although one case converted due to unclear anatomy at the Triangle of Calot, the rest were successfully treated with laparoscopy. In this study, 2 patients were identified as having Mirizzi's syndrome; however, neither of these patients required conversion. DDLC appears to be a feasible and safe procedure to consider in patients with Mirizzi's syndrome.

Use of ultrasonic instrumentation (LCS-5 Harmonic scalpel) was also examined in this study. A benefit of ultrasonic surgical devices is the cavitational effect, whereby low pressure at the blade causes fluids to vaporize at low temperatures, thus separating tissue planes, facilitating dissection, and aiding in developing the plane between

Table 4.
Patient Conversion to Open Cholecystectomy

Number of Patients (n=8)	Cholecystitis	Reason(s) for Conversion
1	Acute gangrenous with perforation	Adhesions and poor visualization
1	Acute	Adhesions and poor visualization
2	Acute	Poor visualization
2	Chronic	Adhesions
1	Chronic	Poor visualization
1	Chronic	Enlarged liver and pancreatitis lead to obscured visualization. Gallbladder could not be retracted to observe cystic duct junction

the gallbladder and liver. In the present study, none of the 105 patients had collateral injuries.

Two prospective, randomized studies[23,24] have compared the use of an ultrasonic surgical device versus monopolar electrosurgery or laser in LC. In a study of 200 patients, the use of ultrasonically activated sheers versus monopolar electrocautery decreased median blood loss (2 mL versus 14 mL), reduced the incidence (0 versus 3 patients) of bile leakage from the gallbladder bed, and reduced the incidence (1 patient versus 5 patients) of minor subhepatic fluid collection.[23] An additional study[24] of 73 patients compared an ultrasonic dissector with electrocautery or a laser instrument during LC. These 2 studies concluded that an ultrasonic apparatus was safe and easy to use in LC.

Our study further supports the utilization of ultrasonic instrumentation in LC and suggests that it is also appropriate for use when combined with the dome-down anatomical approach.

CONCLUSION

Conventional LC has a higher surgical complication rate than does OC, usually due to misidentification of the biliary anatomy or due to collateral damage from surgical devices, such as monopolar cautery. The dome-down technique may reduce the risk of complications by providing the surgeon with the opportunity for more definitive evaluation of anatomy. In addition, utilization of ultrasonic surgical shears eliminates the risk for inadvertent electrocautery burns. The combination of the dome-down technique and use of ultrasonic surgical shears provides the opportunity for surgeons to minimize the risk for surgical complications without increasing operating time.

References:

1. Litynski GS. Mouret, Dubois, and Perissat: the laparoscopic breakthrough in Europe (1987–1988). *JSLS*. 1999;3(2):163–167.

2. Cohen MM, Young W, Theriault ME, Hernandez R. Has laparoscopic cholecystectomy changed patterns of practice and patient outcome in Ontario? *CMAJ*. 1996;154:491–500.

3. Cervantes J, Rojas G, Anton J. Changes in gallbladder surgery: comparative study 4 years before and 4 years after laparoscopic cholecystectomy. *World J Surg*. 1997;21:201–204.

4. National Institutes of Health. Gallstones and laparoscopic cholecystectomy. *NIH Consensus Statement*. 1992;10:1–20.

5. Lillemoe KD, Lin JW, Talamini MA, Yeo CJ, Snyder DS, Parker SD. Laparoscopic cholecystectomy as a "true" outpatient procedure: initial experience in 130 consecutive patients. *J Gastrointest Surg*. 1999;3:44–49.

6. MacFadyen BV Jr., Vecchio R, Ricardo AE, Mathis CR. Bile duct injury after laparoscopic cholecystectomy. The United States experience. *Surg Endosc*. 1998;12:315–321.

7. Chandler JG, Voyles CR, Floore TL, Bartholomew LA. Litigious consequences of open and laparoscopic biliary surgical mishaps. *J Gastrointest Surg*. 1997;1:138–145.

8. Tucker RD. Laparoscopic electrosurgical injuries: survey results and their implications. *Surg Laparosc Endosc*. 1995;5:311–317.

9. Olsen D. Bile duct injuries during laparoscopic cholecystectomy. *Surg Endosc*. 1997;11:133–138.

10. Shea JA, Healey MJ, Berlin JA, et al. Mortality and complications associated with laparoscopic cholecystectomy. A meta-analysis. *Ann Surg*. 1996;224:609–620.

11. Huang X, Feng Y, Huang Z. Complications of laparoscopic cholecystectomy in China: an analysis of 39,238 cases. *Chin Med J (Engl)*. 1997;110:704–706.

12. Strasberg SM, Hertl M, Soper NJ. An analysis of the problem of biliary injury during laparoscopic cholecystectomy. *J Am Coll Surg*. 1995;180:101–125.

13. Lantis JC II, Durville FM, Connolly R, Schwaitzberg SD. Comparison of coagulation modalities in surgery. *J Laparoendosc Adv Surg Tech A*. 1998;8:381–394.

14. Tulikangas PK, Smith T, Falcone T, Boparai N, Walters MD. Gross and histologic characteristics of laparoscopic injuries with four different energy sources. *Fertil Steril*. 2001;75:806–810.

15. Tucker RD, Voyles CR. Laparoscopic electrosurgical complications and their prevention. *AORN J*. 1995;62:51–3,55,58–9passim; quiz 74–7.

16. Amaral JF. The experimental development of an ultrasonically activated scalpel for laparoscopic use. *Surg Laparosc Endosc*. 1994;4:92–99.

17. Amaral JF. Laparoscopic cholecystectomy in 200 consecutive patients using an ultrasonically activated scalpel. *Surg Laparosc Endosc*. 1995;5:255–262.

18. Kato K, Matsuda M, Onodera K, Kobayashi T, Kasai S, Mito M. Laparoscopic cholecystectomy from fundus downward. *Surg Laparosc Endosc*. 1994;4:373–374.

19. Kato K, Kasai S, Matsuda M, et al. A new technique for laparoscopic cholecystectomy—retrograde laparoscopic cholecystectomy: an analysis of 81 cases. *Endoscopy*. 1996;28:356–359.

20. Raj PK, Castillo G, Urban L. Laparoscopic cholecystectomy: fundus-down approach. *J Laparoendosc Adv Surg Tech A*. 2001;11:95–100.

21. Uyama I, Iida S, Ogiwara H, et al. Laparoscopic retrograde cholecystectomy (from fundus downward) facilitated by lifting

the liver bed up to the diaphragm for inflammatory gallbladder. *Surg Laparosc Endosc*. 1995;5:431–436.

22. Kok KY, Goh PY, Ngoi SS. Management of Mirizzi's syndrome in the laparoscopic era. *Surg Endosc*. 1998;12:1242–1244.

23. Tsimoyiannis EC, Jabarin M, Glantzounis G, Lekkas ET, Siakas P, Stefanaki-Nikou S. Laparoscopic cholecystectomy using ultrasonically activated coagulating shears. *Surg Laparosc Endosc*. 1998;8:421–424.

24. Wetter LA, Payne JH, Kirshenbaum G, Podoll EF, Bachinsky T, Way LW. The ultrasonic dissector facilitates laparoscopic cholecystectomy. *Arch Surg*. 1992;127:1195–1199.