World Journal of Gastroenterology

Submit a Manuscript: http://www.f6publishing.com

World J Gastroenterol 2017 May 28; 23(20): 3664-3674

DOI: 10.3748/wjg.v23.i20.3664

ISSN 1007-9327 (print) ISSN 2219-2840 (online)

ORIGINAL ARTICLE

Basic Study

Sonographic appearance of anal cushions of hemorrhoids

Adilijiang Aimaiti, Ma Mu Ti Jiang A Ba Bai Ke Re, Irshat Ibrahim, Hui Chen, Maimaituerxun Tuerdi, Mayinuer

Adilijiang Aimaiti, Mayinuer, Department of Anorectal Surgery, Second Affiliated Hospital, Xinjiang Medical University, Urumqi 830011, Xinjiang Uygur Autonomous Region, China

Ma Mu Ti Jiang A Ba Bai Ke Re, Chen Hui, Department of Anorectal Surgery, First Affiliated Hospital, Xinjiang Medical University, Urumqi 830011, Xinjiang Uygur Autonomous Region, China

Irshat Ibrahim, Maimaituerxun Tuerdi, Department of General Surgery, First People's Hospital of Kashi Area, Kashi 844000, Xinjiang Uygur Autonomous Region, China

Author contributions: Aimaiti A and A Ba Bai Ke Re MMTJ contributed equally to this study and should be regarded as co-first authors; A Ba Bai Ke Re MMTJ contributed to study conception and design and ultrasound technique for critically important intellectual content; Aimaiti A and Chen H made substantial contributions including research, study design, data source, data recording and acquisition, and final approval of the version; Ibrahim I and Mayinuer analyzed and interpreted the data; all the authors contributed to this manuscript.

Supported by the National Natural Science Foundation of China, No. 81460133; and Innovation Program of Regional Cooperation of Xinjiang Uygur Autonomous Region, No. 2016E02063.

Institutional review board statement: The study was reviewed and approved by the Xinjiang Medical University Institutional Review Board.

Conflict-of-interest statement: To the best of our knowledge, no conflict of interest exists. All the authors have no commercial associations or other interest in connection. Cai Yan has received fees for serving as an advisory board manager for the First Affiliated Hospital of Xinjiang Medical University. Cai Yan has received research funding from the National Natural Science Foundation of China. De Lixiati is an employee of the Research Center of Xinjiang Medical University.

Data sharing statement: Technical appendix, statistical code, and dataset of this original article are available from the corresponding author at mamutjan206@sina.com.

Manuscript source: Unsolicited manuscript

Correspondence to: Ma Mu Ti Jiang A Ba Bai Ke Re, MD, PhD, Chief Physician, Professor, Department of Anorectal Surgery, First Affiliated Hospital, Xinjiang Medical University, No. 1, Liyushan Road, Urumqi 830011, Xinjiang Uygur Autonomous Region, China. mamutjan206@sina.com
Telephone: +86-13579803435
Fax: +86-99-14366938

Received: February 1, 2017
Peer-review started: February 8, 2017
First decision: March 16, 2017
Revised: March 20, 2017
Accepted: April 12, 2017
Article in press: April 12, 2017
Published online: May 28, 2017

Abstract

AIM

To evaluate the diagnostic value of different sonographic methods in hemorrhoids.

METHODS

Forty-two healthy volunteers and sixty-two patients with grades Ⅰ-Ⅳ hemorrhoids received two different sonographic examinations from January 2013 to January 2016 at the First and Second Hospitals of Xinjiang Medical University in a prospective way. We analyzed the ultrasonographic findings of these participants and evaluated the outcomes. Resected grades Ⅲ and Ⅳ hemorrhoid tissues were pathologically examined. The concordance of ultrasonographic results with pathology

results was assessed with the Cohen's kappa coefficient.

RESULTS

All healthy volunteers and all patients had no particular complications related to sonography. There were no statistically significant differences between the participants regarding age (P = 0.5919), gender (P = 0.4183), and persistent symptoms (P > 0.8692). All healthy control participants had no special findings. However, 30 patients with hemorrhoids showed blood signals around the dentate line on ultrasonography. When grades Ⅰ and Ⅱ hemorrhoids were analyzed, there were no significant differences between transrectal ultrasound (TRUS), transperianal ultrasound (TPUS), and transvaginal ultrasound (TVUS) (P > 0.05). Grades Ⅲ and Ⅳ hemorrhoids revealed blood flow with different directions which could be observed as a "mosaic pattern". In patients with grades Ⅲ and Ⅳ hemorrhoids, the number of patients with "mosaic pattern" as revealed by TRUS, TPUS and TVUS was 22, 12, and 4, respectively. Patients with grades Ⅲ and Ⅳ disease presented with a pathologically abnormal cushion which usually appeared as a "mosaic pattern" in TPUS and an arteriovenous fistula in pathology. Subepithelial vessels of resected grades Ⅲ and Ⅳ hemorrhoid tissues were manifested by obvious structural impairment and retrograde and ruptured changes of internal elastic lamina. Some parts of the Trietz's muscle showed hypertrophy and distortion. Arteriovenous fistulas and venous dilatation were obvious in the anal cushion of hemorhoidal tissues. After pathological results with arteriovenous fistulas were taken as the standard reference, we evaluated the compatibility between the two methods according to the Cohen's kappa co-efficiency calculation. The compatibility (Cohein kappa co-efficiency value) between "mosaic pattern" in the TPUS and arteriovenous fistula in pathology was very good (κ = 0.8939). When compared between different groups, TRUS presented the advantage that the mosaic pattern could be confirmed in more patients, especially for group A. There was a statistical difference when comparing group A with group B or C (P < 0.05 for both). There were obvious statistical differences between group A and group B with regard to the vessel diameter and blood flow velocity measured by TRUS (P < 0.05).

CONCLUSION

Patients with grades Ⅲ and Ⅳ hemorrhoids present with a pathologically abnormal cushion which usually appears as a "mosaic pattern" in sonography, which is in accord with an arteriovenous fistula in pathology. There are clearly different hemorrhoid structures shown by sonography. "Mosaic pattern" may be a parameter for surgical indication of grades Ⅲ and Ⅳ hemorrhoids.

Key words: Hemorrhoids; Anal cushion; Transperianal; Transrectal; Transvaginal; Sonography

Core tip: There are still controversial opinions on the etiology of hemorrhoids. As to patients with grades Ⅲ and Ⅳ hemorrhoids, a special signal of blood flow with different directions could be observed, as a mosaic pattern, which was confirmed as arteriovenous fistula in pathology. Mosaic pattern could be a parameter for surgical indication of grades Ⅲ and Ⅳ hemorrhoids. If this abnormal cushion which appears as a "mosaic pattern" in sonography is confirmed, it could help to interpret important etiological aspects of hemorrhoids.

Aimaiti A, A Ba Bai Ke Re MMTJ, Ibrahim I, Chen H, Tuerdi M, Mayinuer. Sonographic appearance of anal cushions of hemorrhoids. *World J Gastroenterol* 2017; 23(20): 3664-3674 Available from: URL: http://www.wjgnet.com/1007-9327/full/v23/i20/3664.htm DOI: http://dx.doi.org/10.3748/wjg.v23.i20.3664

INTRODUCTION

The etiology of hemorrhoids remains somewhat controversial, with the main theories purported as either prolapse of anatomical anal cushions[1] or areas of abnormal vascular hyperplasia with an intrinsically hyperactive vascular sphincter[2,3]. The anal cushions, representing the anal mucosa and submucosa above the dentate line, have been implicated as important structures in hermetic closure of the anal canal, and Gibbons *et al*[4] have shown that internal anal sphincter closure alone is insufficient to maintain anal occlusion at rest. There are several hypotheses, but no definite evidence regarding the etiology or origin of hemorrhoids. Most surgeons confirm the diagnosis and indication of hemorrhoids according to their anal examination result. Ultrasound is an inexpensive, safe technique that can dynamically and noninvasively evaluate the anorectal area using transperianal, transrectal, and transvaginal examinations. In addition, these techniques are helpful for diagnosing rectal cancer, fecal incontinence, anal sphincter abnormalities, sphincter atrophy, and perianal fistula. However, there have been fewer reports concerning hemorrhoid diagnosis or abnormalities using endoanal sonography. Several different techniques of ultrasonography were used for the evaluation of the functional anatomy of the pelvic floor, of which transperianal ultrasound (TPUS), transvaginal ultrasound (TVUS), and trans-rectal ultrasound (TRUS) are frequently used[5]. As a noninvasive method, TPUS was initially used in 1983 as an examination for the anorectal area in newborn babies with imperforate anus; more recently, other studies have reported the importance of this examination for the assessment of the anorectal

area[6,7], and TRUS can clearly show the morphological characteristics of the hemorrhoid vascular network and pathological anal cushion. Therefore, there is clinical importance attached to the selection of treatment options. Endoanal ultrasound (EUS) or TRUS was introduced 25 years ago by urologists to evaluate the prostate[8]. Later, TRUS was used to stage rectal tumors[9] and to diagnose benign disorders of the anal sphincters and pelvic floor[10,11]. Sultan *et al*[12] first reported an abnormal manifestation of female hemorrhoids using TVUS to visualize the anal canal, and it was used to measure the hemorrhoid cushions by Nicholls *et al*[13]. The purpose of this prospective study was to measure the anal cushion area using sonographic examination in a group of patients with hemorrhoids of different grades (Ⅰ-Ⅳ) and to compare the results with a control group of age-matched healthy volunteers. This research also aimed to evaluate the diagnostic value of sonographic examination of the hemorrhoid cushion *via* different sonographic methods to obtain early detection and early intervention. In this study, we analyzed color Doppler ultrasound characteristics of 62 symptomatic patients with hemorrhoids, with the aim to investigate the clinical value of ultrasound and to improve the early diagnostic ability of ultrasound for hemorrhoids.

MATERIALS AND METHODS

Study subjects

Forty-two healthy control volunteers and sixty-two patients with grades Ⅰ-Ⅳ hemorrhoids received two different sonographic examinations (TRUS and TPUS for males, and an additional TVUS for female patients) from January 2013 to January 2016 at the First and Second Hospitals of Xinjiang Medical University. The participants ranged in age from 21 to 76 years with a mean age of 53.6 years. We have prospectively performed ultrasonography for all these participants. All included cases for analysis were followed for at least 4 wk. Rectal cancer, hemorrhoid thrombosis, anal fissure, anal fistula, fecal incontinence, ulcerative colitis, Crohn's disease and any bleeding risk condition were excluded. Study participants were divided into three groups. Group A consisted of patients with stages Ⅲ and Ⅳ disease (38 patients, 26 males and 12 females); the mean age was 42 ± 2.4 years, and the duration of symptoms was 7.8 ± 2.4 mo. Group B consisted of patients with stages Ⅰ and Ⅱ disease (24 patients, 14 males and 10 females); the mean age was 42 ± 2.4 years, and the duration of symptoms was 6.6 ± 3.8 mo. Group C consisted of normal healthy participants (42 volunteers, 24 males and 18 females), with a mean age of 42 ± 2.4 years. TRUS was considered as the standard modality to determine abnormal findings of hemorrhoids. Resected grades Ⅲ-Ⅳ hemorrhoid tissues were pathologically examined.

Diagnostic criteria

Hemorrhoids were diagnosed based on the diagnostic criteria established previously[14]. Grade Ⅰ hemorrhoids are characterized by prominent vasculature with engorgement but no prolapse. Grade Ⅱ hemorrhoids prolapse only with straining but spontaneously reduce. Grade Ⅲ hemorrhoids prolapse beyond the dentate line with straining and require manual reduction. Grade Ⅳ hemorrhoids prolapse beyond the dentate line with straining but cannot be reduced manually.

Instruments and ultrasound procedures

Patients received a cleansing enema 1 h before examination. The patients were placed in the left lateral position. Performance of the examination was accomplished using either a linear 12- to 7-MHz transducer or a transvaginal 8- to 4-MHz probe (ATL 3000 or 5000; ATL Ultrasound, Bothell, WA, United States), which was placed against the patient body. TPUS was used to provide a standardized image of the anal canal displaying the mucosa and submucosa, the hypoechoic internal anal sphincter, and the hyperechoic external anal sphincter, and the images provided are comparable with those obtained with an endoluminal probe. The anal cushion area was measured as described by Nicholls *et al*[13]. Generally, the measurement was made in the mid-anal canal where the image of the anal canal is most enduring and reproducible measurements can be made. Before TRUS and TVUS, the rigid probes were covered for hygienic reasons with a condom filled with ultrasound gel. Then, during the endoluminal process, the condom was covered with a gel on the outside and gently introduced into the rectum for a distance of about 3 to 5 cm. Landmarks used are the prostate, vagina, and puborectalis (PR) muscle. Then the probe was slowly withdrawn and entered the anal canal. Pressure of the probe and gravity can lead to different thickness measurements (that is, lying on the left side, left thickness measurements may be smaller). In female patients, the transvaginal probe was placed low in the vagina and angled posteriorly to image the anal canal as described by Stewart and Wilson[15]. Then, the ultrasound probe was used to examine the rectal cavity in a clockwise direction. We analyzed the ultrasonographical findings of these participants and evaluated the outcomes. After finding the irregular widening of the hypoechoic area in the second layer, the probe was placed in the five-layer longitudinal muscle of the rectal wall, and we used color Doppler ultrasound to examine the size, shape, distribution, and number of blood vessels, and the vessel shape and vascular hemodynamic index of the hemorrhoid. To achieve maximum sensitivity, Doppler settings were set at low frequency and filter, and the

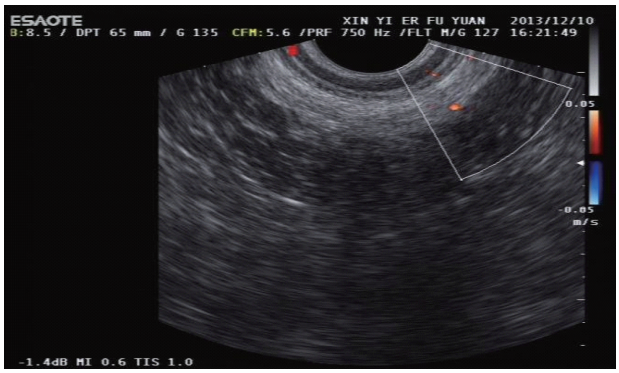

Figure 1 Normal five-layer structure of a healthy participant.

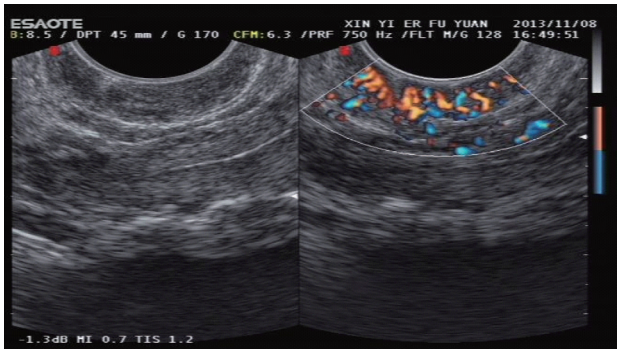

Figure 2 Typical blood flow in patients with stage Ⅰ or Ⅱ (left) and stage Ⅲ or Ⅳ (right) hemorrhoids.

artifact in the image was removed. Starting from the highest level (4-6 cm above the anorectal junction) and continuing to the anal verge (1 cm below the line of the internal sphincter muscle), the transanal probe was slowly pulled distally. Doppler window was placed at the haemorrhoidal artery, and the baseline and pulse repetition frequency were changed according to blood flow velocity to obtain continuous blood flow images for measurement of peak systolic velocity and resistance index. Each artery diameter was measured three times, and mean value was calculated. Parameters of power Doppler settings were: frequency, 6.1 MHz; power Doppler gain, 40 dB; dynamic power Doppler setting parameter: range, 20 dB; edge, 1; time smooth, 7; special smooth, 2; color map, 5; filter, 5; pulse repetition frequency, 21.5 kHz; scale, 3.8 m/s. The vessel diameter and blood flow velocity were detected by TRUS in groups A and B.

Ethic and informed consent

This research was approved by the Ethic Committee of Human Subject Research of the First and Second Affiliated Hospitals of Xinjiang Medical University. All healthy participants and patients signed an informed consent form before this study. There were no commercial conflicts or other problems related to the participants. All sonographic examinations were free to all the participants.

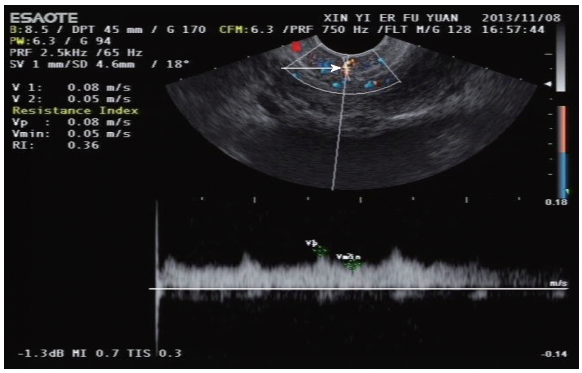

Figure 3 Mosaic pattern in the anal cushion of stages Ⅲ and Ⅳ hemorrhoids. Blood flow with different directions could be observed as a "mosaic pattern" (white arrow). High-speed low-resistance arterial flow spectrum and arterialized venous spectrum could be observed as a bright colored area.

Statistical analysis

Statistical analyses were performed using SPSS software version 19.0. The intention-to-treat principle was applied in this study. Numerical data are expressed as median and ranges. Student's *t*-test was used to compare the treatment results, and the chi square (χ^2) test was used for the comparison of proportions. A *P*-value < 0.05 was considered statistically significant. The diagnostic reliability of sonography in determining significant mosaic pattern (more than 70%) was assessed. Pathological results with arteriovenous fistulas were taken as the standard reference. To evaluate the compatibility between the two methods in grading the mosaic pattern, Cohen kappa co-efficiency [very good (κ > 0.8), good (κ = 0.61-0.8), moderate (κ = 0.41-0.6), low (κ = 0.21-0.4), and very low (κ ≤ 0.2)] was calculated.

RESULTS

Comparison of baseline data

All healthy participants and all patients had no particular complications related to sonography. There were no statistical differences between the three groups with regard to age and gender, or between the two patient groups with regard to persistent symptoms (*P* > 0.05). All healthy participants had no special findings on sonography (Figures 1 and 2). The general characteristics of the three groups showed no significant differences (*P* > 0.05) (Table 1).

"Mosaic pattern" in TPUS

TPUS was considered as the standard modality to determine abnormal findings of hemorrhoids. Grades Ⅲ and Ⅳ hemorrhoids revealed blood flow with different directions which could be observed as a "mosaic pattern" (Figures 3 and 4, Table 2). In patients with grade Ⅲ or Ⅳ hemorrhoids, color Doppler ultrasound showed multidirectional, turbulent flow consistent with an arteriovenous flow pattern, which seemed similar to the mosaic pattern mentioned in other studies of

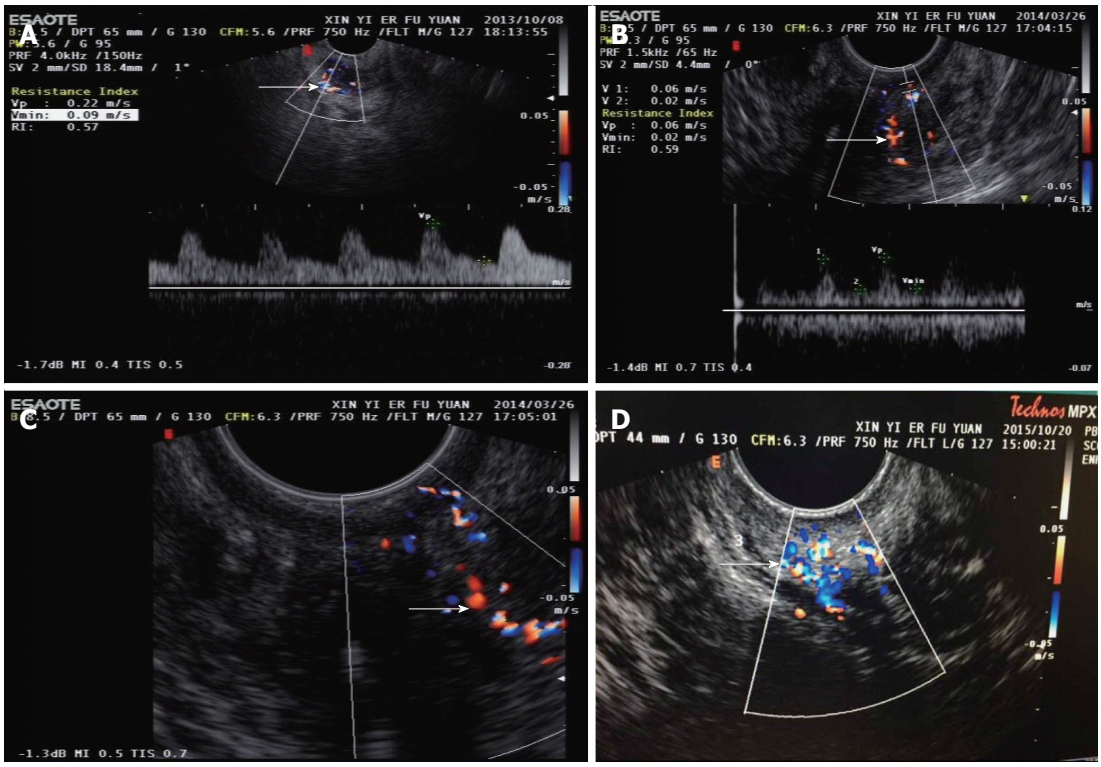

Figure 4 Mosaic pattern in the pathological anal cushion. A: "Mosaic pattern" was a special blood flow with different directions (white arrow); B: Special blood flow of "mosaic pattern" (white arrow); C: Special blood flow of "mosaic pattern" instructed with red and blue color (white arrow); D: Special blood flow of "mosaic pattern" instructed with multiple colors (white arrow).

Table 1 General characteristics of the three groups

	Total No.	Gender, male/female	Age (yr)	Duration of symptoms (mo)
Group A (stages Ⅲ and Ⅳ)	38	26/12	42 ± 2.4	7.8 ± 2.4
Group B (stages Ⅰ and Ⅱ)	24	14/10	44 ± 2.5	6.6 ± 3.8
Group C (healthy controls)	42	24/18	41 ± 2.2	-
χ^2/*t*-value	1	0.28751	1	
	2	0.65502	2	
	3	0.02713	3	
P value	1	0.59191	1	
	2	0.41832	2	
	3	0.86923	3	

[1]Comparison between group A and group B; [2]Comparison between group A and group C; [3]Comparison between group B and group C.

Table 2 The mosaic pattern according to different methods for the three groups

	TRUS	TPUS	TVUS in female	Pathology	*P* value
Group A (stages Ⅲ and Ⅳ)	22/38	12/38	4/12	20/38	0.0379[4] 0.2488[5] 0.8093[6]
Group B (stages Ⅰ and Ⅱ)	4/24	2/24	2/10	-	0.6625[4] 0.7983[5] 0.7055[6]
Group C (healthy controls)	0/42	0/42	0/18	-	-
χ^2/*t*-value	8.6449[1] 30.6981[2] 4.8117[3]	3.3142[1] 13.2252[2] 1.3305[3]	0.0477[1] 4.3389[2] 1.4479[3]	-	-
P value	0.0033[1] 0.0000[2] 0.0283[3]	0.0687[1] 0.0003[2] 0.2487[3]	0.8270[1] 0.0373[2] 0.2289[3]	-	-

[1]Comparison between group A and group B; [2]Comparison between group A and group C; [3]Comparison between group B and group C; [4]Comparison between TRUS and TPUS; [5]Comparison between TRUS and TVUS; [6]Comparison between TPUS and TVUS. TRUS: Transrectal ultrasound; TPUS: Transperianal ultrasound; TVUS: Transvaginal ultrasound.

arteriovenous malformation[16,17]. In patients with grade Ⅲ and Ⅳ hemorrhoids, the number of patients with the "mosaic pattern" as revealed by TRUS, TPUS, and TVUS was 22, 12, and 4, respectively. When compared between different groups, TRUS presented the advantage that the "mosaic pattern" could be confirmed in more patients, especially for group A. Patients with grade Ⅲ and Ⅳ disease presented with a pathologically abnormal cushion which usually appeared as a "mosaic pattern" in TPUS and an arteriovenous fistula in pathology. The compatibility (Cohen's kappa co-efficiency value) between the TPUS and pathology was calculated as 0.8939 (Table 3). The vessel diameter measured by TRUS in group A and group B was 2.6 ± 0.4 and 0.6 ± 0.4, respectively. Blood flow velocity measured by TRUS in group A and group B was 56.4 ± 4.3 and 20.8 ± 3.4, respectively (Table 4). There were obvious statistical differences between group A and group B with regard to the vessel diameter and blood flow velocity measured by TRUS ($P < 0.05$).

Table 3 Cohen's kappa co-efficiency between mosaic pattern in transrectal ultrasound and arteriovenous fistula in pathology in stages Ⅲ and Ⅳ hemorrhoids

Pathology	Mosaic pattern in transrectal US		Total
	Positive	Negative	
Positive	20	0	20
Negative	2	16	18
Total	22	16	38

The compatibility (Cohen's kappa co-efficiency value) between the transperianal US and pathology was calculated as 0.8939. The distribution of the Cohen kappa (κ) co-efficiency values: very high (κ > 0.8), high (κ = 0.61-0.8), moderate (κ = 0.41-0.6), low (κ = 0.21-0.4), very low (κ ≤ 0.2).

Table 4 Vessel diameter and blood flow velocity detected by transrectal ultrasound

	n	Vessel diameter (mm)	Blood flow velocity (cm/s)
Group A (stages Ⅲ and Ⅳ)	22	2.6 ± 0.4	56.4 ± 4.3
Group B (stages Ⅰ and Ⅱ)	20	0.6 ± 0.4	20.8 ± 3.4
χ^2/*t*-value		16.1835	29.5566
P value		0	0

"Arteriovenous fistulas" in pathology

Subepithelial vessels of resected grades Ⅲ-Ⅳ hemorrhoid tissues were manifested by obvious structural impairment and retrograde and ruptured changes of internal elastic lamina. Some parts of the Trietz's muscle showed hypertrophy and distortion. Arteriovenous fistulas and venous dilatation were obvious in the anal cushion of hemorhoidal tissues (Figures 5-7). After pathological results with arteriovenous fistulas were taken as the standard reference, we evaluated the compatibility between the two methods according to the Cohen's kappa co-efficiency calculation. The compatibility (Cohen's kappa co-efficiency value) between the "mosaic pattern" in TPUS and arteriovenous fistula in pathology was very good (Table 3).

Comparison of findings of the three different sonographic modalities

There was no special findings in sonography of healthy participants (Figure 1). A pilot series of experiments enabled the sonographers to attain technical expertise in all methods before commencement of the study. Ultrasonographic measurements using a 2-sonographer protocol were obtained for all 104 study patients; the examinations were blinded and paired and used transperineal and transrectal techniques combined with transvaginal technique in female patients. No patients were excluded from the analysis. We calculated the number of patients in which the "mosaic pattern" could be observed in each group, and we analyzed the outcomes between the different groups of patients, and between different techniques (Table 2). For patients with stages Ⅲ and Ⅳ hemorrhoids, TRUS seemed to be the most effective technique.

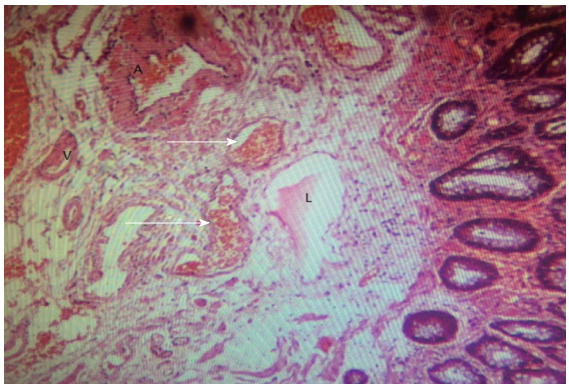

Figure 5 Subepithelial vessels of resected grades Ⅲ and Ⅳ hemorrhoid tissues were manifested by obvious structural impairment and retrograde and ruptured changes of internal elastic lamina. Arteriovenous fistulas and venous dilatation were obvious in the anal cushion of hemorhoidal tissues (white arrow, magnification × 80); A: Artery, V: Vein, L: Lymphatic duct.

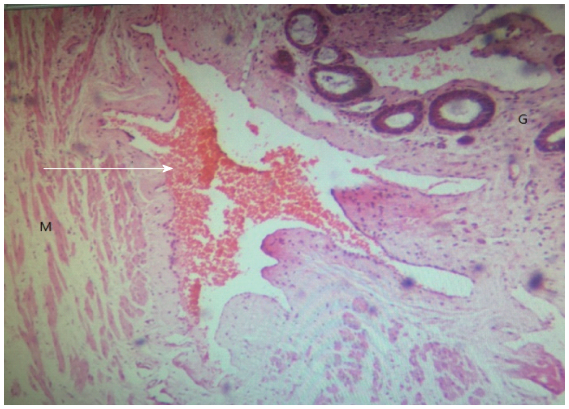

Figure 6 Blood cells in the arteriovenus fistula of anal cushion were seen (white arrow, magnification × 80). M: Muscle; G: Glands.

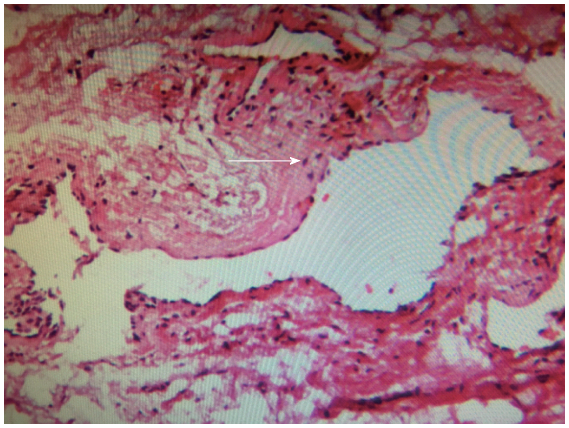

Figure 7 Arteriovenus fistula of anal cushion was obvious (white arrow, magnification × 400). Some parts of the Trietz's muscle showed hypertrophy and distortion.

When compared with TPUS, there was a significant difference ($P < 0.05$). But between TRUS and TVUS, and between TPUS and TVUS, there was no significant difference ($P > 0.05$ for both). When stages Ⅰ and Ⅱ hemorrhoids were examined, there were no significant

differences between TRUS, TPUS, and TVUS (P > 0.05). When compared between different groups, the technique of TRUS presented advantages; the "mosaic pattern" could be confirmed in more patients, especially in group A, and there was a statistical difference when comparing group A with group B or C (P < 0.05 for both). A statistical difference using TPUS was also observed between group A and group B or C, but group A and B had no statistical difference between the results of the TVUS examination. In patients with hemorrhoids, the submucosa may be thickened and show a more echolucent appearance, suggesting the presence of fluid (*i.e.*, blood). The amount of fluid was correlated with the degree of severity of hemorrhoids. Treatment of hemorrhoids with rubber band ligation or infrared coagulation did not alter anal configuration. The mucosal hemorrhoidal plexus was better visualized by vaginal endosonography. Thirty patients with hemorrhoids had blood signals around the dentate line on ultrasonography, and on the same scanning plane, blood flow with different directions could be observed as a mosaic pattern in grades Ⅲ and Ⅳ hemorrhoids. There were underlying characteristics of the sonographic changes of hemorrhoids (Figures 1-4). Patients with grade Ⅲ and Ⅳ hemorrhoids presented with a pathologically abnormal cushion which usually appeared as a "mosaic pattern" in sonography and an arteriovenous fistula in pathology (Figures 1-6). Two-dimensional ultrasonography revealed point sheet hypoechoic areas and intertwined flowing fine punctate anechoic areas; these were observed inside the inner layer of the thickened internal sphincter, which resembled a mixed cystic and solid honeycomb echo area. Color Doppler ultrasonography indicated that the anal cushion area of hemorrhoids contained blood signals. On the same scanning plane, blood flow with different directions could be observed as a "mosaic pattern". High-speed low-resistance arterial flow spectrum and arterialized venous spectrum could be observed as a bright colored area (Figures 3 and 4).

DISCUSSION

Hemorrhoids are a commonly occurring human disease, and the causes are not well known to date. There are still controversial opinions on the etiology of hemorrhoids. There are several hypotheses, but no definite evidence regarding the etiology or origin of hemorrhoids. Ultrasonographic examination is an accepted technique for local staging of both benign anorectal disease and disorders, and malignant anal and perianal neoplasms[18,19]. Endoanal ultrasound (EAUS) of the anal sphincters is achieved by the simple expedient of replacing the balloon system used for rectal scanning with a hard cone[20]. The normal rectal wall is 2 to 3 mm thick and is composed of a 5-layer longitudinal muscle, joint longitudinal muscle and external sphincter, as is the rest of the digestive tract[21]. The anal canal is 2 to 4 cm long and is closed in the normal situation. Therefore, excellent images can be obtained by TRUS, as the anus lies tight around the probe. It is very important that the rectum is empty and clear prior to examination because residual stool can cause a deterioration of the image quality and impede interpretation[22]. The external anal sphincter is a voluntary muscle arising from the levator ani and puborectalis muscle to form a circular structure around the anal canal. The anatomy of the external anal sphincter remains controversial and is usually described as having three parts: a deep part joining with the puborectalis muscle, a superficial part attached to the superficial transverse perinei muscle, and a subcutaneous part continuing below the internal anal sphincter. The length of the anal canal, corresponding to the posterior longitudinal length of the external anal sphincter, was substantially greater in men than in women (3.5 cm *vs* 3.05 cm, on average), consistent with numerous previous reports[23,24]. The anatomical gap produced by this asymmetrical configuration would explain, on the basis of a lower resistance of the anterior rectal wall, the greater incidence of functional female pelvic floor disorders[5,25]. This anatomical description cannot always be observed using TRUS[26-28]. Vaginal endosonography, used to visualize the perianal area and especially the perineum, is an alternative when rectal endosonography is not possible because the anus is asymmetrical, causing air artifacts, extreme anal stenosis, or pain[29]. TPUS is also used to image the perianal area in patients with perianal fistula[30,31] or imperforate anus[31]. However, results using EUS seem somewhat better[32,33].

The highlight of this study was a new finding of a "mosaic pattern" in sonography which may be concordant with an arteriovenous fistula in pathology. Patients with grades Ⅲ and Ⅳ hemorrhoids presented with a pathologically abnormal cushion which usually appeared as a "mosaic pattern" in sonography and an arteriovenous fistula in pathology. "Mosaic pattern" was a special blood flow with different directions. This special pattern was firstly reported by Aslan H[16], and described as "clover-leafed shape" in a pilot study reported by Zbar *et al*[34]. Color Doppler ultrasonography also indicated that "mosaic pattern" in the anal cushion area of hemorrhoids contained special blood signals. On the same scanning plane, blood flow with different directions can be observed as an "mosaic pattern". High-speed low-resistance arterial flow spectrum and arterialized venous spectrum can be observed as a bright colored area. This result is encouraging. This new finding of a pathologically abnormal cushion, observed as "mosaic pattern" in sonography and an arteriovenous fistula in pathology, was confirmed in our study. After pathological results with arteriovenous fistulas were taken as the standard reference, we evaluated the compatibility between the two methods according to the Cohen's kappa co-efficiency calculation. The compatibility (Cohen's kappa co-efficiency value) between "mosaic pattern" in the

transperianal US and arteriovenous fistula in pathology was very good (Kappa = 0.8939). It could help to interpret important etiological aspects of hemorrhoids, and could influence traditional surgical methods. The procedure of prolapse to hemorrhoids (PPH) or tissue selecting therapy (TST) for hemorrhoid treatment could be replaced by sonographic vascular therapy or other related techniques which are safer and less expensive.

TPUS is a simple, accessible, inexpensive, safe, and painless technique that dynamically and noninvasively evaluates anorectal structures. A previous study showed that two-dimensional TPUS had a specificity and sensitivity of 85% and 64%, respectively[35]. In addition, TRUS has been used for almost every possible disease in the anal region, and by delineating the anatomy it has increased insight into anal pathology. Clinical indications for TRUS in benign anorectal diseases are fecal incontinence for the detection of defects and atrophy, perianal fistulas, and abscesses for the demonstration of fistula tracts. Thekkinkattil *et al*[36] reported differences of the anal cushion area for some anorectal diseases using TVUS. These types of anal cushion differences were also confirmed in this study. We suggest that abnormalities and pathological changes of the anal cushion are one of the important reasons for symptomatic hemorrhoids.

Ultrasound can provide high-resolution images that can show hemodynamic information, and allow one to observe morphological and hemodynamic changes through a unique perspective. Therefore, ultrasound can play an important role in the diagnosis and differential diagnosis of hemorrhoids. The researcher can observe the rectal cavernous region and blood supply to the hemorrhoid through color endosonography, perineal sonography, and even transvaginal sonography. The vascular plexus full of blood flow can also be observed[37]. The reduction of the hemorrhoid blood supply could reduce blood reflux burden, symptoms of bleeding, and swelling. In recent years, hemorrhoid artery ligation has already been used as a minimally invasive surgery[38]. Color biplane endosonographic imaging studies have shown that the vast majority of hemorrhoidal arteries are located within the anorectal junction at 2 cm above the rectal mucosa, and this is regarded as the best area for hemorrhoid artery ligation[39]. Ten years before, Aigner *et al*[40] concluded that increased caliber and arterial blood flow of the terminal branches of the superior rectal artery are correlated with the appearance of hemorrhoids. They suggested that the hypervascularization of the anorectum contributes to the growth of hemorrhoids rather than being a consequence of hemorrhoids. Their observations confirmed that morphological changes are clearly detectable with the use of transperineal color Doppler ultrasound in patients with symptomatic hemorrhoids. Aigner F believed that transperineal color Doppler ultrasound is an appropriate method to assess these findings in patients with hemorrhoids. Four years before, Miyamoto *et al*[41] reported encouraging results using power Doppler imaging transanal ultrasound and three-dimensional power doppler angiography to visualize the haemorrhoidal plexus and the course of the haemorrhoidal artery *in vivo*. They found that blood flow significantly increased following advancement of the grade of haemorrhoid, and they also concluded that the distribution of haemorrhoidal arteries varies widely in both the number and the position. In their research, they demonstrated that the median number of haemorrhoidal arteries was five (range, 3-9) and that they were found in various positions, being located, in 62.1% of patients, at 1 o'clock but more commonly at the 3, 7 and 11 o'clock positions. Around the hemorrhoid area, using color biplane endosonographic imaging, we found this new abnormal structure characterized as a "mosaic pattern" inside the abnormal anal cushions, and we found an arteriovenous vascular plexus or fistula using pathology. We also observed a specific sonographic appearance characterized as arterialized venous blood flow of the arteriovenous fistula under pulsed sonography. The hemorrhoid in the same patient may have a single or several vessels in certain anal points or may have specific characteristics of an arteriovenous fistula at other points. Hemorrhoid vessels may directly penetrate the submucosa in other patients. It is unclear if these characteristics define the severity of the hemorrhoid, and further research is needed to confirm this. The discovery of an arteriovenous fistula in pathological anal cushions provides important diagnostic, therapeutic, and etiologic information for hemorrhoids. We strongly believe that the "mosaic pattern" inside the abnormal anal cushion on endosonography was most likely to fit with a pathological diagnosis of an arteriovenous fistula. However, we need further investigation and research to clarify these changes.

In our study, arteriovenous fistulas and venous dilatation were very obvious in the anal cushion of hemorhoidal tissues. After pathological results with arteriovenous fistulas were taken as the standard reference, we evaluated the compatibility between the two methods according to the Cohen's kappa co-efficiency calculation. The compatibility (Cohen's kappa co-efficiency value) between "mosaic pattern" in the transperianal US and arteriovenous fistula in pathology was very good. We believe that correctly identifying the hemorrhoidal artery and arteriovenous vascular plexus and avoiding blind treatment at the 3, 7, and 11 o'clock positions has become an urgent problem when dealing with bleeding anal diseases. The aim of this study was to provide a highly sensitive and accurate method for positioning vessels in the hemorrhoid area. We believed that not all the grades Ⅲ and Ⅳ hemorrhoids should receive surgery. We considered that mosaic pattern should be a key parameter in determining surgical operation. In addition, we hope

to guide clinicians in their preoperative assessment by selecting minimally invasive, safe and effective treatment strategies and decreasing surgical complications and the recurrence rate. At the same time, we aimed to provide a broader range of ideas for reasonable treatment, the innovation of new surgical techniques, and drug development which targets hemorrhoids. However, ultrasonography still has its limitations, although TVUS of the anorectum is well tolerated and can accurately detect abnormalities of the anal sphincter and surrounding structures[42]. Limitations for the application of EAUS include strictures and acute painful conditions. These caveats are largely caused by the size of regular rectal probes which have an average diameter of 17 to 20 mm. The introduction of EAUS probes with a diameter below 1 cm (actually 7 mm) represents a major improvement, particularly for imaging all layers of the anal canal even under acute pain[43]. The second pitfall of EAUS, also caused by the size of the probes, relates to changes in the anatomy of the anal canal resulting from the stretching of the anal canal and compression of the mucosal tissues. Thus, the EAUS picture of the anal canal does not reflect the anatomical situation, which makes it difficult to judge the status of the anoderm and to locate the hemorrhoidal tissue. The use of a small endoanal probe of only 7 mm in diameter enabled us to overcome these limitations. The limitation of EAUS *vs* endoanal magnetic resonance imaging, however, is the poor inherent contrast on images, which makes characterization of the external anal sphincter difficult, but it could be overcome by using a higher frequency transducer (10 MHz)[44].

We can conclude from this prospective study that there were clearly different structures of hemorrhoids observed by sonography compared with sonography of the control group. Findings of special mosaic pattern in sonography greatly influence clinical decisions in the treatment of hemorrhoids. Sonography may be useful for the early detection and early intervention of hemorrhoids. Mosaic pattern can play a key role in determining the best hemorrhoids management. Mosaic pattern could be a parameter for surgical indication of stages Ⅲ and Ⅳ hemorrhoids. If our new finding of a pathologically abnormal cushion, which appeared as a "mosaic pattern" in sonography and an arteriovenous fistula in pathology, is confirmed in the future, it could help to interpret important etiological aspects of hemorrhoids and would influence traditional surgical methods. The PPH or TST for hemorrhoids could be replaced by sonographic vascular therapy or other related techniques which are safer and less expensive.

ACKNOWLEDGMENTS

The authors would like to thank Professor Adali and Professor Xiang Yan at Xinjiang Medical University for their technical support and careful statistical assistance. The authors also thank Dr. Turgunjan Tuerxun at Xinjiang Medical University and Pro Adili Abudoureyimu at ATLAN International Language Center for their careful language assistance.

COMMENTS

Background

There are still controversial opinions on the etiology of hemorrhoids. Most surgeons confirm the diagnosis and indication of hemorrhoids according to their anal examination result. Ultrasound is an inexpensive, safe technique that can dynamically and noninvasively evaluate the anorectal area, using transperianal, transrectal, and transvaginal examinations. However, there have been few reports concerning hemorrhoid diagnosis or abnormalities using endoanal sonography. There are clearly different hemorrhoid structures shown by sonography in patients.

Research frontiers

The main purpose of this prospective study was to measure the anal cushion area using sonographic examinations in a group of patients with hemorrhoids of different grades (I-Ⅳ) and to compare them with a control group of age-matched healthy volunteers. This research also aimed to evaluate the diagnostic value of different sonographic methods in hemorrhoids.

Innovations and breakthroughs

The authors found the special structure in hemorrhoid patients by ultrasound and it was confirmed by pathology. Patients with grade Ⅲ and Ⅳ disease presented with a pathologically abnormal cushion which usually appeared as a mosaic pattern in transperianal US and an arteriovenous fistula in pathology.

Applications

Mosaic pattern could be a parameter for surgical indication of stages Ⅲ and Ⅳ hemorrhoids. Mosaic pattern can play a key role in determining the best hemorrhoid management. If they new finding of a pathologically abnormal cushion, which appeared as a "mosaic pattern" in sonography and an arteriovenous fistula in pathology, is confirmed in the future, it could help to interpret important etiological aspects of hemorrhoids and would influence traditional surgical methods.

Terminology

"Mosaic pattern" is a special blood flow with different directions. Patients with grades Ⅲ and Ⅳ hemorrhoids present with a pathologically abnormal cushion which usually appears as a "mosaic pattern" in sonography and an arteriovenous fistula in pathology.

Peer-review

It is a very interesting paper. These data could be very useful for the diagnosis and choice of treatment for hemorrhoids.

REFERENCES

1 **Thomson WH**. The nature of haemorrhoids. *Br J Surg* 1975; **62**: 542-552 [PMID: 1174785]

2 **Gaj F**, Trecca A. Hemorrhoids and rectal internal mucosal prolapse: one or two conditions? A national survey. *Tech Coloproctol* 2005; **9**: 163-165 [PMID: 16007353 DOI: 10.1007/s10151-005-0219-0]

3 **Aigner F**, Gruber H, Conrad F, Eder J, Wedel T, Zelger B, Engelhardt V, Lametschwandtner A, Wienert V, Böhler U, Margreiter R, Fritsch H. Revised morphology and hemodynamics of the anorectal vascular plexus: impact on the course of hemorrhoidal disease. *Int J Colorectal Dis* 2009; **24**: 105-113 [PMID: 18766355 DOI: 10.1007/s00384-008-0572-3]

4 **Gibbons CP**, Trowbridge EA, Bannister JJ, Read NW. Role of

anal cushions in maintaining continence. *Lancet* 1986; **1**: 886-888 [PMID: 2870357 DOI: 10.1016/S0140-6736(86)90990-6]
5 **Santoro GA**, Wieczorek AP, Dietz HP, Mellgren A, Sultan AH, Shobeiri SA, Stankiewicz A, Bartram C. State of the art: an integrated approach to pelvic floor ultrasonography. *Ultrasound Obstet Gynecol* 2011; **37**: 381-396 [PMID: 20814874 DOI: 10.1002/uog.8816]
6 **Oppenheimer DA**, Carroll BA, Shochat SJ. Sonography of imperforate anus. *Radiology* 1983; **148**: 127-128 [PMID: 6856821 DOI: 10.1148/radiology.148.1.6856821]
7 **Maconi G**, Porro GB. Ultrasound of the gastrointestinal trct. 2nd edition. Springer, 2014
8 **Rifkin MD**. Endorectal sonography of the prostate: clinical implications. *AJR Am J Roentgenol* 1987; **148**: 1137-1142 [PMID: 2437784 DOI: 10.2214/ajr.148.6.1137]
9 **Hildebrandt U**, Feifel G, Ecker KW. Rectal endosonography. *Baillieres Clin Gastroenterol* 1989; **3**: 531-541 [PMID: 2692730]
10 **Law PJ**, Kamm MA, Bartram CI. A comparison between electromyography and anal endosonography in mapping external anal sphincter defects. *Dis Colon Rectum* 1990; **33**: 370-373 [PMID: 2183977]
11 **Law PJ**, Talbot RW, Bartram CI, Northover JM. Anal endosonography in the evaluation of perianal sepsis and fistula in ano. *Br J Surg* 1989; **76**: 752-755 [PMID: 2670055 DOI: 10.1002/bjs.1800760737]
12 **Sultan AH**, Loder PB, Bartram CI, Kamm MA, Hudson CN. Vaginal endosonography. New approach to image the undisturbed anal sphincter. *Dis Colon Rectum* 1994; **37**: 1296-1299 [PMID: 7995162]
13 **Nicholls MJ**, Dunham R, O'Herlihy S, Finan PJ, Sagar PM, Burke D. Measurement of the anal cushions by transvaginal ultrasonography. *Dis Colon Rectum* 2006; **49**: 1410-1413 [PMID: 16729219 DOI: 10.1007/s10350-006-0550-1]
14 **Cataldo P**, Ellis CN, Gregorcyk S, Hyman N, Buie WD, Church J, Cohen J, Fleshner P, Kilkenny J, Ko C, Levien D, Nelson R, Newstead G, Orsay C, Perry WB, Rakinic J, Shellito P, Strong S, Ternent C, Tjandra J, Whiteford M. Practice parameters for the management of hemorrhoids (revised). *Dis Colon Rectum* 2005; **48**: 189-194 [PMID: 15711856 DOI: 10.1007/s10350-004-0921-4]
15 **Stewart LK**, Wilson SR. Transvaginal sonography of the anal sphincter: reliable, or not? *AJR Am J Roentgenol* 1999; **173**: 179-185 [PMID: 10397123 DOI: 10.2214/ajr.173.1.10397123]
16 **Aslan H**, Acar DK, Ekiz A, Kaya B, Sezer S, Ismayilzade R, Can M. Sonographic features and management options of uterine arteriovenous malformation. A case report. *Med Ultrason* 2015; **17**: 561-563 [PMID: 26649357 DOI: 10.11152/mu.2013.2066.174.sgh]
17 **Poen FB**, Cuesta M. Anal endosonography in haemorrhoidal disease: do anatomical changes have clinical implications? *Colorectal Dis* 1999; **1**: 146-150 [PMID: 23577761 DOI: 10.1046/j.1463-1318.1999.00038.x]
18 **Stoker J**, Halligan S, Bartram CI. Pelvic floor imaging. *Radiology* 2001; **218**: 621-641 [PMID: 11230632 DOI: 10.1148/radiology.218.3.r01mr26621]
19 **Sudakoff GS**, Quiroz F, Foley WD. Sonography of anorectal, rectal, and perirectal abnormalities. *AJR Am J Roentgenol* 2002; **179**: 131-136 [PMID: 12076921 DOI: 10.2214/ajr.179.1.1790131]
20 **Law PJ**, Bartram CI. Anal endosonography: technique and normal anatomy. *Gastrointest Radiol* 1989; **14**: 349-353 [PMID: 2680741]
21 **Wu CJ**, Liu YL, Wang JF, Wu GZ, Chu YZ, Zhang F, Wang Y. Dual plane ultrasonography study of anal canal. *Zhonghua Chaosheng Yingxiangxue Zazhi* 2010; **19**: 960-962 [DOI: 10.3760/cma.j.issn.1004-4477.2010.11.014]
22 **Saranovic D**, Barisic G, Krivokapic Z, Masulovic D, Djuric-Stefanovic A. Endoanal ultrasound evaluation of anorectal diseases and disorders: technique, indications, results and limitations. *Eur J Radiol* 2007; **61**: 480-489 [PMID: 17188828 DOI: 10.1016/j.ejrad.2006.07.033]
23 **Brunese L**, Amitrano M, Gargano V, Vallone G, Grassi R, Rotondo A, Smaltino F. [Anal endosonography: the study technic and the correlations between the normal and echographic anatomy]. *Radiol Med* 1996; **91**: 253-257 [PMID: 8628939]
24 **Williams AB**, Cheetham MJ, Bartram CI, Halligan S, Kamm MA, Nicholls RJ, Kmiot WA. Gender differences in the longitudinal pressure profile of the anal canal related to anatomical structure as demonstrated on three-dimensional anal endosonography. *Br J Surg* 2000; **87**: 1674-1679 [PMID: 11122183 DOI: 10.1046/j.1365-2168.2000.01581.x]
25 **Thakar R**, Fenner DE. Anatomy of the perineum and the anal sphincter. In: Sultan AH, Thakar R, Fenner D, editors. Perineal and anal sphincter trauma. London: Springer; 2007: 1-12
26 **Lunniss PJ**, Phillips RK. Anatomy and function of the anal longitudinal muscle. *Br J Surg* 1992; **79**: 882-884 [PMID: 1422746]
27 **Gerdes B**, Köhler HH, Zielke A, Kisker O, Barth PJ, Stinner B. The anatomical basis of anal endosonography. A study in postmortem specimens. *Surg Endosc* 1997; **11**: 986-990 [PMID: 9381354]
28 **Konerding MA**, Dzemali O, Gaumann A, Malkusch W, Eckardt VF. Correlation of endoanal sonography with cross-sectional anatomy of the anal sphincter. *Gastrointest Endosc* 1999; **50**: 804-810 [PMID: 10570340]
29 **Poen AC**, Felt-Bersma RJ, Cuesta MA, Meuwissen GM. Vaginal endosonography of the anal sphincter complex is important in the assessment of faecal incontinence and perianal sepsis. *Br J Surg* 1998; **85**: 359-363 [PMID: 9529493 DOI: 10.1046/j.1365-2168.1998]
30 **Kleinübing H**, Jannini JF, Campos AC, Pinho M, Ferreira LC. The role of transperineal ultrasonography in the assessment of the internal opening of cryptogenic anal fistula. *Tech Coloproctol* 2007; **11**: 327-331 [PMID: 18058065 DOI: 10.1007/s10151-007-0375-5]
31 **Maconi G**, Ardizzone S, Greco S, Radice E, Bezzio C, Bianchi Porro G. Transperineal ultrasound in the detection of perianal and rectovaginal fistulae in Crohn's disease. *Am J Gastroenterol* 2007; **102**: 2214-2219 [PMID: 17680844 DOI: 10.1111/j.1572-0241.2007.01441.x]
32 **Haber HP**, Seitz G, Warmann SW, Fuchs J. Transperineal sonography for determination of the type of imperforate anus. *AJR Am J Roentgenol* 2007; **189**: 1525-1529 [PMID: 18029895 DOI: 10.2214/AJR.07.2468]
33 **Zbar AP**, Oyetunji RO, Gill R. Transperineal versus hydrogen peroxide-enhanced endoanal ultrasonography in never operated and recurrent cryptogenic fistula-in-ano: a pilot study. *Tech Coloproctol* 2006; **10**: 297-302 [PMID: 17115320 DOI: 10.1007/s10151-006-0296-8]
34 **Zbar AP**, Murison R. Transperineal ultrasound in the assessment of haemorrhoids and haemorrhoidectomy: a pilot study. *Tech Coloproctol* 2010; **14**: 175-179 [PMID: 20390316 DOI: 10.1007/s10151-010-0572-5]
35 **Roos AM**, Abdool Z, Sultan AH, Thakar R. The diagnostic accuracy of endovaginal and transperineal ultrasound for detecting anal sphincter defects: The PREDICT study. *Clin Radiol* 2011; **66**: 597-604 [PMID: 21440249 DOI: 10.1016/j.crad.2010.11.017]
36 **Thekkinkattil DK**, Dunham RJ, O'Herlihy S, Finan PJ, Sagar PM, Burke DA. Measurement of anal cushions in idiopathic faecal incontinence. *Br J Surg* 2009; **96**: 680-684 [PMID: 19384910 DOI: 10.1002/bjs.6597]
37 **Fu CG**, Lu JP, Li WP. Atlas of pelvic floor and analcanalradiology. Beijing: People's Medical Publishing House, 2010: 7-8
38 **Tiernan J**, Hind D, Watson A, Wailoo AJ, Bradburn M, Shephard N, Biggs K, Brown S. The HubBLe trial: haemorrhoidal artery ligation (HAL) versus rubber band ligation (RBL) for haemorrhoids. *BMC Gastroenterol* 2012; **12**: 153 [PMID: 23098097 DOI: 10.1186/1471-230X-12-153]
39 **Ratto C**, Parello A, Donisi L, Litta F, Zaccone G, Doglietto GB. Assessment of haemorrhoidal artery network using colour duplex imaging and clinical implications. *Br J Surg* 2012; **99**: 112-118 [PMID: 22021046 DOI: 10.1002/bjs.7700]
40 **Aigner F**, Bodner G, Gruber H, Conrad F, Fritsch H, Margreiter R, Bonatti H. The vascular nature of hemorrhoids. *J Gastrointest Surg* 2006; **10**: 1044-1050 [PMID: 16843876 DOI: 10.1016/

j.gassur.2005.12.004]
41 **Miyamoto H**, Asanoma M, Miyamoto H, Takasu C, Masamune K, Shimada M. Visualization and hypervascularization of the haemorrhoidal plexus in vivo using power Doppler imaging transanal ultrasonography and three-dimensional power Doppler angiography. *Colorectal Dis* 2013; **15**: e686-e691 [PMID: 24034699 DOI: 10.1111/codi.12406]
42 **Fuchsjäger MH**, Maier AG. Imaging fecal incontinence. *Eur J Radiol* 2003; **47**: 108-116 [PMID: 12880991]
43 **Weyandt GH**, EggertAO, Brocker EB. The sonographic appearance of the anal canal by endoanal sonography with a 7 mm probe. *Coloproctology* 2004; **26**: 15-20[DOI: 10.1007/s00053-004-5113-0]
44 **Frudinger A**, Halligan S, Bartram CI, Price AB, Kamm MA, Winter R. Female anal sphincter: age-related differences in asymptomatic volunteers with high-frequency endoanal US. *Radiology* 2002; **224**: 417-423 [PMID: 12147837 DOI: 10.1148/radiol.2242010985]

P- Reviewer: Vidal V **S- Editor**: Gong ZM **L- Editor**: Wang TQ
E- Editor: Wang CH

Published by **Baishideng Publishing Group Inc**
7901 Stoneridge Drive, Suite 501, Pleasanton, CA 94588, USA
Telephone: +1-925-223-8242
Fax: +1-925-223-8243
E-mail: bpgoffice@wjgnet.com
Help Desk: http://www.f6publishing.com/helpdesk
http://www.wjgnet.com

ISSN 1007-9327