

Cytogenetic Evaluation of Down Syndrome: A Review of 1020 Referral Cases

N. Chandra¹, Cyrus Cyril¹, Prema Lakshminarayana², P. Nallasivam⁵, A. Ramesh¹,
P. M. Gopinath³ and K. M. Marimuthu⁴

¹*Department of Genetics, Dr. ALM PG Institute of Basic Medical Sciences,
University of Madras, Taramani, Chennai 600 113, Tamil Nadu, India*

²*Department of Medical Genetics, The Tamil Nadu Dr. M.G.R. Medical University, Guindy,
Chennai 600 032, Tamil Nadu, India*

³*KMC Life Sciences Center, Manipal Academy of Higher Education, Manipal 576 104,
Karnataka, India*

⁴*26, I Main Road, Indira Nagar, Adyar, Chennai 600 020, Tamil Nadu, India*

⁵*Michigan Centre for Translational Pathology, University of Michigan Medical School,
Ann Arbor MI, USA*

KEYWORDS Down Syndrome. Trisomy 21. Robertsonian Translocation. Mosaicism. Tandem 21;21 Rearrangement

ABSTRACT A retrospective analysis was performed on 1102 cases with a provisional diagnosis of Down syndrome referred to the Department of Genetics, Dr.ALMPGIBMS, University of Madras during the period from 1979 to 2006. Cytogenetic analyses confirmed the diagnosis in 1020 cases (92.6%). Among them, regular (free) trisomy 21 constituted 83.82 percent. Mosaicism was recorded in 10.78% and Robertsonian translocations in five percent of cases. The translocation was of *de novo* origin in about 50 percent of the individuals where families had been investigated. Trisomy 21 was associated with structural and numerical chromosomal anomalies in one case each. A tandem 21;21 rearrangement and a familial 13;21 Robertsonian translocation with mosaicism for Y chromosome were seen in two other cases. The mean maternal age was higher in regular trisomy 21 (25.08 years) than in translocation (22.83 years) cases. An excess of males was seen in all groups except in the translocation group where the male:female ratio was 0.93. This paper summarizes the chromosomal abnormalities and the clinical features seen in these patients.

INTRODUCTION

Down syndrome (DS) or trisomy 21, with its characteristic clinical features is the most frequently observed autosomal aneuploidy with an incidence of about 1 in 700 live births. The prevalence of DS in India is 0.88 per 1000 (1 out of 1139) to 1.09 per 1000 (1 out of 916) and three DS children are reported to be born every hour (Rajangam and Thomas 1992; Verma 2000; Malini and Ramachandra 2006). In general, over 95% of Down syndrome individuals possess free trisomy 21 resulting from non-disjunctional error of chromosome 21 during gametogenesis in one on the parents. While about 2-4% result from a translocation of chromosome 21 on to a D or G group chromosome, 1-2% are mosaics showing a normal cell line additionally, due to mosaicism (Nussbaum et al. 2001). This retrospective study on referral cases of Down syndrome was undertaken to correlate the cytogenetic profile with the clinical features and parental age.

SUBJECTS AND METHODS

Cytogenetic investigation was carried out on 1159 cases referred with clinical features of Down syndrome and aged between 2 days to 36 years during the period from 1979 to 2006. Culture failure resulted in successful determination of the karyotype in 1102 cases. The patients were referred to the Department of Genetics, University of Madras from different parts of Tamil Nadu and also from neighboring states. Information on age, birth order, parental age and clinical features at presentation were documented using pre-signed questionnaire. Karyotypes were prepared from GTG-banded mitotic chromosomes of PHA-stimulated peripheral blood leucocytes. Parents were also investigated wherever possible.

RESULTS

Abnormalities recorded in 1020 cytogenetically confirmed cases of Down syndrome are

presented in table 1. There were 855 cases with free trisomy 21 (83.82%), 110 cases showing mosaicism (10.78%) and 51 cases with translocation (5%). Four cases were non-classical forms of Down syndrome. Eighty-two (7.4%) children possessed a normal chromosomal constitution. An excess of males was observed among Down syndrome patients (1.41:1). The sex ratio was even higher (1.91) in case of mosaic individuals. However, the sex ratio was skewed in favour of females among Robertsonian translocation cases (Table 1). The origin of the derivative chromosome could be determined in 29 patients and it was inherited in 12 of them (41.4%) (Table 2). The most frequent translocation was t(21;21) followed by t(14;21). Robertsonian translocations der(13;21)(q10;q10) and der(21;22)(q10;q10) recorded in this study are depicted in Figure 1A and 2A respectively. A paternally inherited pericentric inversion involving the heterochromatic region on chromosome 9 was also seen in the latter. The karyograms of the carrier mother and father are shown in Figure 1B and 2B respectively.

The clinical characteristics of the four children who had non-classical karyotype abnor-

malities are briefly described. The first proband, a 4-month-old male infant exhibited double aneuploidy, 48,XXY,+21. He showed open fontanel, microcephaly, flat occiput, slanting palpebral fissures, hypertelorism, low set and malformed ears, thick furrowed protruding tongue, open mouth, hypotonia, short broad hands, clinodactyly, sandal gap and plantar furrow (Cyril et al. 2005). The second case, a 10-month-old male, had the karyotype mos47,XY,der(13;21)(q10;q10),+21/46,XY,der(13;21),+21. The child presented with open fontanel, brachycephaly, slanting palpebral fissures, epicanthal folds, low set ears, flat nasal root, open mouth, short broad hands, simian crease on the left hand, clinodactyly, hypotonia, sandal gap, plantar furrow and delayed developmental milestones. Both his father and paternal grandfather were carriers for the same translocation. At the age of 2¼ years, he developed acute myeloid leukemia and died (Cyril et al. 2006).

The third case, a one-year and eight-month-old male child, was referred for chromosomal analysis with Down syndrome and severe Ebstein's anomaly. This report of Ebstein's

Table 1: Cytogenetic profile of 1020 referral cases of Down syndrome

Karyotype	n	%	Sex ratio (M:F)
Free trisomy 21	855	83.82	1.39:1
Robertsonian translocation	51	5	0.86:1 (0.93:1)*
Mosaicism	110	10.78	1.9:1
Others	4	0.39	3:1
48,XXY,+21 ¹	1		
47,XY,der(13;21)(q10;q10),+21/ 46,XY,der(13;21),+21 ²	1		
46,XY,der(21;21)(q22;q11.2) ³	1		
47,XX,t(2;18)(q31;q23),+21 ⁴	1		
Total	1020	100	1.41:1

* including the case showing mosaicism for Y chromosome

¹Cyril et al. (2005); ²Cyril et al. (2006); ³Cyril et al. (2007a); ⁴Cyril et al. (2007b)

Table 2: Parental origin of the derivative chromosome in cases with Robertsonian translocation

Type of translocation	Parental origin				Total
	Maternal	Paternal	De novo	Unknown	
13;21*	2	1*	-	-	3
14;21	2	1	8	11	22
21;21	3†	2†	9	11	25
21;22	-	1	-	1	2
Total	7	5	17	23	52

* including the case showing mosaicism for Y chromosome

† two children were sibs

anomaly in a Down individual carrying a 21;21 tandem translocation, der(21;21)(q22;q11.2), is the first one of its kind (Cyril et al. 2007a). The fourth proposita was a 4-year-old girl who was the first born of consanguineous parents. She showed moderate mental retardation (IQ=60), generalized hypotonia, microcephaly, brachycephaly, low set ears, open anterior fontanel, obliquely upward-slanting palpebral fissures, epicanthal folds in both eyes, depressed nasal root, microstomia with relative macroglossia, clinodactyly, transitional palmar crease in left hand, small umbilical hernia, and genu recurvatum. She was of proportionately short stature and had hyperextensible joints in both lower limbs. Both knees exhibited anteroposterior and lateral instability that was corrected using calipers. She exhibited a *de novo* reciprocal translocation t(2;18) in addition to trisomy 21 (Cyril et al. 2007b).

The majority of the Down syndrome children belonged to the age group of one month to one year. The mean age at referral did not differ for the different categories of karyotypic abnormalities. A small number of patients were referred from neonatal ward while the remaining were referred for delayed development and speech defect.

The mean maternal age in the Robertsonian translocation group (22.83 ± 3.89) and in mosaic individuals (23.1 ± 5.60) was significantly lower than in free trisomy group (25.08 ± 4.77 ; $P < 0.05$) (Table 3). The birth order varied from 1 to 11 but most of the patients were first born. The mean paternal age in mosaic Down individuals (26 ± 6.79) was also significantly lower compared to free trisomics (31.09 ± 5.44 ; $P < 0.05$).

The clinical features observed in various types of Down syndrome are summarized in table

Table 3: Mean referral age and parental ages seen in different categories of Down syndrome

	Age (Mean \pm SD)			
	Trisomy 21	Translocation	Mosaic	Others
Down	2.28 \pm 3.43	2.1 \pm 1.86	1.56 \pm 1.53	1.75 \pm 1.40
Maternal	25.08 \pm 4.77	22.83 \pm 3.89	23.1 \pm 5.60	25.25 \pm 2.63
Paternal	31.09 \pm 5.44	30.44 \pm 3.96	26 \pm 6.79	33.75 \pm 4.19

Table 4: Clinical features observed in Down syndrome children

Clinical features	Trisomy 21(n=855)	Translocation (n=51)	Mosaic (n=110)
Brachycephaly	388 (45.4)	6	4
Flat occiput	363 (42.5)	10	3
Microcephaly	72	5	1
Flat facial features	425 (49.7)	16	82 (74.5)
Depressed nasal bridge	684 (80.0)	37 (72.5)	49 (44.5)
Slanting palpebral fissures	722 (84.4)	35 (68.6)	94 (85.5)
Epicanthal folds	403 (47.1)	24	37
Hypertelorism	151	1	1
Low set ears	391 (45.7)	16	9
Open small mouth	410 (48.0)	42 (82.4)	34
Protruding tongue	248	16	24
Short neck	350 (40.9)	7	33
Congenital heart defect	215	14	6
Short broad hands	487 (57.0)	19	24
Clinodactyly	384 (44.9)	15	22
Hypotonia	662 (77.4)	14	13
Sandal gap	426 (49.8)	22 (43.1)	18
Simian crease	221	14	4
Open fontanel	116	9	2
Plantar furrow	138	12	1
High arched palate	55	4	1
Brushfield spots	4	1	2
Furrowed tongue	65	0	0
Delayed development	419 (49.0)	0	0
Small penis	5	0	1

Figures in parentheses indicate percentages.

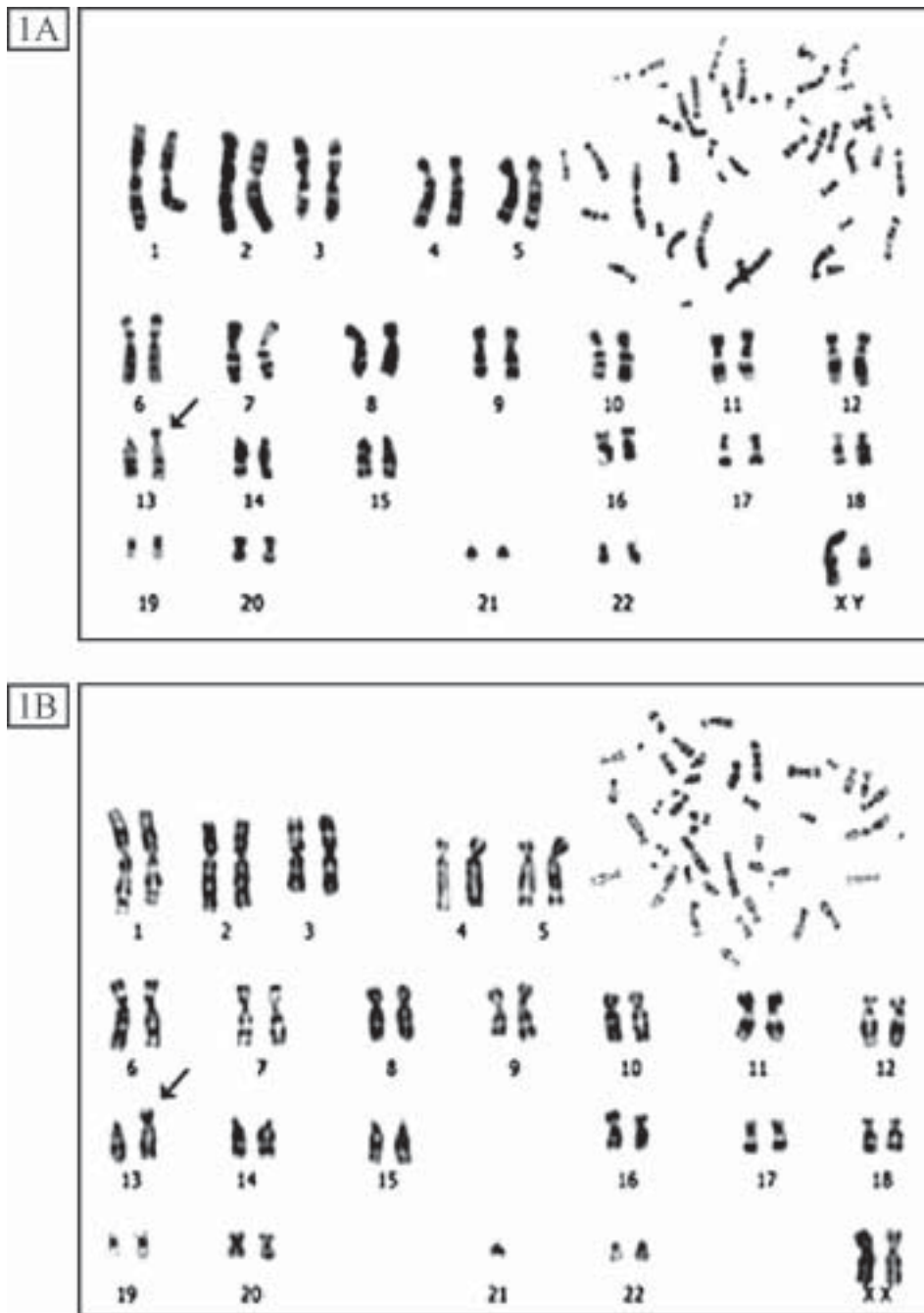


Fig. 1A – GTG-banded karyogram of a male baby with translocation Down syndrome: 46,XY,der(13;21)(q10;q10),+21. Insert shows GTG-banded metaphase.

Fig. 1B – GTG-banded karyogram of carrier mother: 45,XX,der(13;21)(q10;q10). Insert shows GTG-banded metaphase.




Fig. 2A – GTG-banded karyogram of a female baby with translocation Down syndrome and inversion 9: 46,XX,der(21;22)(q10;q10),inv(9qh),+21. Inserts show the GTG-banded metaphase; inv(9) and normal 9 chromosomes from another metaphase.

Fig. 2B – GTG-banded karyogram of carrier father showing 45,XY,der(21;22)(q10;q10),inv(9qh). Insert shows GTG-banded metaphase.

4. Brachycephaly, flat occiput, epicanthal folds, upward-slanting palpebral fissures, low set ears, depressed nasal bridge, open mouth, short neck, short broad hands, clinodactyly, sandal gap, hypotonia and delayed development were observed in more than 40 percent of the free trisomy cases. Mosaic cases showed milder phenotypes (in terms of the number of characteristic features) in comparison to free trisomy.

DISCUSSION

A variety of abnormal karyotypes such as free trisomy 21, Robertsonian translocations, isochromosome 21q, mosaicism, partial trisomy 21, double trisomies and very rarely tandem translocations have been observed in Down syndrome. A review of over 5000 cases of Down syndrome from laboratories in England and Wales between 1989 and 1993 revealed that 95 percent had an extra chromosome 21 resulting from a nondisjunctional error during gametogenesis. Less than 1% showed somatic mosaicism while the rest carried translocations involving chromosome 21 (Mutton et al. 1996). Similar frequencies were also documented in other reports (Christianson 1996; Mokhtar et al. 2003; Azman et al. 2007).

An observation of free trisomy in 83.82%, Robertsonian translocations in 5% and mosaicism in 10.78% of cases in the present study on 1020 cases, was in accordance with earlier reports from India (Krishnamurthy et al. 1981; Verma et al. 1991; Thomas et al. 1992; Jyothy et al. 2000; Kothare et al. 2002; Kava et al. 2004; Sheth et al. 2007). Four individuals revealed non-classical karyotypes. Free trisomy 21 associated with structural and/or numerical anomalies of other chromosomes have been reported by Verma et al. (1991), Mutton et al. (1996), Mokhtar et al. (2003) and Sheth et al. (2007).

Although a vast amount of information is available on several aspects of Down syndrome, a complete understanding of the underlying mechanism(s) is yet to be ascertained. The mean maternal age is raised in free trisomy 21, but not in translocations (Mutton et al. 1996), and this was evident in the present study. An excess of males in all the cytogenetic subgroups of Down syndrome except Robertsonian translocations was also in agreement with previous findings. An almost double the number of Down syndrome males showed mosaicism. A similar finding was observed by Thomas et al. (1992) and Jyothy

et al. (2000). In contrast, Mokhtar et al. (2003) reported a skewed male: female ratio of 0.67 among the mosaics.

Down syndrome is characterized by a constellation of physical features and systemic malformations. A recent report on the clinical data on Down syndrome from India noted Mongoloid slant, ear abnormalities, epicanthic folds, flat facies, and hypotonia in >50% of cases (Kava et al. 2004). These features were also recorded in the present study. However, there existed a wide variation in clinical manifestation among individuals, in particular neonates. Cytogenetic investigations were very essential for confirmation of the clinical diagnosis. A parental study further aided in the determination of the recurrence risk and to counsel regarding available options.

ACKNOWLEDGEMENT

The authors are grateful to University Grants Commission, New Delhi and University of Madras for the financial support.

REFERENCES

- Azman BZ, Ankathil R, Siti Mariam I, Suhaida MA, Norhashimah M, Tarmizi AB, Nor Atifah MA, Kannan TP, Zilfalil BA 2007. Cytogenetic and clinical profile of Down syndrome in Northeast Malaysia. *Singapore Med J*, 48: 550-554
- Christianson AL 1996. Down Syndrome in Sub-Saharan Africa. *J Med Genet*, 33: 89-92.
- Cyril C, Chandra N, Jegatheesan T, Chandralekha K, Ramesh A, Gopinath PM, Marimuthu KM 2005. Down syndrome child with 48,XXY,+21 karyotype. *Ind J Hum Genet*, 11: 47 – 48.
- Cyril C, Teena K, Solomon FD Paul, Chandra N, Meena J, Anuradha D, Ramesh A, Gopinath PM, Marimuthu KM 2006. Familial Robertsonian translocation 13;21 in a Down syndrome patient with XYY/XY mosaicism. *Int J Hum Genet*, 6: 291-295.
- Cyril C, Emmanuel C, Cherian KM, Kulkarni S, Chandra N 2007a. Down syndrome with tandem 21;21 rearrangement and Ebstein's anomaly — A case report. *Int J Cardiol*, 115: e58–e60.
- Cyril Cyrus, Kaur Harpreet, Teena Koshy, Jegatheesan Thankanadar, Chandra Nallathambi 2007b. A *de novo* reciprocal t(2;18) translocation with regular trisomy 21. *Genetic Testing*, 11: 459-462
- Jyothy A, Kumar KS, Rao GN, Rao VB, Swarna M, Devi BU, Sujatha M, Kumari CK, Reddy PP 2000. Cytogenetic studies of 1001 Down syndrome cases from Andhra Pradesh, India. *Ind J Med Res*, 111: 133-137.
- Kava MP, Tullu MS, Muranjan MN, Girisha KM 2004. Down syndrome: Clinical profile from India. *Archives Med Res*, 35: 31–35.

- Kothare S, Shetty N, Dave U 2002. Maternal Age and Chromosomal Profile in 160 Down Syndrome Cases – Experience of a Tertiary Genetic Centre from India. *Int J Hum Genet*, 2: 49-53.
- Krishna Murthy DS, Patel ZM, Khanna SA, Danthi V, Amtani LM 1981. Frequency of trisomy 21, translocation, mosaicism and familial cases of Down's syndrome in Bombay. *Ind J Med Res*, 73: 218-222.
- Malini SS, Ramachandra NB 2006. Influence of advanced age of maternal grandmothers on Down syndrome. *BMC Med Genet*, 147: 4.
- Mokhtar MM, Abd el-Aziz AM, Nazmy NA, Mahrous HS 2003. Cytogenetic profile of Down syndrome in Alexandria, Egypt. *East Mediterr Health J*, 9: 37-44.
- Mutton D, Alberman E, Hook EB 1996. Cytogenetic and epidemiological findings in Down syndrome, England and Wales 1989 to 1993. National Down syndrome Cytogenetic Register and the Association of Clinical Cytogeneticists. *J Med Genet*, 33: 387-394.
- Nussbaum RL, McInnes RR, Willard HF 2001. *Thompson and Thompson Genetics in Medicine*. Philadelphia: WB Saunders Company.
- Rajangam S, Thomas IM 1992. Down syndrome and birth order. *Man in India*, 72: 239-242.
- Sheth F, Rao S, Desai M, Vin J, Sheth J 2007. Cytogenetic Analysis of Down syndrome in Gujarat. *Ind Pediatr*, 44: 774-777.
- Thomas IM, Rajangam S, Hegde S 1992. Cytogenetic investigations in Down syndrome patients and their parents. *Ind J Med Res*, 96: 366-371.
- Verma IC 2000. Burden of genetic disorders in India. *Ind J Pediatr*, 67: 893-898.
- Verma IC, Mathew S, Elango R, Shukla A 1991. Cytogenetic studies in Down syndrome. *Ind Pediatr*, 28: 991-996.