Edinburgh Medical Journal

May 1929

OBSERVATIONS ON THE PATHOLOGY OF INFLUENZAL PNEUMONIA.

By D. M. LYON and W. A. ALEXANDER.

(*From the Clinical Medicine Laboratory, Royal Infirmary, Edinburgh.*)

BETWEEN 22nd October and 21st December 1918, during the second great wave of the pandemic, 100 fatal cases of influenzal pneumonia were examined at a Base Hospital in France. The subjects for the most part were British soldiers representing all arms of the service; a few Americans and Germans were included. The majority of the victims had been quite healthy prior to the onset of the influenza, but a few belonged to the lower categories. Evidence of pre-existing disease was found in a small proportion of cases (4 valvular disease of heart, 3 cirrhosis of liver, 1 nephritis). No active tuberculosis of the lungs was observed. Subsequent microscopic examination revealed a degree of antecedent bronchial or pulmonary damage in at least 7 instances.

In 10 cases the date of the onset of symptoms could not be ascertained. In the remaining 90 cases, the duration of the illness was 10 days or under in 55 per cent. The days on which death occurred were:—5th day or under (3), 6th day (4), 7th (9), 8th (13), 9th (14), 10th (7), 11th (7), 12th (4), 13th (7), 14th (4), 15th (4), 16th to 20th (11), 29th, 30th, 41st (each 1).

The general nutrition was, on the whole, of a high order, but recent wasting as a result of the fever was common.

The bodies presented an unusual degree of lividity affecting the upper as well as the more dependent parts. Jaundice of the face and eyes or of the body generally was noted on 10 occasions. Despite the great tendency to hæmorrhage in the

internal lesions, it was never seen on the surface of the body. Œdema of the subcutaneous tissues was not observed in any of the cases.

Lungs and Pleuræ.

Naked-Eye Appearances—*Pleural Sacs.*—There was some involvement of the pleura in the great majority of cases. In 9, the cavities were obliterated by old adhesions or recent organisation. In 42, both sacs were dry, although frequently the lung surfaces showed a fibrinous deposit. In the remainder (49), fluid was present in greater or less amount. In 2 cases it was purulent and in small pockets; in 5, turbid; and in 42, pale yellow and clear. Often it was coagulated into a clear gelatinous mass, from which a more fluid portion could sometimes be squeezed. Hæmorrhage on the surface of the lungs was extremely common. Sometimes it was scanty, consisting of a few petechial spots only (37 cases), but mostly the blood extravasation under the pleura was a very striking feature. The accompanying table gives an analysis of the findings.

Pleural Sacs.

	R.	L.
Cavity obliterated by old or recent adhesions	9	9
Lung surface dry but "matt"	20	16
" showing definite deposit (with or without fluid)	72	51
Free fluid under 5 oz.	20	22
" from 5 to 10 oz.	7	3
" over 10 oz.	11	7
Fluid cloudy	5	0
" purulent	1	1
Punctate subpleural hæmorrhages	32	31
Larger " "	39	35

Lungs.—In virtually every case in the series both lungs were affected, though as a rule the incidence of the pneumonia and other changes was unequal on the two sides.

The great variability in the appearances presented was remarkable. Not only was there a marked disparity between individual cases, but there was often a striking variation in different parts of the lungs in the same case. This diversity of appearance makes a general account of the changes difficult, but it is possible to divide the series into five main groups. It will be understood, however, that the figures presented are only

approximate, and that there was the greatest tendency towards the production of mixed or intermediate types. These groups and the numbers in each are:—

A. A group in which *œdema* was the predominant feature: 39 cases.

B. A group in which *hæmorrhage* was so extensive as to dominate the picture: 16 cases.

C. Cases of typical *broncho-pneumonia*, discrete or confluent: 32 cases.

D. A group in which *confluent "lobular"* consolidation had occurred: 9 cases.

E. A group in which typical *lobar* pneumonia was present in one or more lobes: 4 cases. It should be pointed out that the figure for this group gives a false impression of the frequency of an appearance approximating to that of lobar pneumonia, for several of the cases in Group *A* closely resembled that type.

These main classes demand further analysis and description.

A. This, the œdematous, group (39 cases) could be divided into three sub-groups. (*a*) In 3 cases, in which there had been a short illness of from 2 to 5 days, the lungs were intensely congested and waterlogged, but there was no consolidation. (*b*) In 12 instances there was a degree of more or less diffuse consolidation in addition to the congestion and œdema. The organs had a fairly soft elastic feel; on section, though quantities of frothy fluid escaped, there was not the same collapse as in the first sub-group; it was difficult to break the tissues with the finger, and they could hardly be described as friable. This curious fleshy consistence has been referred to as splenisation, gelatinisation, or inflammatory carnification. The change might be confined to the lower lobes, but tended to creep upwards until only the apices and anterior borders remained aerated. Sufferers from this type of pneumonia must have died from suffocation. (*c*) In the other 24 cases, the pneumonic element was more conspicuous though there was still a background of œdema. Parts of the lungs were more solid, more friable, and perhaps paler in colour than the remainder; sometimes such a definitely pneumonic area was lobar in extent.

In the more acute cases in this large group *A*, the patients brought up great quantities of frothy blood-stained fluid prior to death, and post-mortem the air-passages were filled with it.

B. Hæmorrhage of greater or less degree was almost constant in the series, but in 16 instances it was so massive as to justify a label of hæmorrhagic pneumonia. The affected areas were indurated, friable, and of a dark red colour. Elsewhere there might be œdema or pneumonia, but these were overshadowed by the hæmorrhage.

The presence during life of fresh blood in the sputum was commonly observed.

C. The broncho-pneumonia group (32 cases) could also be sub-divided. (*a*) In 3 instances, the principal lesion was an intense inflammation of the smaller bronchi, with some pulmonary congestion and œdema but little in the shape of pneumonia. All three of these patients had been ill for some time—11, 20, and 41 days respectively—and in each case more severe symptoms had developed on the day before death. The appearances suggested a fresh infection or exacerbation of the earlier infection, occurring in subjects who were in process of slow recovery but were debilitated as the result of prolonged fever. (*b*) Thirteen cases showed discrete broncho-pneumonia, the patches usually occurring in clusters. The relation of the consolidated areas to bronchi was not in doubt. Sometimes they were of much the same colour as the surrounding tissue and were more palpable than visible; more often they were grey or yellowish, with fairly well-defined margins. (*c*) There were 16 examples of confluent broncho-pneumonia. While in certain of these the consolidation was massive and there was some question as to its correct designation, the prominence of the bronchitis, the uneven character of the pneumonia, and the relation of the more solid portions to the inflamed bronchi indicated its essentially broncho-pneumonic nature. The occurrence in some cases of what amounted to bronchial abscesses will be referred to later.

The expectoration of a copious purulent sputum was a prominent feature in many cases of the series, especially in this group.

D. In 9 cases, the appearances were such as to justify separate consideration. On section, consolidated portions of the lungs were divided, often by visibly thickened septa, into polygonal areas of some size. These might vary appreciably in colour, the whole picture suggesting the arrangement of counties on a map. Where they abutted on less solid lung the margins were sharply outlined. Anatomically, such polygonal

areas might be supposed to correspond to the portions of lung connected with medium-sized bronchi. While the type has been referred to as confluent lobular pneumonia, the term "lobular" in this connection is open to objection, because the usual anatomical lobule is the unit of lung tissue related to a terminal bronchiole, and the consolidated blocks of lung in the group under consideration obviously represent many such lobules.

E. This group does not call for further comment at this point. That pneumonia occurring as a complication of influenza should occasionally be of the lobar type is not surprising, in view of the fact that the pneumococcus is known to play a considerable part in producing the respiratory sequelæ of influenza.

Bronchi.—The frequency and degree of bronchitis in the series were very striking. While the definite broncho-pneumonia cases constituted only 32 per cent. of the whole, obvious bronchitis was present in a considerably higher proportion. In the œdematous and hæmorrhagic cases the content of the bronchi consisted largely of frothy fluid and blood, but often it was muco-purulent or frankly purulent. There were 28 instances in which its marked purulent character was specially noted. A definite ulcerative type of bronchitis, affecting the bronchial tree as a whole, was observed on 5 occasions, while in 23 cases there were recognisable erosion and bronchiectatic dilatation of the smaller branches, In some of these, the purulent capillary bronchitis was so extreme as to have resulted in bronchial abscesses.

Bronchial Glands.—The tracheo-bronchial and root glands were commonly large and soft. Unusually great enlargement was noted 33 times. Hæmorrhages into the glands were infrequent.

Microscopic Appearances.—Sections of the lungs from most of the 100 cases—in many, of more than one lobe—have been available. The opportunity of examining microscopically such a large consecutive series from undoubted cases of influenza in adults in the prime of life is one that is unlikely to be readily repeated. The examination of this material serves to confirm the points upon which stress has been laid in the section dealing with the morbid anatomy.

The *lack of uniformity* in the pathological picture is bewildering; as has been indicated, this applies not only to

the lungs in different cases, but often also to the different lobes in the same case.

The *intensity* of the inflammatory process in the majority of cases is also remarkable. Amongst evidences of this severity, œdema and hæmorrhage are pre-eminent.

The *œdema* is often overwhelming in degree. It shows typically as a homogeneous acidophil coagulum, varying somewhat in density in individual cases and containing embedded within it a varying number of inflammatory cells and red blood corpuscles. For the solid appearance of this coagulum fixation is partly responsible. It is characteristically riddled with clean-cut circular holes indicative of the bubbling of air through water-logged lung. The question arises as to the relative importance of terminal passive transudation and active inflammatory exudation in the production of this œdema in the substance of the lungs, as well as of the accumulations of serous fluid in the pleural sacs. Without elaborating the point, however, it may be stated that there is ample justification, clinical and pathological, for regarding the œdema in these cases as essentially part of an intense acute inflammatory reaction.

The necessity of looking upon *hæmorrhage* as one of the salient features of influenzal pneumonia receives further support from histological study. Hæmorrhage of appreciable degree in the sections is the rule rather than the exception. In the more extreme cases, the picture in certain fields resembles that of recent pulmonary infarction. Altered blood in the form of hæmosiderin pigment is commonly seen in phagocytic cells in the alveoli, a relic of smaller hæmorrhages at an earlier stage of the disease.

If proof were needed of the relationship between œdema and hæmorrhage and the seat of active inflammation, it is forthcoming in some of the lungs showing the discrete form of broncho-pneumonia, in which these two features are practically confined to the neighbourhood of the pneumonic patches. Œdema and hæmorrhage are of course often found in association, but either may be present in extreme degree with a minimum of the other.

The almost constant occurrence of *pathological changes in bronchi* becomes very obvious on microscopic examination. In œdematous and hæmorrhagic cases, the air-passages may be obscured and difficult of definition, but otherwise the smaller

bronchi usually stand out in the sections by reason of their cellular contents and inflamed walls. Even in cases of lobar type in this series, there is an element of bronchitis and a bronchial exudate of unusual cellularity. In ordinary lobar pneumonia the bronchi are not so conspicuous, for they are not themselves inflamed and serve merely as channels of escape for alveolar exudate.

In the majority of the cases, the bronchitis that is present is severe, and the exudate purulent in character. In not a few, it is extreme and of an ulcerative type. The disorganisation of the walls that results is emphasised in sections stained for elastic tissue. The most advanced cases show a spreading suppuration following the course of the bronchi. Ulceration and distension by purulent exudate account for the acute bronchiectasis or bronchiolectasis which is so comparatively frequent.

The *pneumonia*, which in some form and in some degree is common to all cases, remains to be considered, but a complete presentation of the complex histological features is not practicable. Moreover, it would entail the repetition of much that has already been stated or implied. Obviously, œdema and hæmorrhage contribute to the consolidation in certain cases, but there is always an underlying pneumonic process.

As already pointed out, one of the chief general impressions that is left after the examination of the histological material is that of sharpness of reaction and rapidity of alveolar exudation. This holds good even for the broncho-pneumonic type of case, and rapid out-pouring of inflammatory products into the alveoli is not ordinarily a characteristic of this type. It is true that typical cases of broncho-pneumonia occur, in which the picture differs in no essential from that seen in fatal cases in young children, but what may be termed the deliberate form of broncho-pneumonia, with very obvious extension by a process of acute interstitial inflammation, is not very frequent.

In the group *D*, in which on naked-eye examination areas of consolidation of some size, often confluent and outlined by interlobular septa, are present, the alveolar exudate is usually recent and the fairly uniform character of the pneumonia more suggestive of the lobar type than of broncho-pneumonia. Occasionally, isolated patches of this nature are found. It is the rule for definite bronchitis to be evident. Cases of this kind are commonly included under the heading of broncho-

pneumonia, but this is not altogether satisfactory. The chief reason for their being given this label seems to be the extent rather than the character of the consolidation. They can be regarded as a class intermediate between lobar and broncho-pneumonia, and more nearly related to the former than the latter type.

The emphasis laid on bronchial inflammation and rapidity and extent of alveolar exudation as characteristics of the pulmonary lesions in general will have made it clear that difficulty in classifying the pneumonia is not confined to the group just mentioned. The problem becomes perhaps more acute on microscopic examination of small sections. The statement commonly made, that the type of pneumonia that is so liable to develop in influenza is broncho-pneumonia, is allowable only if the special features which have been stressed are taken into consideration.

As regards histological detail, a network of fibrin in the alveolar exudate is quite common in the patchy as well as the more diffuse and uniform cases. The polymorph is naturally the characteristic cell of the exudate, but mononuclear or "catarrhal" cells are frequently met with, especially early or very late in the pneumonic process. There were two circumstances which determined a prominence of these cells in certain fields, viz., the occurrence of hæmorrhages sufficiently long before death to allow of phagocytosis of the red cells and the elaboration of hæmosiderin, and secondly, the presence of carbon pigment derived from the smoke-laden atmosphere to which many of the patients were exposed. In some of the fulminating œdematous cases, a tendency to necrosis is obvious. There are parts of the sections in which the nuclear staining is poor and the walls of the alveoli and terminal air-passages hyaline and structureless. More definite necrosis is present in only two sections. In one, a sort of septic infarction is seen, with numbers of organisms in the perivascular lymphatics. Local thrombosis as a result of infection of vessel walls from without can be held responsible for the production of these more extensive necrotic areas. Local vesicular emphysema is common.

Other Organs.

Heart and Pericardium.—The pericardial sac contained a slight excess of fluid in more than half of the cases. In 4, there was an early pericarditis and the fluid was cloudy.

The heart was usually enlarged. This was due in 82 instances to dilatation, associated as a rule with pallor or mottling and a flabby condition of the myocardium. There were no hæmorrhages of any size. Recognisable hypertrophy was present in 21 cases resulting presumably from the severe physical strain of war service, and valvular defects in 4 (3 aortic and 1 combined aortic and mitral).

The aorta frequently showed extensive superficial fatty streaks of recent toxic origin. Older lesions of the aorta were conspicuously absent.

Liver and Kidneys.—In both of these organs toxic changes were almost constant. In the case of the liver, they were particularly striking and had reached the stage of advanced fatty degeneration or infiltration in 44 cases. In the kidneys, obvious fatty change was not so frequent (12 cases), but well-marked cloudy swelling was the rule. Sometimes the renal cortex was so soft that the capsule could not be detached without bringing with it portions of kidney substance. Incidental findings in these organs included one example of well-developed hepatic cirrhosis and one of granular contracted kidneys. In addition, there were 2 instances of earlier cirrhosis of the liver and 6 cases in which the kidney cortex was narrow.

Spleen.—The size of the spleen showed great variation. Definite enlargement was present in only a third of the bodies, but sometimes it was considerable. A pale or pale pink colour and an unduly soft consistence were recorded in 33 and 16 cases respectively. The proportion in which there was macroscopic evidence of reaction was therefore surprisingly small.

Rectus and other abdominal muscles.—Hæmorrhages into these muscles, occasionally extensive, were observed in 20 of the subjects. On microscopic examination, Zenker's degeneration of the muscle fibres in the neighbourhood of the extravasated blood was an interesting and prominent feature.

Bacteriology.

The autopsies were carried out as early as possible after death. Material for bacteriological examination was taken in all cases from the lungs (often from several parts), from the contents of the bronchi, and from the heart blood. In a few instances the pleural fluid was investigated as well. Cultures were made on blood-smeared agar and direct films were also examined.

In most cases, the growth obtained was very mixed, though the relative proportions of the different organisms varied greatly. No attempt was made to identify all the organisms, but the presence of *B. Influenzæ* (Pfeiffer) was specially noted. This organism was found in one or other of the samples in all the cases except two, and was often in almost pure culture. It was recovered with about equal frequency from the lung and from the bronchial secretion, but only rarely from the heart blood (9 times).

Discussion.

In studying this series of cases of influenzal pneumonia, it must be remembered that the subjects represent a selected group of the community, men of military age on active service. As might be expected, the great majority seem to have been in perfect health prior to the onset of the influenza. Pre-existing disease either of the respiratory tract or of other systems did not appear to play any appreciable part in predisposing to a fatal issue.

Clinically, the disease was characterised by an intense toxæmia, with local manifestations in the respiratory system. Cough was distressing and yielded large quantities of sputum. Dyspnœa and a peculiar generalised cyanosis were marked features, especially towards the end of life.

Post-mortem investigation confirmed the clinical observation that the main pathological lesions were in the respiratory organs, though practically all the tissues of the body bore evidences of intoxication. Pathological study also indicated that infection took place by way of the air-passages. The points in the morbid anatomy upon which stress has been laid are—the diversity of appearance in the lungs, the difficulty of classifying the pneumonia, the frequency and often extreme degree of hæmorrhage and œdema, and the prominence of bronchitis. It seems highly probably that, in patients debilitated by influenza, the type of invading organism that gains the ascendancy in the susceptible respiratory tracts accounts for the very diverse appearances presented. The bronchial changes, ranging from congestion to extensive erosion and dilatation, are of great interest, and it is easy to understand, provided the more severe type of bronchial lesion is compatible with life, how permanent structural alterations in the lungs may result from influenza.

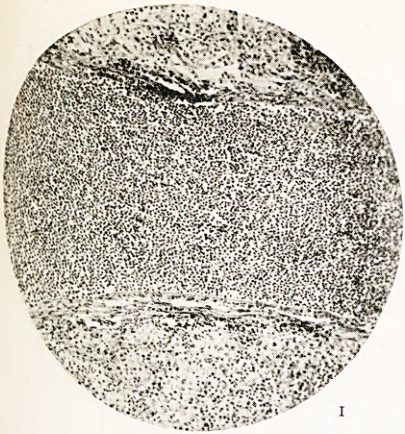

1

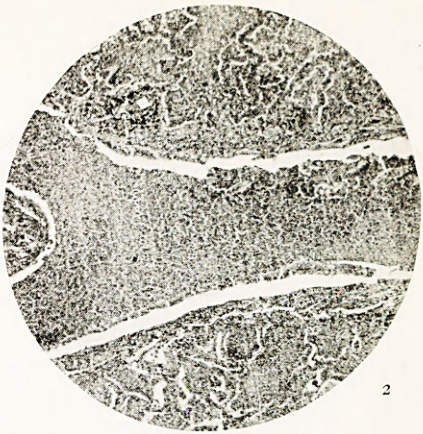

2

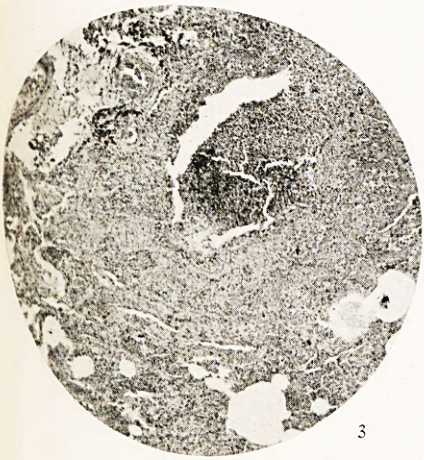

3

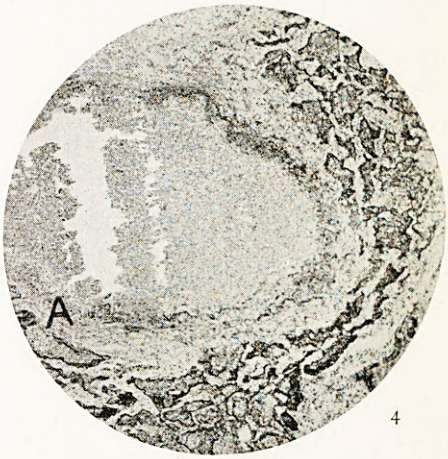

4

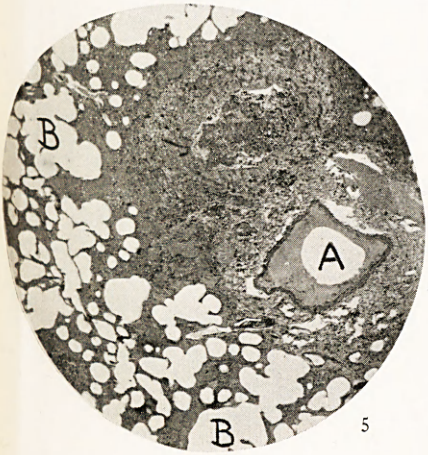

5

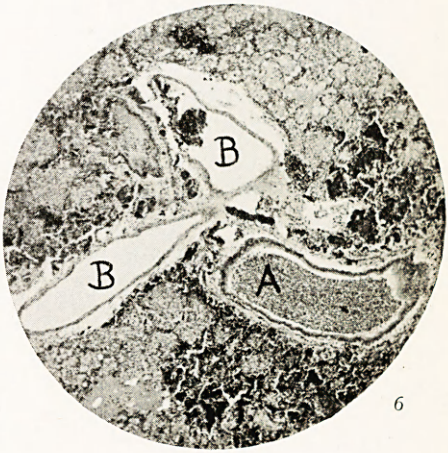

6

PLATE II

7

8

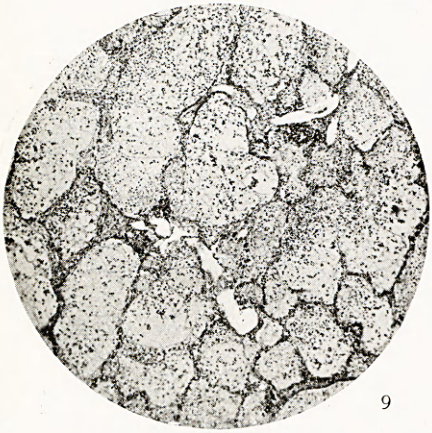

9

10

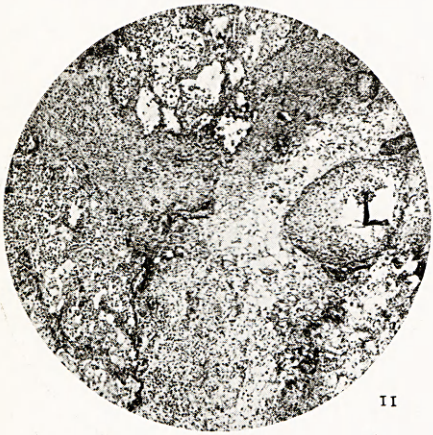

11

12

Pathology of Influenzal Pneumonia

DESCRIPTION OF PLATES.

Plate I.

1. Bronchiole distended with pus. The pneumonia in this case was diffuse and not of broncho-pneumonic type.
2. Dilated and eroded bronchiole at bifurcation, with purulent content. Alveolar exudate also very cellular. The consolidation in this case was very extensive, though not so uniform as in typical lobar pneumonia.
3. Bronchiole showing great thickening of wall from acute interstitial inflammation, with loss of lining and content of pus. Extension of inflammation outwards along alveolar walls. There was typical discrete broncho-pneumonia in this case.
4. Bronchiole stained with Weigert's elastic tissue stain. The destruction of the wall, that occurs in the destructive type of bronchitis so common in influenza, is emphasised. The stain has also been taken up by the fibrin network in the adjacent alveoli. The consolidation here was due to a confluent broncho-pneumonia and the section demonstrates that a "croupous" type of exudate is not confined to cases of lobar or so-called "croupous" pneumonia. A = portion of wall in which elastic tissue has disappeared.
5. A typical patch of broncho-pneumonia, showing an œdematous type of exudate. A bronchiole, with its wall inflamed, its lining desquamated, and its lumen plugged with inflammatory products, is seen towards 1 o'clock. Below there is an arteriole (A). The clear spaces (B) represent bubbles of air in the œdematous coagulum.
6. A patch of broncho-pneumonia, showing a hæmorrhagic type of exudate. The dark material is the extravasated blood. The picture is not so typical of broncho-pneumonia as in the preceding three photographs. The small bronchus is filled with pus, but its lining is intact and the substance of its walls not particularly inflamed. Nevertheless, throughout the section the hæmorrhage and the pneumonia were found particularly in relation to bronchi. A = bronchus, B = blood-vessel.

Plate II.

7. An area of lung, which illustrates the complexity of the pathological picture so characteristic of influenzal pneumonia. An interlobar fissure, containing some recent fibrinous exudate, runs obliquely across the field. On the left, a diffuse pneumonia of lobar type; on the right, a patchy hæmorrhagic consolidation of broncho-pneumonic type.
8. A very common appearance in influenzal pneumonia. The exudate is fresh and has obviously been rapidly poured out. Œdema is a prominent feature. There is a large well of œdematous fluid (coagulated by the fixative) in an alveolar passage.
9. A pneumonia of lobar type and of recent development. The alveoli are distended by a loose coagulum in which inflammatory cells are relatively scanty.
10. A typical example of lobar or croupous pneumonia.
11. An area of lung from one of the cases classed as confluent "lobular" pneumonia (group *D*). The field is largely occupied by a branching septum which is broadened as a result of inflammatory exudation into its substance. In the septum is a dilated lymphatic (L) containing a fibrinous coagulum. The picture in this case resembled lobar pneumonia rather than broncho-pneumonia.
12. A section to illustrate the presence in "catarrhal" cells of two varieties of pigment. Below and to the right, there are hæmosiderin-laden phagocytes (A); above and to the left, carbon-laden cells (B).