



# Femoroacetabular impingement and the cam-effect

## A MRI-BASED QUANTITATIVE ANATOMICAL STUDY OF THE FEMORAL HEAD-NECK OFFSET

K. Ito, M.-A. Minka-II, M. Leunig, S. Werlen, R. Ganz

*From the AO ASIF Research Institute, Davos Platz, Switzerland*

**We** have observed damage to the labrum as a result of repetitive acetabular impingement in non-dysplastic hips, in which the femoral neck appears to abut against the acetabular labrum and a non-spherical femoral head to press against the labrum and adjacent cartilage. In both mechanisms anatomical variations of the proximal femur may be a factor. We have measured the orientation of the femoral neck and the offset of the head at various circumferential positions, using MRI data from volunteers with no osteoarthritic changes on standard radiographs. Compared with the control subjects, paired for gender and age, patients showed a significant reduction in mean femoral anteversion and mean head-neck offset on the anterior aspect of the neck. This was consistent with the site of symptomatic impingement in flexion and internal rotation, and with lesions of the adjacent rim. Furthermore, when stratified for gender and age, and compared with the control group, the mean femoral head-neck offset was significantly reduced in the lateral-to-anterior aspect of the neck for young men, and in the anterolateral-to-anterior aspect of the neck for older women. For patients suspected of having impingement of the rim, anatomical variations in the proximal femur should be considered as a possible cause.

*J Bone Joint Surg [Br] 2001;83-B:171-6.*

*Received 23 February 2000; Accepted after revision 5 July 2000*

K. Ito, MD, DSc, Group Head, Cartilage Biomechanics  
AO ASIF Research Institute, Clavadelerstrasse, CH-7270 Davos Platz,  
Switzerland.

M.-A. Minka-II, Resident, Orthopaedic Surgery

M. Leunig, MD, Attending

R. Ganz, MD, Chief

Department of Orthopaedic Surgery, University of Berne, Inselspital, CH-3010 Berne, Switzerland.

S. Werlen, MD, Chief

Department of Radiology, Sonnenhof Clinic, Buchserstrasse 30, CH-3006 Berne, Switzerland.

Correspondence should be sent to Dr K. Ito.

©2001 British Editorial Society of Bone and Joint Surgery  
0301-620X/01/211092 \$2.00

Hip pain, resulting from disorders of the acetabular rim in non-dysplastic hips, has been increasingly recognised.<sup>1,2</sup> The conditions observed, notably degeneration, tearing, rupturing and ossification of the labrum,<sup>3</sup> as well as progressive damage to the adjacent acetabular cartilage, can be early precursors of arthritis.<sup>4,5</sup> Hence, understanding the pathomechanics is imperative if further degeneration of the joint is to be prevented.

Injury to the labrum and associated degeneration in dysplastic hips are believed to result from chronic abnormal loading of the acetabular rim.<sup>6,7</sup> In non-dysplastic hips, it has been suggested that the cause is repetitive microtrauma from impingement of the femoral neck against the acetabular rim,<sup>8</sup> or a cam-effect, in which a portion of the head with an increasing radius is squeezed under the acetabular rim. Several authors have reported a close correlation of coxarthrosis and femoral head-tilt or pistol-grip deformity<sup>9-11</sup> and reduced anteversion of the femoral neck.<sup>2</sup> In such situations, reduced clearance may cause impingement in flexion, particularly with internal rotation. This has been shown to occur in slipped capital femoral epiphysis with posterior tilt of the femoral head<sup>11,12</sup> and in cases of fracture of the femoral neck which have healed with slight rotational deformity.<sup>13</sup>

We have noted an increasing number of cases of pain in the hip associated with abnormality of the labrum in patients with a variety of hip shapes, for example in protrusio, acetabular retroversion, an elliptical femoral head and decreased anterior femoral offset (Fig. 1). We have also seen hips at operation with apparently normal femoral morphology on anteroposterior (AP) radiographs, but with little or no offset of the anterolateral head-neck junction (i.e., analogous to the head-neck ratio of hip prostheses). These conditions vary with the age, gender and physical activity of the patient. In this study, we have compared the femoral head-neck offset of patients with that of asymptomatic control subjects, in order to characterise the distribution and anatomical femoral locations which may cause femoroacetabular impingement and the cam-effect.

### Patients and Methods

Between September 1997 and September 1998 we examined prospectively 24 patients (12 men, 12 women) with

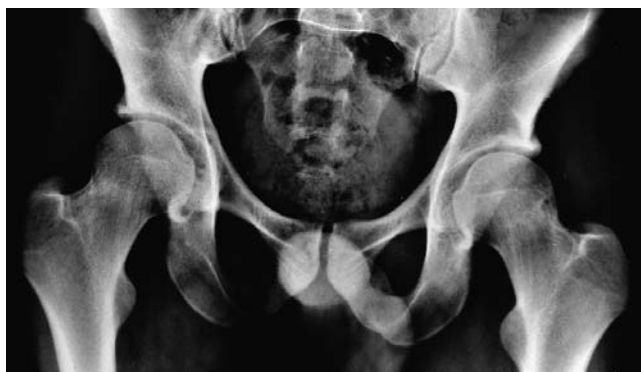

Fig. 1a

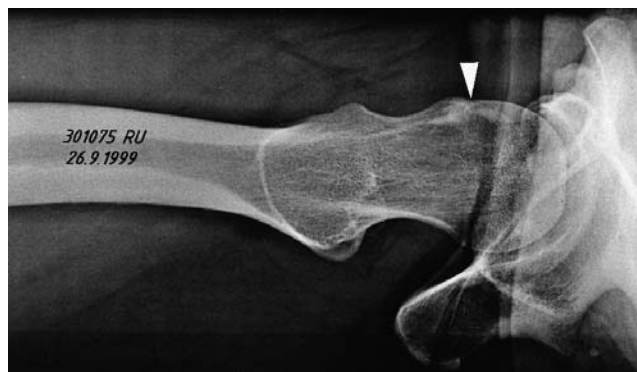

Fig. 1b

Radiographs from a 24-year-old man with bilateral groin pain limiting flexion in internal rotation by 10°. Figure 1a – AP pelvic radiograph showing the apparently normal morphology of the proximal femur and acetabulum. There is slight irregularity of the bony structure near the lateral contour of the head-neck junction. There is also reactive sclerosis corresponding to femoral abnormality. Figure 1b – Cross-table lateral radiograph of the right hip in slight internal rotation allowing for projection of the anterolateral head-neck junction. Lack of offset at this junction (arrow) is believed to cause impingement on the superior acetabular rim and pressure against the adjacent acetabular cartilage in flexion and flexion-internal-rotation.

pain in the hip. The criteria for inclusion were a painful hip, a positive impingement provocation test, i.e., pain with flexion, adduction and internal rotation, and abnormality of the labrum confirmed by MRI. We excluded patients with hip dysplasia, for example, protrusio (Tönnis grade 2 or higher),<sup>14</sup> or with slight osteoarthritic changes on radiographs or MRI, and those with a previous history of hip surgery, Perthes' disease or epiphysiolysis. Using the same exclusion criteria, 24 asymptomatic volunteers were selected for the control group with a similar age and distribution (Table I).

MRI (Vision 1.5T; Siemens, Erlangen, Germany) was used to record the geometry of the hip. Symptomatic hips were scanned after intra-articular injection of gadolinium-diethylenetriamine penta-acetic acid to identify and locate labral abnormality. In the asymptomatic group, one hip was randomly selected for MRI without injection of gadolinium. For all subjects, a FLASH sequence, coronal oblique section through the centre of the femoral head (CO) was taken (Fig. 2). This angle (femoral anteversion) was measured on transverse FLASH images of each hip. Using the angle of the femoral neck from the transverse plane (transverse angle), measured on section CO, double-oblique serial cross-sections of the femoral head and neck were imaged at 2 mm intervals. This final sequence for all

subjects was a three-dimensional FISP acquisition with high spatial resolution (512 × 512 matrix for 200 × 200 mm FOV) and 2 mm effective thickness.

Quantitative image analysis was performed using AutoCAD 14R (AutoDesk Inc, San Rafael, California). For each subject, the cross-section through the femoral head (FH section) and the section of potential impingement of the femoral neck (O section), that is the intersection between the best-fit circle to the acetabular articulating surface and the outer cortex of the femoral neck, were identified on the CO section (Fig. 2). For each cross-section image between the FH and O sections, closed spline contours were created to match the outer cortex of the femoral head and neck to produce a map of the femoral head and neck (see Fig. 5).

The contours corresponding to the equator of the femoral head and neck at the sites of impingement were used to quantify the femoral head-neck offset. Radial lines were described at intervals of 22.5°. Circumferentially around the femoral neck, at each radial line, the femoral head-neck offset ratio was defined as:

$$OR_i = \frac{(FH_i - O_i)}{R}$$

where OR = the offset ratio at position i, FH = the radius of

**Table I.** Summary of subject age and general femoral anatomy, stratified according to age group, gender and symptoms

Age (yr)	Gender	Symptoms	Number	Age (yrs)		Mean (± sd) femoral anteversion (degrees)	Mean (± sd) transverse angle (degrees)	Mean (± sd) impingement depth* (mm)
				Mean ± sd	Range			
<40	F	Symptomatic	7	27 ± 7	18 to 37	8.7 ± 4.5	38.3 ± 4.5	16.9 ± 4.3
		Asymptomatic	6	32 ± 5	23 to 38	14.7 ± 6.2	38.0 ± 6.0	21.0 ± 1.7
	M	Symptomatic	6	33 ± 18	28 to 38	11.5 ± 3.5	39.3 ± 3.2	13.0 ± 7.4
		Asymptomatic	7	34 ± 6	26 to 39	14.4 ± 3.6	39.9 ± 2.5	19.7 ± 2.1
≥40	F	Symptomatic	5	57 ± 14	44 to 78	7.4 ± 4.5	39.0 ± 5.3	18.0 ± 1.4
		Asymptomatic	6	50 ± 10	40 to 66	15.8 ± 3.1	39.0 ± 4.9	20.0 ± 1.3
	M	Symptomatic	6	49 ± 4	45 to 54	11.0 ± 6.1	37.3 ± 3.1	22.0 ± 2.5
		Asymptomatic	5	43 ± 4	40 to 51	18.6 ± 4.3	40.0 ± 6.0	20.4 ± 1.7

\* impingement depth is the location of impingement on the femoral neck with respect to distance distal to the centre of the femoral head

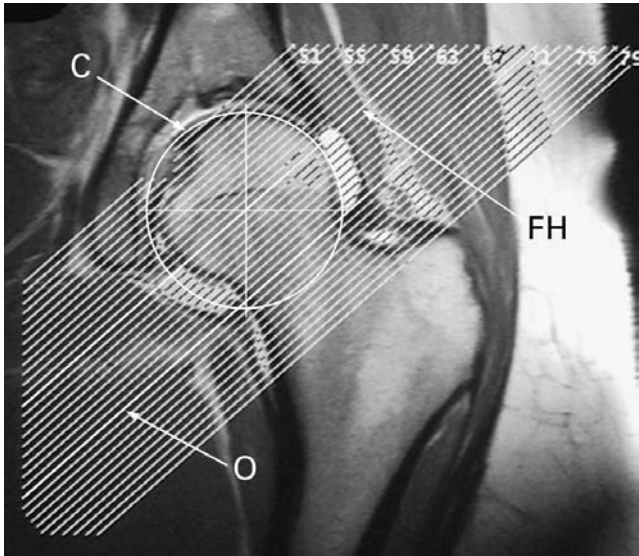


Fig. 2

A typical MRI scout view with the position of the serial neck cross-sections. A best-fit circle (C) to the acetabular articular circle is positioned. The centre of this circle defines the equatorial section of the femoral head (FH). The intersection of this circle with the outer cortex of the femoral neck defines the impingement section (O) of the femoral neck.

the femoral head at position  $i$ ,  $O$  = the neck radius at position  $i$  and  $R$  = the radius of the femoral head calculated from the area of the femoral head contour (Fig. 3). The position,  $i$ , was defined in relation to the anatomical positions, namely anteroposterior and mediolateral for each hip.

**Statistical analysis.** This was done using general linear model regression techniques which are similar to repeated-measures analysis of variance. Differences in offset ratios were analysed using a repeated-measures model with repeated variable location and independent variables, gender and symptomatic status. The relationship between gender and age was examined and included if found to be statistically significant. Recorded age was used to stratify the data from younger (< 40 years) and older (> 40 years) subjects. Normality of data and homogeneity of variance were examined respectively using Q-Q plots and Mauchly's

criterion for sphericity. If necessary, the Huynh-Feldt adjusted F values were used to determine significant effects. For significant effects ( $p < 0.05$ ), Tukey-Kramer *post-hoc* multiple comparisons were used to examine differences in the least-square means  $\pm$  standard errors of each group or subgroup. Least-square, rather than raw means were compared since the former accounts for covariate effects.

## Results

The patients and subjects in this study had a mean age which was less than that in the general population (Table I). Within age and gender groups, the mean angle of the neck, with respect to the transverse plane (transverse angle, approximate neck-shaft angle  $+90^\circ$ ), did not differ between the patients and the control subjects. Although there was no significant effect of gender or age, the mean ( $\pm$ SD) femoral anteversion, pooled for gender and age, was significantly less in the patients than in the control group ( $9.7 \pm 4.7^\circ$  v  $15.7 \pm 4.4^\circ$ ;  $p < 0.001$ ). Furthermore, within each subgroup of gender and age, the mean femoral anteversion angle was always significantly less in the patients (Table I). In younger subjects, pooled for gender, the location of impingement of the femoral neck was significantly closer to the femoral head in the patients compared with the control group ( $15.1 \pm 6.0$  v  $20.3 \pm 2.0$  mm;  $p < 0.001$ ). This was also true within the subgroup defined by gender (Table I).

There was a significant difference in the overall mean femoral head-neck offset between patients and control subjects, without regard to age or gender ( $p = 0.002$ ). Despite our initial clinical impression, there was no significant difference between genders alone. Comparing the specific locations around the femoral neck, the mean offset in the patients was significantly less than that in the normal subjects from the anterolateral to the medial region (mediolateral = inferosuperior). The significantly greater mean radii of the femoral neck in these regions for the patients confirm this (Fig. 4). Typical contour sets of the radii of the neck extending from the centre of the femoral head distally to the smallest cross-sectional area of the neck, showed the anatomical shape of the femoral neck and the difference in neck radii at various circumferential positions (Fig. 5).

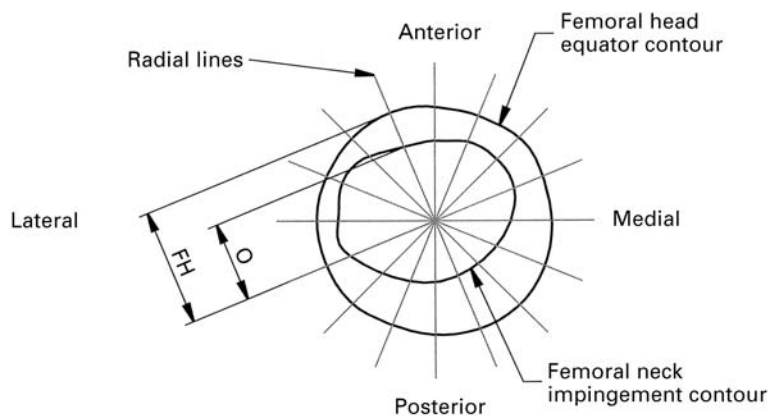


Fig. 3

Method of measurement of femoral head-neck offset. At each radial line, the radius FH to the equator contour of the femoral head and the radius O to the impingement contour of the femoral neck are measured.

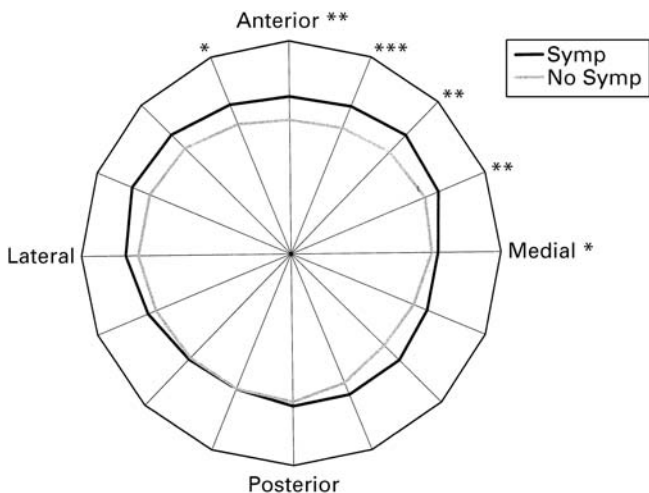


Fig. 4

Symptomatic (patients) *versus* asymptomatic (control) femoral head-neck offset pooled for gender and age group. The values represent mean radii of the femoral neck for various anatomical locations at the level of impingement. The radii are normalised to the radius of the femoral head. The outermost ring is the outline of the femoral head. Statistically significant intergroup differences based on symptomatic status are noted as \* $p = 0.05$ , \*\* $p = 0.01$  and \*\*\* $p < 0.01$ .

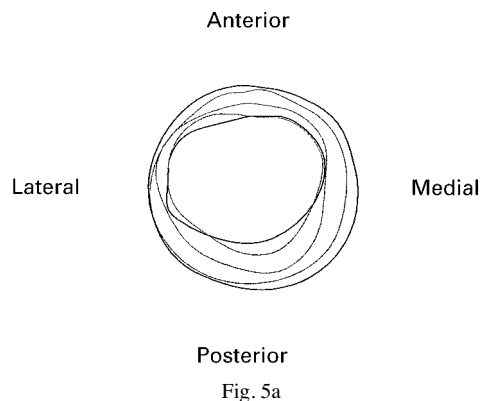


Fig. 5a

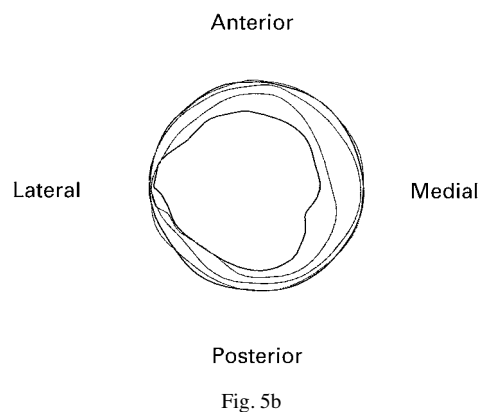


Fig. 5b

Contours of the outer cortex of the femoral neck at 2 mm intervals from the equator of the femoral head to the minimum head cross-sectional area for a) non-symptomatic control subjects and b) symptomatic subjects.

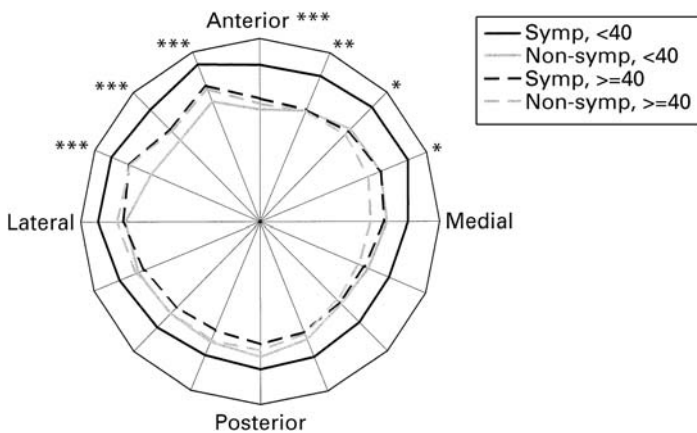


Fig. 6

Symptomatic (patients) *versus* asymptomatic (controls) femoral head-neck offset in men only, stratified for age group. The values represent the mean radii of the femoral neck for various anatomical locations at the level of impingement. The radii are normalised to the radius of the femoral head. The outermost ring is the outline of the femoral head. Statistically significant intergroup differences based on symptomatic status are noted as \* $p < 0.05$ , \*\* $p < 0.005$  and \*\*\* $p < 0.001$ .

Qualitative comparison of the contours between patients and control subjects revealed that there was a shallower taper to the neck of patients in the anterior and lateral aspects.

Stratifying the subject groups to younger (< 40 years old) and older ( $\geq 40$  years old) showed that there was a significant effect of gender on the mean femoral head-neck offset, and that this was significantly affected by age. In younger subjects, only the men had a significantly smaller mean offset in the patients when compared with the control

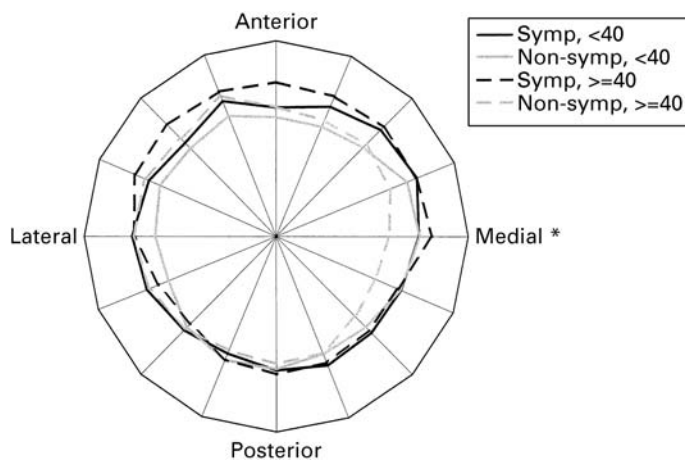


Fig. 7

Symptomatic (patients) *versus* asymptomatic (controls) femoral head-neck offset for women only, stratified for age group. The values represent the mean radii of the femoral neck for various anatomical locations at the level of impingement. The radii are normalised to the radius of the femoral head. The outermost ring is the outline of the femoral head. Statistically significant intergroup differences based on symptomatic status are noted as \* $p = 0.05$ .

group ( $p < 0.02$ ). By contrast, the reverse was found for older subjects with a significant effect for women ( $p = 0.005$ ). In younger men, the smaller mean offset of the patients was entirely in the anterior aspect, extending from the lateral to medial regions, but older men showed no significant difference in regard to symptomatic status (Fig. 6). In women, the difference in offset was not as great. When comparing all the offset in all subjects, older women showed a greater difference than younger women, but a statistically significant difference was found only in the medial region, with the anterior and anterolateral regions showing no more than a tendency (Fig. 7). Comparing all the offsets around the neck, variations in the shape of the neck may lessen the capacity to detect differences in the region of interest; acetabular abnormality commonly occurs at the superior and medial regions of the acetabular rim.<sup>1,12</sup> This more detailed comparison reveals that for older women, those with symptoms had a significantly smaller offset in the anterolateral and anterior regions ( $p < 0.003$ ).

## Discussion

In patients who present with hip pain which is inconsistent with the radiological findings, the pain may be elicited on clinical examination by a combination of passive flexion, adduction and internal rotation.<sup>7</sup> This provocation test indicates damage to the rim in which pain is a result of stimulation of the nociceptive receptors in the innervated labrum.<sup>15</sup> Our study shows that one possible cause is labral impingement or a cam-effect due to a variation in the proximal femoral anatomy, in which the proximal femur may abut the labrum lining the acetabular rim, or a portion of the proximal femur may intrude under the acetabular rim.

Although the MRI analyses used in our study were not calibrated, the conclusions remain valid. The statistical comparison was carried out on normalised values, which were all measured in a similar fashion. No absolute measurements were used, and the systematic image analysis introduced only consistent errors. Unlike the patients the control subjects did not receive intra-articular injections of gadolinium, for ethical reasons. The images used to define the anatomy were, however, of the same sequence and the cortical surfaces of the femoral neck were clear in all images. Furthermore, our general technique for the anatomical measurement of the femoral neck is supported by earlier anthropological studies, i.e. statistically larger neck radii in the superior and anterior aspects of the neck in control subjects.<sup>16</sup> Although measurement on cadavers would have been more exact, it is not possible to identify donors with documented impingement. MRI is a diagnostically useful non-invasive technique readily available in the clinic, and impingement could be verified at operation in the patients.

In our study, variations in the anatomy of the proximal femur appear to be a possible cause of labral impingement

or the cam-effect. Comparison between gender- and age-pooled patients and control subjects showed a statistically significant reduction in femoral anteversion and head-neck offset in the anterior aspect of the femoral neck. The patients appear to have a shallower taper between the femoral head and neck. With these anatomical variations, contact of the femur against the acetabular rim is explicable. With relatively greater anterior radii and/or shallower taper of the neck, the occurrence of impingement against the anterior acetabular rim, even within the normal range of movement, is quite possible. Reduced femoral anteversion may exacerbate this situation or by itself cause anterior impingement because it decreases the clearance for flexion, and even more for flexion in internal rotation. Consistent with this mechanism, Tönnis and Heinecke<sup>2</sup> have recently demonstrated that a decreased femoral anteversion is associated with pain and osteoarthritis. A subclinical slipped capital femoral epiphysis with posterior tilt may cause damage to the labrum and osteoarthritis.<sup>11,12</sup>

Our study shows that acetabular impingement or the cam-effect, caused by variations in the anatomy of the proximal femur, varies with gender and age. Symptomatic younger men had a significantly reduced head-neck offset in the lateral and anterior aspects of the neck, and symptomatic older women showed the same features in the anterior aspect, in comparison with age- and gender-matched control subjects. Although anecdotal, our clinical experience suggests that the level of activity of patients may play a role. Reduced femoral offset can only cause impingement when the hip is positioned in a specific point in the arc of movement. The gender and age distribution shown in our study is helpful for diagnostic guidance when an anatomical aetiology of impingement or cam-effect is suspected by the presence of a positive impingement sign. In such cases, a lateral radiograph or MR arthrogram may be helpful to reveal anterior and anterolateral reduced femoral head-neck offset. Since pathology caused by acetabular impingement or the cam-effect may lead to coxarthrosis, early treatment to eliminate this microtrauma could preserve the joint.

This study was supported in part by the Research Funds of the Orthopaedic Surgery Department, University of Berne, Inselspital and the AO Foundation. Dr R. Gruetter of the AO Research Institute and T. Heldstab of the AO Development Institute provided assistance in image processing.

No benefits in any form have been received or will be received from a commercial party related directly or indirectly to the subject of this article.

## References

1. Leunig M, Werlen S, Ungersbock A, Ito K, Ganz R. Evaluation of the acetabular labrum by MR arthrography. *J Bone Joint Surg [Br]* 1997;79-B:230-4.
2. Tönnis D, Heinecke A. Acetabular and femoral anteversion: relationship with osteoarthritis of the hip. *J Bone Joint Surg [Am]* 1999;81-A:1747-70.
3. Ito K, Leunig M, Keller I, Werlen S, Ganz R. Impingement-induced damage of the acetabular labrum: a possible initiator of hip arthrosis. 8th Annual Meeting, European Orthopaedic Research Society, 1998:55.
4. Harris WH, Bourne RB, Oh I. Intra-articular acetabular labrum: a possible etiological factor in certain cases of osteoarthritis of the hip. *J Bone Joint Surg [Am]* 1979;61-A:510-4.

5. **Santori N, Villar RN.** Arthroscopic findings in the initial stages of hip osteoarthritis. *Orthopaedics* 1999;22:405-9.
6. **Dorrell JH, Catterall A.** The torn acetabular labrum. *J Bone Joint Surg [Br]* 1986;68-B:400-3.
7. **Klaue K, Durnin CW, Ganz R.** The acetabular rim syndrome: a clinical presentation of dysplasia of the hip. *J Bone Joint Surg [Br]* 1991;73-B:423-9.
8. **Ganz R, Leunig M, Ito K, Werlen S.** MR arthrography of the hip joint: value in the detection of acetabular labrum pathologies. Proc 3rd congress European Federation of National Associations of Orthopaedics and Traumatology, Barcelona, 1997:7-8.
9. **Murray RO.** The aetiology of primary osteoarthritis of the hip. *Br J Radiol* 1965;38:810-24.
10. **Solomon L.** Patterns of osteoarthritis of the hip. *J Bone Joint Surg [Br]* 1976;58-B:176-83.
11. **Goodman DA, Feighan JE, Smith AD, et al.** Subclinical slipped capital femoral epiphysis: relationship to osteoarthritis of the hip. *J Bone Joint Surg [Am]* 1997;79-A:1489-97.
12. **Leunig M, Casillas MM, Hamlet M, et al.** Slipped capital femoral epiphysis: early mechanical damage to the acetabular cartilage by impingement of the prominent femoral metaphysis. *Acta Orthop Scand* 2000;71:370-375.
13. **Eijer H, Ganz R.** Anterieur femoro-acetabulair impingement na een mediale collumfractuur: een casus. *Ned Tijdschr Trauma* 1999;2:50-2.
14. **Busse J, Gasteigu W, Tönnis D.** A new method for roentgenologic evaluation of the hip joint – the hip factor. *Arch Orthop Unfallchir* 1972;72:1-9.
15. **Kim YT, Azuma H.** The nerve endings of the acetabular labrum. *Clin Orthop* 1995, 320:176-81.
16. **Backman S.** The proximal end of the femur: investigations with special reference to the etiology of femoral neck fractures; anatomical studies; roentgen projections; theoretical stress calculations; experimental production of fractures. *Acta Radiol (Stockh) [Suppl]* 1957;146:1-166.