

Research Article

# Clinical characteristics in STEMI-like aortic dissection versus STEMI-like pulmonary embolism

Oscar MP Jolobe\*

Manchester Medical Society, Medical Division, Simon Building, Brunswick Street, Manchester, M13 9PL, UK

## Abstract

Dissecting aortic aneurysm with ST segment elevation, and pulmonary embolism with ST segment elevation are two of a number of clinical entities which can simulate ST segment elevation myocardial infarction.

**Objective:** The purpose of this review is to analyse clinical features in anecdotal reports of 138 dissecting aortic aneurysm patients with STEMI-like presentation, and 102 pulmonary embolism patients with STEMI-like presentation in order to generate insights which might help to optimise triage of patients with STEMI-like clinical presentation.

**Methods:** Reports were culled from a literature search covering the period January 2000 to March 2020 using Google Scholar, Pubmed, EMBASE and MEDLINE. Reports were included only if there was a specification of the location of ST segment elevation and an account of the clinical signs and symptoms. Search terms were "ST segment elevation", "aortic dissection", "pulmonary embolism", "myocardial infarction", and "paradoxical embolism". Fisher's exact test was utilised for two-sided comparison of proportions. Proportion was calculated for each group as the number of patients with that parameter relative to the total number of patients assessed for that parameter.

**Findings:** There were 138 patients with aortic dissection, 91 of whom were either fast-tracked to coronary angiography (81 patients) or fast-tracked to thrombolytic treatment (10 patients). There were 47 patients managed with neither of those strategies. There were 102 patients with pulmonary embolism, 71 of whom were fast tracked to coronary angiography, and 31 who did not receive that evaluation. Compared with their dissecting aortic aneurysm counterparts, those dissecting aortic aneurysm patients initially managed by percutaneous coronary intervention or by thrombolysis were significantly ( $p = 0.0003$ ) more likely to have presented with chest pain, and significantly ( $p = 0.018$ ) less likely to have presented with breathlessness. The preferential fast-tracking to coronary angiography prevailed in spite of comparable prevalence of back pain in fast tracked and in non-fast tracked subjects. Use of transthoracic echocardiography was also comparable in the two subgroups of dissecting aortic aneurysm patients. Pulmonary embolism patients fast tracked to percutaneous coronary intervention were significantly ( $p = 0.0008$ ) more likely to have presented with chest pain than their pulmonary embolism counterparts who were not fast-tracked. The prevalence of paradoxical embolism was also significantly ( $p = 0.0016$ ) higher in fast-tracked patients than in counterparts not fast-tracked. Cardiac arrest was significantly ( $p = 0.0177$ ) less prevalent in fast-tracked pulmonary embolism patients than in pulmonary embolism patients who were not fast-tracked. Preferential fast-tracking to coronary angiography prevailed in spite of the fact that prevalence of documented deep vein thrombosis was comparable in fast-tracked subjects and in subjects not fast-tracked. The prevalence of use of transthoracic echocardiography was also similar in fast-tracked pulmonary embolism patients vs counterparts not fast tracked. Overall, however, transthoracic echocardiography had been utilised significantly ( $p = 0.007$ ) less frequently in dissecting aneurysm patients than in pulmonary embolism patients.

**Conclusion:** Given the high prevalence of STEMI-like presentation in aortic dissection there is a need for greater use of point-of-care transthoracic echocardiography to mitigate risk of inappropriate percutaneous coronary intervention (which might delay implementation of aortic repair surgery) and inappropriate thrombolysis (which might precipitate hemorrhagic cardiac tamponade) (75) during triage of patients presenting with ST segment elevation simulating ST segment elevation myocardial infarction (STEMI). Furthermore, during triage of patients with STEMI-like clinical presentation, the combined use of point-of-care echocardiography and evaluation for deep vein thrombosis will facilitate the differentiation between acute myocardial infarction, STEMI-like aortic dissection, and STEMI-like pulmonary embolism. Among STEMI-like patients in whom DAA has been ruled out by point of care TTE, fast tracking to PCI might generate an opportunity to identify and treat paradoxical coronary artery embolism by thrombectomy. Thereby mitigating the mortality risk associated with coronary occlusion. Concurrent awareness of PE as the underlying cause of paradoxical embolism also generates an opportunity to relieve the clot burden in the pulmonary circulation, either by pulmonary embolectomy or by thrombolysis. Above all, frontline clinicians should have a greater awareness of the syndrome of STEMI-like presentation of aortic dissection and STEMI-like pulmonary embolism so as to mitigate the risk of inappropriate thrombolysis and inappropriate percutaneous coronary angiography which seems to prevail even in the presence of red flags such as back pain (for aortic dissection) and deep vein thrombosis (for pulmonary embolism).

## More Information

\*Address for Correspondence: Oscar MP Jolobe, MRCP, Manchester Medical Society, Medical Division, Simon Building, Brunswick Street, Manchester, M13 9PL, UK, Tel: 44 161 900 6887; Email: oscarjolobe@yahoo.co.uk

Submitted: 07 July 2020

Approved: 30 July 2020

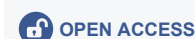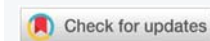
Published: 31 July 2020

**How to cite this article:** Jolobe OPM. Clinical characteristics in STEMI-like aortic dissection versus STEMI-like pulmonary embolism. Arch Vas Med. 2020; 4: 019-030.

DOI: 10.29328/journal.avm.1001013

**Copyright:** © 2020 Jolobe OPM. This is an open access article distributed under the Creative Commons Attribution License, which permits unrestricted use, distribution, and reproduction in any medium, provided the original work is properly cited.

**Keywords:** Aortic dissection; Pulmonary embolism; ST-elevation; Percutaneous coronary intervention





## Introduction

The syndrome of ST segment elevation encompasses acute myocardial infarction (AMI) [1], dissecting aortic aneurysm (DAA) [2], and pulmonary embolism (PE) [3], respectively. When faced with a patient with an electrocardiogram (ECG) characterised by ST segment elevation, the challenge which confronts front line doctors is whether or not to fast-track the patient to the catheter lab for percutaneous coronary intervention (PCI) [4] or to evaluate the patient for alternative diagnoses, which include DAA [2] and PE [3], respectively. Although clinical decision rules (CDRs) explicitly spell out algorithms for the differential diagnosis of ST segment elevation myocardial infarction (STEMI) [1], DAA [5], and PE [6], those CDRs do not take into account those cases of DAA and PE, respectively, who have a STEMI-like presentation. In the absence of guidelines for management of STEMI-like DAA and STEMI-like PE most clinicians rely on gestalt (ie unstructured clinical decision-making) for the work-up of STEMI-like clinical presentation. This review of the clinical characteristics of STEMI-like patients with DAA and STEMI-like patients with PE is, in essence, a reflection of the degree to which the index of suspicion for either DAA or PE operates in real world clinical medicine, where clinicians rely mainly on gestalt for clinical decision making.

### Clinical features in 138 DAA patients with ST segment elevation

These 138 patients [2,7-124] were subdivided into 91 who had initially been managed by percutaneous coronary intervention (PCI) or by thrombolysis, arguably on the premise that the underlying cause of their clinical presentation was acute myocardial infarction (AMI), and 47 who had experienced alternative strategies for diagnostic workup.

### Clinical features in 91 patients managed according to the AMI protocol

There were 91 patients [2,7-85,105,124] managed according to an AMI-oriented protocol encompassing either PCI or thrombolysis, the latter administered in 10 of the subjects [18,29,31,32,34,39,41,42,75,82]. Mean age of the 91 patients was 58. Sixty-eight were males, 23 females. Chest pain was reported in 85 (98%), and back pain in 17 (20%) of the 87 patients in whom those parameters could be ascertained. In 4 instances it could not be ascertained whether or not there was back pain nor chest pain. Breathlessness occurred in 11 (12%) subjects [20,27,32,34,35,37,42,58,62,80,84], including one patient with a clinically audible murmur of aortic regurgitation. Focal neurological symptoms were present in six subjects, comprising unilateral upper limb pain, lower limb sensory symptoms, hemiparesis, unilateral headache, unilateral lower limb sensory symptoms, and paraparesis, respectively. The murmur of aortic regurgitation was detected in six, and mediastinal enlargement in two. The caveat is that there was no routine evaluation for the murmur of aortic regurgitation,

focal neurological symptoms, or mediastinal widening in "all comers" with ST segment elevation. In the period leading up to operative intervention, cardiac arrest occurred in 16 subjects [2,31,40-44,46-51,66]. Nine survived the episode of cardiac arrest. Electrocardiographic manifestations in these 91 patients were the following:-

ST segment elevation in the inferior leads II,III,AVF ( singly or in various combinations, with or without concurrent ST elevation in AVR or precordial leads) was documented in 45 patients. ST elevation in precordial leads was documented in 34 patients (without concurrent ST elevation in II,III,AVF, and also without concurrent ST elevation in AVR). ST elevation in AVR was documented in 12 patients (with or without concurrent elevation in precordial leads, and exclusive of concurrent ST elevation in II, III, or AVF).

Electrocardiographic stigmata at the moment of cardiac arrest were the following:-

Ventricular tachycardia (4 patients), ventricular fibrillation (3 patients), pulseless electrical activity (1 patient), asystole (1 patient), shock (1 patient), unspecified (5 patients).

In the entire group of 91 subjects managed according to the AMI-oriented algorithm, 46 (51%) were also evaluated by TTE. Three of these 46 patients were evaluated by TTE as well as by transoesophageal echocardiography (TOE). Thirty-two (70%) of the 46 TTE evaluations showed stigmata of DAA. Ten subjects were evaluated by transoesophageal echocardiography (including 3 evaluated by TTE as well as TOE), which showed stigmata of DAA in each instance.

### Clinical features in 47 patients who were not managed according to the ST segment elevation myocardial infarction algorithm

These 47 patients [86-124] had a mean age 58. Thirty-two were male, 15 were female. Chest pain occurred in 34 (72%), and back pain 13 (27.6%) of the 44 patients in whom those parameters could be ascertained. However, in 3 instances it could not be ascertained whether or not there was presence or absence of either back pain or chest pain. In 8 other instances [107-109,111,113,114,122], the patients specifically denied presence of both chest pain and back pain. Breathlessness occurred in 14 (30%) [22,45,63,88,91,92,99,100,104,111,114,118,122] subjects, including 4 with the clinically audible murmur of aortic regurgitation. Focal neurological symptoms occurred in 14, comprising paraparesis, unilateral lower limb weakness, unilateral upper limb pain, unilateral lower limb pain, and unilateral lower limb pain, respectively. The murmur of aortic regurgitation was elicited in 12, and mediastinal enlargement was documented in 10. However, none of the latter three parameters were routinely evaluated in every patient not fast tracked. In the period leading up to surgical intervention cardiac arrest occurred in 9 patients [52,53,92-95,98,124]. Three survived that episode.

Electrocardiographic manifestations in these 47 patients were the following:-

In 22 patients ST segment elevation was documented in leads II,III,AVF (with or without ST concurrent segment elevation in AVR or precordial leads). In 19 patients, ST segment elevation was documented in precordial leads, without concurrent ST segment elevation in II,III,AVF, or AVR. In 6 patients ST segment elevation was documented in lead AVR, with or without ST segment elevation in precordial leads, but exclusive of concurrent ST elevation in II,III,AVF.

Electrocardiographic stigmata at the time of the cardiac arrest were the following:-

Ventricular tachycardia (2 patients), ventricular fibrillation (1 patient), pulseless electrical activity (3 patients), asystole (1 patient), unspecified (3 patients).

In the entire subgroup of 47 subjects not managed according to an AMI-related algorithm 31(66%) were evaluated by TTE. One of these 31 patients was evaluated by TTE as well as by TOE. Twenty six (84%) of the 31 TTE evaluations showed stigmata of DAA. Three others were evaluated only by TOE, which was diagnostic of DAA in all three.

### Comparison between DAA patients fast tracked to the AMI-algorithm vs DAA patients not fast tracked (Table 1)

**Table 1:** STEMI-like DAA (138 patients).

Parameter	Fast-tracked	Not Fast-tracked	Difference
Number of patients	91	47	
Mean Age in years	58	58	NS
Male/Female ratio	68/23	32/15	NS
Chest pain <sup>#</sup>	85/87	34/44	$p = 0.0003$
Back pain <sup>#</sup>	17/87	13/44	NS
Neither chest nor back pain <sup>#</sup>	0/87	8/44	$p = 0.0001$
Breathlessness	11	14	$p = 0.018$
Cardiac arrest	16	9	NS
Survival from cardiac arrest <sup>###</sup>	9/16	3/9	NS
Inferior ST elevation	45	22	NS
Precordial ST elevation	34	19	NS
AVR ST elevation	12	6	NS
TTE use	46	31	NS
TOE use	10	4	NS

<sup>#</sup>not available for all patients  
<sup>###</sup>only applicable to those who had cardiac arrest  
 NS not significant at the 5% level

Chest pain was significantly ( $p = 0.0003$ ) more prevalent in patients fast-tracked to the myocardial infarction pathway than in counterparts managed differently. Furthermore, all 8 of the DAA patients with pain-free presentation belonged to the subgroup of patients not fast-tracked to PCI [107-109,111,113,114,122]. Breathlessness was significantly ( $p = 0.018$ ) more prevalent in patients not fast tracked to the myocardial infarction pathway. Back pain, cardiac arrest were each just as prevalent in subjects fast-tracked to the AMI-related algorithm as in counterparts not fast-tracked to that algorithm. TTE use was comparable in the two subgroups.

### Clinical features in 102 PE subjects with STEMI-like presentation

These 102 subjects [3,125-221] included 71 in whom the initial management consisted of fast-tracking to PCI. Among these were 32 patients with paradoxical coronary embolism [134,136,189-209,211,212,214,215,217,219-221]. The other subgroup consisted of 31 subjects who were not fast-tracked to PCI Among these were 4 subjects with paradoxical coronary embolism [210,213,216,218].

### PE patients in the PCI subgroup (71 patients; 33 males, 38 females)

In the PCI subgroup mean age was 60. Thirty-three were males, thirty-eight were females. Among those 71 patients chest pain was documented in 56, and breathlessness in 47. In 4 instances the presence or absence of chest pain and/or breathlessness could not be ascertained. Thirty two patients had paradoxical coronary artery embolism, associated, in 9 instances, with stroke and, in 2 instances, with transient ischaemic attack. Other manifestations of paradoxical embolism(PDE) were emboli to arteries in the limbs [195], and emboli to the renal artery (2 cases) [195,206], and to the splenic artery (1 case) [206]. All 32 PDE subjects had coronary angiography but thrombotic occlusion was absent in 2 cases [189,195]. In both of the latter 2 cases there were concurrent extracardiac embolic manifestations. Thirty-one of the 71 subjects with STEMI-like PE had documentation of deep vein thrombosis (DVT). Twenty of the 31 cases of DVT were in the PDE subgroup. Cardiac arrest was a feature of the clinical presentation in 15 patients (21%) [151-160,173,174,180,203], including one with PDE [203]. Six patients survived the cardiac arrest episode. Three of the survivors had received thrombolysis, one had embolectomy, and one had been managed solely by anticoagulants.

Electrocardiographic manifestations in these 71 patients were as follows:-

In 30 patients, the ECG showed ST segment elevation in the precordial leads without concurrent ST elevation in AVR or in inferior leads.

Lead AVR(with or without involvement of precordial leads was the location of ST segment elevation in 6 cases. In 35 patients ST segment elevation occurred in leads II,III,AVF (singly or in various combinations) with or without concurrent ST segment elevation in AVR or precordial leads. Twenty-two of the 35 cases of ST segment elevation with inferior location were attributable to PDE. Among those with cardiac arrest, that complication was associated with pulseless electrical activity in 9, ventricular fibrillation in 2, ventricular tachycardia in one, and shock in 2.

Fifty-four (76%) of the 71 patients were evaluated by TTE. Right ventricular dilatation was documented in 43 (79.6%) of

the 54 TTE evaluations. Five patients were evaluated by TOE [189,200,206,212,214], which showed embolus-in-transit across the interatrial septum in 4 cases.

### PE subgroup not managed with PCI (31 patients)

In the subgroup managed without PCI, there were 31 patients, including 4 with PDE. Their mean age was 54. Twenty were males, eleven females. Chest pain and breathlessness occurred in 13 and in 23 patients, respectively. In 4 instances the presence or absence of chest pain and/or breathlessness could not be ascertained. Twenty-one had TTE, which showed right ventricular dilatation in twenty. Two others, both with PDE, had transoesophageal echocardiography (TOE), which showed embolus-in-transit in one instance [213]. Coexistence of DVT was documented in ten (32%) of the 31 subjects. Six of the ten [161,162,167,175,179,185] had TTE, and in each case TTE showed right ventricular dilatation. Two patients, each with right ventricular dilatation on TTE [175,185] had cardiac arrest, and were successfully resuscitated. Altogether 14 had cardiac arrest [175,177-188]. Seven patients survived the cardiac arrest episode. Four of the survivors had received thrombolysis, one had been managed by embolectomy, and two had been managed solely by anticoagulants. In these 31 patients, electrocardiographic manifestations were as follows:-

In 16 patients the electrocardiogram showed ST elevation in the precordial leads. In 10 patients the ECG showed ST segment elevation in inferior leads. In 2 instances inferior ST segment elevation was associated with paradoxical embolism. In 6 patients the ECG showed ST segment elevation in AVR. Among those with cardiac arrest, that complication was associated with pulseless electrical activity in 6, ventricular fibrillation in 2, shock in 2, unknown mechanism in 3.

### Comparison between PE patients fast-tracked to PCI and PE patients not fast tracked to PCI (Table 2)

Parameter	Fast-tracked	Not Fast-tracked	Difference
Number of patients	71	31	
Mean Age in years	60	54 <sup>s</sup>	NS
Male/Female ratio	33/38	20/11	NS
Chest pain <sup>#</sup>	56/67	13/27	$p = 0.0008$
Breathlessness <sup>#</sup>	47/67	23/27	NS
Paradoxical embolism	32	4	$p = 0.0016$
Deep vein thrombosis	31	10	NS
Cardiac arrest	15	14	$p = 0.0177$
Survival from arrest <sup>##</sup>	6/15	7/14	NS
Inferior ST elevation	35	10	NS
Precordial ST elevation	30	16	NS
AVR ST elevation	6	6	NS
TTE use	54	21	NS
TOE use	7	2	NS

<sup>#</sup>not available for all patients  
<sup>##</sup>only applicable to those who had cardiac arrest  
 NS: Not Significant at the 5% level  
<sup>s</sup>unknown for 1 patient

### Overall Comparison between STEMI-like DAA and STEMI-like PE (Table 3)

Parameter	STEMI-like DAA	STEMI-like PE	Difference
Number of patients	138	102	
Mean Age in years	58	60	NS
Male/Female ratio	100/38	53/49	$p = 0.0017$
Chest pain <sup>#</sup>	119/131	69/94	$p = 0.0008$
Breathlessness <sup>#</sup>	25/138	70/94	$p = 0.0001$
Cardiac arrest	25	29	NS
Survival from cardiac arrest <sup>##</sup>	12/25	13/29	NS
Inferior ST elevation	67	45	NS
Precordial ST elevation	53	46	NS
AVR ST elevation	18	6	NS
TTE use	77	75	$p = 0.007$
TOE use	14	9	NS
Fast tracked	91	71	NS

<sup>#</sup>not available for all patients  
<sup>##</sup>only applicable to those who had cardiac arrest  
 NS: Not Significant at the 5% level

### Summary of STEMI-like DAA vs STEMI-like PE

The proportion of men in the STEMI-like DAA subgroup was greater than the proportion of men in STEMI-like PE.

Chest pain was significantly more prevalent in STEMI-like DAA than in STEMI-like PE.

Breathlessness was more prevalent in STEMI-like PE than in STEMI-like DAA.

Prevalence of cardiac arrest was lower in PE patients fast-tracked to PCI than in PE patients not fast tracked to PCI.

Prevalence of use of TTE was significantly greater in STEMI-like PE than in STEMI-like DAA.

Irrespective of the underlying cause of ST segment elevation, and also irrespective of presence of risk factors, either for DAA (such as back pain) or for PE (such as DVT), patients with STEMI-like presentation who had chest pain were more likely to be fast-tracked to coronary angiography than to be initially evaluated with alternative strategies.

## Discussion

The pattern which emerges from this review is that chest pain is the principal clinical feature which raises the index of suspicion for AMI in DAA patients who present with ST segment elevation. Conversely, when a patient with STEMI-like DAA presents with dyspnoea that symptom appears to raise the index of suspicion for a diagnosis (such as DAA) other than AMI. Although not all patients with STEMI-like clinical presentation were evaluated for the murmur of aortic regurgitation, focal neurological symptoms, and mediastinal widening, it may well be that, in some patients, breathlessness was a symptom of aortic regurgitation, thereby indirectly raising the index of suspicion for DAA.



Back pain had comparable prevalence in patients fast-tracked to the AMI-related pathway vs patients managed by alternative strategies, arguably because none of the patients described their back pain as having the “tearing” quality attributed to DAA in the clinical decision rules [5]. When back pain does not have that distinctive quality it can be indistinguishable from the back pain which sometimes occurs in AMI [224].

In the context of STEMI-like PE, presenting features included chest pain, breathlessness, and cardiac arrest. The higher prevalence of chest pain in the patients fast-tracked to PCI was, arguably, indicative of a heightened index of suspicion for AMI in that subgroup. Cardiac arrest, on the other hand had significantly lower prevalence in fast-tracked patients than in their non fast-tracked counterparts. This phenomenon might have been attributable to the fact that 32 of the fast tracked patients had paradoxical coronary embolism, the latter a risk factor for cardiac arrest which can be mitigated by PCI. Indeed, 20 of the 32 PDE subjects in the fast-track subgroup were managed by thrombectomy, thereby mitigating the mortality risk associated with coronary occlusion. The opportunity to mitigate the risk of sudden death in this manner was missed in a 75 year old patient with PDE and angiographically documented right coronary artery embolism, and in whom coronary thrombectomy was not undertaken. Instead, after coronary angiography, she was urgently evaluated by computed tomography for suspected DAA. Soon after that procedure(which showed massive PE but no DAA), he suffered a fatal cardiac arrest [203]. Arguably, in her case, the risk of cardiac arrest could have been mitigated by the hybrid approach of combined coronary thrombectomy and pulmonary artery thrombectomy [192,202,211]. Breathlessness, on the other hand, had comparable prevalence in patients fast tracked to PCI vs patients managed according to a PE-related algorithm. The same was also true of the comparable prevalence of DVT in the two subgroups, the caveat being that not all subjects were evaluated for presence or absence of DVT. The suboptimal inclusion of PE in the differential diagnosis of patients in whom ST segment elevation coexisted either with breathlessness or DVT, and the suboptimal use of point-of care- Doppler ultrasonography of the lower limbs (to identify DVT) might have been attributable to underrecognition of the entity of PE related ST segment elevation [3].

The management of STEMI-like DAA would, arguably, have been vastly improved by point-of care ultrasonography, especially in the subgroup with breathlessness. In that context the use of point-of-care ultrasonography is exemplified by the Vivid-7 system(GE Medical, Milwaukee, Wisconsin, USA) which can also be taught to paramedical personnel [225]. Use of this system would have facilitated detection of heart murmurs including the wide variety of heart murmurs associated with aortic dissection[226]. Mere detection of a

heart murmur would then have raised the index of suspicion for DAA, prompting more sophisticated evaluation by means of point of care TTE. The corollary is that routine lower limb ultrasonography would have raised the index of suspicion for PE, thereby prompting more sophisticated evaluation of suspected PE by point-of-care TTE.

This review was not only a reflection of “real world” clinical practice but also a reflection of the demographics of DAA and PE, respectively, exemplified by the observation that, in this review, STEMI-like DAA had a male preponderance which mirrored the male preponderance of DAA documented in epidemiological studies [227]. For STEMI-like PE this review did not show a distinctive male preponderance, arguably reflecting the observation that epidemiological studies document only a 1.2:1 male: female ratio in the incidence of venous thromboembolism [228]. This review also created an opportunity to compare the rate at which STEMI-like DAA and STEMI-like PE have been reported in the medical literature. Remarkably, notwithstanding the fact that DAA(with age and sex adjusted incidence of 4.4 per 100,000 person years [227] has a much lower incidence than PE(with age and sex adjusted incidence 100-130 per 100,000 (persons/years) [228], the number of DAA-related reports of ST segment elevation was much higher than the number of PE-related reports of ST segment elevation. This anomaly might be a reflection of a greater propensity for Type II myocardial infarction to occur in DAA than in PE. That propensity might, in turn, be attributable to differences in the mechanism for generating the equivalent of Type II myocardial infarction in the two disorders. In DAA, myocardial ischaemia is attributable to the mechanical disruption of myocardial blood supply as a result of involvement of the coronary ostium by the tear in the ascending aorta [2,229]. That aetiopathogenic mechanism is the underlying cause for the high prevalence of myocardial malperfusion in DAA. In PE the operative factor might be the mismatch between oxygen demand and oxygen supply to the myocardium as a result of PE-related haemodynamic changes. The latter aetiopathogenic mechanism appears to have only a modest likelihood of generating the occurrence of myocardial infarction with nonobstructive coronary arteries.

## Acknowledgment

I am grateful to Angela McKenzie M.Sc for statistical analysis of the results.

## References

1. Thygesen K, Alpert JS, Jaffe AS, Simoons ML, Chaitman BR, et al. Third universal definition of myocardial infarction. *Eur Heart J*. 2012; 33: 2551-2567.  
**PubMed:** <https://pubmed.ncbi.nlm.nih.gov/22922414/>
2. Wang JL, Chen CC, Wang CY, Hsieh MJ, Chang SH, et al. Acute Type A aortic dissection presenting as ST segment elevation myocardial infarction referred for percutaneous coronary intervention. *Acta Cardiol Sinica*. 2016; 32: 265-272.  
**PubMed:** <https://www.ncbi.nlm.nih.gov/pmc/articles/PMC4884753/>

3. Villablanca PA, Vlismas PP, Aleksandrovich T, Omondi A, Gupta T, et al. Case report and systematic review of pulmonary embolism mimicking ST-elevation myocardial infarction. *Vascular*. 2019; 27: 90-97.  
**PubMed:** <https://pubmed.ncbi.nlm.nih.gov/30056785/>
4. Fabris E, Arrigoni P, Falco L, Barlati G, Stolfo D, et al. Impact of patient delay in a modern real world STEMI network. *Am J Emerg Med*. 2020.
5. Nazerian P, Mueller C, de Matos Soeiro, Leidel BA, Salvadeo SAT, et al. Diagnostic accuracy of the aortic dissection risk score plus D-dimer for acute aortic syndromes. *Circulation*. 2018; 137: 250-258.  
**PubMed:** <https://pubmed.ncbi.nlm.nih.gov/29030346/>
6. Wells PS, Anderson DR, Rodger M, Ginsberg JS, Kearon C, et al. Derivation of a simple clinical model to categorize patients probability of pulmonary embolism: Increasing the model's utility with the simpliRED D-dimer. *Thromb Haemost* 2000; 83: 416-420.  
**PubMed:** <https://pubmed.ncbi.nlm.nih.gov/10744147/>
7. Hibi K, Kimura K, Nakatogawa T, Okuda J, Umcumura S, et al. Intracoronary ultrasound diagnosis of an aortic dissection causing anterior acute myocardial infarction. *Circulation*. 2003; 108: e145-e146.
8. Wang ZG, Zhao W, Shen BT, Zheng Y, Liu Q. Successful treatment of a case of acute myocardial infarction due to type A aortic dissection by coronary artery stenting: A case report. *Exper Therap Med*. 2015; 10: 759-762.  
**PubMed:** <https://pubmed.ncbi.nlm.nih.gov/26622389/>
9. Wang W, Wu J, Zhao XZ, You K, Li C. Type A aortic dissection manifesting as acute inferior myocardial infarction: 2 case reports. *Medicine*. 2019; 98: 43: e17662.  
**PubMed:** <https://www.ncbi.nlm.nih.gov/pmc/articles/PMC6824788/>
10. Wang JY, Su X, Li CW, Zhang ZP, Song D, et al. Acute myocardial infarction could induce aortic dissection. *Int J Cardiovasc Dis Diag*. 2017; 2: 001-003.
11. Wang D, Zhang LL, Wang ZY, Wang Y. The missed diagnosis of aortic dissection in patients with myocardial infarction: a disastrous event. *J Thoracic Dis*. 2017; 9: E636-E639.  
**PubMed:** <https://www.ncbi.nlm.nih.gov/pmc/articles/PMC5542992/>
12. Chen A, Ren X. Aortic dissection manifesting as ST-segment-elevation myocardial infarction. *Circulation*. 2015; 131: e503-e504.
13. Yunoki K, Naruko T, Itoh A, Furakawa A, Abe Y, et al. Stenting of right coronary ostial occlusion due to thrombosed type A aortic dissection: One year follow-up results. *J Cardiol Cases*. 2010; 1: e166-e170.  
**PubMed:** <https://www.ncbi.nlm.nih.gov/pmc/articles/PMC6264950/>
14. Doksoz A, Ozturk MT, Salha W, Taraktas M, Soydemir H. A case of aortic dissection complicating right subclavian artery occlusion and mimicking myocardial infarction. *Emerg Case Rep*. 2011; 8: 40-42.
15. Cardozo C, Riadh R, Mazen M. Acute myocardial infarction due to left main stem compression aortic dissection treated by direct stenting. *JIC*. 2004: 16.
16. Baydar O, Abaci O, Cetinkal G, Oktay V, Kocas C, et al. PP-227 Acute myocardial infarction due to acute aortic dissection involving the left main coronary artery. *Int J Cardiol*. 2013; 163: Suppl 1: S171.
17. Rodrigues RC, Santos N, Pereira D. Aortic dissection mimicking ST elevation myocardial infarction. *Acta Med Port*. 2017; 30: 80-80.
18. Tsigkas G, Kasimis G, Theodoropoulos K, Chouchoulis K, Balkoussis NG, et al. A successfully thrombolysed acute inferior myocardial infarction due to Type A aortic dissection with lethal consequences; the importance of early cardiac echocardiography. *J Cardiothoracic Surg*. 2011; 6: 101.  
**PubMed:** <https://pubmed.ncbi.nlm.nih.gov/21864356/>
19. Sir JJ, Kim YI, Cho WH, Choi SK. Acute myocardial infarction due to aortic dissection. *Intern Med*. 2009; 48: 173.  
**PubMed:** <https://pubmed.ncbi.nlm.nih.gov/19182429/>
20. Okamoto M, Amano T, Matsuoka S, Hirai H, Masuda K, et al. A case of acute myocardial infarction due to left main trunk occlusion complicated with acute dissection as diagnosed by intravascular ultrasound. *Cardiol Res*. 2012; 3: 232-235.  
**PubMed:** <https://www.ncbi.nlm.nih.gov/pmc/articles/PMC5358137/>
21. Kawano H, Tomichi Y, Fukae S, Koide Y, Tode G, et al. Aortic dissection associated with acute myocardial infarction and stroke found at autopsy. *Internal Med*. 45: 957-962.  
**PubMed:** <https://pubmed.ncbi.nlm.nih.gov/16974058/>
22. Gu YL, van den Heuvel AFM, Erasmus ME, Zijlstra F. Aortic dissection presenting as acute myocardial infarction potential harm of antithrombin and antiplatelet therapy. *Netherlands Heart J*. 2006; 14: 147-149.  
**PubMed:** <https://pubmed.ncbi.nlm.nih.gov/25696613/>
23. Dendramis G, Fazzari F, Paleologo C, Ascitutto S. Acute aortic dissection debut as STEMI; A case report. *J Indian Coll Cardiol*. 2014; 4: 182-185.
24. Kwon YS, Lee HS, Shin KJ, Chang BJ, Kim HS, et al. A case of left main coronary stenting for acute myocardial infarction complicated by ascending aortic dissection. *Korean Circulat J*. 2004; 34: 1210-1215.
25. Masuda Z, Murakami T, Shishido E, Kuinose M. A rare cause of dissection of ascending aorta after aortic valve replacement. *Asian Cardiovasc Thorac Ann* 2008; 16: 4-6.
26. Almanson M, Tymchak W. Aortic dissection and sudden unexpected deaths: A retrospective study of 31 forensic autopsy cases. *J Forensic Sci*. 2015.
27. Siddiqui S, Kwan CNK, Concepcion J, Malik BA, Moskovitz N, et al. A unique case of acute dissection mimicking myocardial infarction. *J Case Rep Images Med*. 2017; 3: 53-57.
28. Ahmed T, Nair R, Lak H, Lodhi SH, Maroo A. Two intriguing cases of Stanford Type A acute aortic dissection. *Cureus* 2020; 12: e6986.  
**PubMed:** <https://www.ncbi.nlm.nih.gov/pmc/articles/PMC7075513/>
29. Irvibogbe O, Mirrer B, Loarte P, Gale M, Cohen R. Thrombolytic-related complication in a case of misdiagnosed myocardial infarction. *Acute Cardiac Care*. 2014; 16: 83-87.  
**PubMed:** <https://pubmed.ncbi.nlm.nih.gov/24749992/>
30. Guner EG, Agus H, Guner A, Kalkan AK, Ertuk M. Spontaneous aortic root rupture during pregnancy. *Turk Kardiyol Dern Ars*. 2020; 48: 186.
31. Gibbs O, Faour A, Femia G, Nguyen T, Lo S. Inferior ST elevation myocardial infarction secondary to type A aortic dissection treated with percutaneous coronary intervention immediately prior to urgent ascending aortic repair. *Heart Lung Circulat*. 2018; 27: S456-S457.
32. Danbauchi SS, Ibinaiye PO, Anyiam CA, Ahlassan MA, Oyati AI. DeBakey type 1 aortic dissection presenting as inferior myocardial infarction: A case report and review of literature. *Arc Int Surg*. 2013; 3: 154-157.
33. Zschaler S, Schmidt G, Kukucka M, Syrmay G, Zschke L, et al. How to prevent inadvertent emergency anticoagulation in acute type A aortic dissection: when in doubt, don't. *Cardiovasc Diagn Ther*. 2018; 8: 805-810.  
**PubMed:** <https://www.ncbi.nlm.nih.gov/pmc/articles/PMC6331368/>
34. Massetti M, Neri E, Babatesi G, Le Page O, Sabatier R, et al. Flap suffocation: An uncommon mechanism of coronary malperfusion in acute type A dissection. *J Thoracic Cardiovascular Surg*. 2003; 125: 1548-1550.
35. Zakaria S, Desai D, Jeudy J, Thorn EM. Aortic dissection and pericardial tamponade causing compression of the pulmonary arteries in a patient with prior cardiac surgery. *J Card Surg*. 2011; 26: 316-321.
36. He X, Liu X, Li W, Gao B, Zeng H. Acute Stanford type A aortic dissection occurred simultaneously with acute myocardial infarction. *Int J Cardiol*. 2013; 189: 56-58.
37. Laine M, Grisoli D, Bonello L. An atypical case of acute myocardial infarction. *JIC*. 2011; 23: 305-306.
38. Omar AR, Goh WP, Lim YT. Peripartum acute anterior ST segment



- elevation myocardial infarction: An uncommon presentation of acute aortic dissection. *Ann Acad Med Singapore*. 2007; 36: 854-856.  
**PubMed:** <https://pubmed.ncbi.nlm.nih.gov/17987238/>
39. Fossum E, Ata B, Eritslund J, Klow NE, Mangschau A. Thoracic aortic dissection-an important differential diagnosis of chest pain and ECG changes. *Tidsskriftet Den Norske Legeforening. J Norwegian Med Assoc*. 2003; 123: 2431-2432.
  40. Tang L, Hu XQ, Zhou SH. Acute Stanford type A aortic dissection mimicking acute myocardial infarction: A hidden catastrophe which should prompt greater vigilance. *Acta Cardiol Sin*. 2014; 30: 493-496.  
**PubMed:** <https://pubmed.ncbi.nlm.nih.gov/27122825/>
  41. Cook J, Aeschlimann S, Fuh A, Kohmoto T, Chang SM. Aortic dissection presenting as concomitant and STEMI. *J Human Hypertens*. 2007; 21: 818-821.
  42. Sung LC, Kuo CH, Hou CJY, Tsai CH. Acute myocardial infarction caused by ascending aortic dissection. *Acta Cardiol Sin*. 2005; 21: 105-110.
  43. Fujiyoshi T, Koizumi N, Nishibe T, Sugiyama K, Ogino H. Direct repair of localized aortic dissection with critical malperfusion of the left main trunk. *Ann Thorac Cardiovasc Surg*. 2018; 24: 320-323.  
**PubMed:** <https://pubmed.ncbi.nlm.nih.gov/29386473/>
  44. Courand PY, Dauohin R, Roussel E, Besnard C, Lanteime P. An uncommon presentation of acute Type A aortic dissection: left main coronary artery obstruction. *Images Cardiovasc Med*. 2012; 13: 53-55.
  45. Hirata K, Wake M, Kyushima M, Takahashi T, Nakazato J, et al. Electrocardiographic changes in patients with type A aortic dissection. Incidence, patterns and underlying mechanisms in 159 cases. *J Cardiol*. 2010; 56: 147-153.  
**PubMed:** <https://pubmed.ncbi.nlm.nih.gov/20434885/>
  46. Radwan K, Peszek-Przybyla E, Gruszka A, Sonsowski M, Buszman P. Acute aortic dissection imitating ST elevation myocardial infarction with accompanying pulmonary embolism. *Cardiol J*. 2007; 14: 595-596.
  47. Ruisi M, Fallahi A, Lala M, Kanei Y. Aortic dissection presenting as acute subtotal left main coronary artery occlusion: A case approach and review of the literature. *J Clin Res*. 2015; 7: 356-360.  
**PubMed:** <https://pubmed.ncbi.nlm.nih.gov/25780485/>
  48. Kozinski L, Orzalkiewicz M, Lica-Gorzyńska M, Orzalkiewicz Z. Left main stem pulsation: easily missed angiographic phenomenon in acute aortic dissection. *European Heart J*. 2015; 36: 129.  
**PubMed:** <https://pubmed.ncbi.nlm.nih.gov/25157111/>
  49. Na SH, Youn TJ, Cho YS, Lim C, Chung WY, et al. Acute myocardial infarction caused by extension of a proximal aortic dissection flap into the right coronary artery. *Circulation*. 2006; 113: e669-e671.
  50. Ravandi A, Penny WF. Percutaneous intervention of an acute left main coronary occlusion due to dissection of the aortic root. *JACC Cardiovasc Interv*. 2011; 4: 713-715.
  51. Lentini S, Specchia L, Cricco A, Mangia F, Ignone G, et al. Hybrid management of acute type A aortic dissection presenting as acute coronary syndrome. *Int J Cardiol*. 2013; 167: e85-e87.  
**PubMed:** <https://pubmed.ncbi.nlm.nih.gov/23664702/>
  52. Treptau J, Ebnet J, Akin M, Tongers J, Bauersachs J, et al. Angiographic detection of fatal acute aortic dissection Stanford Type A under resuscitation. *Cardiol J*. 2016; 23: 620-622.  
**PubMed:** <https://pubmed.ncbi.nlm.nih.gov/27976792/>
  53. Attia T, Robichi M, Lincoff AM, Shishehbor MH, Svenson L, et al. Successful treatment of aortic root dissection complicated with extensive myocardial infarction using the total artificial heart. *J Case Rep*. 2017; 8: 1-3.
  54. Barabas M, Gosselin G, Crepeau J, Petitclerc R, Cartier R, et al. Left main stenting as a bridge to surgery for acute type A aortic dissection and anterior myocardial infarction. *Catheterisation and Cardiovascular Interventions* 2000; 51: 74-77.
  55. Wu BT, Li CY, Chen YT. Type A aortic dissection presenting with inferior DT-elevation myocardial infarction. *Acta Cardiol Sin*. 2014; 30: 248-252.  
**PubMed:** <https://www.ncbi.nlm.nih.gov/pmc/articles/PMC4804865/>
  56. Hawatmeh A, Arqoub AA, Isbitan A, Shamooun F. A case of ascending aortic dissection mimicking acute myocardial infarction and complicated with pericardial tamponade. *Cardiovasc Diagn Ther*. 2016; 6: 166-171.  
**PubMed:** <https://www.ncbi.nlm.nih.gov/pmc/articles/PMC4805766/>
  57. Erkan H, Cirakoglu OF, Erkan M. Aortic dissection flap imitating thrombus: an extremely rare angiographic presentation of myocardial infarction. *J Intervent Cardiol*. 2015; 28: 117-118.
  58. Pinney SP, Wasserman HS. Anterior myocardial infarction, acute aortic dissection, and anomalous coronary artery. *J Intervent Cardiol*. 2002; 15: 293-296.  
**PubMed:** <https://pubmed.ncbi.nlm.nih.gov/12238425/>
  59. Horszczaruk G, Roik MF, Kochman J, Bakon L, Stolarz P, et al. Aortic dissection involving ostium of right coronary artery as the reason for myocardial infarction. *Eur Heart J*. 2006; 27: 518.  
**PubMed:** <https://pubmed.ncbi.nlm.nih.gov/16243924/>
  60. Zegers ES, Gehlmann HR, Verheuger FWA. Acute myocardial infarction due to an acute type A aortic dissection involving the left main coronary artery. *Neth Heart J*. 2007; 15: 263-264.  
**PubMed:** <https://www.ncbi.nlm.nih.gov/pmc/articles/PMC1995115/>
  61. Lee CH, Lim J. Type A aortic dissection: a hidden and lethal cause for failed thrombolytic treatment in acute myocardial infarction. *Heart*. 2007; 93: 825.  
**PubMed:** <https://pubmed.ncbi.nlm.nih.gov/17569805/>
  62. Chammanphol N, Cheewatanakornkul S, Wisaratapong T. Coronary spasm due to type A aortic dissection complicated by hemopericardium: case report of another possible cause of coronary malperfusion. *Intern Med*. 2010; 49: 829-831.
  63. Lee MJ, Park YS, Ahn S, Sohn CH, Seo DW, et al. Clinical features of acute aortic dissection patients initially diagnosed with ST segment elevation myocardial infarction. *Cardiovasc*. 2016; 27: 30-35.
  64. Phowthongkum P. Acute aortic dissection mimics acute inferoposterior wall myocardial infarction in a Marfan syndrome patient. *BMJ Case Rep*. 2010.  
**PubMed:** <https://www.ncbi.nlm.nih.gov/pmc/articles/PMC3028170/>
  65. Arrivi A, Tanzilli G, Puddu PE, Truscilli G, Dominici M, et al. Acute aortic dissection mimicking STEMI in the catheterization laboratory: Early recognition is mandatory. *Case Rep Cardiol*. 2012: 367542.  
**PubMed:** <https://pubmed.ncbi.nlm.nih.gov/24826248/>
  66. Arrivi A, Tanzilli G, Tritapepe L, Mazzei G, Mangieri E. Undetected acute aortic dissection in a patient referred for primary coronary angioplasty: a successful treatment of perioperative bleeding after abciximab administration. *BMJ Case Rep*. 2010.  
**PubMed:** <https://pubmed.ncbi.nlm.nih.gov/22802278/>
  67. Ali RG, Chrissoheris MP. Lead aVR ST segment elevation in acute aortic dissection. *Connecticut Medicine* 2008; 72: 19-20.
  68. Hsu PC, Su HM, Lin TS, Huang JW, Lai WT, et al. Acute type A aortic dissection involving right coronary artery orifice in a case presenting with anterior ST elevation. *A Rare Case Rep Cardiol*. 2011; 119: 11-14.
  69. Kaya MG, Mavill E, Dogdu O, Dogan A, Inanc T, et al. Acute type A aortic dissection in a patient with ventricular septal defect. *Cardiovasc Revascularization Med*. 2010; 11: 186-188.
  70. Inoue T, Fukumoto Y, Mohri M, Inokuchi K, Hirakawa Y, et al. Wandering ST segment elevation. *Circulation*. 2003; 108: e102-e103.
  71. Huang CY, Hung YP, Lin TH, Chang SL, Lee WL, et al. Catheter directed diagnosis of ST-segment elevation myocardial infarction induced by type A aortic dissection. *Medicine*. 2020; 99: e18796.  
**PubMed:** <https://pubmed.ncbi.nlm.nih.gov/32011481/>
  72. Sadaba M, Subinas A, Rumoroso JR. STEMI with fluctuating closing



- of LAD and Cx. Do not concentrate on the finger. *Cardiovasc Revascularization Med.* 2017; 18: S35-S39.
73. Hanaki Y, Yumoto K, Seigen I, Aoki H, Fukuzawa T, et al. Coronary stenting with cardiogenic shock due to acute ascending aortic dissection. *World J Cardiol.* 2015; 26: 104-110.  
**PubMed:** <https://www.ncbi.nlm.nih.gov/pmc/articles/PMC4325300/>
  74. Szabo S, Hoffmeister HM. Aortic dissection causing 2 myocardial infarctions. *J Cardiol Cardiovasc Med.* 2019; 4: 233-235.
  75. Harlandt O, Kupper W, Rebolledo Godoy M, Frenkel C, Lankisch PG. Fatal outcome of prehospital thrombolysis in a case of aortic dissection mimicking ST segment elevation myocardial infarction. *Intensivmedizin und Notfallmedizin* 2006; 43: 219-225.
  76. Latifi AN, Ibe U. ST-elevation myocardial infarction: rare presentation of an uncommon disease. *CHEST.* 2019; 156 (4 Suppl): A1471.
  77. Ali OM, White B. Trapdoor ischemia coronary ostial occlusion by an aortic dissection. *BMJ Case Rep* 2012.
  78. Lee MJ, Park YS, Ahn S, Sohn CH, Seo DW, et al. Clinical features of acute aortic dissection patients initially diagnosis with ST-segment elevation myocardial infarction. *Cardiovascular.* 2016; 27: 30-35.
  79. Ichihashi T, Ito T, Murai S, Ikehara N, Fujita H, et al. Acute myocardial infarction due to spontaneous localized acute dissection of the sinus of Valsalva detected by intravascular ultrasound and electrocardiogram-gated computed tomography. *Heart Vessels.* 2016; 31: 1570-1573.  
**PubMed:** <https://pubmed.ncbi.nlm.nih.gov/26710761/>
  80. Nandan AY, Singh A, Negesh NM, Gandhi M. Suspected ST segment elevation myocardial infarction referred for primary angioplasty: a masquerader. *BMJ Case Rep.* 2019; 12: e227687.
  81. Kaul P. Spontaneous retrograde dissection of ascending aorta from descending thoracic aorta-a case review. *Perfusion.* 2011; 26: 215-222.
  82. Palmeira MM, Ribeiro HYU, Lira YC, Neto FOM, da Silva Rodrigues IA, et al. Aortic aneurysm with complete atrioventricular block and acute coronary syndrome. *BMC Research Notes.* 2016; 9: 257.  
**PubMed:** <https://www.ncbi.nlm.nih.gov/pmc/articles/PMC4855812/>
  83. Camaro C, Wouters NTAE, Gin MTJ, Bosker HAB. Acute myocardial infarction with cardiogenic shock in a patient with acute aortic dissection. *Am J Emerg Med.* 2009; 27: 899-899.
  84. Cai J, Cao Y, Yuan H, Yang K, Vhu YS. Inferior myocardial infarction secondary to aortic dissection associated with bicuspid aortic valve. *JCDR.* 2012; 3: 138-142.  
**PubMed:** <https://www.ncbi.nlm.nih.gov/pmc/articles/PMC3354459/>
  85. Stefanidis C, Sanoussi A, Demanet H, Castro-Rodriguez, Wauthy P. Acute myocardial infarction due to an acute aortic dissection. *Rev Med Brux.* 2011; 32: 179-181.
  86. Scott C, Burruss N, Kalimi R, Manetta F, Palazzo RS, et al. Acute ascending aortic dissection during pregnancy. *Am J Critical Care.* 2001; 10: 430.
  87. Marek D, Nemecek P, Herman M, Gwozdziwicz M, Troubil M, et al. Mistakes in dealing with aortic dissection, lessons from three warning cases. *Biomed Pap Med Fac Univ Palacky Olomouc Czech Repub.* 2008; 152: 283-287.
  88. Jaguszewski M, Widmer N, Ghadri JR, Alibegovic J, Gaemperli O, et al. Haemodynamic tracing pattern reveals acute type A aortic dissection. *Acute Cardiac Care.* 2012; 14: 94-95.
  89. Kubiak G, Gianowska G, Kubiak L, Traczewska M, Nowalany-Kozielska E. Acute aortic syndrome mimicking anterior wall ST-elevation myocardial infarction. *Kardiologia Polska.* 2013; 71: 852-854.
  90. Boulaamayi El Fatemi S. Acute aortic syndrome mimicking myocardial infarction. *Eur Heart J Cardiovasc Imaging.* 2015 (Suppl 1): 127.
  91. Guo XM, Bonde P. Ruptured pneumococcal aortic aneurysm presenting as ST-elevation myocardial infarction. *AORTA.* 2015; 3: 30-37.  
**PubMed:** <https://www.ncbi.nlm.nih.gov/pmc/articles/PMC4714936/>
  92. Chenkin J. Diagnosis of aortic dissection presenting as ST-elevation myocardial infarction using point-of-care ultrasound. *J Emerg Med.* 2017; 53: 880-884.  
**PubMed:** <https://pubmed.ncbi.nlm.nih.gov/29066079/>
  93. Abrams E, Allen A, Lahham S. Aortic dissection with subsequent hemorrhagic tamponade diagnosed with point-of-care ultrasound in a patient presenting with STEMI. *Clin Pract Cases Emerg Med.* 2019; 3: 103-106.  
**PubMed:** <https://www.ncbi.nlm.nih.gov/pmc/articles/PMC6497200/>
  94. Wang Y, Zhu Z, Xu R, Li D, Wang T, et al. A complete occlusion of right coronary artery due to Stanford Type A aortic dissection. Successful treatment with extracorporeal membrane oxygenation. *Bra J Cardiovasc Surg.* 2019; 34: 491-494.  
**PubMed:** <https://www.ncbi.nlm.nih.gov/pmc/articles/PMC6713360/>
  95. Pocar M, Passolunghi D, Moneta A, Donatelli F. Recovery of severe neurological dysfunction after restoration of cerebral blood flow in acute aortic dissection. *Interac Cardiovasc Thoracic Surg.* 2010; 10: 839-842.
  96. Ohtani N, Kiyokawa K, Asada H, Kawakami T. Stanford type A acute dissection developing acute myocardial infarction. *JJTCVS.* 2000; 48: 69-72.
  97. Ashida K, Arakawa K, Yanagishi T, Tahara T, Ayaori M, et al. A case of aortic dissection with transient ST segment elevation due to functional left main coronary artery obstruction. *Jpn Circ J.* 2000; 64: 130-134.  
**PubMed:** <https://pubmed.ncbi.nlm.nih.gov/10716527/>
  98. McBeth BD, Rosenstein DI. Acute aortic dissection with ST segment myocardial infarction following masturbation. *J Emerg Med.* 2020; 58: E193-E196.  
**PubMed:** <https://pubmed.ncbi.nlm.nih.gov/32204992/>
  99. Fernandez-Jimenez R, Vivas D, de Augustin JA, Kallmeyer A, Balbacid E, et al. Acute aortic dissection with ongoing right coronary artery and aortic valve involvement. *Int J Cardiol.* 2012; 161: e34-e36.
  100. Sherwood JT, Gill IS. Missed acute ascending aortic dissection. *J Card Surg.* 2001; 16: 86-88.
  101. Kamata S, Funatsu T, Itou Y, Yagihara T. Conservatively treated coronary malperfusion associated with acute type A dissection before aortic root replacement. *J Cardiol Cases.* 2018; 17: 36-39.  
**PubMed:** <https://www.ncbi.nlm.nih.gov/pmc/articles/PMC6149557/>
  102. Al-Wahibi K, Al-Dhuhli H, Diputado T, Alzadjali N. Acute cardiovascular emergency; missed killer in the emergency room. *Oman Med J.* 2008; 23: 112-115.  
**PubMed:** <https://www.ncbi.nlm.nih.gov/pmc/articles/PMC3282426/>
  103. Ohuchi H, Kyo S, Matsumura M, Tanabe H, Asano H, et al. Global myocardial ischaemia as a complication of Type A aortic dissection. *Jpn Circ J.* 2000; 64: 533-536.
  104. Li SW, Osman M. Thoracic aortic aneurysm (TAA)-A diagnostic dilemma in a patient with hemoptysis. *MOJEM* 2017; 2: 23-27.
  105. Beggs A, Al-Rawi H, Parfitt A. Chest pain and fleeting neurological signs. *Lancet.* 2005; 365: 1514.
  106. Thota LTD, Zononi LTS, Mells C, Auten JD. Acute proximal aortic dissection with negative D-dimer assay and normal portable chest radiograph: A Case Report. *Military Med.* 2015; 180: e164-e167.
  107. Correale M, Di Martino L, Ieva R, Di Biase M, Brunetti ND. Aortic dissection after cocaine abuse. *Clin Res Cardiol.* 2011; 100: 1129-1130.
  108. Ascione L, Accadia M, Damiano S, De Michele M, Tuccillo B. Painless acute aortic dissection presenting as echocardiographically diagnosed left ventricular outflow obstruction. *Ital Heart J.* 2002; 3: 752-754.  
**PubMed:** <https://pubmed.ncbi.nlm.nih.gov/12611129/>
  109. Ngermsritrakul T, Sathirapanya P. Type A aortic dissection presenting



- as acute ischemic stroke. Caution for thrombolytic therapy; a case report and literature review. *J Med Assoc Thai.* 2008; 91: 1302-1307.
110. Theodosios-Georgilas A, Beidekos D. Aortic dissection involving the ostium of left main coronary artery. *Hospital Chronicles* 2009; 4: 91-94.
  111. Abdelnaby M, Abada M, Elsayed A, Dawood M, Saleh Y, et al. Painless aortic dissection presented with acute paraplegia. *Int J Cardiovasc Acad.* 2019; 5: 22-24.
  112. D'Aloia A, Vizzardì E, Bugatti S, Magatelli M, Bonadei I, et al. A Type A aortic dissection mimicking an acute myocardial infarction. *Cardiol Res.* 2012; 3: 94-96.  
**PubMed:** <https://www.ncbi.nlm.nih.gov/pmc/articles/PMC5358147/>
  113. Gudivada KK, Umesh K, Sudeendrababu ARB. Complete heart block in acute aortic dissection: An unusual presentation. *Am J Med Sci.* 2018; 356: e39-e40.
  114. Alsaad AA, Odunukan OW, Patton JN. Ascending aortic dissection presented as inferior myocardial infarction: a clinical and diagnostic mimicry. *BMJ Case Rep.* 2016.
  115. Kodera S, Ikeda M, Sato K, Kushida S, Kanda J. Percutaneous coronary intervention is a useful bridge treatment for acute myocardial infarction due to acute type A aortic dissection. *Cardiovasc Interv and Ther.* 2015; 30: 61-67.
  116. Li CH, Leta R, Pons-Llado G. Myocardial hypoperfusion in acute aortic dissection. *Rev Esp Cardiol.* 2014; 67: 323.  
**PubMed:** <https://pubmed.ncbi.nlm.nih.gov/24774597/>
  117. Guvenc TS, Erer HB, Cetin R, Hasdemir H, Ihan E, et al. Acute aortic regurgitation with myocardial infarction: an important clue for aortic dissection. *J Emerg Med.* 2013; 44: e5-e8.  
**PubMed:** <https://pubmed.ncbi.nlm.nih.gov/22305147/>
  118. Tarver K, Kindler H, Lythall D. Extensive aortic dissection presenting as acute inferior myocardial infarction. *Heart.* 2007; 93:  
**PubMed:** <https://www.ncbi.nlm.nih.gov/pmc/articles/PMC2000954/>
  119. Katayama A, Uchida N, Sutoh M, Sueda T. Partial remodelling on the two sinuses for acute type A aortic dissection with right coronary arterial dissection. *Ann Vasc Dis.* 2013; 6: 666-669.
  120. Amabile N, Foin N, Girard MJ, Dabauchez M, Caussin C. Left main artery compression by haematoma following acute aortic root dissection: identification by optical coherence tomography. *European Heart J Cardiovasc Imaging.* 2016; 17: 1317.  
**PubMed:** <https://pubmed.ncbi.nlm.nih.gov/27458184/>
  121. Tomaszuk-Kazberuk A, Sobkowicz B, Lewezuk A, Prokop A, Sawicki R, et al. Silent pulmonary embolism in a patient with myocardial infarction and type B acute aortic dissection-a case report. *Adv Med Sci.* 2010; 55: 99-102.
  122. Ayrik C, Cece H, Aslon O, Karcioglu O, Yilmaz E. Seeing the invisible: painless aortic dissection in the emergency setting. *Emerg Med J.* 2006; 23:e24.  
**PubMed:** <https://www.ncbi.nlm.nih.gov/pmc/articles/PMC2464426/>
  123. Monteiro P, Vieira A, Parreira M. Aortic aneurysm dissection-diagnosis may be hard to make. *Medicina Interna.* 2009; 16: 211-215.
  124. Gomez-Polo JC, Aguilar-Navarro E, Olmos C, Rosillo S, Garcia-Diego G, et al. Atrial Septum Hematoma - Another Way to Die in Acute Aortic Dissection. *Circ J.* 2017; 81: 1370-1372.  
**PubMed:** <https://pubmed.ncbi.nlm.nih.gov/28344204/>
  125. Panneerselvam A, Dattatreya PV, Sridhar L, Prabhavathi B, Nanjappa M. ST-segment elevation in right precordial leads in acute pulmonary embolism. *J Indian Coll Cardiol.* 2011; 1: 112-114.
  126. Zhang F, Qian J, Dong L, Ge J. Multiple ST-segment elevations in anterior and inferior leads: An unusual electrocardiographic manifestation in acute pulmonary embolism. *Int J Cardiol.* 2012; 160: e18-e20.
  127. Emren SV, Arikan ME, Senoz O, Varis E, Akan E. Acute pulmonary embolism mimicking inferior myocardial infarction. *Arch Turk Soc Cardiol.* 2014; 42: 290-293.  
**PubMed:** <https://pubmed.ncbi.nlm.nih.gov/24769824/>
  128. Sadeghpour A, Alizadeasl. Can isolated ST elevation in aVR lead be a sign of acute pulmonary embolism. *Anadolu Kardiyol Derg.* 2013; 13: 286-294.
  129. Zelfani S, Manal H, Laabidi S, Wahabi A, Akeri S, et al. Pulmonary embolism mimicking acute myocardial infarction: a case report and review of the literature. *Pan African Med J.* 2019; 33: 275.  
**PubMed:** <https://www.ncbi.nlm.nih.gov/pmc/articles/PMC6814957/>
  130. Bozorgi A, Rahnamoun Z. Pulmonary thromboembolism initially mistaken for inferior STEMI. *Herz.* 2013; 38: 553-555.
  131. Beygui F, Tran H, Montalescot G. Chest pain, ST segment elevation in aVR lead, and high troponin levels. *Arc Cardiovasc Dis.* 2009; 102: 79-80.  
**PubMed:** <https://pubmed.ncbi.nlm.nih.gov/19233114/>
  132. Raghav KPS, Makkuni P, Figueredo VM. A review of electrocardiography in pulmonary embolism: Recognizing pulmonary embolus masquerading as ST elevation myocardial infarction. *Rev Cardiovasc Med.* 2011; 12: 157-163.  
**PubMed:** <https://pubmed.ncbi.nlm.nih.gov/22145193/>
  133. Budavari AI, Glenn TJ, Will KK, Askew JW, Fortuin FD. A case of simultaneous pulmonary embolism and acute myocardial infarction secondary to a previously undiagnosed patent foramen ovale. *J Hosp Med.* 2009; 4: E5-E8.  
**PubMed:** <https://pubmed.ncbi.nlm.nih.gov/19504585/>
  134. Wasek WC, Samul W, Ryczek R, Skrobowski A. Unique case of ST-Segment-elevation myocardial infarction related to paradoxical embolization and simultaneous pulmonary embolization. *Circulation.* 2015; 131: 1214-1223.
  135. Yildiz A, Bostan C, Akin F, Ozkan AA, Gurmen T. Concurrent pulmonary embolism and acute coronary syndrome with dynamic electrocardiographic changes. *Am J Emerg Med.* 2012; 30: 637.e1-4.  
**PubMed:** <https://pubmed.ncbi.nlm.nih.gov/21450430/>
  136. Goslar T, Podbregar M. Acute ECG ST-segment elevation mimicking myocardial infarction in a patient with pulmonary embolism. *Cardiovasc Ultrasound.* 2010; 8: 50.  
**PubMed:** <https://www.ncbi.nlm.nih.gov/pmc/articles/PMC3002912/>
  137. Gul EE, Nikus KC, Erdogan H, Ozdemir K. Differential diagnostic dilemma between pulmonary embolism and acute coronary syndrome. *J Arrhythmia.* 2016; 32: 160-161.  
**PubMed:** <https://www.ncbi.nlm.nih.gov/pmc/articles/PMC4823566/>
  138. Ozer N, Yorgun H, Canpolat U, Ates AH. Pulmonary embolism presenting with evolving electrocardiographic abnormalities mimicking anteroseptal myocardial infarction: a case report. *Med Princ Pract.* 2011; 20: 577-580.  
**PubMed:** <https://pubmed.ncbi.nlm.nih.gov/21986020/>
  139. Fallahi MJ, Masoompour M, Mirzaee M. Pulmonary embolism with abdominal pain and ST elevation: A Case Report. *Iran J Med Sci.* 2014; 39: 395-398.  
**PubMed:** <https://www.ncbi.nlm.nih.gov/pmc/articles/PMC4100053/>
  140. Piywaczewska M, Piotrowska-Kownacka D, Zdonczyk O, Roik M, Jankowski K, et al. Two in one: Unexpected acute pulmonary embolism detected by cardiovascular magnetic resonance in a patient with acute myocarditis. *Cardiol J.* 2017; 24: 96-97.  
**PubMed:** <https://pubmed.ncbi.nlm.nih.gov/28245048/>
  141. Abdalla A, Kelly F. STEMI-like acute pulmonary embolism, an unusual presentation. *BMJ Case Rep.* 2014; 2014: bcr2014206517.  
**PubMed:** <https://pubmed.ncbi.nlm.nih.gov/25414218/>
  142. Akgedik R, Gunayadin ZY, Yildirim BB, Dagli CE, Bektas O. What should be done in the event of simultaneous pulmonary embolism and myocardial infarction with ST elevation? *Turk Kardiyol Dern Ars.* 2015; 43: 734-738.



143. Noble J, Singh AS. Asymptomatic pulmonary embolus masquerading as acute anteroseptal myocardial infarction. *Can J Emerg Med.* 2011; 13: 62-65.
144. Navas MH, Barreda AP, Selman-Housein KH, Obregon-Santos AG, de Zayas Gaiguera YQB. Tromboembolismo pulmonario o infarto de ventriculo derecho: Dilema clinic, a proposito de un caso. *CorSalud.* 2015; 7: 243-247.
145. Motazedian P, Le May MR, Glover C, Hibbert B. A woman on her 80s with anterior ST elevation myocardial infarction and shock. *CHEST.* 2017; 151: e5-e8.  
**PubMed:** <https://pubmed.ncbi.nlm.nih.gov/28065257/>
146. Fasullo S, Paterna S, Di Pasquale P. An unusual presentation of massive pulmonary embolism mimicking septal acute myocardial infarction treated with tenecteplase. *J Thrombosis Thrombolysis.* 2009; 27: 215-219.  
**PubMed:** <https://www.ncbi.nlm.nih.gov/pmc/articles/PMC4350959/>
147. Livatidis IG, Paraschos M, Dimopoulos K. Massive pulmonary embolism with ST elevation in leads V1-V3 and successful thrombolysis with tenecteplase. *Heart.* 2004; 90: e41.  
**PubMed:** <https://www.ncbi.nlm.nih.gov/pmc/articles/PMC1768302/>
148. Montenegro FS, Barzan V, De Lorenzo AR, Pittella FJM, da Rocha ASC. ST-segment elevation in pulmonary thromboembolism. *Arq Bras Cardiol.* 2012; 99: e131-e133.
149. Wilson GT, Schaller FA. Pulmonary embolism mimicking anteroseptal acute myocardial infarction. *J Am Osteopath Assoc.* 2008; 108: 344-349.  
**PubMed:** <https://pubmed.ncbi.nlm.nih.gov/18648028/>
150. Roongsangmanoon W, Wongsoasup A, Rattanajaruskul N, Angkananard T. Acute pulmonary embolism masquerading as antroseptal myocardial infarction. *J Med Assoc Thai.* 2017; 100 Suppl 8: S221-S225.
151. Alsaidawi S, Abdalla M, Helmy T. Massive pulmonary embolism with ST elevation in the inferior leads and other interesting ECG findings. *J Biomed Graph Computing.* 2013; 3: 43-50.
152. Grant-Orser A, Ballantyne B, Haddara W. Unique ECG findings in acute pulmonary embolism STE with reciprocal changes and pathologic Q wave. *Case Rep CritCare.* 2018; 2018: 7865894.  
**PubMed:** <https://pubmed.ncbi.nlm.nih.gov/29850272/>
153. Toprak C, Avci A, Ozturkeri B, Tabakci MM, Kahveci G. PE with ST-segment elevation in leads V1-3 and AVR treated successfully by catheter directed high dose bolus thrombolytic therapy during CPR. *Am J Emerg Med.* 2014; 32: 1557 -1557.
154. Oguzhan A. Percutaneous rotational pulmonary thrombectomy. *N Engl J Med.* 2016.
155. Zhan ZQ, Wang CQ, Baranchuk A. Acute pulmonary embolism with ST segment elevation in the inferior leads. *Int J Cardiol.* 2014; 177: 718-719.
156. Barsoum EA, Bhat T, McCord DA, Lafferty J. Uncommon presentation of fatal pulmonary embolism. *Angiology.* 2013; 1: 1-2.
157. Mohammed K, Sasieta-Tello H, Badireddi S. Massive pulmonary embolism with ST elevation in leads V1-V3 and successful aspiration thrombectomy Case report and review of EKG changes in acute pulmonary embolism. *J Med Cases.* 2013; 4: 662-666.
158. Agdamag A, Krishnappa D, Benditt DG. ST-segment changes after loss of consciousness. *Circulation.* 2020; 141: 80-82.
159. Kameczura T, Rajzer M, Jankowski P, Wilinski J, Czarnaiecka D. Acute pulmonary embolism mimicking STEMI. Do the potential benefits of pulmonary artery angiography support the decision to perform the procedure? *Przegl Lek.* 2014; 71: 407-409.
160. Lu YW, Tsai YL, Chang CC, Huang PH. A potential diagnostic pitfall in acute chest pain: massive pulmonary embolism mimicking acute STEMI. *Amer J Emerg Med.* 2018; 36: 461-463.  
**PubMed:** <https://pubmed.ncbi.nlm.nih.gov/29169886/>
161. Shy BD, Gutierrez A, Strayer RJ. Bedside ultrasound to evaluate pulmonary embolism masquerading as ST elevation myocardial infarction (STEMI). *J Emerg Med.* 2015; 49: 703-704.
162. Omar HR. ST segment elevation in V1-V4 in acute pulmonary embolism: a case presentation and review of the literature. *European Heart J Acute Cardiovasc Care.* 2016; 5: 579-586.  
**PubMed:** <https://pubmed.ncbi.nlm.nih.gov/26373811/>
163. Kahyaoglu M, Alizade E, Naser A, Izgi A. Pulmonary embolism presenting with ST segment elevation in inferior leads. *Int J Cardiovasc Academy.* 2017; 3: 41-44.
164. Yeh KH, Chang HC. Massive pulmonary embolism with anterolateral ST-segment elevation electrocardiogram limitations and the role of the echocardiogram. *Amer J Emerg Med.* 2008; 26: 632 -632.
165. Nakata A, Aburadani I, Kontani K, Hirota S. Acute pericarditis following acute pulmonary thromboembolism. *Int Heart J.* 2017; 58: 1028-1033.  
**PubMed:** <https://pubmed.ncbi.nlm.nih.gov/29151495/>
166. Lee DZJ, Whittaker M, Al-Mohammed A. An unusual presentation of pulmonary embolism. *BMJ Case Rep.* 2012; 2012:bcr2012006210.  
**PubMed:** <https://pubmed.ncbi.nlm.nih.gov/22878987/>
167. Yamagami F, Mizumo A, Shirai T, Niwa K. A savage sequence: ST elevations with pulmonary embolism. *Am J Med.* 2014.
168. Velasco CE, Howard C. Trouble on both sides: Pulmonary embolism with pneumothorax. *Amer J Med.* 2017; 130: 530-533.  
**PubMed:** <https://pubmed.ncbi.nlm.nih.gov/28159603/>
169. Manne JRR. Acute ST segment elevation in a patient with massive pulmonary embolism mimicking acute left main coronary obstruction. *JACC.* 2017.
170. Pavlidis AN, Poulimenos LE, Giannakopoulos AK, Tsoukas A, Kallistratos MS, et al. Electrocardiographic changes in a patient with pulmonary embolism and septic shock. *Korean Circ J.* 2011; 41: 692–693.  
**PubMed:** <https://www.ncbi.nlm.nih.gov/pmc/articles/PMC3242029/>
171. Sheng FQ, Xu R, Xia JD, He MR. ECG patterns indicate severity of acute pulmonary embolism: Insights from serial ECG changes in a patient treated with thrombolysis. *Visual Diagnosis in Emergency Medicine.* 2017; 52: E251-E253.
172. Lin JF, Li YC, Yang PY. A case of massive pulmonary embolism with ST elevation in leads V1-V4. *Circ J.* 2009; 73: 1157-1159.  
**PubMed:** <https://pubmed.ncbi.nlm.nih.gov/19096187/>
173. Ghatak A, Alsulaimi A, Acosta YM, Ferreira A. Acute pulmonary embolism masquerading as acute myocardial infarction. *Proc (Bayl Univ Med Cent).* 2015; 28: 69-70.  
**PubMed:** <https://www.ncbi.nlm.nih.gov/pmc/articles/PMC4264717/>
174. Bhatia N, Vongooru H, Ikram S. Acute myocardial infarction and massive pulmonary embolus presenting as cardiac arrest: Initial rhythm as a diagnostic clue. *Case Rep Emer Med.* 2013; 2013: 343918.  
**PubMed:** <https://www.ncbi.nlm.nih.gov/pmc/articles/PMC3728547/>
175. Piggott Z, Jelic T. Pulmonary embolism with cardiac arrest: a STEMI patient's unexpected course. *CJEM.* 2018; S31-S36.  
**PubMed:** <https://pubmed.ncbi.nlm.nih.gov/28875864/>
176. Vanke P, Nordseth T, Loennechen JP, Mostad DH, Skjaerpe T, et al. A young woman with cardiac arrest. *Idsskrift for den Norske Laegeforening.*
177. Mohsen A, El-Kersh K. Variable ECG findings associated with pulmonary embolism. *BMJ Case Rep.* 2013; 2013: bcr2013008697.  
**PubMed:** <https://pubmed.ncbi.nlm.nih.gov/23449833/>
178. Dasa O, Ruzieh M, Ammari Z, Syed MA, Brickman KR, et al. It's a ST elevation myocardial infarction (STEMI), or is it? Massive Pulmonary Embolism Presenting as STEMI. *J Emerg Med.* 2018; 55: 125-127.  
**PubMed:** <https://pubmed.ncbi.nlm.nih.gov/29731284/>
179. Lu CR, Chen JY, Hsu CH, Chang KC, Huang SKS. Acute massive

- pulmonary embolism after radiofrequency catheter ablation. *Texas Heart Institute J.* 37: 498-499.  
**PubMed:** <https://www.ncbi.nlm.nih.gov/pmc/articles/PMC2929862/>
180. Hsieh YK, Siao FY, Chiu CC, Yen HH, Chen YL. Massive pulmonary embolism mimicking acute myocardial infarction: Successful use of extracorporeal membrane oxygenation support as bridge to diagnosis. *Heart, Lung and Circulation.* 2016; 25: e78-e80.
181. Hodkinson EC, Noad RL, Menown IBA. Massive pulmonary embolus presenting with abdominal pain. *Ulster Med J.* 2012; 81: 98.  
**PubMed:** <https://pubmed.ncbi.nlm.nih.gov/23526855/>
182. Falterman TJ, Martinez JA, Daberkow D, Weiss LD. Pulmonary embolism with ST segment elevation in leads V1 to V4: Case report and review of the literature regarding electrocardiographic changes in acute pulmonary embolism. *J Emerg Med.* 2001; 21: 255-261.  
**PubMed:** <https://pubmed.ncbi.nlm.nih.gov/11604280/>
183. Yu HH, Jeng JR. Pulseless activity in acute massive pulmonary embolism during thrombolytic therapy. *Tzu Chi Med J.* 2017; 29: 50-54.
184. Idris A, Tong A. Pulmonary embolism mimicking acute AT-segment elevation myocardial infarction. *JACC.* 2018; 71: 1241-145.
185. Bottinor W, Turlinton J, Roberts CS, Malhotra R, Jovin IS, Abbate A. Life-Saving Systemic Thrombolysis in a Patient with Massive Pulmonary Embolism and a Recent Hemorrhagic Cerebrovascular Accident. *Tex Heart Inst J.* 2014; 41: 174-176.  
**PubMed:** <https://www.ncbi.nlm.nih.gov/pmc/articles/PMC4004492/>
186. Valderrey FP, del Ojo JV, Lopez FJA, Millan EM, Cumplido MC, et al. Massive pulmonary embolism and cardiac arrest complicating a stab wound to the heart. *Injury Extra.* 2011; 42: 171-172.
187. Glancy DL. Syncope and dyspnoea and pulmonary embolism. *Am J Cardiol.* 2016; 118: 463-464.
188. Zhong-Qun Z, Chong-Guan W, Nikus KC, Sclarovsky S, Cho-Rong H. A new electrocardiogram finding for massive pulmonary embolism: ST elevation in lead aVR with ST depression in leads and V4-V6. *Am J Emerg Med.* 2013; 31: 456-456.
189. Willis SL, Welch TS, Scally JP, Bartoszek MW, Sullenberger LE, et al. Impending paradoxical embolism presenting as a pulmonary embolism, transient ischemic attack, and myocardial infarction. *CHEST.* 2007; 132: 1358-1360.  
**PubMed:** <https://pubmed.ncbi.nlm.nih.gov/17934122/>
190. Ramineni R, Daniel G. Association of a patent foramen ovale with myocardial infarction and pulmonary emboli in a peripartum woman. *Am J Med Sci.* 2010; 340: 326-328.  
**PubMed:** <https://pubmed.ncbi.nlm.nih.gov/20827172/>
191. Chen Z, Li C, Li Y, Tang H, Rao L, et al. Concomitant coronary and pulmonary embolism associated with patent foramen ovale. *Medicine.* 2017; 96: e9480.  
**PubMed:** <https://pubmed.ncbi.nlm.nih.gov/29384941/>
192. Smith JG, Koul S, Roijer A, Holmqvist J, Keussen I, et al. Acute right ventricular failure caused by concomitant coronary and pulmonary embolism: successful treatment with endovascular coronary and pulmonary thrombectomy. *Eur Heart J Cardiovasc Care.* 2013; 2: 131-136.  
**PubMed:** <https://pubmed.ncbi.nlm.nih.gov/24222822/>
193. Ferreira AR, Freitas A, Magno P, Soares AO, Abreu PF, et al. Acute coronary syndrome of paradoxical origin. *Revista Portuguesa de Cardiologia.* 2013; 32: 817-821.
194. Hayiroglu M, Bozbeyoglu E, Akyuz S, Yildiyimturk O, Bozbay M, et al. Acute myocardial infarction with concomitant pulmonary embolism as a result of patent foramen ovale. *Am J Emerg Med.* 2015; 33: 984-984.
195. Tukaye DN, Cavallazzi. Paradoxical thromboembolism/ST-elevation myocardial infarction via a patent foramen ovale in submassive pulmonary embolism following an upper extremity deep venous thrombosis: Is it time for a change in the standard of care? *Cardiol Res.* 2014; 5: 112-117.  
**PubMed:** <https://pubmed.ncbi.nlm.nih.gov/28348707/>
196. Alkhalil M, Cahill TJ, Boardaman H, Choudhury RP. Concomitant pulmonary embolism and myocardial infarction due to a paradoxical embolism across a patent foramen ovale: A case report. *Eur Heart J Case Rep.* 2017; 1: 1-4.  
**PubMed:** <https://pubmed.ncbi.nlm.nih.gov/31020069/>
197. Marcu CB, Israel DH, Donohue TJ. Paradoxical coronary embolism, extensive pulmonary embolism and deep venous thrombosis. *J Invasive Cardiol.* 2005; 17: 487-488.
198. Hline A, Malik N, Khokhar A, Affarwal R. Acute myocardial infarction caused by paradoxical embolism with concomitant pulmonary embolism. *BMJ Case Rep.* 2011; 2011: bcr0320113953.  
**PubMed:** <https://www.ncbi.nlm.nih.gov/pmc/articles/PMC4545089/>
199. Woo JS, Chung H, Kim WS, Kim W. Embolic myocardial infarction with massive pulmonary thromboembolism. *Korean Circulation J. Korean Circ J.* 2017; 47: 420-421.  
**PubMed:** <https://www.ncbi.nlm.nih.gov/pmc/articles/PMC5449539/>
200. Hakim FA, Kransdorf EP, Abudiab MM, Sweeney JP. Paradoxical coronary artery embolism: A rare cause of myocardial infarction. *Heart Views.* 2014; 15: 124-126.  
**PubMed:** <https://www.ncbi.nlm.nih.gov/pmc/articles/PMC4348985/>
201. Abecasis, Ribeiros R, Gabriel HM, Andrade MJ. Thrombus entrapment: the clue for coronary embolism. *Eur Heart J.* 35: 2971.  
**PubMed:** <https://pubmed.ncbi.nlm.nih.gov/24906617/>
202. Rivas CG, Sharma A, Arora B, Jaiswal A. Paradoxical coronary embolism in the setting of PFO. *JACC.* 2020; 75: 3165.
203. Cvetkovic D, Zivkovic V, Nokolic S. Patent foramen ovale, paradoxical embolism and fatal coronary obstruction. *Forensic Science, Medicine and Pathology.*
204. Tang L, Fang ZF, Zhou SH. Paradoxical embolism causing acute embolic events in a patient with hereditary thrombophilia. *Herz.* 2015; 40: 314-317.
205. Almeznadi FS, Mehdar AM, Sridhar K, Teefy P. ST-elevation myocardial infarction secondary to paradoxical coronary emboli in a patient with massive pulmonary embolism and essential thrombocytosis: A case report. *Int J Case Rep Images.* 2015; 6: 149-155.
206. Ediban C, Morgan DJ, Rao SV, Keren A, Deague J. Deep vein thrombosis and fatal paradoxical embolism after delayed reduction of a traumatic hip dislocation. *J TRAUMA Injury, Infection and Critical Care.* 2008; 64: 1133-1135.  
**PubMed:** <https://pubmed.ncbi.nlm.nih.gov/17413519/>
207. De Agular DL, Bezerra GN, Plens ICM, de Sousa Belem L, da Costa Lino DO. Thrombus in transit and paradoxical embolism in patient with ST-segment elevation acute coronary syndrome. *Arq Bras Cardiol: Imagem cardiovasc* 2018; 31: 283-286.
208. Onsea K, Bogaard FW, Asselbergs FW, Stella PR. Simultaneous Pulmonary, cerebral and coronary emboli. *Int J Cardiol.* 2012; 157: e18-e20.
209. Stortecky S, Cook S, Meier B. Patent foramen ovale. A culpable pathway for myocardial infarction. *JACC.* 2011; 58: 1923.  
**PubMed:** <https://pubmed.ncbi.nlm.nih.gov/22018303/>
210. Islam AS, Khaligi K, Goldstein JE, Raso J. Paradoxical embolism-Report of a case involving four organ systems. *J Emerg Med.* 2000; 19: 31-43.
211. Falcetta G, Scioti G, Barzaghi C, Bortolotti U. Pulmonary and paradoxical coronary embolism with a patent foramen ovale. *Asian Cardiovasc Thoracic Annals.* 2018; 26: 413-415.
212. Delvigne M, Vermeersch P, van den Heuvel P. Thrombus-in-transit causing paradoxical embolism in cerebral and coronary arterial circulation. *Acta Medica Belgica.* 2004; 59: 669-672.  
**PubMed:** <https://pubmed.ncbi.nlm.nih.gov/15636454/>
213. Mirachi FL, Hecker J, Kramer CM. Pulmonary embolism complicated

- by patent foramen ovale and paradoxical embolization. *J Emerg Med.* 2000; 19: 27-30.  
**PubMed:** <https://www.ncbi.nlm.nih.gov/pmc/articles/PMC3503354/>
214. Barros-Gomes S, El Sabbagh A, Eleid MF, Mankad SV. Concomitant acute stroke, pulmonary and myocardial infarction due to in-transient thrombus across a patent foramen ovale. *Echo Res Practice.* 2018; 5: 19-110.  
**PubMed:** <https://www.ncbi.nlm.nih.gov/pmc/articles/PMC6130432/>
215. Zhang HY, Zhang Y, Cao YJ., Mei LL, Zhang X, et al. Acute inferior ST elevation myocardial infarction and previous cryptogenic stroke caused by a paradoxical embolism with a concomitant pulmonary embolism. *J Geriatric Cardiol.* 2017; 14: 421-424.  
**PubMed:** <https://www.ncbi.nlm.nih.gov/pmc/articles/PMC5540877/>
216. Yee J., Kumar V., Pham A., Shaik K., Omar MStys A, et al. Simultaneous onset of deep vein thrombosis, pulmonary embolism, cerebral infarction and myocardial infarction in a patient with patent foramen ovale South Dakota. *J Med.* 2017; 70: 266-269.  
**PubMed:** <https://pubmed.ncbi.nlm.nih.gov/28813763/>
217. Rovner A, Valika AA, Kovacs A, Kates AM. Possible paradoxical embolism as a rare cause of an acute myocardial infarction. *ECHOCARDIOGRAPHY.* 2006; 23: 407-409.
218. Huang G, Pavan D, Antonini-Canterin F, Piazza R, Cassin M, et al. Thrombus in the right atrial appendage during pulmonary and paradoxical embolism: a case report. *Ital Heart J.* 2002; 3: 486-489.  
**PubMed:** <https://pubmed.ncbi.nlm.nih.gov/12407828/>
219. Lak HM., Ahmed T., Nair R., Maroo A. Simultaneous multifocal embolism in an elderly patient with patent foramen ovale: A case report. *CUREUS.* 2020; 12: e6992.  
**PubMed:** <https://www.ncbi.nlm.nih.gov/pmc/articles/PMC7077121/>
220. Hayman S, Dooris M. Paradoxical coronary embolism and tight to left shunting. *Heart Lung and Circulation.* 2015; 24: Suppl 3: S387-S388.
221. Pilgrim T, Meier B, Khattab AA, Death by patent foramen ovale in a soccer player. *J Invasive Cardiol.* 2013; 25: 162-164.  
**PubMed:** <https://pubmed.ncbi.nlm.nih.gov/27047287/>
222. Nazerian P, Mueller C, Vanni S, de Matos Soeiro A, Leidel BA, et al. Integration of transthoracic focused cardiac ultrasound in the diagnostic algorithm for suspected acute aortic syndromes. *Eur Heart J* 2019; 40: 1952-1960.
223. Dabbousseh NM, Patel J, Bergi PA. Role of echocardiography in managing acute pulmonary embolism. *Heart.* 2019; 105: 1785-1792.  
**PubMed:** <https://pubmed.ncbi.nlm.nih.gov/31439657/>
224. Berg J, Bjorck L, Dudas K, Lappas G, Rosengren A. Symptoms of a first acute myocardial infarction in women and men. *Gender Med.* 2009; 6: 454-460.  
**PubMed:** <https://pubmed.ncbi.nlm.nih.gov/19850241/>
225. Draper J, Subbiah S, Bailey R. Chambers Murmur clinic: validation of a new model for detecting heart valve disease. *Heart.* 2019; 105: 56-59.
226. Hamirani YS, Dietl CA, Voyles W, Peralta M, Begay D, et al. Acute aortic regurgitation. *Circulation.* 2102; 126: 1121-1126.
227. De Martino RR, Sen I, Huang Y, Bower TC, Oderich GS, et al. Population based assessment of the incidence of aortic dissection, intramural hematoma, and penetrating ulcer, and its associated mortality from 1995-2015. *Circulation : Cardiovascular Quality and Outcomes.* 2018; 11; e004689.  
**PubMed:** <https://pubmed.ncbi.nlm.nih.gov/30354376/>
228. Heit JA, Spencer FA, White RH. The epidemiology of venous thromboembolism. *J Thromb Thrombolysis.* 2016; 41: 3-14.  
**PubMed:** <https://pubmed.ncbi.nlm.nih.gov/26780736/>
229. Neri E, Toscano T, Papalia U, Frati G, Massetti M, et al. Proximal aortic dissection with coronary malperfusion: presentation, management, and outcome. *J Thorac Cardiovasc Surg.* 2001; 121: 552-560.  
**PubMed:** <https://pubmed.ncbi.nlm.nih.gov/11241091/>