



## **Favipiravir and Ribavirin Treatment of Epidemiologically Linked Cases of Lassa Fever**

Vanessa N. Raabe, *Emory University*  
Gerrit Kann, *Goethe University Hospital*  
[Bruce Ribner](#), *Emory University*  
Andres Morales, *Samaritan's Purse*  
[Jay Varkey](#), *Emory University*  
[Aneesh Mehta](#), *Emory University*  
[George Lyon III](#), *Emory University*  
[Sharon Vanairsdale](#), *Emory University*  
Kelly Faber, *Hospital of Hope*  
Stephan Becker, *Philipps University*

*Only first 10 authors above; see publication for full author list.*

---

**Journal Title:** Clinical Infectious Diseases

**Volume:** Volume 65, Number 5

**Publisher:** Oxford University Press (OUP): Policy B - Oxford Open Option C |  
2017-09-01, Pages 855-859

**Type of Work:** Article | Post-print: After Peer Review

**Publisher DOI:** 10.1093/cid/cix406

**Permanent URL:** <https://pid.emory.edu/ark:/25593/s6df7>

---

Final published version: <http://dx.doi.org/10.1093/cid/cix406>

### **Copyright information:**

© Author 2017.

*Accessed April 24, 2019 5:29 PM EDT*



Published in final edited form as:

*Clin Infect Dis.* 2017 September 01; 65(5): 855–859. doi:10.1093/cid/cix406.

## Favipiravir and Ribavirin Treatment of Epidemiologically Linked Cases of Lassa Fever

Vanessa N. Raabe<sup>1,a</sup>, Gerrit Kann<sup>2,a</sup>, Bruce S. Ribner<sup>1</sup>, Andres Morales<sup>3</sup>, Jay B. Varkey<sup>1</sup>, Aneesh K. Mehta<sup>1</sup>, G. Marshall Lyon<sup>1</sup>, Sharon Vanairsdale<sup>4</sup>, Kelly Faber<sup>5</sup>, Stephan Becker<sup>6</sup>, Markus Eickmann<sup>6</sup>, Thomas Strecker<sup>6</sup>, Shelley Brown<sup>7</sup>, Ketan Patel<sup>7</sup>, Philipp De Leuw<sup>2</sup>, Gundolf Schuettfort<sup>2</sup>, Christoph Stephan<sup>2</sup>, Holger Rabenau<sup>8</sup>, John D. Klena<sup>7</sup>, Pierre E. Rollin<sup>7</sup>, Anita McElroy<sup>7</sup>, Ute Ströher<sup>7</sup>, Stuart Nichol<sup>7</sup>, Colleen S. Kraft<sup>1,9,a</sup>, Timo Wolf<sup>2,a</sup>, and for the Emory Serious Communicable Diseases Unit<sup>b</sup>

<sup>1</sup>Division of Infectious Diseases, Emory University, Atlanta, Georgia

For permissions, journals.permissions@oup.com

Correspondence: C. S. Kraft, Emory University Hospital, Department of Pathology and Laboratory Medicine, 1364 Clifton Rd NE, F145C, Atlanta, GA 30322 (colleen.kraft@emory.edu).

<sup>a</sup>V. N. R., G. K., C. S. K., and T. W. contributed equally to this work.

<sup>b</sup>Members of the Emory Serious Communicable Diseases Unit are listed after the References.

### Supplementary Data

Supplementary materials are available at *Clinical Infectious Diseases* online. Consisting of data provided by the authors to benefit the reader, the posted materials are not copyedited and are the sole responsibility of the authors, so questions or comments should be addressed to the corresponding author.

### Author contributions

T. W., G. K., and C. S. K.: Treated the patient, collected data, wrote the manuscript. S. B. and M. E.: Performed virological analysis, assisted in writing the manuscript, provided discussion of results. T. S.: Performed virological analysis, analyzed data. P. L.: Treated the patient, collected data. G. S.: Treated the patient. C. S.: Treated the patient, provided discussion of the manuscript. H. R.: Assisted in sample and data collection, provided discussion of the manuscript. V. N. R.: Collected data, wrote the manuscript. A. M.: Collected data, edited the manuscript. B. S. R., J. B. V., A. K. M., G. M. L., S. V., and K. F.: Treated the patient, collected data, edited the manuscript. S. B., J. D. K., P. E. R., U. S., S. N.: Performed virological analysis, analyzed data, edited the manuscript. K. P.: Performed virological analysis, analyzed data. A. M.: Performed virological analysis, assisted in writing the manuscript, provided discussion of results.

### Disclaimer

The findings and conclusions in this report are those of the authors and do not necessarily represent the official position of the CDC.

**Potential conflicts of interest.** All authors: No reported conflicts of interest. All authors have submitted the ICMJE Form for Disclosure of Potential Conflicts of Interest. Conflicts that the editors consider relevant to the content of the manuscript have been disclosed.

### Emory Serious Communicable Diseases Unit

*SCD Unit Coordinator:* Sonia Bell. *Administration:* Catherine Maloney, Pam Cospers, Nancye Feistritz, John Lewin, Bryce Gartland, Ira Horowitz, David Pugh, Chad Ritenour, Jerry Lewis, David Hatcher, Linda Scott-Harris, Lynne Ometer, Kip Hardy, Jeff Broughton, Robert Jackson, Samantha Thomas. *Nursing:* Toni Ash, Christopher Barnes, Jamie Breedlove, Bob Bridgman, Lane Darragh, Tracey Daye, Dustin Hillis, Crystal Johnson, Julie-Ann Johnson, Danni LaFond, Courtney Lyons, Josia Mamora, Anna McCord, Samantha McDaniel, Haley Morgan, Jill Morgan, Alexander Sanchez, Marissa Simon, Jason Slabach, Kevin Tirado, Sally Watkins, Terrica Wilson, Ken Logan. *Emory Medical Labs:* Juli Buchanan, Eileen Burd, John Cardella, Brenda Eaves, Crystal Evans, Charles Hill, Doris Igwe, Karen Jenkins, Maureen Lindsey, Jordan Magee, Stacy McCarthy, Randall Powers, James Ritchie. *Pharmacy:* Jan Pack, Susan Rogers. *Emory Health and Safety:* Patricia Olinger, Kalpana Rengarajan, Scott Thomaston, Esmeralda Meyer. *Occupational Health:* Emily Beck, Paula Desroches, Cynthia Hall, Celeste Walker. *Infection Prevention:* Esther Baker, Betsy Hackman. *Environmental Services:* Jeff Broughton, Robert Jackson, Jerry Lewis. *Pastoral Care:* Robin Brown-Haithco, Faith Richardson. *Emory Faculty and Staff Assistance:* Art Krasilovsky, Clevevoya Jordan, Sue Matthews, Marilyn Hazzard Lineberger, Paula G. Gomes. *Supplies/Logistics:* Gentrice McGee, Porcia Jones. *EUH Security:* Linda Scott-Harris, James Cain, Roderick Davis, Tyrone Johnson, Tyrone Pickett, Anthony Shaw, Tenina Truesdale. *Emergency Medicine:* Alex Isakov, Sam Shartar, Wade Miles, Aaron Jamison, John Arevalo, Gail Stallings. *Communications/Media Relations:* Janet Christenbury, Vince Dollard, Melanie De Gennaro, Holly Korschun. *Nutrition:* Tom Ziegler, Daniel P. Griffith, Nisha Dave

<sup>2</sup>Department of Medicine, Infectious Diseases Unit, Goethe University Hospital, Frankfurt/Main, Germany

<sup>3</sup>Samaritan's Purse, Togo, West Africa

<sup>4</sup>Emory Healthcare, Atlanta, Georgia

<sup>5</sup>Hospital of Hope, Mango, Togo

<sup>6</sup>Institute of Virology and Germany Centre for Infectious Diseases Research (DZIF), Gießen-Marburg-Langen, Philipps University, Marburg, Germany

<sup>7</sup>US Centers for Disease Control and Prevention, Viral Special Pathogens Branch, Atlanta, Georgia

<sup>8</sup>Institute of Medical Virology, University Hospital, Frankfurt, Germany

<sup>9</sup>Department of Pathology and Laboratory Medicine, Emory University, Atlanta, Georgia

## Abstract

Two patients with Lassa fever are described who are the first human cases treated with a combination of ribavirin and favipiravir. Both patients survived but developed transaminitis and had prolonged detectable virus RNA in blood and semen, suggesting that the possibility of sexual transmission of Lassa virus should be considered.

## Keywords

Lassa; favipiravir; ribavirin; Togo

---

Lassa fever (LF), a disease endemic to West Africa caused by infection with Lassa virus (family Arenaviridae), causes an estimated 100 000–300 000 human cases annually [1]. Most cases are caused by infection from ingestion, inhalation, or direct contact with the environmental reservoir, *Mastomys natalensis* rodents; human-to-human spread is uncommon [2, 3]. Mortality among hospitalized patients ranges from 15% to 20% [1]. Treatment with ribavirin during the first 6 days of illness decreases mortality rates to 5% [4]. Favipiravir, a novel antiviral agent with broad-spectrum activity against RNA viruses, decreases levels of Lassa viremia and increases survival in animal models [5, 6]. We describe 2 cases of LF acquired via secondary spread from the same index case who survived after treatment with ribavirin and favipiravir.

The index patient was a medical worker employed at a missionary institution in Oti District, Togo. The index patient was medically evacuated to Cologne, Germany, after 2 weeks of fevers, but died approximately 10 hours after admission despite intensive care. LF was diagnosed postmortem by reverse-transcription polymerase chain reaction (RT-PCR) from a liver biopsy (Gerd Fätkenheuer, submitted).

## CLINICAL COURSE AND TREATMENT

### Patient E

Patient E is a previously healthy 33-year-old man who provided 7 days of nursing care to the index patient in Togo and developed fevers 9 days after his last contact with the index patient. A thick blood smear was positive for malaria and he received 3 days of artemether/lumefantrine. LF was suspected when his fevers persisted and he developed sore throat, retro-orbital headache, intermittent diminished hearing, diarrhea, malaise, and generalized weakness. Laboratory testing in Togo revealed leukopenia with a nadir of  $1 \times 10^9$  cells/L, thrombocytopenia of  $50 \times 10^9$  cells/L, mild transaminitis (aspartate aminotransferase 131 U/L, alanine aminotransferase 77 U/L), and creatinine of 2.3 mg/dL. Patient E received ribavirin 2 g orally once followed by 1 g every 8 hours as intravenous ribavirin was not immediately available. He was medically evacuated to the Serious Communicable Diseases Unit at Emory University Hospital in Atlanta, Georgia, on day 8. An admission blood specimen was positive for Lassa virus infection by conventional RT-PCR and retrospective quantitative (q) RT-PCR (using laboratory-developed primers LV-Tog2 F (TCACAACCTCATCGCCTCATAC) and LV-Tog2 R (AATCTGTATGACCACGCACTC) and of probe LV-Tog2 P (56-FAM/TCCATCTGT/ZEN/CCATCCCAAACCTCAACC/3IABkFQ) with a cycle threshold value (Ct) of 23.4 (Figure 1A). On admission, intravenous ribavirin 16 mg/kg every 6 hours and oral favipiravir 2000 mg once followed by 1000 mg every 12 hours were administered after emergency investigational new drug approval was obtained from the US Food and Drug Administration. On day 12, favipiravir was discontinued and ribavirin was decreased to 8 mg/kg every 8 hours as per protocol from the manufacturer. He completed his ribavirin regimen on day 15.

Initial vital signs included temperature 37.1°C, heart rate 50 beats/minute, respiratory rate 24 breaths/minute, and blood pressure 140/91 mm Hg. Examination revealed a thin, ill-appearing male with mild conjunctival pallor, oral thrush, a soft precordial systolic murmur, and mild bladder distension with suprapubic tenderness. Tests for Ebola virus, human immunodeficiency virus (HIV), and malaria were negative. The patient had fevers to a maximum of 40.4°C, which resolved on day 12, and intermittent headaches. He developed nausea, which he attributed to favipiravir. His appetite improved and his sore throat resolved on day 14. He developed painful diffuse lymphadenopathy on day 14, epididymitis between days 19 and 21 (which later correlated to semen culture positivity for Lassa), and night sweats on day 22. He was discharged on day 25. His hearing slowly improved, although subjective right-sided decreased hearing persisted for 4 months despite normal audiological testing.

### Patient F

Patient F is a mortician who prepared the index patient's corpse for repatriation 11 days after the patient's death. He was ill with mild upper respiratory tract symptoms prior to contact with the deceased patient, making the first day of symptoms due to LF difficult to clarify. Qualitative PCR for LF was ordered by the health authorities 2 days after contact with the corpse due to temperatures between 37.5°C and 38.0°C (illness day 1) with an inconclusive result (1 faint band in 1 of 3 parallel assays). His condition deteriorated over 3 days with

fevers to 38.2°C, pronounced generalized weakness, myalgia, arthralgias, headache, and nausea. Repeat qRT-PCR testing 4 days later was positive (Ct 31.0; Figure 1B), and he was transferred to the Frankfurt University High-Level Isolation unit.

Initial vital signs were temperature 38.9°C, blood pressure 145/75 mm Hg, and heart rate 77 beats/minute. Examination revealed dry mucous membranes, pharyngeal erythema with patchy white exudates, conjunctival injection, a faint macular rash on the epigastrium, and slowed rapport and speech. Diagnostic testing was negative for HIV, hepatitis B and C, influenza, and group A *Streptococcus* pharyngitis. His fevers resolved on day 7 and his myalgias and arthralgias gradually improved. He developed nonproductive coughing without chest radiographic abnormalities. His pharyngitis worsened during the first week and resolved during week 3. He was discharged on day 39 after his symptoms resolved.

He received 1000 mg of intravenous ribavirin followed by 1000 mg every 6 hours for 4 days followed by 500 mg intravenously every 8 hours for another 6 days per the World Health Organization protocol [7]. Oral favipiravir 2000-mg loading dose was administered followed by 1200 mg twice daily for 4 days. He developed atrial fibrillation 2.5 hours after initiation of favipiravir and 10.5 hours after ribavirin. Therapeutic heparin treatment was administered. Four hours after discontinuation of favipiravir and 14 hours after ribavirin dose reduction, he converted to sinus rhythm.

## LABORATORY STUDIES

For both patients, clinical laboratory support was provided as described in Supplementary Data 1 and initial molecular testing was performed as previously described [8, 9]. Patient-specific qRT-PCR assays were developed, designated LV-Tog2 for patient E and LV-Tog1 for patient F (Supplementary Data 1). Pertinent laboratory results for both patients are shown in Figures 2A and 2B, respectively. Lassa immunoglobulin M (IgM) antibodies were detected on day 13 in patient E and immunoglobulin G (IgG) antibodies were detected on day 46 in patient E and day 38 in patient F. IgM was not tested in patient F.

Cell culture by Vero cell culture for Lassa virus was positive from whole blood specimens from patient E on days 8, 9, and 11 and patient F on day 5. Lassa virus nucleic acid was detected in blood samples by qRT-PCR in patient E through day 59 (Figure 1A) with 1 exception and in patient F through day 28 (Figure 1B). Patient E had 6 positive RT-PCR assays from urine samples but virus was not isolated from urine by cell culture. Urine testing on patient F yielded 1 positive RT-PCR on day 22. Saliva RT-PCRs were intermittently positive from patient E through day 46 and pharyngeal swab RT-PCRs from patient F were positive through day 28. Three semen samples from patient E (days 15, 20, and 48) and 4 samples from patient F (days 35, 46, 82, and 103) all had detectable Lassa virus RNA by qPCR. Culture yielded Lassa virus in 1 semen sample from patient E on day 20.

## DISCUSSION

We report 2 epidemiologically linked patients with LF secondarily acquired from the same index case treated with favipiravir and ribavirin and who made full recovery. Ribavirin, the only previously described anti-LF therapy associated with reduced mortality in humans, was

initiated on day 6 (patient E) and day 5 (patient F). Favipiravir is licensed for influenza treatment in Japan and may reduce mortality in other RNA virus infections, including Ebola virus disease [10]. Favipiravir was started on day 8 (patient E) and day 5 (patient F) but was discontinued after 5 days of treatment in both patients due to nausea and worsening transaminitis. Transaminitis has been described in LF in both untreated and ribavirin-treated patients [4, 11], so it was unclear if the patients' transaminitis was due to their underlying disease vs a drug effect. In both patients, aminotransferase levels declined shortly after discontinuation of favipiravir and decreases in the ribavirin dose. Both patients also showed a decline in hemoglobin (Figure 2A and 2B) with an elevated lactate dehydrogenase and bilirubin in patient F, which may partially be explained by a toxic effect of ribavirin and metemazole. Viral copy number values declined on therapy, although given the lack of comparator patients or sufficient historical data using PCR methods, it remains unclear whether this was due to an effect of combined antiviral therapy or the normal course of Lassa viremia. The utility of combined ribavirin and favipiravir treatment for LF should be evaluated in further clinical studies.

Viral nucleic acid was detected for a prolonged period in both patients in blood (days 27 and 62) and semen (days 48 and 103). The long-term persistence of viable virus in convalescent patients in immune-privileged compartments has been described for Ebola virus in ocular and seminal fluid [12–14]. Arenavirus escape attributed to evasion of immune system antigen presentation has been shown to contribute to long-term virus excretion in natural and dead-end hosts [15]. Well-documented longitudinal molecular detection of Lassa virus in semen has not been previously published, raising the possibility that Lassa virus could be sexually transmitted.

## Supplementary Material

Refer to Web version on PubMed Central for supplementary material.

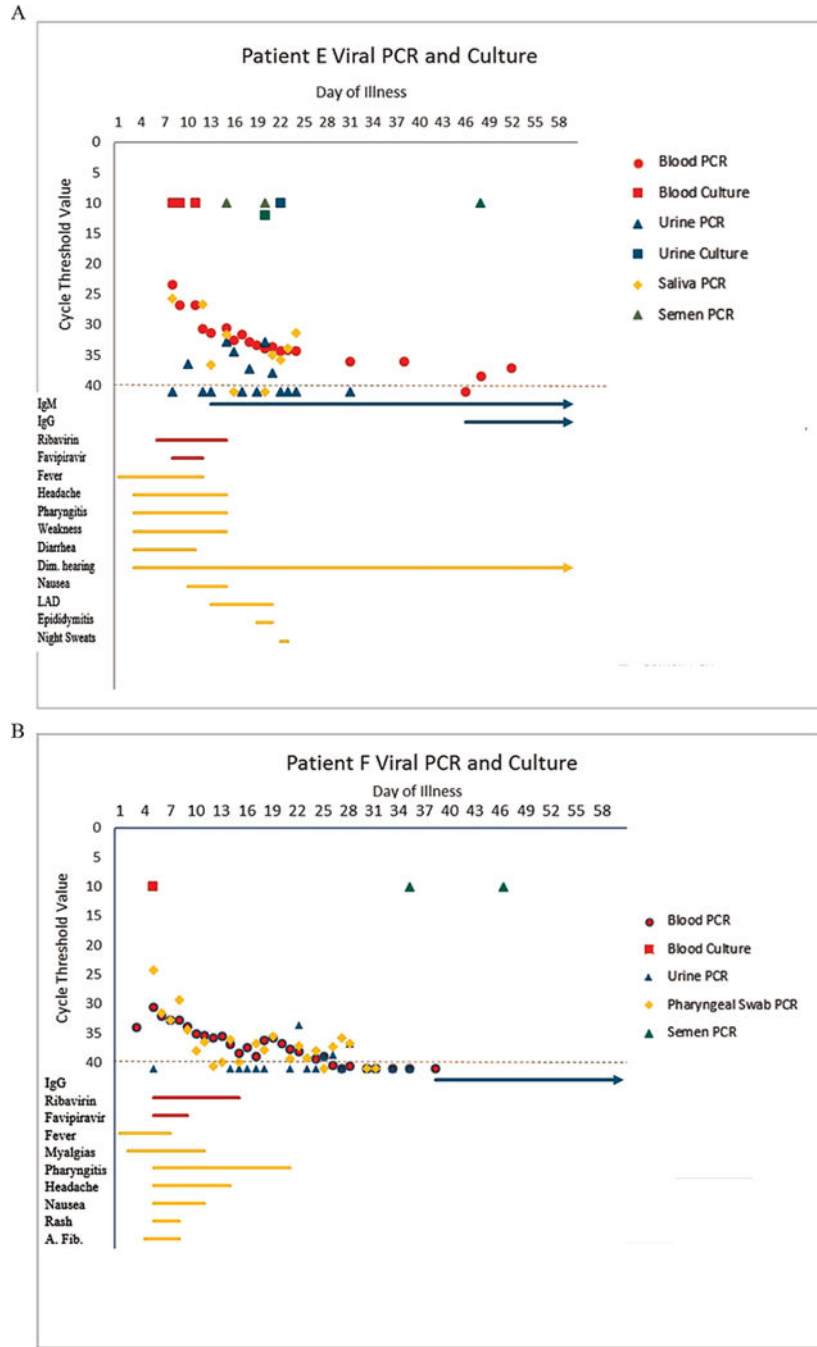
## Acknowledgments

We thank Sarah Katharina Fehling and Svenja Wolff for virus isolation work and Michael Schmidt and Gotthard Ludwig for technical support in the biosafety level 4 facility at the Philipps University of Marburg. We express our gratitude to the nursing staff of the intensive care pool and the Infectious Diseases Department, University Hospital Frankfurt. We thank Debi Cannon, Cheng-Feng Chiang, William Davis, Aridith Gibbons, James Graziano, Mary Jenks, Maria Morales-Betouille and Nishi Patel for their assistance in performance of the laboratory testing at the Centers for Disease Control and Prevention (CDC). We are appreciative of the support of the US Food and Drug Administration, Valeant, and Medivector for the provision of the therapeutics for these patients. We thank the Investigational Drug Service at Emory University and the Emory University Institutional Review Board.

## References

1. Centers for Disease Control and Prevention. Lassa fever. Available at: <https://www.cdc.gov/vhf/lassa/>. Accessed 18 March 2017.
2. Haas WH, Breuer T, Pfaff G, et al. Imported Lassa fever in Germany: surveillance and management of contact persons. *Clin Infect Dis*. 2003; 36:1254–8. [PubMed: 12746770]
3. Lo Iacono G, Cunningham AA, Fichet-Calvet E, et al. Using modelling to disentangle the relative contributions of zoonotic and anthroponotic transmission: the case of Lassa fever. *PLoS Negl Trop Dis*. 2015; 9:e3398. [PubMed: 25569707]

4. McCormick JB, King IJ, Webb PA, et al. Lassa fever. Effective therapy with ribavirin. *N Engl J Med.* 1986; 314:20–6. [PubMed: 3940312]
5. Safronetz D, Rosenke K, Westover JB, et al. The broad-spectrum antiviral favipiravir protects guinea pigs from lethal Lassa virus infection post-disease onset. *Sci Rep.* 2015; 5:14775. [PubMed: 26456301]
6. Oestereich L, Rieger T, Lüdtkke A, et al. Efficacy of favipiravir alone and in combination with ribavirin in a lethal, immunocompetent mouse model of Lassa fever. *J Infect Dis.* 2016; 213:934–8. [PubMed: 26531247]
7. World Health Organization. Communicable diseases toolkit Sierra Leone. Available at: [http://apps.who.int/iris/bitstream/10665/68741/1/WHO\\_CDS\\_2004.25\\_%28Profile%29.pdf](http://apps.who.int/iris/bitstream/10665/68741/1/WHO_CDS_2004.25_%28Profile%29.pdf). Accessed 14 June 2016.
8. Olschläger S, Lelke M, Emmerich P, et al. Improved detection of Lassa virus by reverse transcription-PCR targeting the 5' region of S RNA. *J Clin Microbiol.* 2010; 48:2009–13. [PubMed: 20351210]
9. Vieth S, Drosten C, Lenz O, et al. RT-PCR assay for detection of Lassa virus and related Old World arenaviruses targeting the L gene. *Trans R Soc Trop Med Hyg.* 2007; 101:1253–64. [PubMed: 17905372]
10. Sissoko D, Laouenan C, Folkesson E, et al. JIKI Study Group. Experimental treatment with favipiravir for Ebola virus disease (the JIKI trial): a historically controlled, single-arm proof-of-concept trial in Guinea. *PLoS Med.* 2016; 13:e1001967. [PubMed: 26930627]
11. Schmitz H, Köhler B, Laue T, et al. Monitoring of clinical and laboratory data in two cases of imported Lassa fever. *Microbes Infect.* 2002; 4:43–50. [PubMed: 11825774]
12. Varkey JB, Shantha JG, Crozier I, et al. Persistence of Ebola virus in ocular fluid during convalescence. *N Engl J Med.* 2015; 372:2423–7. [PubMed: 25950269]
13. Uyeki TM, Erickson BR, Brown S, et al. Ebola virus persistence in semen of male survivors. *Clin Infect Dis.* 2016; 62:1552–5. [PubMed: 27045122]
14. Sow MS, Etard JF, Baize S, et al. Postebogui Study Group. New evidence of long-lasting persistence of Ebola virus genetic material in semen of survivors. *J Infect Dis.* 2016; 214:1475–6. [PubMed: 27142204]
15. Schildknecht A, Welti S, Geuking MB, Hangartner L, van den Broek M. Absence of CTL responses to early viral antigens facilitates viral persistence. *J Immunol.* 2008; 180:3113–21. [PubMed: 18292534]



**Figure 1.** Patient E (A) and patient F (B): Symbols represent different samples taken from different body fluids. Filled symbols represent body fluid samples from which a viral isolate was recovered. Positive culture results and positive qualitative polymerase chain reaction (PCR) results are indicated by cycle threshold values ranging from 10 to 15. Symbols below the red bar indicate body fluid samples testing negative by PCR. The presence of immunoglobulin G, immunoglobulin M, duration of treatment, duration of symptoms, and duration of clinical examination findings are indicated by the bars underneath. Abbreviations: A. Fib, atrial



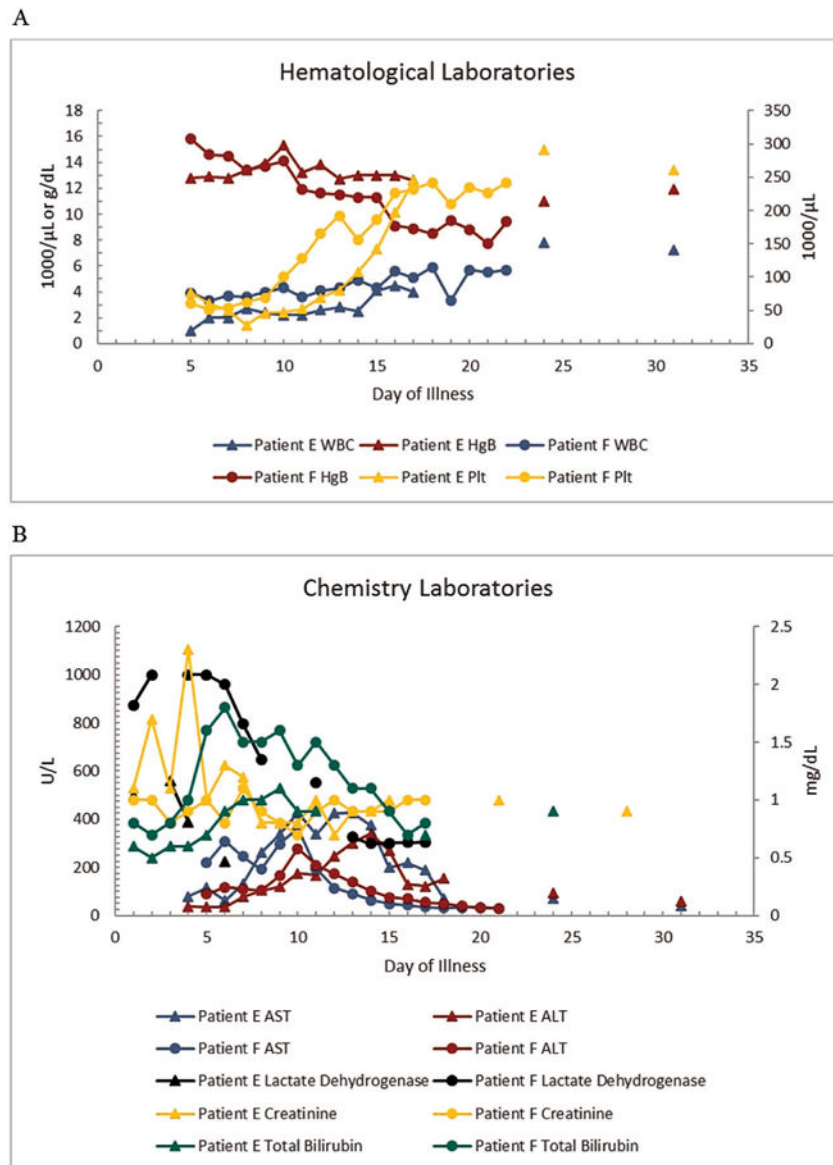
fibrillation; Dim. Hearing, diminished hearing; IgG, immunoglobulin G; IgM, immunoglobulin M; LAD, painful lymphadenopathy; PCR, polymerase chain reaction.

Author Manuscript

Author Manuscript

Author Manuscript

Author Manuscript



**Figure 2.**  
**A**, White blood cell (WBC) count, hemoglobin (Hgb), and platelet (Plt) counts for patient E (triangles) and patient F (circles). **B**, Aspartate aminotransferase (AST), alanine aminotransferase (ALT), total bilirubin, lactate dehydrogenase, and creatinine values for patient E (triangles) and patient F (circles).