

**COEXISTENCE OF CELIAC DISEASE AND SYSTEMIC LUPUS ERYTHEMATOSUS
IN A 6-YEAR-OLD GIRL-CASE REPORT**

**Geanina Irina Crișcov*, A.B. Stana, Ileana Katerina Ioniuc,
Mihaela Monica Alexoae, Evelina Moraru**

University of Medicine and Pharmacy “Grigore T. Popa”- Iași
Faculty of Medicine

Department of Mother and Child Medicine

*Corresponding author. E-mail: irinacriscov@yahoo.com

COEXISTENCE OF CELIAC DISEASE AND SYSTEMIC LUPUS ERYTHEMATOSUS IN A 6-YEAR-OLD GIRL (A CASE REPORT) (Abstract): Systemic lupus erythematosus (SLE) is a serious and potentially fatal syndrome characterized by an autoimmune assault on various organs and systems that may include the skin, joints, central nervous system, heart and kidneys. Recent research shows that gluten sensitivity causes more than just celiac disease and gluten has been linked to numerous autoimmune conditions. We report here a 6-year-old girl presenting with malaise, abdominal pain, loss of appetite, abdominal distension. After three weeks she developed other symptoms such as arthralgias, malar rash, being finally diagnosed with SLE and possible autoimmune hepatitis. The suspicion of celiac disease was based on a combination of symptoms (poor growth, iron deficiency anemia, chronic abdominal pain, abdominal distension, constipation, “sad child”), IgA deficiency, in the presence of SLE diagnosis. Positive diagnosis of celiac disease was confirmed by the presence of an anti IgG anti-transglutaminase antibodies titer of 120 EU/ml (normally less than 20 EU/ml). Small bowel biopsy showed a IIB1 stage according to the Marsh classification. Three methylprednisolone pulses were promptly administered, followed by oral prednisone (2 mg/kgbw/day) with a good outcome. **Keywords:** SYSTEMIC LUPUS ERYTHEMATOSUS, PEDIATRIC CELIAC DISEASE, AUTOIMMUNE HEPATITIS, OVERLAP SYNDROME

Systemic lupus erythematosus is an autoimmune disease characterized by auto antibodies directed against self antigens, immune complex formation and immune disturbances which may affect joints, skin, kidneys, heart, lungs, the nervous system and the immune system (1). Children generally have a more severe disease onset and progression than adults (2, 3).

The disease is more common in girls and is quite rare under the age of 6 years.

Diagnosing SLE in children is usually problematic. It was previously believed that the association between celiac disease (CD) and SLE is rare and uncertain (4). However their coexistence was proved by showing that both diseases have an autoimmune origin and share human leukocyte antigen (HLA)-B8 and histocompatibility antigen (HLA)-DR3 (5).

The manifestation of Celiac disease can occur before or after the diagnosis of lupus (6). The description of overlap syndromes

in terms of auto antibodies is based on the assumption that the pattern of autoimmunity reflects the underlying cause for the disease (7).

We present a severe case of a young patient who was diagnosed with overlap syndrome: SLE, celiac disease and hepatitis.

CASE REPORT

We report the case of a 6-year-old girl who presented with malaise and abdominal pain. She had no chronic medical conditions and no significant family history of medical illnesses. Before the onset of symptoms she was in good health but her mother complained about poor weight gain and constipation. She also had stated that her daughter was always a "sad child".

Current disease history stands ten days before admission with malaise, fatigue, pale skin, abdominal pain and loss of appetite. On physical examination, the patient was in obvious discomfort, her body temperature was 37°C, her skin was pale with discrete jaundice, nutritional status revealed a low weight for age (2 standard deviations for normal weight), her blood pressure was normal but a systolic murmur was detected. Further on, full clinical exam revealed hepatosplenomegaly, no palpable lymphadenopathies or abdominal bloating.

The laboratory testing revealed normal white blood cell (WBC) count of $6.88 \times 10^3/\mu\text{L}$, moderate anemia with red blood cells (RBC) count of $3.05 \times 10^6/\mu\text{L}$, a hematocrit of 24.9%, hemoglobin level of 7.6 g/dL and platelet counts of $320 \times 10^3/\mu\text{L}$. Aspartate aminotransferase (AST) and alanine aminotransferase (ALT) were elevated (AST=1641 U/L, ALT=1554 U/L), indirect hyperbilirubinemia at 2.03 mg/dL was also detected. Liver functional involvement syndromes revealed low fi-

brinogen values of 179 mg/dL (normal between 200-400 mg/dL), low albumin values of 37% (normal between 53.5-66.5%), elongated TQ of 21.7 seconds (normal between 13-17 seconds), hypergammaglobulinemia of 42% and no abnormal bilioexcretory syndrome. Acute and chronic liver diseases were ruled out by negative serologies for viral hepatitis A, B, C, cytomegalovirus (CMV) and Epstein-Barr virus (EBV); also human immunodeficiency virus (HIV) infection was ruled out by negative serologies. An abdominal ultrasound was performed and it showed hepato-spleno-megaly without deep lymphadenopathy.

She promptly received arginine (10mL/kgbw/day) as hepatoprotective perfusions. Meanwhile we excluded metabolic hepatitis, alpha-1-antitrypsin deficiency, Wilson's disease (ceruloplasmin, cupruria and cupremia with normal values), cystic fibrosis (iontophoresis with values of 25 mmol/L NaCl). She had a very high erythrocyte sedimentation rate (ESR) of 138mm/h and a positive C-reactive protein (CRP).

Anemia associated with indirect hyperbilirubinemia imposed investigations for a possible hemolytic anemia; reticulocytes were increased (5%), but globular resistance, autohemolysis and alkali-resistant hemoglobin were all within normal ranges. The Coombs test was positive, confirming autoimmune hemolytic anemia. We also evaluated serum iron with low values of 25 $\mu\text{mol/L}$, total iron-binding capacity (TIBC) of 455 $\mu\text{g/dL}$ (normal 228-428 $\mu\text{g/dL}$), and serum ferritin of 20 ng/mL (normal values between 13-150 ng/mL). Bone marrow aspiration and biopsy showed all three cell line elements without evidence of malignancy.

As a result of these investigations we

Coexistence of Celiac Disease and Systemic Lupus Erythematosus in a 6-Year-Old Girl

suspected an autoimmune disorder. Immunological profile revealed a positive value of antinuclear antibodies (AAN) 1 index (negative <0.7 index), the antideoxyribonucleic acid antibodies (dsDNA) positive titers, with high values of 120.4 IU/mL (negative <10), a normal complement C3 fraction 99 mg/dL (normal between 90-180 mg/dL), a negative titer of anti-LKM 1 antibodies (liver-kidney microsome) and anti-smooth muscle antibodies and absence of SLE cells and cryo-globulins.

Other immunological investigations have revealed immunoglobulin A (IgA) deficiency of 20.37mg/dL(normal 91-255 mg/dL), hyper IgG of 6824.15 mg/dL (normal 850-1300 mg/dL) and normal levels of IgM.

The result of renal function tests were in the normal range (serum urea 30 mg/dL, serum creatinine 0.72 mg/dL). No microscopic hematuria or proteinuria was detected. Also serum glucose, amylases and cholesterol were on normal range but triglycerides are elevated values of 165 mg/dL (normal 40-135 mg/dL).

During her three-week hospitalization her symptoms gradually worsened and

other important elements occurred: malar rash and arthralgia in the small joints of the hands, without local inflammatory phenomena. We performed a chest X-ray for exclusion of TB infection and an echocardiography who revealed normal structure and function of the heart with minimal presence of pericardial reaction.

Finally positive lupus diagnosis was based on 6 of the 11 required ACR criteria: "butterfly rash", arthritis, serositis (pericarditis), hematological disorder: autoimmune anemia, immunological changes as SLE cells, antideoxyribonucleic acid antibodies (dsDNA) positive titers and positive antinuclear antibodies (ANA).

Because the patient maintained unexplained abdominal distension in the context of the existence of an autoimmune disease we considered necessary to perform further investigations for other autoimmune disorder. We detected an elevated level of anti-transglutaminase IgG antibody titer of 120 EU/ml (normal less than 20 EU/ml); IgA antritransglutaminase antibodies were negative. The small bowel biopsy result revealed a IIIB1 stage according to the Marsh classification.

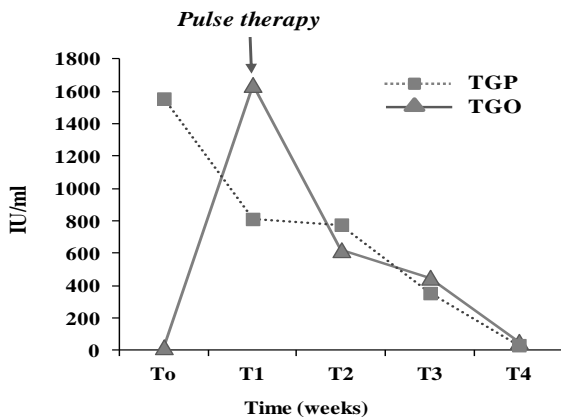


Fig. 1. Evolution of transaminases; TGO and TGP liver enzymes decreased significantly after initiating pulse therapy.

We initiated the treatment with corticosteroids, three methylprednisolone pulses (1 g/1.73 m² per day) and gluten free diet. Patient's response to steroid along with gluten-free diet was excellent, with a significant decrease of liver enzymes (TGO and TGP) (Fig. 1), ESR (26 mm/h) and improvement of Hb to 8.8 g/dL. After that she was treated with oral Prednisone (2 mg/kgbw/day).

The particularity of this case consists in the complexity onset, with accompanying hepatitis, young age and the association of other autoimmune disorders: celiac disease and hepatitis

DISCUSSION

SLE is one of the most diverse autoimmune diseases as it may affect more organs in the body. It has a broad spectrum of clinical and immunological manifestations (1, 8).

Nowadays, among people with lupus "overlapping" autoimmune conditions, including celiac disease, are common. On the other hand, according to statistics, patients diagnosed with celiac disease will be diagnosed with other autoimmune diseases in their lifetime: collagen vascular disease, type 1 diabetes, rheumatoid arthritis, Sjögren's syndrome, liver disease (2, 9).

People with celiac disease face three-times higher risk of SLE compared to the general population (10).

Celiac disease is a multifactorial, autoimmune disorder that occurs in genetically susceptible individuals. It is triggered by an environmental factor-gluten (11). Testing for CD should be performed in children with unexplained poor growth, iron deficiency anemia, chronic abdominal pain, constipation, and abnormal liver biochem-

istry, symptoms that our patient has showed (12).

Serological diagnostic based on determination of autoantibodies against transglutaminase type 2 (TG2) and endomysial antibodies (EMA) and can be confirmed by result of small bowel biopsy and HLA serotyping (11). HLA testing should be performed in cases where there is an uncertain diagnosis of CD (cases with negative CD specific antibodies and mild changes on proximal small intestinal biopsy) (4).

In our case the suspicion of celiac disease was based on combination of symptoms (poor growth, iron deficiency anemia, chronic abdominal pain, abdominal distension, constipation, "sad child"), immunological changes (IgA deficiency) and the presence of other autoimmune diseases.

It is also important to test total serum IgA to be able to interpret the IgA anti-TG2 result (as IgA deficiency is more frequent in patients with CD) and, in those individuals with IgA deficiency, IgG TG2 antibodies may be used (although these are less specific).

In our case with IgA deficiency was necessary to use IgG TG2 antibodies; it was not necessary to carry out HLA serotyping because the biopsy was conclusive.

In practice, the diagnosis of an overlap syndrome makes little difference to treatment although the detection of an autoantibody does help the clinician to anticipate particular complications (13).

Management of SLE in children is challenging (9). The unpredictability of the disease, with remissions and relapses, can be difficult for the family and child and for doctors. Corticosteroids are the mainstay of treatment (14).

Coexistence of Celiac Disease and Systemic Lupus Erythematosus in a 6-Year-Old Girl

Most of the children will also require additional medications depending on organ involvement. However, investigations and treatment should not be delayed until these criteria are fulfilled. Our patient requires careful, long-term follow-up and should adopt a gluten-free diet to avoid future complications of the condition.

REFERENCES

1. Hu W, Ren H. A meta-analysis of the association of IRF5 polymorphism with systemic lupus erythematosus. *Int J Immunogenet.* 2011; 38(5): 411-417.
2. Petty RE, Laxer RM. Systemic lupus erythematosus. In: Cassidy JT, Petty RE, Laxer RM, et al. eds. *Textbook of Pediatric Rheumatology*, 5th Ed. Philadelphia: Elsevier Saunders, 2005, 342–391.
3. Tucker LB, Menon S, Schaller JG, et al. Adult- and childhood-onset systemic lupus erythematosus: a comparison of onset, clinical features, serology, and outcome. *Br J Rheumatol* 1995; 34: 866–872.
4. Rensch MJ, Szyjowski R, Shaffer RT, et al. The prevalence of celiac disease autoantibodies in patients with systemic lupus erythematosus. *Am J Gastroenterol.* 2001; 96: 1113–1115.
5. Gupta D, Mirza N. Systemic lupus erythematosus, celiac disease and antiphospholipid antibody syndrome: a rare association. *Rheumatol Int.* 2008; 28: 1179–1180.
6. Hrycek A, Siekiera U. Coeliac disease in systemic lupus erythematosus: a case report. *Rheumatol Int.* 2008; 28: 491–493.
7. Jump up Iaccarino (Jun 2012). "Overlap connective tissue disease syndromes.". *Autoimmune Rev* 12 (3): 363–73.
8. Rahman A, Isenberg DA. Systemic lupus erythematosus. *New England Journal of Medicine* 2008; 358(9): 929–939.
9. Murphy G, Lisnevskaja L, Isenberg D. Systemic lupus erythematosus and other autoimmune rheumatic diseases: challenges to treatment. *Lancet* 2013; 382: 809-818.
10. Ludvigsson JF, Rubio-Tapia A, Chowdhary V, Murray JA, Simard JF. Increased risk of systemic lupus erythematosus in 29,000 patients with biopsy-verified celiac disease. *J Rheumatol.* 2012; 39(10): 1964-1970.
11. Husby S, Koletzko S, Korponay-Szabó IR, Mearin ML, Phillips A, Shamir R, et al. European Society for Pediatric Gastroenterology, Hepatology, and Nutrition guidelines for the diagnosis of coeliac disease. *J Pediatr Gastroenterol Nutr.* 2012; 54(1): 136-160.
12. Takeno M, Ishigatsubo Y. Intestinal manifestations in systemic lupus erythematosus. *Intern Med.* 2006; 45: 41–42.
13. Rubio-Tapia A, Kyle RA, Kaplan EL, et al. Increased prevalence and mortality in undiagnosed celiac disease. *Gastroenterology.* 2009; 137(1): 88-93.
14. Luijten RK, Fritsch-Stork RD, Bijlsma JW, Derksen RH. The use of glucocorticoids in systemic lupus erythematosus. After 60 years still more an art than science. *Autoimmun Rev* 2013; 12: 617-628.