

## Note

### Effect of ethanolic extract of *Quisqualis indica* L. flower on experimental esophagitis in albino Wistar rats

Sarita Singh<sup>1</sup>, Amit Rai<sup>1</sup>, Siddhartha Maity<sup>2</sup>,  
Srimanta Sarkar<sup>3</sup>, Sutanu Maji<sup>4</sup> & Sudipta Saha<sup>1\*</sup>

<sup>1</sup>Department of Pharmaceutical Sciences; <sup>4</sup>Department of Applied  
Plant Sciences, Babasaheb Bhimrao Ambedkar University,  
Lucknow-226 025, Uttar Pradesh, India

<sup>2</sup>Department of Pharmaceutical Technology, Jadavpur University,  
Kolkata-700 032, West Bengal, India

<sup>3</sup>Department of Pharmacy, National University of Singapore, 18,  
Science Drive 4, Singapore, 116543

Received 11 September 2015; revised 31 March 2016

*Quisqualis indica* L., Syn. *Combretum indicum* (L.) DeFilipps., known as Rangoon creeper or Chinese Honeysuckle, is an abundant source of phenols and flavonoids that have crucial role in free radical scavenging. Therefore, here we investigated whether extract of *Q. indica* flower has any role against esophagitis through scavenging of free radical oxygen species. In this study, we elucidated the effect of ethanolic flower extract of *Q. indica* on experimental esophagitis in albino Wistar rats. The fasted animals divided into six groups and received carboxymethyl cellulose (CMC) (0.25%, 3 mL/kg, Sham control) or toxic control or pantoprazole (30 mg/kg) or flower extract of different doses (100, 200 and 300 mg/kg) were subjected to pylorus and fore stomach ligation. All the animals were sacrificed after 8 h and evaluated for various parameters such as total acidity, free acidity, gastric pH, volume of gastric juices and esophagitis index. Esophageal tissues were subjected to estimation of various oxidative stress parameters like malonaldehyde (MDA), glutathione (GSH), catalase (CAT), superoxide dismutase (SOD) and protein carbonyl (PC). In a separate experiment, *in vitro* antioxidant assays such as DPPH and H<sub>2</sub>O<sub>2</sub> assays, total phenolic and flavonoid contents were also conducted. The results revealed that treatments with pantoprazole and flower extracts significantly inhibited the gastric secretion, total acidity and esophagitis index. Various oxidative stress parameters also restored to normal level in the treated groups. This action could be due to the presence of higher phenolic and flavonoid contents. All these findings collectively suggest that the flower extract of *Q. indica* possibly possess anti-esophagitis potential.

**Keywords:** Burma Creeper, Chinese Honeysuckle, Flavonoids, Gastro esophageal reflux disease, Oxidative stress, Phenols, Rangoon Creeper, Ulcer

Gastro esophageal reflux disease (GERD) is nothing but reflux of stomach content back to

esophagus resulting in mucosal damage and oxidative stress. About 10-20% of western population is reported to suffer from this disease<sup>1</sup>. Investigation suggests that GERD condition may lead to damage of mucosal and sub mucosal cells, which releases various anti-inflammatory mediators<sup>2</sup>. This biochemical process finally enumerates for various pathophysiological conditions such as irritable bowel syndrome and functional dyspepsia<sup>3</sup>.

*Quisqualis indica* L. Syn. *Combretum indicum* (L.) DeFilipps., (fam. Combretaceae), commonly known as Rangoon creeper, Chinese Honeysuckle or Madhumati<sup>4,5</sup>, native to Southeast Asia, and now broadly grown in India too as an ornamental plant<sup>6</sup>. This plant mostly used against pyrexia, staphylococcal and helminth infection is also known to possess antidiarrhoeal<sup>7</sup>, anti-inflammatory, antiseptic and immunomodulatory activities<sup>8</sup>. Sahu *et al.* suggested that the flowers of *Q. indica* are rich in flavonoids and phenols<sup>9</sup> and they have important role in free radical scavenging activity. As the flower contains these polar compounds in higher amounts, we hypothesized that the flower might be active against GERD via scavenging of free radical oxygen species generated from esophageal site. In this context, we explored if ethanolic extract of *Q. indica* flower had any significant effect on GERD.

### Materials and Methods

#### Plant material and preparation of extract

The fresh flowers of *Q. indica* were collected during the month of July from Lucknow, Uttar Pradesh, India and authenticated by Department of Horticulture, Babasaheb Bhimrao Ambedkar University (A Central University), Lucknow, India. A voucher specimen has been deposited for future reference (45/SM/DAPS/BBAU/14). The plant materials (200 g) were air dried under shade, powdered and extracted with ethanol (1.0 L) using soxhlet apparatus by successive solvent extraction method for three consecutive days. Finally, the extracted samples were evaporated to dryness using rotary vacuum evaporator (IKA, Germany). The final yield was 13.5%.

#### Experimental animals

Albino Wistar rats (90-140 g) were purchased from Animal House, CDRI, Lucknow and were kept

\*Correspondence:

Phone: +91 8090747008

E-mail: sudiptapharm@gmail.com

in polypropylene cages under standard conditions of temperature ( $25\pm 1^\circ\text{C}$ ) with 12 h light/dark cycle, free access to commercial pellet diet and water *ad libitum*. All the rats were transferred to the laboratory one week before the experiment in order to acclimatize them in the laboratory conditions. Animals were randomized and divided into six groups with six animals in each group. The experimental protocol was approved by Institutional Animal Ethical Committee (Ref. No. is UIP/IAEC/2014/FEB/15).

#### Induction of esophagitis by pylorus ligation

Six (n=6) groups of rats fasted for 24 h were received carboxymethyl cellulose (CMC) as Sham control or toxic control (0.25% CMC, 3ml/kg, orally) or plant extracts (100, 200, 300 mL/kg, orally, for 7 days) or pantoprazole (30 mg/kg, orally, in single dose). Next day, coeliotomy was performed using thiopentone sodium anesthesia (50 mg/kg, intraperitoneally). The abdomen of the animal was opened by midline incision about 2 cm and esophagitis was induced by ligating the fore stomach and corpus with silk suture. The incised regions were sutured and the animals were kept in recovery chamber and returned to their home cages<sup>10</sup>. The animals were finally sacrificed by cervical dislocation after 6 h and stomach was opened along the greater curvature and esophagus was removed by extending the dissection line of the major axis to determine the esophagitis index as described for "ulcer index" under the section "Gastric secretion in pylorus ligated rats"<sup>11</sup>. The number of ulcer is noted and the severity of esophagitis was recorded and calculated with the following scores: 0 = no ulcers. 1=superficial ulcers (with erosion of <1 mm), 2=deep ulcers (erosion 1-2 mm); and 3=perforation (erosion >2 mm).

The sum of scores was divided by a factor of ten which was designated as the esophagitis index<sup>12</sup>. The volume of gastric juice was measured as described subsequently under "Gastric secretion in pylorus ligated rats"<sup>12</sup>. The pH measurement of gastric juice was done using a pH meter. Total acidity, free acidity and volume of gastric juice were also measured during the experiment.

#### Estimation of free radical generation and scanning electron microscopy (SEM) of esophageal tissues

Esophageal tissue was homogenized in ice-cold 0.01 (M) Tris-HCl buffer, pH 7.4 and subjected to estimation of tissue glutathione (GSH)<sup>13</sup>, malonaldehyde (MDA)<sup>14</sup>, catalase (CAT)<sup>15</sup>, superoxide dismutase (SOD)<sup>14</sup> and protein carbonyl (PC)<sup>16</sup>. Later,

SEM analysis of the tissue was performed using the method as described previously<sup>17</sup>.

#### Free radical scavenging assay and total phenolic and flavonoids contents

Free radical scavenging assays like 1,1-diphenyl-2-picrylhydrazine (DPPH) and hydrogen peroxide ( $\text{H}_2\text{O}_2$ ) assays were performed by the method as described previously<sup>18,19</sup>. Total phenolic and flavonoid contents were also measured in our study<sup>20,21</sup>.

#### Statistical analysis

Statistical analysis was carried out using GraphPad Prism 5.0 (Graph Pad Software, San Diego, CA). All results were expressed as Mean  $\pm$  Standard deviation (SD). The data were analyzed by one-way ANOVA followed by Bonferroni multiple comparison test. For biochemical estimations, statistical significance differences were considered with respect to toxic control (<sup>a</sup> $P < 0.05$ , <sup>b</sup> $P < 0.01$ , <sup>c</sup> $P < 0.001$ ).

## Results and Discussion

GERD is a condition when stomach reflux to the esophagus, leading to various pathological symptoms like heartburn and regurgitation accompanied by other complications. When the laryngopharyngeal mucosa is damaged by excessive stomach contents, a different condition known as laryngopharyngeal reflux (LPR) arises. It appears that LPR would be the extension of GERD<sup>22</sup>. Oral administration of *Q. indica* flower extract significantly inhibited the esophagitis in a dose dependent manner. Ulcer was observed in esophageal region in toxic control group. However, *Q. indica* flower extract decreased the total acidity, gastric juice secretion, esophagitis index and raised the gastric pH as compared to toxic control.

#### Determination of pH, total and free acidity and esophagitis index

Necrosis and ulceration in the esophagus was found in all animals, which was also prominent during microscopic observation. Oral administration of *Q. indica* extract (100, 200, 300 mg/kg) significantly reduced the esophagitis in a dose dependent manner. *Q. indica* (300 mg/kg) reduced the esophagitis index (25%), gastric volume (52.98%), and total acidity (48.18 %) as compared to normal control (Table 1). *Q. indica* extract inhibited the esophagitis index, decreases the volume of gastric juices, total acidity and increases the gastric pH, which suggested that ethanolic extract of *Q. indica* are active against esophagitis.

### Estimation of free radical generation of esophageal tissues

Although, extract reduced the secretion of acid and increased the pH of gastric juice, it was necessary to investigate the mechanism of action of *Q. indica* extract. Therefore, we performed various biochemical parameters (GSH, MDA, SOD, CAT and PC) to observe mechanism of action.

Recent investigation described elaborately about the important role of free radicals for esophagitis condition in experimental animals<sup>23</sup>. MDA has been reported to increase during reflux esophagitis, which is the indicator of oxidative stress damage and marker of esophageal membrane damage<sup>24</sup>. Membrane damage during oxidative stress leads to the formation of MDA which forms complex with thiobarbituric acid. Higher formation of MDA in toxic control

represented that reactive oxygen species (ROS) and oxidative stress played an important role in GERD. This formation was inhibited during oral administration of *Q. indica* extract (Table 2). This was an indirect indication that extract reduced the release of free radicals; however, it was necessary to perform other oxidative stress parameters to check the mechanism of action of the flower extract.

Therefore, we measured tissue GSH level where we observed that GSH level was recovered to normal level after oral administration of *Q. indica* flower extract at a dose of 300 mg/kg bw (Table 2). GSH is a tripeptide which is most abundant in all tissues including liver. GSH plays a major role in the oxidation-reduction process, resulting in the formation of disulfide glutathione (GSSG) during

Table 1—Effect of *Quisqualis indica* flower extract on pH, volume of gastric juice, total acidity, free acidity and esophagitis index on experimental esophagitis in albino rats

Groups	Treatment	pH	Volume of gastric juices(ml)	Total acidity (mEq/L)	Free acidity (mEq/L)	Esophagitis Index
I	Sham control (3 mL/kg, orally)	3.16±0.14	0.96±0.16	28.24±0.70	24.91±1.49	0.58±0.14
II	Toxic control (3 mL/kg, orally)	3.30±0.24	1.38±0.17	63.88±1.0	51.74±1.46	0.88±0.21
III	Pantoprazole (30 mg/kg, orally)	3.14±0.48	0.98±0.14 28.98 %	36.82±2.04 42.36%	32.27±1.62	0.70±0.10 20.45%
IV	Plant extract (100 mg/kg, orally)	2.54±0.30	0.96±0.16 30.43%	42.00±3.05 34.25%	38.62±1.32	0.96±0.11 9.09%
V	Plant extract (200 mg/kg, orally)	2.96±0.39	0.76±0.26 44.92%	36.76±1.73 42.45%	32.37±2.27	0.84±0.26 4.45%
VI	Plant extract (300 mg/kg, orally)	3.12±0.17 <sup>a</sup>	0.65±0.11 52.98%	33.10±1.59 48.18 %	30.30±2.42	0.66±0.16 25%

Each group contains six animals (n=6). All data are presented as mean ± SD. [Statistical significance data was observed between toxic control and test groups (one way-ANOVA followed by Bonferroni Multiple Comparison Test). (a)  $P < 0.05$ , (b)  $P < 0.01$ , (c)  $P < 0.001$ ].

Table 2—Effect of *Quisqualis indica* flower extract in esophageal tissues. [Various biochemical parameters like PC, TBARS, SOD, CAT and GSH were measured during the experiment]

Groups	Treatment	PC (µg/mg of protein)	MDA (nm of MDA/mg of protein)	SOD (unit of SOD/mg of protein)	CAT (nm at H <sub>2</sub> O <sub>2</sub> /min/mg of protein)	GSH (µM/mg of protein)
I	Sham control (3 mL/kg, orally)	0.35±0.06	1.23±0.04	0.98±0.05	15.34±0.32	1.63±0.04
II	Toxic control (3 mL/kg, orally)	0.62±0.05	2.68±0.02	0.54±0.04	6.73±0.10	0.87±0.03
III	Pantoprazole (30 mg/kg, orally)	0.48±0.04 <sup>b</sup>	1.04±0.08 <sup>c</sup>	1.1±0.04 <sup>c</sup>	20.89±0.24 <sup>c</sup>	1.67±0.08
IV	Plant extract (100 mg/kg, orally)	0.52±0.01 <sup>c</sup>	1.55±0.07 <sup>c</sup>	0.76±0.01 <sup>c</sup>	11.34±0.40 <sup>c</sup>	1.31±0.04 <sup>c</sup>
V	Plant extract (200 mg/kg, orally)	0.54±0.06 <sup>c</sup>	1.34±0.11 <sup>b</sup>	0.83±0.02 <sup>c</sup>	13.89±0.59 <sup>c</sup>	1.46±0.04 <sup>c</sup>
VI	Plant extract (300 mg/kg, orally)	0.34±0.05	0.85±0.04 <sup>c</sup>	0.95±0.02 <sup>a</sup>	17.66±0.48 <sup>c</sup>	1.60±0.03

Each group contains six animals (n=6). All data are presented as mean ± SD. [Statistical significance data was observed between toxic control and test groups (one way-ANOVA followed by Bonferroni Multiple Comparison Test). (a)  $P < 0.05$ , (b)  $P < 0.01$ , (c)  $P < 0.001$ ].

oxidative damage<sup>25</sup>. Increase of GSH level by *Q. indica* extract was an indication of protective effect against oxidative stress induced damage. Decrease in the levels of GSH in toxic control represented the higher utilization of GSH during oxidative damage, which was completely restored during oral administration of extract.

To prove the protective effect against oxidative damage, the tissue PC levels were also measured. The carboxyl group of protein becomes oxidized by ROS and converted to PC, which is an important marker for oxidative stress<sup>26</sup>. As depicted in Table 2, toxic control groups formed more PC, which was recovered to normal level at 300 mg/kg dose of *Q. indica* flower extract, indicating protective action against oxidative stress induced damage during esophagitis.

In order to support the protective action against oxidative stress induced damage, we measured both CAT and SOD enzyme levels in infected tissue. The enzyme CAT is also most abundant in liver which catalyses the conversion of H<sub>2</sub>O<sub>2</sub> to oxygen and water. This enzyme action is reduced due to the presence of peroxides and ROS<sup>14,27,28</sup>. H<sub>2</sub>O<sub>2</sub> levels were measured and values were compared among various treated groups. Increase in concentration of H<sub>2</sub>O<sub>2</sub> in the extract treated groups depicted that there was a higher amount of CAT enzyme available in the tissue to decompose the H<sub>2</sub>O<sub>2</sub> with respect to toxic control. This assay indirectly indicated that oral administration of extract increased the level of CAT enzyme in infected esophagus (Table 2). Separately, the estimation of SOD levels in infected tissue was performed. SOD is a free radical scavenging enzyme, which neutralizes superoxide free radical in normal physiological situations<sup>27</sup>. Again, SOD levels were also decreased among the toxic control groups but this enzyme level became normal to *Q. indica* treated groups (Table 2). Therefore, it might be concluded that *Q. indica* flower extract is active against esophagitis via inhibiting the release of ROS.

#### Scanning electron microscopy (SEM) of esophageal tissues

SEM analysis also supported our hypothesis, and we observed the presence of lesions in toxic control group which was absent in extract treated groups (Fig. 1).

#### Free radical scavenging assay and total phenolic and flavonoids contents

It was also necessary to know the actual compound which is active against esophagitis. Previous studies revealed that flavonoid and phenolic compounds from natural origin had good antioxidant properties due to free radical scavenging actions<sup>29-32</sup>. Therefore, the

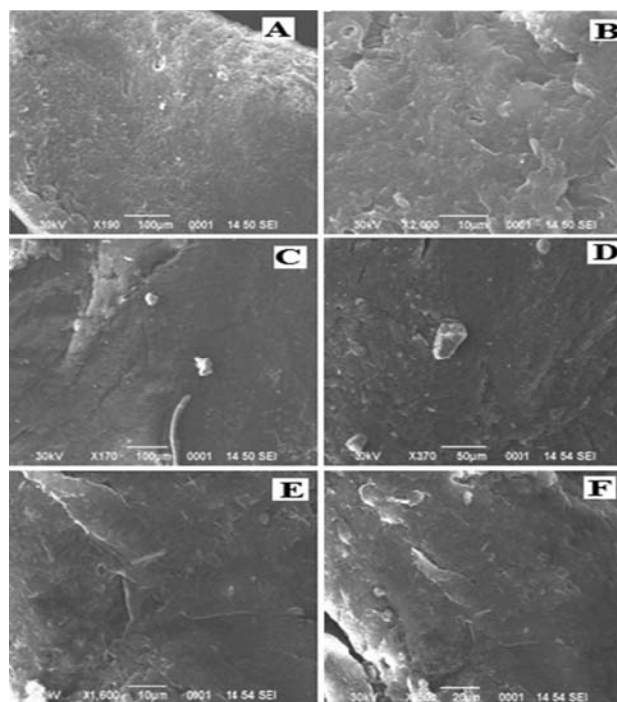


Fig. 1—Scanning Electron Microscopic (SEM) photomicrographs of the esophageal tissues (A) Sham Control; (B) Toxic Control; (C) Pantoprazole (30 mg/kg); (D) *Q. indica* (100 mg/kg); (E) *Q. indica* (200 mg/kg); and (F) *Q. indica* (300 mg/kg). [Lesion was found in toxic control that was completely removed in both pentoprazole and test groups]

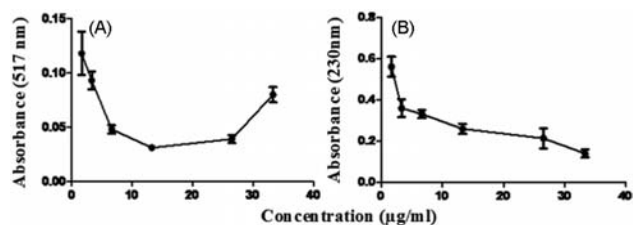


Fig. 2—(A) DPPH and (B) H<sub>2</sub>O<sub>2</sub> scavenging activity of *Q. indica* flower extract. [Ascorbic acid was used as reference standard (data not shown). Both compounds scavenged free radicals in a dose dependent manner]

question arose whether free radical scavenging action of *Q. indica* flower extract might be due to presence of flavonoid and phenolic contents. We estimated both contents in *Q. indica* flower extract and found that the concentration of both these contents were about 50 mg/g of extract. The total phenolic content (in terms of gallic acid (GA) equivalent) was 55.85±1.74 mg of GA/g of extract; and the total flavonoid content (in terms of rutin (RU) equivalent) was 47.28±2.52 mg of RU/g of extract. Later, various free radical scavenging assays like DPPH and H<sub>2</sub>O<sub>2</sub> of *Q. indica* flower extract were also performed *in vitro* and we found that the extract scavenged free radicals in a dose dependent manner (Fig. 2).

## Conclusions

Our results have shown that alcoholic extract of *Q. indica* flower is active against esophagitis via inhibition of ROS and free radicals. It normalized pH, total acidity of esophageal content and increased the levels of SOD, CAT and GSH whereas decreased TBARS and PC concentrations. The SEM analysis also supported the protective action of *Q. indica* flower extract on esophageal tissue and this action may be due to the presence of higher content of phenols and flavonoids.

## References

- Dent J, El-Serag HB, Wallander MA & Johansson S, Epidemiology of gastro-esophageal reflux disease: a systematic review. *Gut*, 54 (2005) 710.
- Souza RF, Huo X, Mittal V, Schuler CM, Carmack SW, Zhang HY, Zhang X, Yu C, Hormi-Carver K, Genta RM & Spechler SJ, Gastroesophageal reflux might cause esophagitis through a cytokine-mediated mechanism rather than caustic acid injury. *Gastroenterology*, 137 (2009)1776.
- Kin DS, Tertychnyy A, De-hertogh G, Geboes K & Tack J, Intestinal immune activation in presumed post-infectious functional dyspepsia. *Neurogastroent Motil*, 21 (2009) 832.
- The Plant list 2013. <http://www.theplantlist.org/tpl1.1/record/kew-2868686>. As accessed on 29 January 2017.
- Mandal J, *In vitro* regeneration of Rangoon creeper (*Quisqualis indica* Linn.) *Indian J Biotechnol*, 12 (2013) 415.
- Joshi SG, in *Medicinal plants* (Oxford and I.B.H. publishing Co Pvt. Ltd, New Delhi, India) 2002, 141.
- Singh N, Mohan G, Sharma RK & Gnaneshwari D, Evaluation of anti diarrhoeal activity of *Quisqualis indica* L. leaves. *Indian J Nat Prod Resour*, 4 (2013) 155.
- Sahu J, Patel PK & Dubey B, *Quisqualis indica* Linn: A Review of its Medicinal Properties. *Int. J Pharm. Phytopharm. Res.*, 1 (2012) 313.
- Sahu J, Patel PK & Dubey B, Effects of methanolic extracts of *Quisqualis indica* (aerial parts) on passive smoking induced hyperlipidemia in rats. *Asian J Pharm Technol*, 3 (2013) 26.
- Rao CV & Kumar VM, Effect of quercetin, flavonoid and alpha-tocopherol, an antioxidant vitamin on experimental reflux oesophagitis in rats. *Eur J Pharmacol*, 589 (2008) 233.
- Renu R, Kaithwas G, Ramteke PW & Saraf SA, Effect of *Linum usitatissimum* fixed oil on experimental esophagitis in rats, *Acta Gastroenterol. Belg.* 75 (2012) 331.
- Kaithwas G & Majumdar DK, Evaluation of antiulcer and antisecretory potential of *L. usitatissimum* fixed oil and possible mechanism of action. *Inflammopharmacol*, 18 (2010) 137.
- Saha S, New LS, Ho HK, Chui WK, Chan ECY. Investigation of the role of the thiazolidinedione ring of troglitazone in inducing Hepatotoxicity. *Toxicol Lett*, 192 (2010) 141.
- Lodhi RL, Maity S, Kumar P, Saraf SA, Kaithwas G & Saha S, Evaluation of mechanism of hepatotoxicity of leflunomide using albino wistar rats. *Afr J Pharm Pharmacol*, 7 (2013) 1625.
- Claiborne A, Catalase activity, in *Hand Book of Methods for Oxygen Radical Research* (CRC Press, Boca Raton, USA) 1985, 283.
- Saha S, Chan DSZ, Lee CY, Wong W, New LS, Chui WK, Yap CW, Chan ECY & Ho HK, Pyrrolidinediones reduce the toxicity of thiazolidinediones and modify their anti-diabetic and anti-cancer properties. *European J Pharmacol* 697 (2012) 13.
- Shukla K, Raj P, Kumar A, Kumar M & Kaithwas G, Effect of Monotherapy and Combination Therapy of Pantoprazole and Aprepitant in Gastric Esophageal Reflux Disease in Albino Rats. *Scient World J*, 2014 Article ID 183147.
- Gawron-Gzella A, Dudek-Makuch M & Matlawska I, DPPH radical scavenging activity and phenolic compound content in different leaf extracts from selected blackberry species. *Acta Biol Cracov Ser Bot*, 54 (2012) 32.
- Corpuz MJAT, Osi MO & Santiago LA, Free radical scavenging activity of *Sargassum siliquosum*. *Int Food Res J*, 20 (2013) 291.
- Singleton VL, Orthofer R & Lamuela-Raventos RM, Analysis of total phenols and other oxidation substrates and antioxidants by means of folin-ciocalteu reagent. *Meth. Enzymol.* 299 (1999)152.
- Quettier DC, Gressier B, Vasseur J, Dine T, Brunet C, Luyckx MC, Cazinc M, Cazinc J, Bailleulb F & Trotinb F, Phenolic compounds and antioxidant activities of buckwheat (*Fagopyrum esculentum moench*) hulls and flour. *J Ethnopharmacol*, 72 (2000) 35.
- Hopkins C, Yousaf U & Pedersen M, Acid reflux treatment for hoarseness. *Cochrane Database Syst Rev*, 25 (2006) 1.
- Das A, Chaudhuri D, Ghate NB, Panja S, Chatterjee A & Mandal N, Protective effect of *Clerodendrum colebrookianum* leaves against iron-induced oxidative stress and hepatotoxicity in Swiss albino mice. *Indian J Exp Biol*, 53 (2015) 281.
- Yusuf S, Nok AJ, Ameh DA, Adelaiye AB & Balogun EO, Quantitative changes in gastric mucosal glycoproteins: effect of cholinergic agonist and vagal nerve stimulation in the rat. *Neurogastroenterol Motil*, 16 (2004) 613.
- Saha S. Hepatotoxicity of thiazolidinedione antidiabetic drugs: A structural toxicity relationship studies, National University of Singapore, Ph.D thesis (2010).
- Suzuki YJ, Carini M & Butterfield DA, Protein Carbonylation. *Antioxid Redox Signal*, 12 (2010) 325.
- Karaman A, Iraz M, Kirimlioglu H, Karadag N, Tas E & Fadillioglu E, Hepatic damage in biliary obstructed rats is ameliorated by leflunomide treatment. *Pediatr Surg Int*, 22 (2006) 701.
- Bhadada SV & Goyal RK, Effect of flavonoid rich fraction of *Tephrosia purpurea* (Linn.) Pers. on complications associated with streptozotocin-induced type I diabetes mellitus. *Indian J Exp Biol*, 54 (2016) 457.
- Pietta PG, Flavonoids as antioxidants. *J Nat Prod*, 63 (2000) 1035.
- Beer D, Joubert E, Gelderblom WCA & Manley M, Phenolic Compounds: A review of their possible role as *in vivo* antioxidants of wine. *S Afr J Enol Vitic*, 23 (2002) 48.
- Bouaziz-Ketata H, Zouari N, Ben-Salah H, Rafrafi M & Zeghal N, Flavonoid profile and antioxidant activities of methanolic extract of *Hyparrhenia hirta* (L.) Stapf. *Indian J Exp Biol*, 53 (2015) 208.
- Nile SH & Park SW. Determination of polyphenols and antioxidant activity of *Vitis labrusca* cv. baile berries. *Indian J Exp Biol*, 53 (2015) 671.