



Original articles

Preliminary report on the International Conference for the Development of Standards for the Treatment of Anorectal Malformations

Alexander Holschneider^{a,*}, John Hutson^b, Albert Peña^c, Elhamy Bekhit^d, Subir Chatterjee^e, Arnold Coran^f, Michael Davies^g, Keith Georgeson^h, Jay Grosfeldⁱ, Devendra Gupta^j, Naomi Iwai^k, Dieter Kluth^l, Giuseppe Martucciello^m, Samuel Mooreⁿ, Risto Rintala^o, E. Durham Smith^p, D.V. Sripathi^q, Douglas Stephens^r, Sudipta Sen^s, Benno Ure^t, Sabine Grasshoff^u, Thomas Boemers^v, Feilin Murphy^w, Yunus Söylet^x, Martin Dübbers^y, Marc Kunst^y

^aDepartment of Surgery, Kinderkrankenhaus of the City of Cologne, Amsterdamerstr. 59, 50735 Cologne, Germany

^bDepartment of General Surgery Royal Children's Hospital, Melbourne, Parkville, 3052, Australia

^cDivision of Pediatric Surgery, The Colorectal Center for Children, Cincinnati Children's Hospital, ML 2023, Cincinnati, OH 45229, USA

^dMedical Imaging Department, Royal Children's Hospital, Melbourne, Parkville 3052, Australia

^ePark Clinic, Kolkata 700.017, India

^fMott Children's Hospital, Ann Arbor, MI 48109

^gRed Cross Memorial Hospital, Cape Town, South Africa

^hChildren's Hospital of Alabama, Birmingham, AL 35233

ⁱRiley Children's Hospital, Indianapolis, IN 46202

^jAll India Institute of Medical Sciences, New Delhi, 110029, India

^kKyoto Prefectural University, Kyoto 602-8566, Japan

^lUniversitätsklinikum Eppendorf, Hamburg 20246, Germany

^mDepartment of Pediatric Surgery, University Pavia, Pavia, Italy

ⁿUniversity of Stellenbosch, Tygerberg, 7505, South Africa

^oChildren's Hospital, University of Helsinki, Helsinki, Finland

^pUnit 3, 42 Severn Street, North Balwyn, Victoria 3052, Australia

^q1 Damodara Mudali Street, Chepet Chennai, 600031 India

^rRoyal Children's Hospital Melbourne, Parkville, 3052 Australia

^sChristian Medical College Hospital, Tamil Nadu 632004, India

^tMedizinische Hochschule Hannover, Hannover 30635, Germany

^uMedical University Klinik, Würzburg, Germany

^vUniversity of Salzburg, Salzburg, Austria

^wOur Lady's Children's, Hospital, Crumlin, Dublin, Ireland

^xChildren's Hospital Istanbul University, Istanbul, Turkey

^yKinderkrankenhaus City of Cologne, Cologne, 50735 Germany

* Corresponding author.

E-mail address: holschneidera@kliniken-koeln.de (A. Holschneider).

Index words:

Classification of anorectal malformation;
Wingspread classification;
Krackenbeck International classification

Abstract

Background: Anorectal malformations (ARM) are common congenital anomalies seen throughout the world. Comparison of outcome data has been hindered because of confusion related to classification and assessment systems.

Methods: The goals of the Krickenbeck Conference on ARM was to develop standards for an International Classification of ARM based on a modification of fistula type and adding rare and regional variants, and design a system for comparable follow up studies.

Results: Lesions were classified into major clinical groups based on the fistula location (perineal, recto-urethral, recto-vesical, vestibular), cloacal lesions, those with no fistula and anal stenosis. Rare and regional variants included pouch colon, rectal atresia or stenosis, rectovaginal fistula, H-fistula and others. Groups would be analyzed according to the type of procedure performed stratified for confounding associated conditions such as sacral anomalies and tethered cord. A standard method for postoperative assessment of continence was determined.

Conclusions: A new International diagnostic classification system, operative groupings and a method of postoperative assessment of continence was developed by consensus of a large contingent of participants experienced in the management of patients with ARM. These methods should allow for a common standardization of diagnosis and comparing postoperative results.

© 2005 Elsevier Inc. All rights reserved.

Based on the experience of a previous workshop organized by Stephens et al [1] in Wingspread, Wis, in 1984, an International Conference for the Development of Standards for the Treatment of Anorectal Malformations was organized at Krickenbeck Castle, Germany, on the 17th to 20th of May 2005. This workshop brought together 26 international authorities on congenital malformations of the organs of the pelvis and perineum (Table 1) (Fig. 1). Recent advances in etiology and genetics, diagnosis, early and late management and methods of improvement of urorectal continence were reviewed. In addition, the participants developed a new international classification for anorectal malformations and a new grouping for follow-up assessment and standard surgical procedures. The principle idea of the Krickenbeck workshop based on the previous experience in Wingspread was to enhance the fundamental concepts concerning these defects in preparation for a new edition of the book of Stephens et al [1] on *Anorectal Malformations in Children* updated in 1988. Springer International Publishers agreed with publishing the results of this Krickenbeck workshop in detail in 2006. The present preliminary report presents some of the international consensus reached at the Krickenbeck conference.

1. International classification of anorectal malformations

The most common previous international classification was referred to as the Wingspread classification of anorectal malformations, elaborated in Wingspread, Wis, in 1984 [1] (Fig. 2). This classification distinguished between high, intermediate, and low anomalies in the male and female, with special groups established for cloacal and rare malformations. High-type anorectal malformations were

subdivided into anorectal agenesis with and without fistula, and rectal atresia. The intermediate malformations were classified as rectovestibular and rectovaginal fistula in the female and rectobulbar fistula in the male as well as anal

Table 1 Coauthors and participants of the International Conference for the Development of Standards for the Treatment of Anorectal Malformations, Krickenbeck, Germany, May 17 to 20, 2005

Dr Elhamy Bekhit; Parkville, Australia
Subir Chatterjee; Calcutta, India
Arnold Coran; Ann Arbor, Mich
Michael Davies; Johannesburg, South Africa
Keith Georgeson; Birmingham, Ala
Jay Grosfeld; Indianapolis, Ind
Devendra Gupta; New Delhi, India
Alex Holschneider; Cologne, Germany
John Hutson; Melbourne, Australia
Naomi Iwai; Kyoto, Japan
Dieter Kluth; Hamburg, Germany
Giuseppe Martucciello; Genoa, Italy
Sam Moore; Stellenbosch, South Africa
Alberto Peña; Cincinnati, Ohio
Risto Rintala; Helsinki, Finland
Durham Smith; Melbourne, Australia
V Sripathi; Chennai, India
Douglas Stephens; Melbourne, Australia
Sudipta Sen; Vellore, India
Benno Ure; Hanover, Germany
Sabine Grasshoff; Würzburg, Germany
Thomas Boemers; Salzburg, Austria
Feilin Murphy; Dublin, Ireland
Yunus Söylet; Istanbul, Turkey
Martin Dübbers; Cologne, Germany
Marc Kunst; Cologne, Germany



Fig. 1 Group photograph of the participants in the International Conference for the Development of Standards for the treatment of anorectal malformations. Names of the participants are listed in [Table 1](#).

agenesis without fistula in both sexes. The low-type malformations were classified as anovestibular fistula in the female and, in both sexes, as anocutaneous fistula and anal stenosis. This classification was widely accepted over the years and was based on detailed embryological and anatomic studies performed especially by Stephens et al [1] and Kelly [2] on anatomic sections and radiographic investigations. They recognized that the pubococcygeal line extending from the upper border of the os pubis to the os coccyx corresponds with the attachment of levator ani muscles to the pelvic wall, separating high-type malformations lying above the levator muscle and intermediate and low forms of anorectal agenesis lying below this anatomic line. Furthermore, in healthy individuals, the lowest point of the ischial tuberosity, the so-called I-point, represents the deepest point of the funnel of the levator ani muscles. Therefore, every blind rectal pouch, lying between the pubococcygeal line and the I-point, was classified as an intermediate anomaly and could be treated by a posterior sagittal anorectoplasty (PSARP) according to Peña [3] and De Vries [4]. Low lesions below the I-point could be easily managed from a perineal approach. Because of these anatomic relations, the Wingspread classification had a significant impact on the choice of surgical approach.

However, some details of the Wingspread classification remained questionable. Some types of anorectal malforma-

tions such as rectovaginal fistulas are very rare, and from the surgical point of view, using PSARP in about two thirds of all anorectal malformations, the sex of the patient did not seem important in the choice of the surgical approach. Therefore, in 1995, Peña [5] proposed a classification based on the type of the fistula present. He distinguished between perineal, vestibular, bulbar, prostatic, and bladder neck fistulas; imperforate anus without fistula; vaginal fistulas; cloacal fistulas; and rectal atresia or stenosis. In his study, Peña [5] presented a critical and detailed analysis of 245 patients examined postoperatively. His follow-up criteria were also new and included voluntary bowel movement, fecal soiling, constipation, and complete fecal continence. This descriptive and fistula-related grouping became widely accepted over the past decade. The advantage of the classification of Peña [5] is that the type of the fistula provides information not only about localization of the blind pouch but also on the anticipated extent of mobilization of the atretic rectal segment necessary to perform a sacro- or abdominosacroperineal pull-through. It is important to remember that the course of the fistula may vary from one individual to another and can be ascending or descending and of shorter or longer length so that the confluence of the fistula with the urogenital tract or perineum may differ from the lowest point of the blind pouch. This is especially true if the fistula arises from a

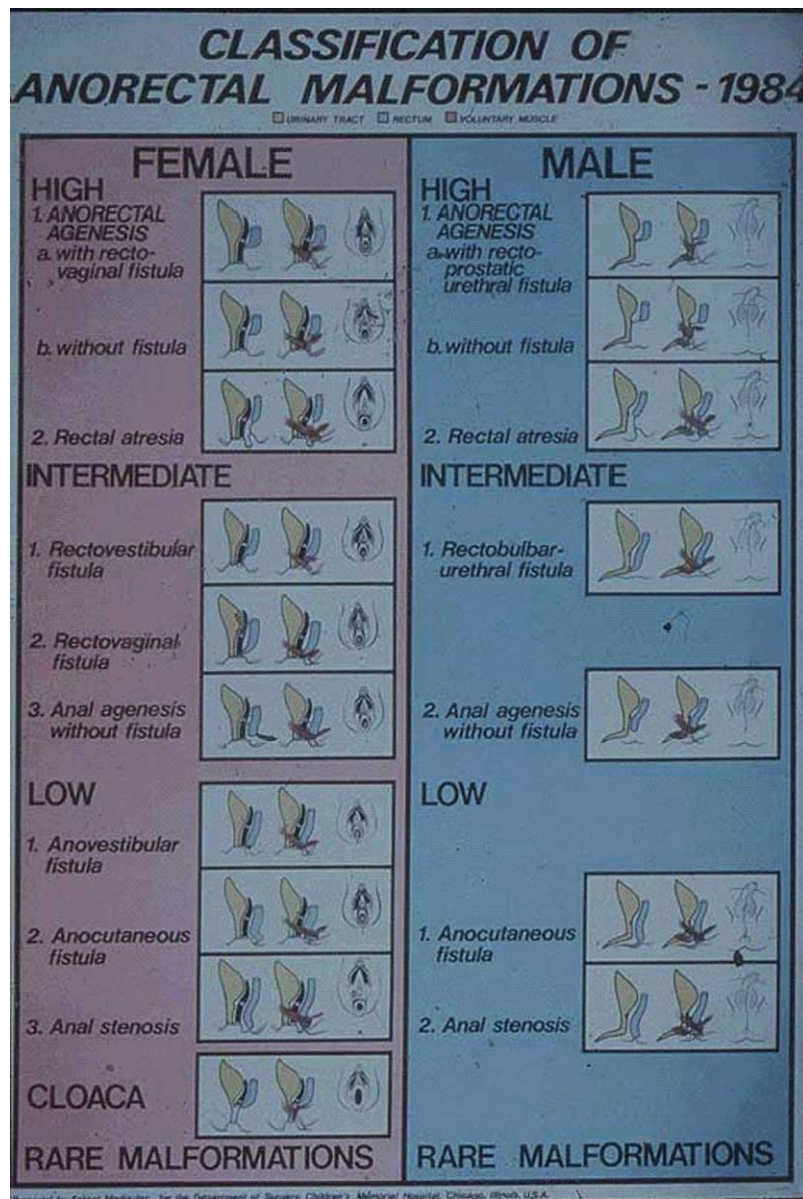


Fig. 2 Classification of anorectal malformations 1984 (Wingspread classification).

higher level of the blind-ending rectum and not from its lower most point. Therefore, the classification of Peña [5] does not distinguish between rectovestibular and anovestibular fistulas. When performing a PSARP procedure, however, this differentiation did not seem important.

By closely comparing both classifications, that is, the Wingspread classification and the suggestions of Peña [5], it becomes clear that there is no real contradiction between them. Perineal and vestibular fistulas could be regarded as low malformations, bulbar fistulas, and imperforate anus without a fistula, and most of the vaginal fistulas may be regarded as intermediate-type anomalies, and prostatic and bladder neck fistulas are considered high-type imperforate anus. The same is true for rectal agenesis or stenosis. In

addition, rare/regional variants, despite being frequent in certain geographic areas of the world, are not alluded to in either classifications.

The Krickenbeck conference, participants came to the following conclusions. The international Wingspread classification is still useful in the choice of the surgical approach. However, to develop a system for comparable follow-up studies, a modification of the classification of Peña [5] according to the type of the fistula and including rare/regional variants was proposed (Table 2). The major clinical groups were classified as perineal (cutaneous) fistulas, rectourethral fistulas (prostatic and bulbar), rectovesical fistulas, vestibular fistulas, cloacal malformations, patients with no fistula, and anal stenosis. Rare/regional

Table 2 Standards for diagnosis international classification (Krackenbeck)

Major clinical groups	Rare/regional variants
Perineal (cutaneous) fistula	Pouch colon
Rectourethral fistula	Rectal atresia/stenosis
Prostatic	Rectovaginal fistula
Bulbar	H fistula
Rectovesical fistula	Others
Vestibular fistula	
Cloaca	
No fistula	
Anal stenosis	

variants were subclassified as pouch colon, rectal atresia/stenosis, rectovaginal fistulas, H-type fistulas and others.

This new international classification enables the different operative procedures to be more comparable to each other than with the Wingspread classification.

2. International grouping of operative procedures

The Krackenbeck study group decided that, for follow-up studies, not only the site of the fistula should be documented but also an additional grouping according to the operative procedure performed is necessary. The operative procedures are listed in Table 3 as follows: perineal operation, anterior sagittal approach, sacroperineal procedure, PSARP, abdominosacroperineal pull-through, abdominoperineal pull-through, and laparoscopic-assisted pull-through.

3. International classification for follow-up assessment

After the introduction of the PSARP by Peña [3] and De Vries [4], the major postoperative problem observed was

Table 3 International grouping (Krackenbeck) of surgical procedures for follow-up

Operative procedures
Perineal operation
Anterior sagittal approach
Sacroperineal procedure
PSARP
Abdominosacroperineal pull-through
Abdominoperineal pull-through
Laparoscopic-assisted pull-through
Associated conditions
Sacral anomalies
Tethered cord

motility disturbances leading to chronic constipation and overflow incontinence, and true sphincter insufficiency with stool incontinence was much less of a problem than was observed in the past [6]. Therefore, after repair, we have to consider 2 different clinical outcomes that must be distinguished from one another to start appropriate therapy: chronic constipation and stool incontinence. In most cases, chronic constipation is the result of impaired rectal motility, whereas stool incontinence represents incompetence of the anorectal sphincters. This latter phenomenon has nothing to do with overflow incontinence because of chronic constipation. It can be distinguished by rectal palpation and electromanometry. The degree of chronic constipation seems to be dependent on the extent of sacral mobilization of the blind pouch (and the experience of the surgeon). In abdominoperineal pull-through procedures and high malformations, the incidence of severe chronic constipation is usually less than observed in intermediate or low malformations. In the 1995 study of Peña [5], constipation was observed in 28.6% of patients with a perineal fistula compared with 61.4% of children with vestibular fistula, 55.5% with bulbar fistula, and 41.4% with prostatic fistulas. In the high malformations, only 18.2% of the children with bladder neck fistulas and 25% of those with vaginal fistulas had severe constipation.

In the 1984 Wingspread conference, the following criteria were regarded as characteristic parameters for comparative follow-up studies: clean, staining, intermittent fecal soiling, and constant fecal soiling. These 4 groups were subdivided in 2 categories: group A with accumulated feces and group B without accumulated feces. These 2 subgroups were classified according to the therapy used in 3 additional categories: no therapy, occasional therapy, and therapy dependent. In addition, related complications such as abnormal anorectal position, stenosis, prolapse, fistula, lack of contractility, abnormal length of anorectum, urogenital, and other abnormalities were specified. Unfor-

Table 4 International classification (Krackenbeck) for postoperative results

1. Voluntary bowel movements	Yes/no
Feeling of urge, capacity to verbalize, hold the bowel movement	
2. Soiling	Yes/no
Grade 1	Occasionally (once or twice per week)
Grade 2	Every day, no social problem
Grade 3	Constant, social problem
3. Constipation	Yes/no
Grade 1	Manageable by changes in diet
Grade 2	Requires laxative
Grade 3	Resistant to laxatives and diet

tunately, this classification focusing on chronic constipation has not been published.

In most of the other assessment scoring systems used in the past, constipation did not play an important role. This is true for the score of continence of Kelly [2], giving 0 to 2 points for accidents, staining, and sphincter squeeze; the evaluation of continence according to Scott et al [7]; the score published by Holschneider [8]; and the score of Schärli [9]. The score of Rintala and Lindahl [10] in 1999 included constipation, but this complaint comprised only 2 of 18 points of evaluation so that this score also did not adequately assess postoperative continence behavior. In 2001, Holschneider et al [6] proposed a new classification for follow-up that was similar to the Wingspread suggestions and relates to postoperative treatment. Patients were classified into 3 main groups. Group I was defined as being continent and had regular voluntary bowel movements without constipation and no soiling. Group II patients were partially continent but could achieve continence with dietary management and/or laxatives (subgroup A) or had chronic constipation with or without overflow soiling (subgroup B) but could be treated and become clean with laxative, diet, and enemas. A third subgroup C, an incontinence group, represented those children that were partially incontinent because of a damaged or hypoplastic muscle complex. These latter patients had occasional soiling but had no constipation. They required loperamide and a constipative diet. Group III children in this classification had such severe problems with constipation or incontinence that they required a surgical procedure. Patients in the constipation subgroup, where the constipation was not manageable because of insufficient motility of the rectum, needed partial resection of the inert ectatic rectum, whereas children in the incontinence subgroup with a completely insufficient muscle complex underwent sphincter-improving operations.

The Krickenbeck conference participants concluded that a simpler classification for follow-up studies is needed. According to the publication of Peña [5] in 1995, voluntary bowel movements, soiling, and constipation were regarded as the main postoperative parameters to evaluate the success of an operation. Voluntary bowel movements were defined as feeling an urge to defecate, the capacity to verbalize this feeling, and the ability to hold the bowel movement. Concerning soiling, instead of the suggestions of Peña [5], 3 grades were proposed: grade 1, occasionally soiling (up to once or twice per week); grade 2, soiling every day but no social problems; and grade 3, constant soiling with social

problems. Regarding constipation, instead of the 2 grades of Peña, 3 grades were proposed. Grade 1 was defined as constipation manageable by changes in diet, grade 2 requires laxatives, and grade 3 is resistant to laxatives and diet (Table 4). This score is based on clear definitions of continence parameters; however, it is not yet validated, which should be done in the future.

4. Conclusions

The participants of the Krickenbeck conference aimed to develop standards for the treatment of anorectal malformations and hope that these 3 new groupings and/or classifications will permit comparison of postoperative results in different centers of pediatric surgery internationally. This will be of great value for children with anorectal agenesis as well as the surgeons that care for them. The final results of the Krickenbeck conference will be published by Springer International Publishers in a book entitled *Anorectal Malformations in Children*, updating the excellent textbook of Stephens et al [1] from 1988.

References

- [1] Stephens FD, Smith ED, Paoul NW. Anorectal malformations in children: update 1988 March of Dimes Birth Defect Foundation Original series, vol. 24 (4). New York: Alan R. Liss Inc; 1988.
- [2] Kelly JH. Cineradiography in anorectal malformations. *J Pediatr Surg* 1969;4:538-46.
- [3] Peña A, De Vries P. Posterior sagittal anorectoplasty: important technical considerations and new applications. *J Pediatr Surg* 1982;17:796-811.
- [4] De Vries P, Peña A. Posterior sagittal anorectoplasty. *J Pediatr Surg* 1982;17:638-43.
- [5] Peña A. Anorectal malformations. *Semin Pediatr Surg* 1995;4:35-47.
- [6] Holschneider AM, Jesch NK, Stragholz E, et al. Surgical methods for anorectal malformations from Rehbein to Peña. Critical assessment of score systems and proposal for a new classification. *Eur J Pediatr Surg* 2002;12:73-82.
- [7] Scott JES, Swenson O, Fisher JH. Some comments on the surgical treatment of imperforate anus. *Am J Surg* 1960;99:137-43.
- [8] Holschneider AM. Elektromanometrie des Enddarmes. Diagnostik und Therapie der Inkontinenz und chronischen Obstipation. 2. Aufl Urban & Schwarzenberg, 1983. p. 219 ff.
- [9] Schärli A. Angeborene Missbildungen des Rektums und Anus. Diagnose, Physiologie und Therapie. Bern: Verlag Hans Huber; 1971.
- [10] Rintala RJ, Lindahl HG. Posterior sagittal anorectoplasty is superior to sacroperineal-sacroabdominoperineal pullthrough: a long-term follow up study in boys with high anorectal anomalies. *J Pediatr Surg* 1999;34:334-7.