

# Assessment of Location and Anatomical Characteristics of Mental Foramen, Anterior Loop and Mandibular Incisive Canal Using Cone Beam Computed Tomography

Mehrdad Panjnoush<sup>1</sup>, Zonnar Sadat Rabiee<sup>2</sup>, Yasaman Kheirandish<sup>3✉</sup>

<sup>1</sup> Assistant Professor, Head of Department of Oral and Maxillofacial Radiology, School of Dentistry, Tehran University of Medical Sciences, Tehran, Iran

<sup>2</sup> Oral and Maxillofacial Radiologist, Tehran, Iran

<sup>3</sup> Assistant Professor, Department of Oral and Maxillofacial Radiology, School of Dentistry, Tehran University of Medical Sciences, Tehran, Iran

## Abstract

**Objectives:** This study aimed to evaluate the location and characteristics of mental foramen, anterior loop and mandibular incisive canal using cone beam computed tomography (CBCT).

**Materials and Methods:** This retrospective cross-sectional study evaluated 200 mandibular CBCT scans for the location of mental foramen, anterior loop prevalence and mandibular incisive canal visibility, its mean length and distance to buccal and lingual plates and inferior border of the mandible. The effect of age and gender on these variables was also analyzed ( $P < 0.05$ ).

**Results:** Anterior loop and mandibular incisive canal were seen in 59.5% and 97.5% of the cases, respectively. The mean length of the mandibular incisive canal was  $10.48 \pm 4.53$  mm in the right and  $10.40 \pm 4.52$  mm in the left side. The mean distance from the endpoints of the canal to buccal plate was  $3.63 \pm 1.73$  mm in the right and  $3.66 \pm 1.45$  mm in the left side. These distances were  $3.89 \pm 1.53$  mm in the right and  $4.13 \pm 1.48$  mm in the left side to lingual plate and  $9.98 \pm 2.07$  mm in the right and  $8.62 \pm 1.97$  mm in the left side to the inferior border of the mandible. The distance from the endpoints of the canal to lingual plate was significantly different in the right and left sides. The distance from the endpoint of the canal to the buccal plate and inferior border of the mandible was significantly shorter in females ( $P = 0.016$ ), and had a weak, significant correlation with age ( $r_{sp} = 0.215$ ,  $P = 0.003$ ).

**Conclusions:** Due to variability in mandibular incisive canal length and high prevalence of anterior loop, CBCT is recommended before surgical manipulation of interforaminal region.

**Keywords:** Anatomic Landmarks; Cone-Beam Computed Tomography; Mandible; Mandibular Nerve

*Journal of Dentistry, Tehran University of Medical Sciences, Tehran, Iran (2016; Vol. 13, No. 2)*

✉Corresponding author:

Y. Kheirandish, Department of Oral and Maxillofacial Radiology, School of Dentistry, Tehran University of Medical Sciences, Tehran, Iran

kheirandish@sina.tums.ac.ir

Received: 27 July 2015

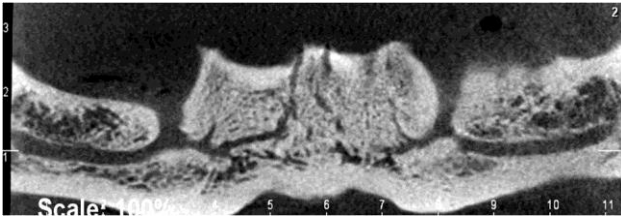
Accepted: 19 December 2015

## INTRODUCTION

It is important to have complete information about the anatomy of the anterior segment of the mandible before performing any surgical procedure at this site. Despite the general belief that the interforaminal area of the mandible should be considered safe for placing implants and other surgeries, detailed anatomy of this area is still a matter of controversy. Important anatomical structures in the anterior segment of the mandible include mental foramina, anterior loop and mandibular incisive canal. To reach

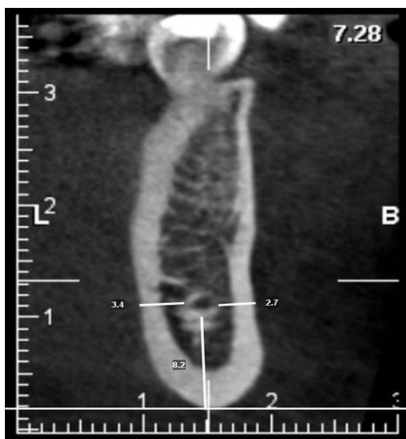mental foramen, the inferior alveolar nerve ascends and often curves for a few millimeters anterior to the mental foramen returning back to the mental foramen, where it is called the anterior loop [1].

Location of mental foramen and anterior loop determines the most distal point for implant placement in the interforaminal area. There have been reports of lower lip sensory disturbances caused by direct trauma to the anterior loop during implant placement [2]. Prevalence of anterior loop on cadavers varied from a minimum

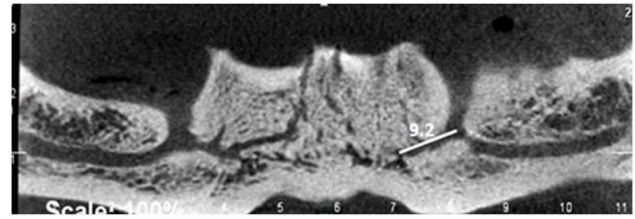


**Fig. 1:** Mandibular incisive canal on CBCT scan

of 28% in a study by Mardinger et al, [3] to a maximum of 96% in a study by Arzouman et al [4]. There have also been different studies regarding the maximum length of the anterior loop with various results, suggesting to keep a minimum distance of 6mm between the mental foramen and the most posterior implant in the interforaminal area where there is no accurate measurement of the length of the anterior loop [5,6]. This 6-millimeter distance is because of the fact that the maximum length of the anterior loop has been determined to be 5mm in anatomical assessments [3,5]. Different studies on cadavers have indicated that the mandibular incisive canal is present in almost 100% of the cases [7-9]. During the placement of implant in this area, if adequate distance from this canal is not maintained, the surgical procedure can lead to an inflammation around the nerve that could extent into the major branches of mental nerve, resulting in sensory disturbances in this area [5].



**Fig. 2:** Measuring the distance from the endmost point of the mandibular incisive canal to the buccal plate, lingual plate and the inferior border of the mandible



**Fig. 3:** Method of mandibular incisive canal length measurement

On conventional such as panoramic radiographs, the bucco-lingual dimension cannot be seen. On the other hand, the non-uniform magnification in panoramic radiography makes this modality unreliable for assessing vertical distances. Computed tomography has the ability to show bone on the axial, coronal and sagittal sections. Therefore, this method is useful for evaluation of the position of anatomical structures. Cone beam computed tomography (CBCT) possesses some capabilities such as showing coronal, sagittal and axial planes in addition to lower absorbed patient dose and lower cost for the patient and dentist. The aim of this study was to assess the location and characteristics of important landmarks in interforaminal region.

## MATERIALS AND METHODS

This retrospective cross-sectional study was conducted on 200 CBCT scans of patients referred to a private radiology clinic. All images were obtained using the same CBCT unit (ProMax 3D, Planmeca, Helsinki, Finland) with the exposure settings of 84 kVp, 14mA, 12 seconds time, 8x8 cm field of view and 0.16 mm voxel size. Using the Planmeca Romexis software version 2.3.1 in high resolution mode, the study was performed as follows: in the panoramic tab, the desired focal through layer on the axial plane of the image with an appropriate width was defined, so that the desirable panoramic image of the mandible was prepared with mental foramina on both sides. The panoramic line in axial images was traced along with the incisive canal followed by decreasing the slice thickness to a minimum of 0.1 mm, to

**Table 1:** Frequency distribution of the position of mental foramen in the right and left sides

Side mental foramen position	Right frequency (%)	Left frequency (%)
Along the first premolar	3.5	5
Between the first and second premolars	32	31.5
Along the second premolar	57.5	58
Between the second premolar and first molar	7	4.5
Along the first molar	-	1
Total	100	100

show the path of the mandibular incisive canal and then confirmed via assessing the cross-sectional and axial planes (Fig.1). Also, through analyzing the cross-sectional and panoramic outputs, the precise location of mental foramen was determined. The presence or absence of the anterior loop was assessed through an analysis of the cross-sectional planes adjacent to the mental foramen and the axial planes. Using Romexis software (Planmeca, Helsinki, Finland), at first the path of the mandibular canal was signified and then on the cross-sectional image, sections made after the mental foramen were signified as the anterior loop. The endmost point of the mandibular incisive canal was in the last cross-sectional plane where the canal had opaque borders. The last slice in which, the incisive canal had well defined cortical border was considered in our study. According to similar studies, incisive canals with cortical borders are important even when they have less than two millimeters diameter. The canal's terminal points were measured in respective areas with cortical borders since these points are clinically important [3,10,11]. On this plane, the distance between the canal and the inferior, buccal and lingual borders of the mandible was measured in such a way that the line from the opaque border of the canal perpendicular to the buccal border of the mandible was considered as the distance from the canal to the buccal border of the mandible,

the line from the opaque border of the canal perpendicular to the lingual border of the mandible was considered as the distance from the canal to the lingual border of the mandible, and the line from the inferior border of the mandibular incisive canal to the lowermost point of the mandible was measured as the distance from the canal to the inferior border of the mandible (Fig. 2). The length of the mandibular incisive canal was calculated via measuring the distance between the endmost point of the canal and the mental foramen using measuring tools on the 2D image extracted from the panoramic radiograph (Fig. 3).

In 2D images extracted from the panoramic view, horizontal lines were drawn at the inferior border of the mental foramen and the inferior border of the endmost point of the mandibular incisive canal, so that it was possible to assess the superior-inferior position of the endmost point of the canal in relation to the mental foramen. In order to have precise measurements, the processes mentioned above were performed by two expert oral radiologists and they repeated the measurements after a one-month interval. The inter-observer and intra-observer agreements were calculated.

## RESULTS

Of 200 CBCT scans used in this study, 110 belonged to females and the remaining to males. The mean age was  $48.78 \pm 13.65$  years in females and  $51.71 \pm 13.02$  years in males.

The most common locations of mental foramen were along the second premolar and between the second and the first premolars, respectively. In 71% of the cases, mental foramina were located symmetrically on both right and left sides; in 45%, they were located along the second premolars in both sides (Table 1).

the anterior loop was seen in 59.5% of the cases, which was bilateral in 39% and unilateral in 20.5%, in such a way that 9.5% of the unilateral cases had the anterior loop on the left and the

**Table 2:** The mean and standard deviation of mandibular incisive canal length and distance from the canal to the buccal and lingual plates and the inferior border of the mandible according to gender

Variables Gender	Mean length of mandibular incisive canal	Distance from the endpoint of the canal to the buccal plate	Distance from the endpoint of the canal to the lingual plate	Distance from the endpoint of the canal to the inferior border
Female	9.94±4.12	3.46±1.10	4.16±1.38	8.36±1.60
Male	10.38±4.27	3.90±1.42	3.83±1.30	9.32±1.81
P-value	0.461	0.016	0.103	0.0001

P-value<0.05 was considered significant

**Table 3:** The mean and standard deviation of mandibular incisive canal length and the distance from the canal to the buccal and lingual plates and the inferior border of the mandible in the right and left sides

Variables Side	Mean length of mandibular incisive canal	Distance from the endpoint of the canal to the buccal plate	Distance from the endpoint of the canal to the lingual plate	Distance from the endpoint of the canal to the inferior border
Right	10.48±4.53	3.63±1.37	3.89±1.53	8.98±2.07
Left	10.40±4.62	3.66±1.45	4.13±1.48	8.62±1.97
P-value	0.917	0.613	0.026	0.015

P-value<0.05 was considered significant

remaining 11% had the loop on the right side (P=0.0001).

The anterior loop was seen in 65% of males and 54.5% of females. In 97.5% of the cases, the mandibular incisive canal could be identified, of which it was bilateral in 94% and unilateral in 3.5%. Of 3.5% unilateral canals, it was located on the left side in 1.5% and on the right side in 2% (P=0.0001).

The average length of the mandibular incisive canal for the right-sided and the left-sided cases was 10.48±4.53mm and 10.40±4.62mm, respectively (P=0.917). The maximum and the minimum lengths of the mandibular incisive canal were 21.5mm and 1.5mm, respectively.

At the endpoints, the mandibular incisive canal had buccal inclination on both right and left sides, so that on the right side the distances from the endpoint of the canal to the buccal plate and the lingual plate were 3.63±1.37 and 3.89±1.53mm, respectively.

These distances to buccal and lingual plates on the left side were 3.66±1.45mm and 4.13±1.48mm, respectively. The distances from the endpoint of the canal to the inferior border of the mandible were 8.98±2.07mm and

8.62±1.97mm in the right and the left sides, respectively.

When assessing the location of the mandibular incisive canal in relation to the mental foramen in the superior-inferior dimension, it was found that the canal on the right and left sides was lower than the mental foramen, that is, in 74.6% and 81% of the cases the canal was lower than the mental foramen on the right and left sides, respectively. (P=0.0001,  $r=0.33$ ). There was a correlation between the right-side and the left-side location of the mandibular incisive canal in relation to the mental foramen in the superior-inferior dimension (Table 2). A comparison of the studied variables as classified by age indicates that the length of the mandibular incisive canal, the distance from the endpoint of the canal to the lingual plate, the position of the mandibular incisive canal from the superior-inferior dimension, prevalence of the anterior loop, the location of mental foramen, and the prevalence of the mandibular incisive canal were not influenced by the patients' age (P≥0.05 in all the above cases,) and there was only a significant and relatively weak direct correlation between age and the distance from the endpoint of the

canal to the buccal plate ( $r_{sp}=0.215$ ,  $P=0.003$ , Table 3). There was no correlation between the presence of anterior loop and mandibular incisive canal ( $P\geq 0.05$ ). The intra-examiner reliability of the researcher was 92%, the intra-examiner reliability of the expert radiologist was 93.8% and the inter-examiner reliability was 91.2%.

## DISCUSSION

It is very important to have complete information about various types of jaws and facial structures prior to perform any surgical operation in this area in order to prevent complications. The most common location of mental foramen in this study was along the second premolar. Mental foramen between the first and second premolars ranked second in terms of prevalence, which was in accordance with the results of Khojastepour et al, [12] Chkoura and El Wady [13] and Udhyia et al [14]. In a study conducted by Haghanifar and Rokouei [15] on the panoramic radiographs taken from patients, the most common locations of the mental foramen were between the second and the first premolars and along the second premolar, respectively. The reason for such a difference in the results may be due to the use of CBCT in the current study instead of panoramic radiography, which is less accurate in illustrating anatomical landmarks.

In the current study, the anterior loop was seen in 59.5% of the cases. In the study by Uchida et al, [16] on cadavers, the anterior loop was seen in 71% of the cases. In various studies using panoramic radiographs, the anterior loop prevalence varied from 28% to 76% [3,17-19]. In the study conducted by Kaya et al, [18] on computed tomography scans, the anterior loop was seen in 34% of the cases. Such differences are attributed to the application of different modalities in imaging and different criteria for presence of the anterior loop; therefore, further studies in this area are recommended.

In the current study, anterior loop was seen more commonly in males than in females, which was

in line with the results of a study by Ngeow et al, [17] conducted on the visibility of the anterior loop on panoramic radiographs. In our study, the mandibular incisive canal was identifiable in 97.5% of the cases. Different studies on cadavers have shown that the mandibular incisive canal was present in almost 100% of the cases [3-6]. This difference is due to the fact that in some cases the diameter of the mandibular incisive canal is too small to be seen on CBCT scans. Compared to the above-mentioned studies, the current study reported the highest prevalence of the mandibular incisive canal. The prevalence values of the identifiable mandibular incisive canal in the studies conducted by Arzouman et al, [4] on CBCT scans, Pires et al, [19] on CBCT scans, and Jacobs et al, [20] on CT scans were 97%, 83% and 93%, respectively. The reason for the high prevalence seen in the current study may be due to the application of high resolution mode in CBCT coupled with a large sample size (200 bilateral cases, that is, 400 canals).

In the current study, the location of the endpoint of the mandibular incisive canal in vertical dimension was lower than the mental foramen in most patients (in 74.6% of the cases in the right and in 81% of the cases in the left side). This result corresponds to that of a study by Mraiwa et al, [9] in this field, which was done on cadavers using 2D radiographs (oral and panoramic) and tomography.

In our study, when analyzing the effect of gender on the variables, it was found that the distances from the endpoint of the mandibular incisive canal to the buccal plate and from the endpoint of the canal to the inferior border of the mandible were influenced by gender, so that the distances were shorter in females; therefore, a more buccal mandibular incisive canal is seen in females compared to males.

The reason for a shorter distance between the mandibular incisive canal and the inferior border of the mandible in females is the smaller size of mandibular dimensions in women, which

corresponds to the findings of Pires et al, [19] who studied the location of the mandibular incisive canal using CBCT. In analyzing the effect of age on the understudy variables, it was found that there was only a direct and meaningful but relatively weak correlation between age and the distance from the endpoint of the canal to the buccal plate. In our study, the mean length of the incisive canal was  $10.48 \pm 4.53$  mm in the right side and  $10.40 \pm 4.62$  mm in the left side; these results were in accordance with those of Pereira-Maciél et al, [21] with less than 1 mm difference. When comparing the variables on the right and left sides, it was found that the distances from the endpoint of the mandibular incisive canal to the lingual plate and to the inferior border of the mandible on both sides had statistically significant differences, but since these differences on both sides were less than 0.5 mm, it did not have much clinical importance and was included just to indicate the high sensitivity of statistical tests.

## CONCLUSION

Considering the high variability in size and position of the incisive canal, use of CBCT seems necessary in order to better assess this landmark prior to surgery.

## REFERENCES

- 1- White SC, Pharo MJ. Oral radiology principle and practices. 6th ed. St. Louis, Mosby Co., 2009:166.
- 2- Kohavi D, Bar-Ziv J. Atypical incisive nerve: clinical report. *Implant Dent.* 1996 Winter;5(4):281-3.
- 3- Mardinger O, Chaushu G, Arensburg B, Taichers S, Kaffe I. Anterior loop of the mental canal: an anatomical- radiologic study. *Implant Dent.* 2000;9(2):120-5.
- 4- Arzouman MJ, Otis L, Kipnis V, Levine D. Observations of the anterior loop of the inferior alveolar canal. *Int J Oral Maxillofac Implants.* 1993;8(3):295-300.
- 5- Kuzmanovic DV, Payne AG, Kieser JA, Dias GJ. Anterior loop of the mental nerve: a morphological and radiographic study. *Clin Oral Implants Res.* 2003 Aug;14(4):464-71.
- 6- Babbush CA. Transpositioning and repositioning the inferior alveolar and mental nerves in conjunction with endosteal implant reconstruction. *Periodontol* 2000. 1998 Jun;17:183-90.
- 7- De Andrade E, Otomo-Corgel J, Pucher J, Ranganath KA, St George N Jr. The intraosseous course of the mandibular incisive nerve in the mandibular symphysis. *Int J Periodontics Restorative Dent.* 2001 Dec;21(6):591-7.
- 8- Uchida Y, Yamashita Y, Goto M, Hanihara T. Measurement of anterior loop length for the mandibular canal and diameter of the mandibular incisive canal to avoid nerve damage when installing endosseous implants in the interforaminal region. *J Oral Maxillofac Surg.* 2007 Sep;65(9):1772-9.
- 9- Mraiwa N, Jacobs R, Moerman P, Lambrichts I, van Steenberghe D, Quirynen M. Presence and course of the incisive canal in the human mandibular interforaminal region: two-dimensional imaging versus anatomical observations. *Surg Radiol Anat.* 2003 Nov-Dec;25(5-6):416-23.
- 10- Juodzbalys G, Wang HL, Sabalys G. Anatomy of mandibular vital structures. Part II: Mandibular incisive canal, mental foramen and associated neurovascular bundles in relation with dental implantology. *J Oral Maxillofac Res.* 2010 Apr;1(1):e3.
- 11- Makris N, Stamatakis H, Syriopoulos K, Tsiklakis K, van der Stelt PF. Evaluation of the visibility and the course of the mandibular incisive canal and the lingual foramen using cone-beam computed tomography. *Clin Oral Implants Res.* 2010 Jul;21(7):766-71.
- 12- Khojastepour L, Mirbeigi S, Mirhadi S, Safaei A. Location of Mental Foramen in a Selected Iranian Population: A CBCT Assessment. *Iran Endod J.* 2015;10(2):117-21.
- 13- Chkoura A, El Wady W. Position of the mental foramen in a Moroccan population: A radiographic study. *Imaging Sci Dent.* 2013 Jun;43(2):71-5.
- 14- Udhaya K, Saraladevi KV, Sridhar J. The

- morphometric analysis of the mental foramen in adult dry human mandibles: a study on the South Indian population. *J Clin Diagn Res.* 2013 Aug;7(8):1547-51.
- 15- Haghani S, Rokouei M. Radiographic evaluation of the mental foramen in a selected Iranian population. *Indian J Dent Res.* 2009 Apr-Jun;20(2):150-2.
- 16- Uchida Y, Noguchi N, Goto M, Yamashita Y, Hanibara T, Takamori H, et al. Measurement of anterior loop length for the mandibular canal and diameter of the mandibular incisive canal to avoid nerve damage when installing endosseous implant in the interforaminal Region: a second attempt introducing cone beam computed tomography. *J Oral Maxillofac Surg.* 2009 Apr;67(4):744-50.
- 17- Ngeow WC, Dionysius DD, Ishak H, Nambiar P. A radiographic study on the visualization of the anterior loop in dentate subjects of different age groups. *J Oral Sci.* 2009 Jun;51(2):231-7.
- 18- Kaya Y, Sencimen M, Sahin S, Oksu KM, Dogan N, Bahcecitapar M. Retrospective radiographic evaluation of the anterior loop of the mental nerve: comparison between panoramic radiography and spiral computerized tomography. *Int J Oral Maxillofac Implants.* 2008 Sep-Oct;23(5):919-25.
- 19- Pires CA, Bissada NF, Becker JJ, Kanawati A, Landers MA. Mandibular incisive canal: cone beam computed tomography. *Clin Implant Dent Relat Res.* 2012 Mar;14(1):67-73.
- 20- Jacobs R, Mraiwa N, van Steenberghe D, Gijbels F, Quirynen M. Appearance, location, course and morphology of the mandibular incisive canal: an assessment on spiral CT scan. *Dentomaxillofac Radiol.* 2002 Sep;31(5):322-7.
- 21- Pereira-Maciel P, Tavares-de-Sousa E, Oliveira-Sales MA. The mandibular incisive canal and its anatomical relationships: A cone beam computed tomography study. *Med Oral Patol Oral Cir Bucal.* 2015 Nov 1;20(6):e723-8.