

# 2.2

## Tissue Doppler imaging in the left ventricle and right ventricle in healthy children: normal age-related peak systolic velocities, timings, and time differences

Submitted

A.E. van der Hulst  
V. Delgado  
A.D.J. ten Harkel  
L.M. Klitsie  
L.H.P.M. Filippini  
J.J. Bax  
N.A. Blom  
A.A.W. Roest

### ABSTRACT

**Background:** Tissue Doppler imaging (TDI) enables assessment of velocities and timings within the left (LV) and right (RV) ventricle with high temporal resolution. Knowledge on normal age-related values of peak systolic velocities and timings in healthy children may optimize the benefit of device-based therapies in pediatric patients with heart failure.

**Methods:** A total of 123 healthy children (from 1 month to 18 years old) underwent TDI evaluation of the RV and LV. Peak systolic velocity and time to peak systolic velocity were assessed at the basal segments of the LV lateral wall, inter-ventricular septum (IVS), RV free wall (RVFW) and at the RVOT. Intra-ventricular time differences were calculated. Regression analysis was performed to assess the age-dependency of the ventricular mechanics.

**Results:** Median peak velocities were: LV lateral wall 6.3 cm/s, (inter-quartile-range: 5.1-7.9 cm/s), IVS: 6.0 cm/s (5.4-6.7 cm/s), RVFW: 10.2 cm/s (8.9-11.3 cm/s), RVOT 7.2 cm/s (6.0-8.2 cm/s). Timings of peak systolic velocities: LV lateral wall 101 ms (91-112 ms), IVS: 114 ms (100-128 ms), RVFW: 177 ms (157-194 ms), RVOT 100 ms (88-113 ms). Timings and peak velocities significantly increased with age at both ventricles. No relevant time difference was observed within the LV, whereas a considerable time delay was observed within the RV between the RVFW and the IVS (62 ms, IQR 45-74 ms) and between the RVFW and the RVOT (74 ms, IQR 59-93 ms).

**Conclusions:** The present evaluation provides TDI-derived reference values on LV and RV mechanics of healthy children. Within the LV, no relevant time difference was observed whereas a considerable mechanical delay is observed within the healthy RV.

## INTRODUCTION

Echocardiographic tissue Doppler imaging (TDI) enables the assessment of left (LV) and right (RV) ventricular mechanics by measuring myocardial velocities and time to peak myocardial velocities with high temporal resolution. The assessment of peak systolic velocities of the LV and RV myocardium with TDI is of incremental value to conventional echocardiography to assess global and regional ventricular performance in various clinical conditions.(1-5) Furthermore, evaluation of the temporal occurrence of peak systolic velocities with TDI provides insight into electromechanical coupling and mechanical dyssynchrony.(6)

TDI-derived peak velocities and time-differences between peak systolic velocities within the myocardium of the LV and RV have been investigated in healthy children.(7-9) However, the absolute timings within the LV and the RV have not been reported. The advent of novel device-based therapies, such as cardiac resynchronization therapy (CRT), has encouraged the research on LV and RV mechanics with noninvasive imaging. Understanding LV and RV mechanics in healthy children may optimize the benefit of these therapies in patients with heart failure. Furthermore, in certain patients with congenital heart disease, RV outflow tract (RVOT) mechanics have an influence on global RV performance. Abnormal RVOT mechanics have been related to RV failure and poor clinical outcome. However, the reference values of normal peak systolic velocities and timings at the RVOT in healthy children have not been evaluated. Accurate standardization of reference values of TDI velocities at the RVOT would help to understand the mechanisms underlying RV failure in patients with congenital heart disease.(5,10,11)

Accordingly, the objectives of this evaluation were to assess peak systolic velocities, timings of peak systolic velocities and intra-ventricular time differences with TDI in the LV and RV of healthy children. In addition, the age-dependency of the peak systolic velocities, timings to peak systolic velocities and intra-ventricular time differences in healthy children were investigated.

## METHODS

### Study population

Healthy children of various ages (from 1 month to 18 years) were prospectively included in the current study. We did not include patients younger than 1 month since these young patients may still have a raised pulmonary pressure, which may interfere with the observed myocardial velocities. All subjects underwent transthoracic echocardiography and TDI. Conventional two-dimensional echocardiography confirmed structurally normal hearts. Peak systolic velocities and timings of peak systolic velocities at the LV and RV were assessed with TDI in all subjects. In addition, intra-ventricular time differences between the peak systolic velocities at the various LV and RV regions were calculated. Finally, the relationship between age and myocardial velocities, time to peak systolic velocity and the intra-ventricular time differences were evaluated. The study protocol was approved by our hospital institutional review board. All participants or their parents gave written informed consent.

**Table 1. Ventricular mechanics as assessed by TDI**

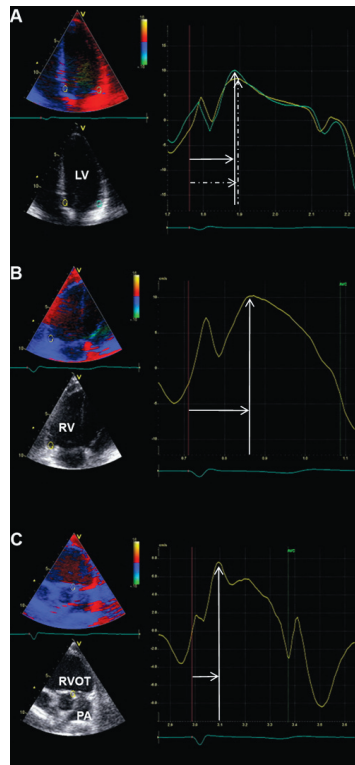
Peak systolic velocity (cm/s)	
Left ventricle	
LV lat	6.3 (5.1 - 7.9)
IVS	6.0 (5.4 - 6.7)
Right ventricle	
RVFW	10.2 (8.9 - 11.3)
RVOT	7.2 (6.0 - 8.2)
Timing peak systolic velocity (ms)	
Left ventricle	
LV lat	101 (91 - 112)
IVS	114 (100 - 128)
Right ventricle	
RVFW	177 (157 - 194)
RVOT	100 (88 - 113)
Intra-ventricular time differences (ms)	
Left ventricle	
LV lat - IVS	10 (0 - 20)
Right ventricle	
IVS - RVFW	62 (45 - 75)
RVOT - RVFW	74 (59 - 93)

Abbreviations: IVS: inter-ventricular septum, LV lat: left ventricular lateral wall, RVFW: right ventricular free wall, RVOT: right ventricular outflow tract.

### Tissue Doppler imaging

Transthoracic echocardiography data were acquired using a commercially available system equipped with a 3.5 MHz transducer (Vivid-7.0.0, GE Vingmed Ultrasound AS, Horten, Norway). Standard two-dimensional gray-scale images were acquired from the parasternal (long- and short-axis) and apical views (4-chamber and long-axis) and digitally stored in cine-loop format. Acquisition of TDI images was performed with adjusted sector width and angle to align the ultrasound beam along the direction of the myocardial motion. The color frame rate was  $\geq 120$  frames/s, and at least three consecutive beats were recorded. Analyses were performed off-line using EchoPac version 108.1.5 (General Electric Medical Systems). Longitudinal myocardial velocity curves were obtained by placing regions of interest at the basal LV lateral wall (Figure 1, panel A), basal inter-ventricular septum (IVS) (Figure 1, panel A) and basal RV free wall (RVFW) (Figure 1, panel B) in the 4-chamber view, and at the lateral wall of the RVOT (Figure 1, panel C) in a dedicated apical RVOT view, as previously reported. (5, 12) Semi-automated tissue tracking was used to maintain the region of interest within the sample area throughout the cardiac cycle. Peak systolic velocity was measured at all LV and RV regions. In addition, time from onset of the Q-wave of the ECG to peak systolic velocity was measured in all LV and RV basal segments. Finally, the LV intra-ventricular time difference was obtained by calculating the difference between time to peak systolic velo-

**Figure 1. TDI images of LV and RV in a healthy child**



**Panel A:** TDI image of LV. Yellow region of interest is placed at the basal IVS. Blue region of interest is placed at the basal lateral wall. From the corresponding velocity curves the peak systolic velocity (vertical dotted arrow: peak systolic velocity IVS, vertical solid arrow: peak systolic velocity LV lateral wall) and time to peak systolic velocity (horizontal dotted arrow: time to peak systolic velocity IVS, horizontal solid arrow: time to peak systolic velocity LV lateral wall) can be derived.

**Panel B:** TDI image of RV. Yellow region of interest is placed at the basal free wall. From the corresponding velocity curve, the peak systolic velocity (vertical arrow) and time to peak systolic velocity (horizontal arrow) can be derived.

**Panel C:** TDI image of RVOT. Yellow region of interest is placed at the septal side of the RVOT, just below the pulmonary valve. From the corresponding velocity curve, the peak systolic velocity (vertical arrow) and time to peak systolic velocity (horizontal arrow) can be derived.

Abbreviations: IVS: inter-ventricular septum, LV: left ventricle, PA: pulmonary artery, RV: right ventricle, RVOT: right ventricular outflow tract.

city at the basal LV lateral segment and at the basal part of the IVS. The RV intra-ventricular time difference was calculated by measuring the time delay in peak systolic velocities between the basal part of the IVS and RVFW and between the RVOT and basal RVFW. Intra and inter observer agreement of all peak velocities and timings of peak velocities was assessed in a blinded manner in 15 randomly chosen subjects. Peak velocity and time to peak velocity at the different LV and RV regions was reassessed by the same and by an independent observer.

### Statistical analysis

Continuous variables are expressed as median and inter-quartile range (IQR). Categorical variables are presented as numbers and percentages. Linear regression analysis was performed to evaluate the relation between age and peak systolic velocities, timings of velocities, and time differences. Intra observer and inter observer agreement was assessed by measuring the absolute difference between the repeated measurements in percent of the mean, averaged over the study subjects and presented as mean  $\pm$  standard deviation. In addition, 95% reference intervals for the linear regression models were calculated. Data were analyzed using the SPSS 17.0 software (SPSS Inc, Chicago, Illinois). A p-value of  $<0.05$  was considered statistically significant.

## RESULTS

### Study population characteristics

A total of 123 healthy children (56% male) were included. The median age at echocardiography was 6.3 years (IQR: 3.3-11.7 years) and children of all ages (1 month to 18 years) were represented in the present study. All subjects showed structurally normal hearts on echocardiography. The median heart rate during image acquisition was  $90 \text{ min}^{-1}$  (IQR:  $72\text{-}111/\text{min}^{-1}$ ) and the median body surface area was  $0.9 \text{ m}^2$  (IQR:  $0.6\text{-}1.3 \text{ m}^2$ ). The obtained TDI images had sufficient image quality for analysis in all subjects.

### Peak systolic velocities

Table 1 summarizes the peak systolic velocities at the different LV and RV regions. The median peak systolic velocity at the LV lateral wall was  $6.3 \text{ cm/s}$  (IQR:  $5.1\text{-}7.9 \text{ cm/s}$ ). At the IVS, peak systolic velocity was  $6.0 \text{ cm/s}$  (IQR:  $5.4\text{-}6.7 \text{ cm/s}$ ). At the RVFW, the median peak systolic velocity was  $10.2 \text{ cm/s}$  (IQR  $8.9\text{-}11.3 \text{ cm/s}$ ). Finally, the median peak systolic velocity at the RVOT was  $7.2 \text{ cm/s}$  (IQR  $6.0\text{-}8.2 \text{ cm/s}$ ).

A significant relationship between age and peak systolic velocity measured at the LV lateral wall was observed (LV lateral wall:  $r=0.75$ ,  $p<0.001$ ) (Figure 2). At the IVS, this relationship, although modest, was also observed (IVS:  $r=0.54$   $p<0.001$ ) (Figure 2). In contrast, the relationship between age and peak systolic velocity at the RVFW and at the RVOT was weak (RVFW:  $r=0.42$   $p<0.001$ , RVOT  $r=0.38$ ,  $p<0.001$ ) (Figure 3). The results of the intra observer and inter observer agreement for the peak velocities were: LV lateral wall: intra observer  $7\% \pm 6\%$ , inter observer:  $9\% \pm 9\%$ , IVS:

intra observer:  $6\% \pm 5\%$ , inter observer:  $14\% \pm 13\%$ , RVFW: intra observer:  $10\% \pm 11\%$ , inter observer:  $17\% \pm 14\%$ , RVOT: intra observer:  $7\% \pm 6\%$ , inter observer  $12\% \pm 13\%$ .

### Timings of peak systolic velocities

Timings of peak systolic velocities are summarized in Table 1. The median time to peak systolic velocity at the LV lateral wall was 101 ms (IQR: 91-112 ms). At the IVS, the median time to peak systolic velocity was 114 ms (IQR 100-118 ms). At the RVFW, the median time to peak systolic velocity was 177 ms (IQR 157-194 ms). The peak systolic velocity at the RVOT occurred prior to that of the RVFW, at 100 ms (IQR: 88-113 ms).

Time to peak systolic velocity at the LV lateral wall and IVS were significantly related with age (LV lateral wall:  $r=0.57$ ,  $p<0.001$ , IVS:  $r=0.41$ ,  $p<0.01$ ) (Figure 4). Similarly, time to peak systolic velocity at the RVFW and RVOT increased significantly along with age (RVFW:  $r=0.58$ ,  $p<0.001$ , RVOT:  $r=0.70$ ,  $p<0.001$ ) (Figure 5). The results of the intra observer and inter observer agreement for the timings of peak velocities were: LV lateral wall: intra observer  $5\% \pm 4\%$ , inter observer:  $14\% \pm 13\%$ , IVS: intra observer:  $6\% \pm 5\%$ , inter observer:  $11\% \pm 8\%$ , RVFW: intra observer:  $7\% \pm 2\%$ , inter observer:  $7\% \pm 5\%$ , RVOT: intra observer:  $7\% \pm 5\%$ , inter observer  $9\% \pm 6\%$ .

### Intra-ventricular time differences

Table 1 shows the median inter-ventricular time delays in the LV and RV in the healthy children. The median time delay between peak systolic velocity at the LV lateral wall and peak systolic velocity at the IVS was very small (median 10 ms, IQR 0-20 ms). In contrast, within the RV, the time difference between the IVS and the RVFW was 62 ms (IQR 45-75 ms), and the median time difference between the RVOT and the RVFW was 74 ms (IQR 59-93 ms). The observed small intra-ventricular time difference within the LV did not change with age. At the RV, the time delay between the IVS and the RVFW showed a weak correlation with age ( $r=0.25$ ,  $p<0.001$ ), whereas the time difference between the RVOT and the RVFW did not relate with age in the healthy subjects.

## DISCUSSION

The present study provides age-related values for peak systolic velocities and timings of peak systolic velocities as assessed with TDI at the basal segments of the LV, RV and of the RVOT in healthy children. The results of the current study show that peak systolic velocities and time to peak systolic velocities increase with age in both ventricles. Furthermore, no intra-ventricular time differences between the basal LV lateral wall and IVS are observed at any age, whereas within the RV, a considerable time delay is present between the basal IVS and the basal RVFW, and between the basal RVFW and the RVOT. Finally, the intra-ventricular time differences within RV did not show relevant changes with age in healthy children.

### Peak systolic velocities

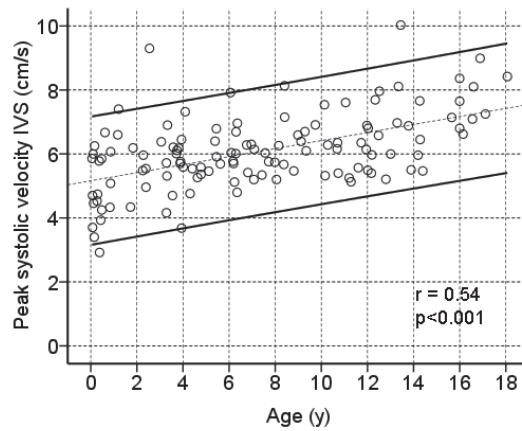
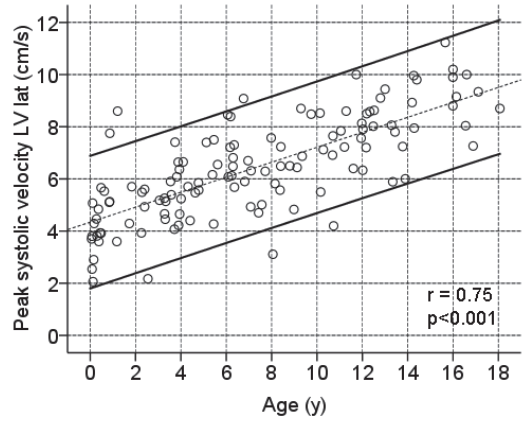
The assessment of peak systolic velocities with TDI provides a quantitative measure of ventricular systolic function. Several studies have demonstrated the value of TDI-derived peak systolic velocities to quantify regional LV and RV ventricular performance in adults with various clinical conditions.(1-5) In pediatric patients, the assessment of peak systolic velocities has been shown to be a sensitive tool to detect myocardial dysfunction.(13,14) The current study provides age-related normal values of peak systolic velocities at the basal LV lateral wall, basal RVFW and at the RVOT with TDI. Peak velocities were highest at the basal RVFW (median 10.2 cm/s) and lowest at the LV lateral wall (median 6.0 cm/s). The observed pattern of different magnitudes of normal peak velocities among the basal LV lateral wall, basal IVS and basal RV is in agreement with previous investigations in children.(5,8,9,15) Furthermore, the observed normal peak velocities at the basal LV and RV increased significantly with age in the current study. This observation is in line with a previous study on the alterations of LV performance during cardiac maturation in healthy children.(16) Notomi and colleagues assessed LV performance in 45 healthy controls by measuring rotational mechanics with TDI. In their study, LV performance increased significantly with age.(16) In contrast, other studies have reported weaker(9) or non-significant(8) relationships between TDI-derived peak velocities at the basal RV and LV and age in healthy children. Kapusta et al. investigated age-related peak systolic velocities at the basal RVFW, IVS and LV lateral wall in 160 healthy children and observed no significant changes with age.(8) However, the age range (4-18 years) of the included subjects was significantly smaller as compared to the present study.

The current report is the first to investigate normal values of peak systolic velocities at the RVOT. The peak systolic velocity at the RVOT was lower than the velocity at the RVFW and showed a significant increase with age. Comprehensive insight into normal values of peak systolic velocities at the RVOT is of interest to evaluate patients with congenital heart disease, specifically those with tetralogy of Fallot.(11,17) Systolic dysfunction at the RVOT has been associated with reduced global performance of the RV.(11,17) Accordingly, the observed normal values on the peak systolic velocity at the RVOT provide a framework for future studies on patients with congenital heart disease and RV failure.

### Timing of peak systolic velocities and intra-ventricular time

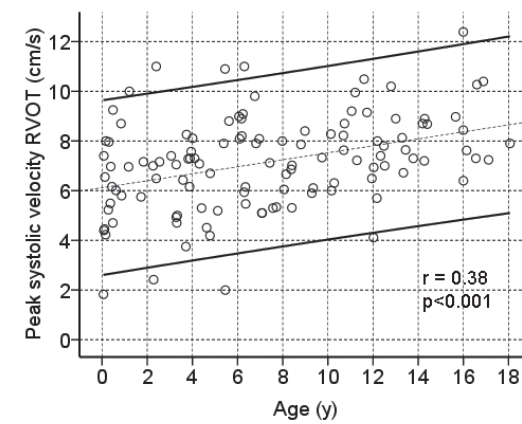
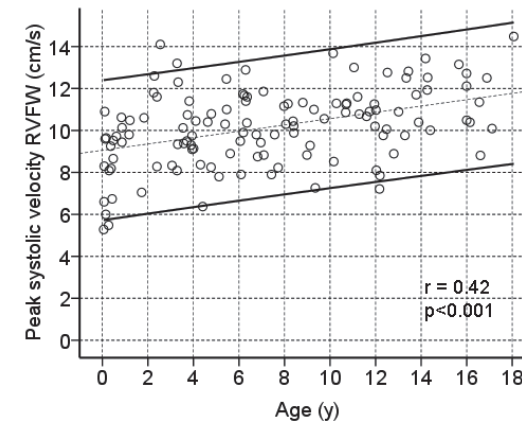
The assessment of timings of peak systolic velocities with TDI yields insight into electromechanical coupling and possible mechanical dyssynchrony. CRT targets dyssynchrony in patients with LV failure by inducing a more synchronous contraction. In pediatric patients, no guidelines for patient selection for CRT are available at present.(18-20) Knowledge on normal values of myocardial velocities, timings and time-differences within the LV as assessed with TDI could play an important role in defining appropriate recommendations for pediatric patients with LV failure who may benefit from CRT. However, a systematic description of the normal temporal occurrence of peak systolic velocities and time differences within the LV has not been previously reported in children. The present study provides insight into the normal electromechanical activation of the LV in children. With a median time difference of 10 ms between the time to peak velocity at the basal LV lateral wall

Figure 2. Relation between age and peak systolic velocity in the LV



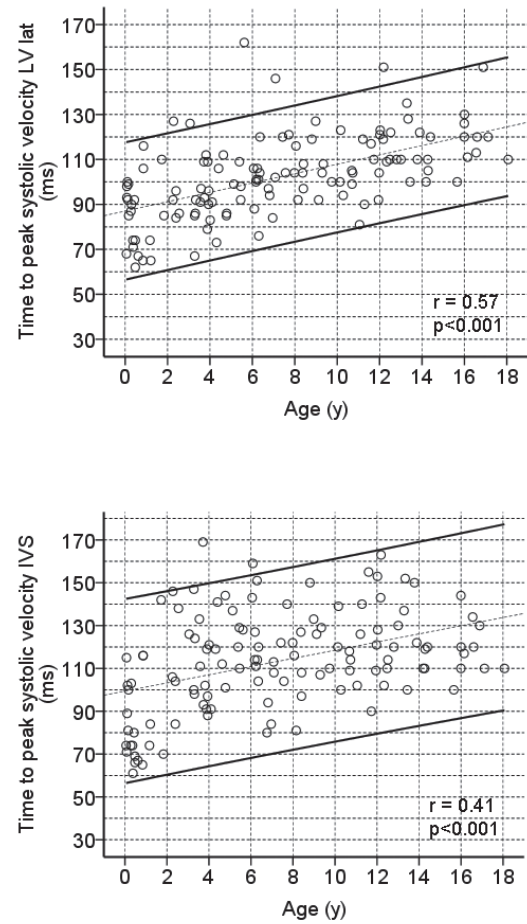
**Upper:** Scatter plot depicting linear relation and 95% reference intervals for age and peak systolic velocity at LV lateral wall. **Lower:** Scatter plot depicting linear relation and reference intervals between age and peak systolic velocity at IVS.  
 Abbreviations: IVS: inter-ventricular septum. LV lat: left ventricular lateral wall.

Figure 3. Relation between age and peak systolic velocity in the RV



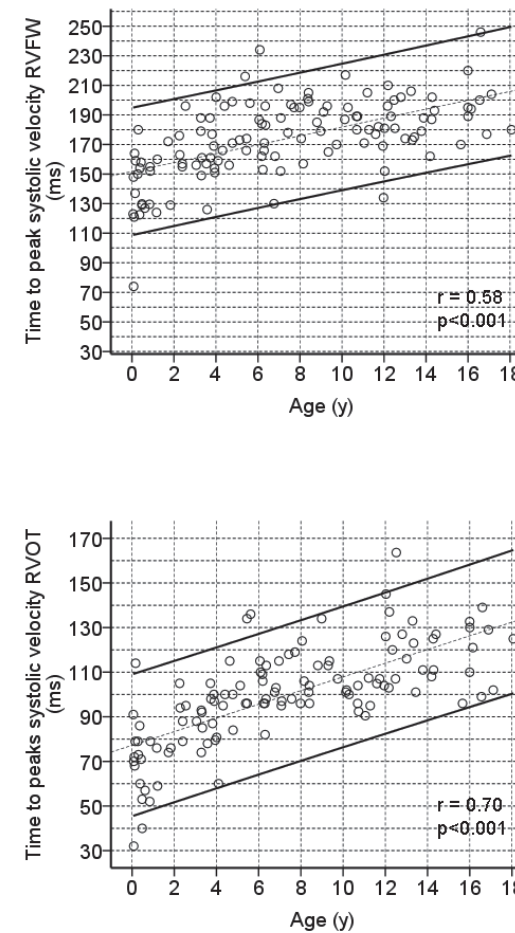
**Upper:** Scatter plot depicting linear relation and 95% reference intervals for age and peak systolic velocity at RVFW. **Lower:** Scatter plot depicting linear relation and reference intervals between age and peak systolic velocity at RVOT.  
 Abbreviations: RVFW: right ventricular free wall, RVOT: right ventricular outflow tract.

Figure 4. Relation between age and time to peak systolic velocity in the LV



**Upper:** Scatter plot depicting linear relation and 95% reference intervals for age and time to peak systolic velocity at LV lateral wall. **Lower:** Scatter plot depicting linear relation and reference intervals between age and time to peak systolic velocity at IVS.  
 Abbreviations: IVS: inter-ventricular septum. LV lat: left ventricular lateral wall.

Figure 5. Relation between age and time to peak systolic velocity in the RV



**Upper:** Scatter plot depicting linear relation and 95% reference intervals for age and time to peak systolic velocity at RVFW. **Lower:** Scatter plot depicting linear relation and reference intervals between age and time to peak systolic velocity at RVOT.  
 Abbreviations: RVFW: right ventricular free wall, RVOT: right ventricular outflow tract.

and the basal IVS, no significant time delay within the LV was observed at any age. These normative data are in line with the results of previous studies including adult population (15), and provide an empirical basis for future studies on LV dyssynchrony in pediatric candidates for CRT.

The RV differs greatly from the LV in terms of anatomy and function. Accordingly, the mechanical activation pattern of the RV may be different from that of the LV. In the current investigation, a significant IVS-to-RVFW delay was observed in the healthy subjects, with a median time difference of 62 ms. Albeit substantially smaller, the presence of an IVS-to-RVFW delay was previously observed with TDI by Hui et al. in a study on 98 healthy children.(7) Moreover, based on their observations, the authors proposed to consider as normal range any IVS-to-RVFW delay below 70 ms.(7) Of note, within the LV, a time delay of 70 ms would indicate significant dyssynchrony.(21) In addition, in the present study, the intra-ventricular time difference between the basal RVFW and RVOT was investigated, yielding a median intra-ventricular time delay of 74 ms. A previous study evaluating RV intra-ventricular timings assessed with TDI showed a similar activation pattern with a significant time delay between the RVOT and RVFW in healthy adults.(5) In the present study, the observed intra-ventricular time differences within the RV did not show a relevant relationship with age. Accordingly, significant intra-ventricular time differences between the IVS and RVFW and between the RVOT and RVFW are present in children of any age.

The presence of a mechanical delay within the RV may have important clinical implications. RV failure is common in pediatric patients with congenital heart disease(22-24) and the best therapeutic approach to RV failure remains incompletely elucidated. CRT has been evaluated as novel therapy for patients with RV failure.(19,25) However, the pathophysiological basis of CRT is the restoration of electromechanical dyssynchrony. With the observed mechanical delay within the healthy RV, this concept of resynchronization may not be applicable to the RV. The application of CRT in patients with RV failure warrants further studies on RV mechanics and its relation with RV performance.

### Study limitations

The relatively small sample size of the study may constitute a limitation. Furthermore, the results of the present study were obtained with equipment from one vendor. A previous study demonstrated that for the assessment of myocardial velocities, different ultrasound systems from different vendors can not be used interchangeably.(26) Accordingly, the presented reference values should be interpreted with caution when using other equipment. Instead of TDI, speckle tracking strain analysis is increasingly used in clinical practice for evaluation of patients with heart failure who may benefit from CRT and early detection of subtle changes in myocardial performance. However, in the pediatric population, speckle tracking strain analysis has been less explored. The higher heart rates observed in small children may challenge the assessment of myocardial strain or even velocities with speckle tracking, a technique strongly dependent on frame rate. Therefore, for this population, TDI might be still preferable. However, additional studies using speckle tracking will confirm whether this technique provides the same results or not.

### CONCLUSIONS

In conclusion, in the present study, reference values are provided on LV and RV peak systolic velocities and timings of peak systolic velocities as assessed with TDI in healthy children. Within the LV, no relevant time-differences were observed at any age. Within the RV of healthy children, an intrinsic time delay was observed, which has implications for future studies on device-based therapies for RV failure.

## REFERENCE LIST

- 1 Alam M, Witt N, Nordlander R, et al. Detection of abnormal left ventricular function by Doppler tissue imaging in patients with a first myocardial infarction and showing normal function assessed by conventional echocardiography. *Eur J Echocardiogr* 2007;8:37-41.
- 2 Dagianti A, Vitarelli A, Conde Y, et al. Assessment of regional left ventricular function during exercise test with pulsed tissue Doppler imaging. *Am J Cardiol* 2000;86:30G-2G.
- 3 Meluzin J, Spinarova L, Bakala J, et al. Pulsed Doppler tissue imaging of the velocity of tricuspid annular systolic motion; a new, rapid, and non-invasive method of evaluating right ventricular systolic function. *Eur Heart J* 2001;22:340-8.
- 4 Mogelvang R, Sogaard P, Pedersen SA, et al. Cardiac dysfunction assessed by echocardiographic tissue Doppler imaging is an independent predictor of mortality in the general population. *Circulation* 2009;119:2679-85.
- 5 Uebing A, Gibson DG, Babu-Narayan SV, et al. Right ventricular mechanics and QRS duration in patients with repaired tetralogy of Fallot: implications of infundibular disease. *Circulation* 2007;116:1532-9.
- 6 Ypenburg C, Westenberg JJ, Bleeker GB, et al. Noninvasive imaging in cardiac resynchronization therapy-part 1: selection of patients. *Pacing Clin Electrophysiol* 2008;31:1475-99.
- 7 Hui W, Slorach C, Bradley TJ, et al. Measurement of right ventricular mechanical synchrony in children using tissue Doppler velocity and two-dimensional strain imaging. *J Am Soc Echocardiogr* 2010;23:1289-96.
- 8 Kapusta L, Thijssen JM, Cuypers MH, et al. Assessment of myocardial velocities in healthy children using tissue Doppler imaging. *Ultrasound Med Biol* 2000;26:229-37.
- 9 Swaminathan S, Ferrer PL, Wolff GS, et al. Usefulness of tissue Doppler echocardiography for evaluating ventricular function in children without heart disease. *Am J Cardiol* 2003;91:570-4.
- 10 Davlourous PA, Kilner PJ, Hornung TS, et al. Right ventricular function in adults with repaired tetralogy of Fallot assessed with cardiovascular magnetic resonance imaging: detrimental role of right ventricular outflow aneurysms or akinesia and adverse right-to-left ventricular interaction. *J Am Coll Cardiol* 2002;40:2044-52.
- 11 Wald RM, Haber I, Wald R, et al. Effects of regional dysfunction and late gadolinium enhancement on global right ventricular function and exercise capacity in patients with repaired tetralogy of Fallot. *Circulation* 2009;119:1370-7.
- 12 van der Hulst AE, Roest AA, Delgado V, Holman ER, de Roos A, Blom NA, et al. Relationship between temporal sequence of right ventricular deformation and right ventricular performance in patients with corrected tetralogy of Fallot. *Heart* 2011;3:231-6.
- 13 Hershenson JA, Zaidi AN, Texter KM, et al. Differences in tissue Doppler imaging between single ventricles after the fontan operation and normal controls. *Am J Cardiol* 2010;106:99-103.
- 14 Vitarelli A, Conde Y, Cimino E, et al. Quantitative assessment of systolic and diastolic ventricular function with tissue Doppler imaging after Fontan type of operation. *Int J Cardiol* 2005;102:61-9.
- 15 Marciniak M, Bijmens B, Baltabaeva A, et al. Interventricular interaction as a possible mechanism for the presence of a biphasic systolic velocity profile in normal left ventricular free walls. *Heart* 2008;94:1058-64.
- 16 Notomi Y, Srinath G, Shiota T, et al. Maturation and adaptive modulation of left ventricular torsional biomechanics: Doppler tissue imaging observation from infancy to adulthood. *Circulation* 2006;113:2534-41.
- 17 Oosterhof T, Mulder BJ, Vliegen HW, et al. Corrected tetralogy of Fallot: delayed enhancement in right ventricular outflow tract. *Radiology* 2005;237:868-71.
- 18 Cecchin F, Frangini PA, Brown DW, et al. Cardiac resynchronization therapy (and multisite pacing) in pediatrics and congenital heart disease: five years experience in a single institution. *J Cardiovasc Electrophysiol* 2009;20:58-65.
- 19 Dubin AM, Feinstein JA, Reddy VM, et al. Electrical resynchronization: a novel therapy for the failing right ventricle. *Circulation* 2003;107:2287-9.
- 20 Janousek J, Gebauer RA, Abdul-Khalik H, et al. Cardiac resynchronization therapy in paediatric and congenital heart disease: differential effects in various anatomical and functional substrates. *Heart* 2009;95:1165-71.
- 21 Bax JJ, Bleeker GB, Marwick TH, et al. Left ventricular dyssynchrony predicts response and prognosis after cardiac resynchronization therapy. *J Am Coll Cardiol* 2004;44:1834-40.
- 22 Dos L, Teruel L, Ferreira JJ, et al. Late outcome of Senning and Mustard procedures for correction of transposition of the great arteries. *Heart* 2005;91:652-6.
- 23 Geva T, Sandweiss BM, Gauvreau K, et al. Factors associated with impaired clinical status in long-term survivors of tetralogy of Fallot repair evaluated by magnetic resonance imaging. *J Am Coll Cardiol* 2004;43:1068-74.
- 24 Helbing WA, Rebergen SA, Maliepaard C, et al. Quantification of right ventricular function with magnetic resonance imaging in children with normal hearts and with congenital heart disease. *Am Heart J* 1995;130:828-37.
- 25 Cowburn PJ, Parker JD, Cameron DA, et al. Cardiac resynchronization therapy: retiming the failing right ventricle. *J Cardiovasc Electrophysiol* 2005;16:439-43.
- 26 Koopman LP, Slorach C, Manlhiot C, McCrindle BW, Friedberg MK, Mertens L, et al. Myocardial tissue Doppler velocity imaging in children: comparative study between two ultrasound systems. *J Am Soc Echocardiogr* 2010;23:929-37.