

Received: 2019.04.12  
Accepted: 2019.06.25  
Published: 2019.09.09

# Modified Radical Mastectomy for Male Breast Cancer

Authors' Contribution:  
Study Design A  
Data Collection B  
Statistical Analysis C  
Data Interpretation D  
Manuscript Preparation E  
Literature Search F  
Funds Collection G

BC **Mahmoud Musa Al Awayshih**  
CF **Mohammad Nabih Nofal**  
ACE **Ali Jad Yousef**

Department of General Surgery and Anesthesia, College of Medicine,  
Mutah University, Karak, Jordan

**Corresponding Author:** Ali Jad Yousef, e-mail: [alijad30@hotmail.com](mailto:alijad30@hotmail.com)  
**Conflict of interest:** None declared

**Patient:** Male, 35  
**Final Diagnosis:** Male breast cancer  
**Symptoms:** Painless breast mass  
**Medication:** —  
**Clinical Procedure:** Modified radical mastectomy  
**Specialty:** Surgery

**Objective:** Unusual setting of medical care

**Background:** Cancer of the male breast is a rare malignancy comprising less than 1% of all male cancers. The traditional surgical management for male breast cancer is modified radical mastectomy. Other surgical methods such as breast conserving surgery with or without sentinel lymph node biopsy have been used with variable results.





**Case Report:** A 35-year old male presented with a 2×2 cm right breast adenocarcinoma. Modified radical mastectomy for male breast cancer as the traditional surgical operation for this rare malignancy is illustrated with special emphasis on oncologic sound resection.

**Conclusions:** Modified radical mastectomy is the corner stone surgical treatment for male breast cancer even though the breast tissue rudimentary. The recurrence of male breast cancer is less with mastectomy than breast conserving surgery.

**MeSH Keywords:** Breast Neoplasms • Breast Neoplasms, Male • Mastectomy, Modified Radical • Mastectomy, Segmental

**Abbreviations:** **BCS** – breast conserving surgery; **FBC** – female breast cancer; **MBC** – male breast cancer; **MRM** – modified radical mastectomy; **SLNB** – sentinel lymph node biopsy; **TRAM** – transverse rectus abdominis myocutaneous

**Full-text PDF:** <https://www.amjcaserep.com/abstract/index/idArt/916947>

 1324   4  10



## Background

Until now, prospective randomized trials to support a specific treatment approach in male breast cancer are not available. Most of the treatment modalities used in male breast cancer are gained from data from female breast cancer trials.

Surgery is the cornerstone management of male breast cancer. For most of the 20<sup>th</sup> century the usual surgical management for localized male breast cancer was radical mastectomy, until the 1970s when it was replaced by more conserving surgical operations such as modified radical mastectomy or simple mastectomy [1]. Currently modified radical mastectomy is the traditional surgical treatment of male breast cancer because of the scarce male breast tissue, the usual retroareolar neoplasm location, early involvement of the nipple, and the unwanted side effects of adjuvant therapy necessary in breast conserving surgery [2].

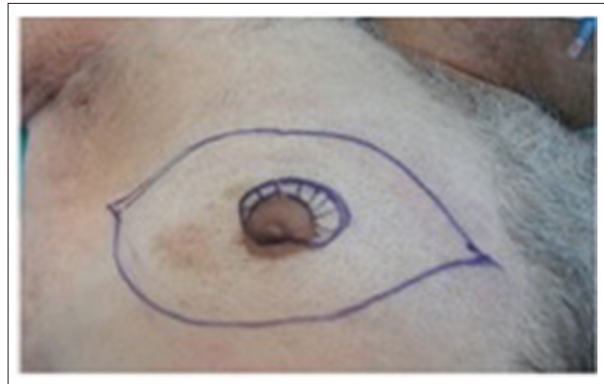## Case Report

A 35-year-old male presented with a 3-month history of slowly growing right breast mass destroying the nipple with bloody discharge and mild pain. His family history was negative for male or female breast cancer. He had no history of radiation exposure or hormonal treatment. Physical examination showed right right breast hard retroareolar mass with destructed nipple and bloody nipple discharge and palpable firm right axillary lymph nodes. Mammography and ultrasonography showed a 2×2 cm right breast mass with enlarged axillary lymph nodes. Core biopsy proved right breast triple negative adenocarcinoma. On full recovery the patient returned to his home country and was lost to follow up.

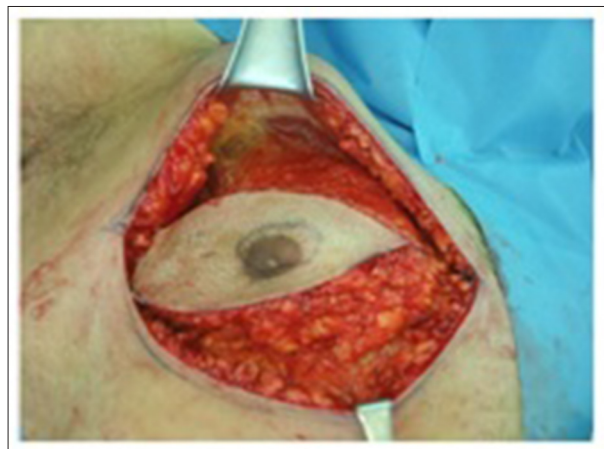## Surgical technique

The surgery was done using general anesthesia and the patient positioned supine, the arm on the surgery site abducted, and the right shoulder supported with a pillow as needed. Marking of the skin incision was done in an elliptical fashion to include the nipple areola complex and the skin overlying the tumor and to facilitate closure without tension, if possible. The incision extended from the sternal edge medially to the latissimus dorsi muscle anterior border (Figure 1).

Breast dissection started with creating upper and lower flaps. The difference from the female breast operation is that the Cooper's ligament which usually determines the level of dissection between the subcutaneous fat and breast fat is absent in the male breast. Thus, dissection should be carried out with wise judgment not to leave thin skin and have skin necrosis, or thick subcutaneous fat and risk recurrence. Dissection was



**Figure 1.** Marking of the skin incision in an elliptical fashion. The tumor site is over shadowed.

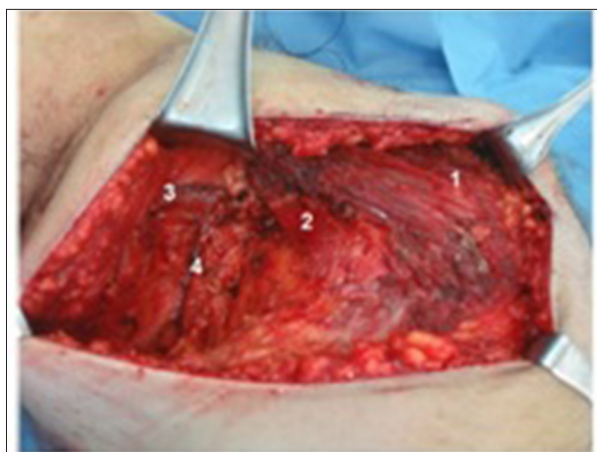

**Figure 2.** Creating upper and lower dissection flaps, showing clavipectoral fascia.

carried out in the upper flap to reach the clavipectoral fascia superiorly (Figure 2), edge of the sternum medially, and the outer edge of pectoralis major muscle laterally.

The lower flap was created to the presumed infra mammary fold crease. The fibers of abdominal external oblique and serratus anterior muscles are reached in dissection bed. Dissection medial and lateral borders are the same for the upper flap.

The next step was to elevate the breast tissue from the deep pectoral fascia, and it was preferably started from the upper medial angle operating downwards obliquely. The common difference from a female operation is that the breast tissue in males is rudimentary and retro areolar is the most common site of the tumor. However, sometimes the tumor is eccentric, and care should be taken to have a sound resection of the deep margin. A major anatomical difference between female and male breast tissue is that the superficial and deep pectoral fascia enclosing the breast in the female is loose areolar tissue covering the pectoralis major muscle in the male, so sometimes it is necessary to excise the pectoralis major



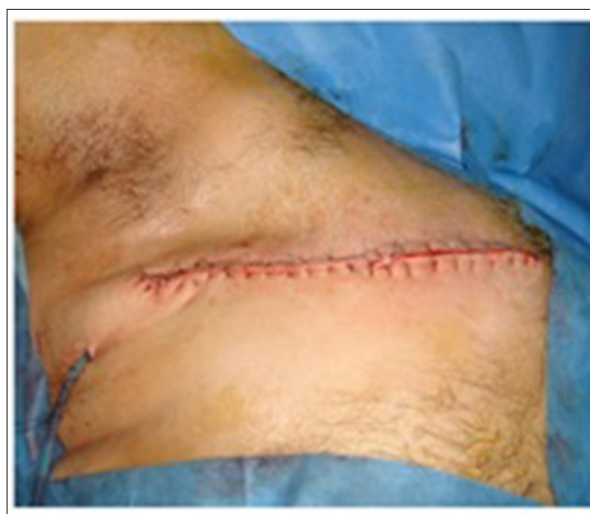**Figure 3.** Dissection bed showing (1) the pectoralis major muscle, (2) the pectoralis minor muscle, (3) the axillary vein, and (4) the long thoracic neurovascular bundle.

muscle aponeurosis or part of the muscle itself if involved by the tumor as judged pre- and intra-operatively (Figure 3). The whole specimen in our patient case was on the pectoralis major muscle lateral margin.

The next step was to enter the axilla through incising pectoral fascia on the pectoralis major muscle outer margin to clear the axillary content en bloc with the breast. Fibrofatty tissue was dissected away from the underlying chest wall muscle reaching behind the pectoralis major muscle and retracting it medially until the lateral edge of the pectoralis minor muscle was reached medially and axillary vein superiorly. This accomplished level I dissection of axillary lymph nodes. Sentinel lymph node biopsy was not planned because of the clinically palpable lymph nodes. Dissection included fibro fatty tissue behind the pectoralis minor muscle and below the axillary vein ends level II axillary lymph nodes dissection (Figure 3). In general, there was usually no need to do level III dissection except in specific situations, and no need to do dissection above the axillary vein, thus minimizing the risk of upper limb lymphedema.

The axillary fat containing the lymph nodes was cleared from the axillary vein by doubly ligating at 1 or 2 vertical tributaries. However, ligation of any vessel running horizontally is generally prohibited for fear of being a normal variation of the axillary vein. The long thoracic and thoracodorsal vessels and nerves should be identified and meticulously spared while dissecting the fibro fatty tissue down between them. The specimen was taken out after cutting the axillary content at the lower edge at the level of the angular vein. The wound was closed without tension over a vacuum drain inserted in the axilla (Figure 4).

Simple closure over 2 vacuum drains was achieved without tension. Finally, the specimen was oriented for pathologic examination.



**Figure 4.** Wound closure without undue tension can be achieved with staples or interrupted or continuous mattress or subcuticular sutures over a vacuum drain.

## Discussion

There are no specific guidelines for male breast cancer treatment as there are for female breast cancer. Indeed, most coregional management data came from retrospective or pilot studies, with a possible bias from data analysis collected over a long period of time.

The types of surgical operations for male breast cancer are: radical mastectomy in which the nipple-areola complex, which is the most common site for the neoplasm, is excised together with wide skin elliptical margins en bloc with underlying pectoralis major muscle and axillary dissection; modified radical mastectomy in which the nipple-areola complex and breast skin and underlying fat are removed en bloc with the axillary content with preservation of the pectoralis major muscle, although sometimes part of the muscle can be excised if involved by the tumor; simple mastectomy in which the nipple-areola complex and surrounding skin eclipse and underlying fat are removed without the axilla; lumpectomy in which the mass is excised with a safety margin of 2 cm usually.

The types of surgeries used to treat male breast cancer are modified radical mastectomy in 70% cases, radical mastectomy in 8–30%, total mastectomy in 5–14%, and lumpectomy with or without irradiation in 1–13% as shown in earlier reports [3,4]. Recent reports showed increasing trend towards breast conserving surgery reaching up to 17% in all male breast cancer surgically treated cases [5]. Radical mastectomy involves nipple-areola complex and wide skin excision resulting sometimes in difficult skin and chest wall closure. Reconstructive surgical methods such latissimus dorsi or transverse thoracoepigastric skin flaps have been used to close the chest wall [6].

Transverse rectus abdominis myocutaneous (TRAM) flap was preferred by other surgeons because it will replace the resected skin and fat with a hairy skin similar to the skin of the male breast. The nipple-areola complex can be reconstructed by tattoo or surgery [7].

For selected male patients with small tumors or when the breast neoplasm is associated with gynecomastia; breast conserving surgery followed by radiotherapy produced encouraging results [8]. To prevent the undesirable axillary lymph nodes dissection side effects such as lymphedema and nerve injuries, sentinel lymph node biopsy in male breast cancer cases was used and proved to be feasible and reliable in predicting the status of axillary nodal involvement with detection rate close to 100% [9]. Sentinel lymph node biopsy is indicated when the

tumor size is smaller than 2.5 cm with no clinical evidence of axillary lymph nodes metastases [10].

## Conclusions

Male breast cancer should be managed as a rare malignant disorder. However, surgery in the form of modified radical mastectomy is the standard choice albeit rudimentary breast tissue and new methods of breast conserving surgery are evolving.

## Conflict of interest

None.

## References:

1. Goss PE, Reid C, Pintilie M et al: Male breast carcinoma: A review of 229 patients who presented to the Princess Margaret Hospital during 40 years: 1955–1996. *Cancer*, 1999; 85: 629–39
2. Cutuli B, Lacroze M, Dilhuydy JM et al: Male breast cancer: Results of the treatments and prognostic factors in 397 cases. *Eur J Cancer*, 1995; 31A: 1960–64
3. Cutuli B: Strategies in treating male breast cancer. *Expert Opin Pharmacother*, 2007; 8: 193–202
4. Sousa B, Moser E, Cardoso F: An update on male breast cancer and future directions for research and treatment. *Eur J Pharmacol*, 20137; 17: 71–83
5. Zaenger D, Rabatic BM, Dasher B: Is breast conserving therapy a safe modality for early-stage male breast cancer? *Clinical Breast Cancer*, 2016; 16: 101–4
6. Caglia P, Veroux PF, Cardillo P et al: [Carcinoma of the male breast: Reconstructive technique.] *G Chir*, 1998; 19: 358–62 [in Italian]
7. Spear SL, Bowen DG: Breast reconstruction in a male with a transverse rectus abdominis flap. *Plast Reconstr Surg*, 1998; 102: 1615–17
8. Golshan M, Rusby J, Dominguez F, Smith BL: Breast conservation for male breast carcinoma. *Breast*, 2007; 16: 653–56
9. Kamila C, Jenny B, Per H, Jonas B: How to treat male breast cancer. *Breast*, 2007; 16: 147–54
10. Gennari R, Curigliano G, Jereczek-Fossa BA et al: Male breast cancer: A special therapeutic problem. Anything new? (Review). *Int J Oncol*, 2004; 24: 663–70