Tapping pain is most marked on tapping the head of the third metacarpal when the hand is in ulnar flexion.

DIFFERENTIATION FROM DISLOCATION OF THE SEMILUNAR

(*a*) In dislocation there is appreciable thickening of the wrist due to, (*i*) prominence on the dorsum formed by the head of the os magnum displaced backwards, and (*ii*) swelling in front beneath the flexor tendons caused by the dislocated semilunar. In fracture there is swelling of the wrist, but not so much thickening.

(*b*) Shortening of the carpus as evidenced by the position of the head of the third metacarpal. The head is at the same level or proximal to the heads of the second and fourth metacarpals in dislocation. In fracture the head of the third metacarpal is distal to the others as in a normal case.

(*c*) In dislocation slight palmar flexion is possible, but dorsal flexion is resisted, whereas in fracture slight dorsal flexion is usually permitted.

(*d*) Dislocation generally produces symptoms due to pressure on the nerves or vessels. This is hardly ever present in fracture.

(*e*) Tapping pain is absent in dislocation.

(*f*) *X*-ray. In a lateral skiagram in dislocation the concavity of the semilunar does not fit like a cup on the head of the os magnum.

Prognosis.—With early diagnosis and treatment, it is good, but Kienböck's disease is liable to supervene later on.

Treatment.—Germans advocate removal of the bone in all cases. French and British surgeons prefer more conservative methods and advise immediate mobilisation massage and movement in addition to alternate hot and cold douches. If in spite of this the patient does not improve, the bone should be removed. This is further recommended on the ground that Kienböck's disease is liable to supervene.

For removal of the bone British surgeons use a dorsal incision, about 2 inches long, over the lower end of radius and the carpus. Destot prefers a horse-shoe-shaped incision over the middle fold of the flexure of the wrist, between the tendons of palmaris longus and palmaris brevis. He thinks that operation by the posterior route is much more difficult and mutilating. The operation is much easier with a tourniquet round the arm.

REFERENCES

Bankert (1932). *Manipulative Surgery*, p. 114.
Brown, K. P. (1928). *Brit. Med. Journ.*, Vol. I, p. 591.
Destot, E. (1925). *Injuries of the Wrist*, p. 57.

HYDATID DISEASE IN SOUTH INDIA

By V. MAHADEVAN, M.R.C.P., F.R.C.S.E.
MAJOR, I.M.S.
Superintendent, Royapuram Medical School, and Surgeon, Government Royapuram Hospital, Madras
and
T. BHASKARA MENON, M.D., M.R.C.P.
Pathologist, Government Royapuram Hospital and Medical School, Madras

FEW cases of hydatid disease have been reported in India. The general impression is that the disease is rare. It is only occasionally that cases appear in the hospitals in large towns, and even these very often are not clearly brought out in hospital reports. The provincial annual reports in India show no separate heading for hydatid disease, and in hospital reports they are included under tumours. It is therefore difficult to arrive at an estimate of the real prevalence of the disease in India. The dog, the natural host of the *Ecchinococcus granulosus*, though present in numbers, is rarely the household pet and companion of man as in

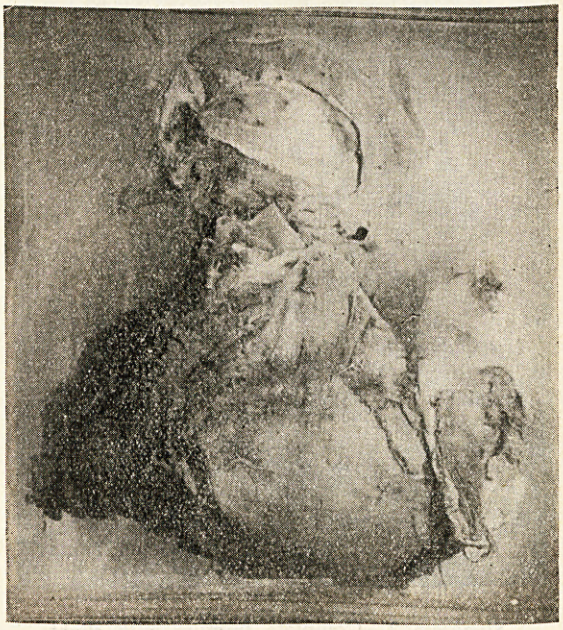

Illustration showing the large cyst arising from the lower pole of the left kidney. A portion of the hydatid membrane can be seen projecting from a tear in the upper part of the cyst.

Europe and Australia. Amongst both Mohammedans and Hindus, owing to religious scruples, dogs are rarely allowed in-doors. This might be a possible explanation of the rarity of the disease here, but it is equally possible that, as the senior writer holds, the condition is frequently overlooked. This paper therefore is intended to emphasise the not uncommon occurrence of this condition in south India where the senior writer has met with seven cases in the course of the last eight years.

The only possible means of estimating the prevalence of this condition in south India, since hospital reports are so meagre in this respect, is by an analysis of the cases of proved hydatid disease that are reported as such by the pathological department of the Madras Medical College, which serves as a central laboratory to which most specimens from the district and mofussil hospitals are sent up for pathological examination. We have been able to analyse the number of cases of proved hydatid disease through the courtesy of Dr. A. Goyle, professor of pathology of the Madras Medical College, from the records of the last 10 years. No cases were reported in 1923, 1926, 1927 and 1929; the incidence in the other six years is as follows :—

Year	Number of cases	Site of cyst	District
1924	one	liver	Madras
1925	one	abdomen	Madras
1928	one	liver	Madras
1930	two	abdomen	Madras
		liver	Madras
1931	one	not known	Anantapur
1932	two	liver	Kurnool
		neck	Anantapur

It will be noticed that only eight cases have been reported for the whole of the presidency during the last ten years.

The cases reported below serve to show that the real incidence is more than is apparent from the above figures, if care is taken to look out for this condition. It is possible that many cases of obscure enlargement of the liver looked upon as abscess or gumma are really cases of hydatid disease. Some puzzling abdominal tumours may come under the same head. These cases also serve to show what varying clinical types are presented. Five of these cases occurred while the senior writer was out in the districts during a period of six years, and the other two were patients that came up to Madras and were admitted to the wards of the Government Royapuram Hospital for treatment.

Case 1. *Cyst of the liver.*—R., Hindu, aged 45 years, came up for treatment to the District Headquarters Hospital, Vellore, in 1923 for a cystic tumour of the liver. On operation it was found that the cyst extended down into the peritoneal cavity and had formed adhesions to the colon and small intestines. It was a unilocular hydatid. Adhesions rendered the removal of the tumour *en masse* impossible, so the cyst was opened, irrigated and touched with formalin; the patient recovered without any complications.

Case 2. *Cyst of the breast simulating cystadenoma.*—Mrs. K. P., a young married Hindu lady, aged 35, came up for treatment to the District Headquarters Hospital, Guntur, in July 1929 for a tumour of the breast of four months' duration. The tumour was of the size of an orange, cystic and slightly tender. No suspicion of hydatid disease was entertained, since cystadenoma of the breast with large cysts is quite a common condition. On operation, however, it was found to be a large hydatid with a well-developed thick ectocyst and a delicate endocyst, besides the fibro-fatty capsule outside the cyst. A number of daughter and grand-daughter cysts were found inside the primary cyst indicating an endogenous development.

Case 3. *Cyst of the abdomen simulating ovarian cyst.*—C., a young Hindu lady, aged 31, came to the Hospital for Women and Children, Vannarpet, Palamcottah, in August 1926, for a tumour of the abdomen of two years' duration. The patient was a multipara and had four children. There was a large cystic tumour in the abdominal cavity. On operation this was found to be a large hydatid arising from the omentum, adherent behind but freely movable in front. The cyst was multilocular having three septa and containing daughter and grand-daughter cysts. The cyst was marsupialized and the patient had an uneventful recovery.

Case 4. *Cyst of the liver.*—J. C., a young Indian Christian girl of 25 years, came to the same hospital at Vannarpet for cystic tumour of the liver, in March 1925. The cyst was of two years' duration and extended down into the abdominal cavity. On operation it was found to arise from the under surface of the liver and to extend down to Poupart's ligament, displacing the liver upwards and pressing on the diaphragm. There were numerous adhesions to the omentum and coils of the intestine. The liver substance was stretched out and atrophied. Small cysts indicating an exogenous development were found in the right lobe of the liver. The cyst itself was multilocular. The patient made an uneventful recovery after operation.

Case 5. *Suppurating hydatid simulating subphrenic abscess.*—In July 1927, in Madura, K. A., a young Chetty girl, aged 13, was seen by the senior writer in consultation, for a swelling in the region of the liver. There was a history of fever with rigors for one month, and the gradual formation of a swelling in the upper abdomen on the right side. The blood showed a leucocytosis. The clinical features were suggestive of subphrenic suppuration, and exploration and drainage were decided upon. The tumour was incised and pus, yellowish in colour with no fæcal smell, was found. A large amount was evacuated, but the sinus persisted. Fifteen days after the operation, gentle pressure brought out two small daughter cysts. The incision was therefore enlarged, all the daughter cysts were removed, and the wall was touched with formalin. The wound healed without any further trouble.

Case 6. *Multiple peritoneal cysts causing retention and extravasation of urine.*—K., a Hindu, aged 46 years, was admitted to the Government Royapuram Hospital in September 1931 for extravasation and retention of urine. Rectal examination showed a lumpy growth in the sacral region which was irregular. Nothing could be made out through the anterior abdominal wall owing to rigidity. A sacral tumour causing pressure on the urethra was thought possible, but on exploration the whole pelvis was found filled with five or six cysts covered over by the omentum. These were removed *en masse*, and microscopical examination showed typical hydatid structures with hooklets.

Case 7. *Hydatid cyst of the kidney.*—Mrs. M. B., a Mohammedan lady, was admitted to the Government Royapuram Hospital in January 1932. She had come from Guntur district for treatment for a swelling in the left side of the abdomen of five years' duration. It had started as a small tender swelling in the left lumbosacral region and had gradually increased in size for the last five years, till it extended from very near the left costal margin to the iliac crest. There had been a low type of fever for some months. The patient was a multipara, had three children, two boys and one girl, and her menstrual history was regular. Her general health was good. On examination the tumour was found to be tense and cystic, and to occupy the whole of the left side of the abdomen with a small projection to the right side about one inch above the umbilicus, There was slight movement with respiration. The skin was freely movable and the tumour itself was slightly movable from side to side. The surface was irregular and appeared divided into three lobes. The differential leucocyte count showed marked lymphocytosis. Eosinophiles were only 3.5 per cent. There was no

albumin in the urine, and urinary symptoms were absent. On operation the tumour was found to be a large cyst arising from the lower pole of the left kidney. The descending colon was adherent to the left side. The cyst had pressed on the ureter below and caused a slight hydronephrosis. The cyst and the left kidney were removed and on examination all the three layers of the hydatid were made out. The outer was the fibro-fatty capsule of the kidney. The contents consisted of clear watery fluid. Microscopical examination of a scraping from the endocyst showed scolices and hooklets.

Comment.—The occurrence of hydatid cysts in the breast in case 2 is certainly unusual, and is a factor to be borne in mind in the diagnosis of cystic tumours of the breast. The development of multilocular cysts in cases 3 and 4 is not in agreement with the idea of a restricted geographical distribution; this is claimed to be different from that of ordinary unilocular cysts. On the other hand, these cases occurring in India suggest that the multilocular cyst is a mere variation in the development of the cyst, which might be partly due to a defective formation of the ectocyst allowing an extra-capsular budding. In case 6 the multiple peritoneal implantation cysts apparently arose from a primary cyst in the recto-vesical pouch. Retention of urine due to pressure of a cyst on the prostatic urethra has not been hitherto reported, and might puzzle the clinician if this condition is not borne in mind. The cyst of the kidney in case 7 offered great diagnostic difficulties since abdominal tumours in this situation show many variations from the common clinical types.

It is noteworthy that an examination of the blood in cases 6 and 7 did not reveal an eosinophilia. The eosinophilia of hydatid disease, while it may be well marked at the commencement, may gradually subside, probably because the mother membranes undergo degenerative changes. This fact should be borne in mind and the absence of eosinophilia should not be taken as a negative indication, especially in old cases.

In view of the recent work on Casoni's intradermal reaction for hydatid disease and the positive results in 90 per cent. of cases reported by Dew and Kellaway, it is worth while that this simple cuti-reaction be made use of in India in all obscure tumours and cysts that occur in and about the abdomen.

THE ZONDEK-ASCHHEIM TEST FOR PREGNANCY AS STUDIED IN 200 CASES*

By K. B. MUKERJEE, B.SC., M.B., CH.B. (Edin.), L.M. (Dublin)
Clinical Laboratory, Mackinnon, Mackenzie & Co., Calcutta

THE investigations of Zondek, Aschheim, and Popanicolaou on the functions of certain of the glands of internal secretion are now so well known that they are even a subject of undergraduate physiology. These studies have incidentally led on to a biological test of pregnancy, known as the Zondek-Aschheim (1928) reaction; it is with this test that this paper is concerned.

After I had carried out the original test on twenty cases I began to doubt if the test could have a wide application since the clinician has to wait for the report for five days—rather a long time when he is faced with a case of, say, tubal pregnancy.

The use of immature white mice has some practical disadvantages; the disadvantages are: (*a*) sex-differentiation—recognition of the sex of immature mice is by no means easy; (*b*) the animals have to be bred for quite a long time to obtain immature females of nearly the same age ready for the test; (*c*) these small animals do not tolerate injections of large quantities of fluids, and thus the speed of the test—a matter of importance in most cases in which we want to do the test—is sacrificed by the necessity for continuing the injections for 3 or 4 days.

For this and other reasons Reinhart and Scott (1931) and other workers have used the rabbit for pregnancy tests. It is not necessary to use immature female rabbits provided they are not pregnant, but for the sake of uniformity of results and in order to produce a maximal reaction it is better to use immature animals of nearly the same age, say, 2½ months old.

A catheter specimen of urine need not be used. It will be better however to use such specimens whenever possible. It is moreover desirable to know the drugs—such as alkaloids and the heavy metals—the patient might have been taking, and to test all specimens for albumin and micro-organisms. Sometimes I injected contaminated urines without any untoward effects, but more often the animals developed peritonitis within 12 hours. In cases of bacilluria I have found the procedure recommended by Stewart (1931) most helpful. This consists in shaking the urine with a little ether and allowing the ether to evaporate from the urine in the incubator. Then the sample is for all practical purposes sterile.

The intraperitoneal has certain advantages over the intravenous route, because large quantities of fluids are more easily introduced and because rabbits are very liable to die soon after intravenous injection of urine containing albumin —a substance we do not infrequently find in the urine of pregnant women. Some workers have advocated the intravenous injection of 5 c.cm. of urine on two consecutive days, but I gave one injection of 10 to 15 c.cm. intraperitoneally, in order to save time.

Finally, for suspected cases of chorionic epithelioma I used concentrated urine. As the anterior-pituitary hormone is thermolabile at 60°C. the best procedure is to evaporate the urine *in vacuo* at 45°C. With a good vacuum pressure 100 c.cm. of urine can be reduced to 10 c.cm. at this temperature in about two hours.

* Rearranged by the Editor.