

Skin Hyperpigmentation and Increased Angiogenesis Secondary to Vitamin B12 Deficiency in a Young Vegetarian Woman

Kyriaki Aroni, Konstantina Anagnostopoulou*, Eugenia Tsagrioni and Eleftherios Ioannidis

Department of Dermatopathology, University of Athens, 50 Nikiforou Lytra Street, GR-11474 Athens, Greece. *E-mail: nantin75@yahoo.com

Accepted August 28, 2007.

Sir,

Reversible skin hyperpigmentation is one of the pigmentary changes associated with vitamin B12 deficiency. It is observed in patients with megaloblastic, non-pernicious anaemia, mainly in those with dark-coloured skin (1–3).

We describe here a case of a 21-year-old Greek woman in whom hyperpigmentation (reddish-brown colour) was confined to the lateral surfaces of the legs. Increased angiogenesis was observed histologically in these areas.

CASE REPORT

A 21-year-old Caucasian female was referred to us because of gradually increasing hyperpigmentation on her legs, observed since she was 4 years old. The hyperpigmentation started from the inner thigh and had extended over the tibia over the past few years. She also reported developing concurrent “finger deformity”.

Her medical history included primary growth hormone deficiency, for which she had been treated with subcutaneous injections of growth hormone. She had been a vegetarian since she was 3 years old and did not consume any milk products.

Physical examination revealed reticulated dark brown with reddish hue hyperpigmentation on both lateral surfaces of her legs (Figs 1a, 2A). Moreover, her fingers were in varying degrees of fixed flexion with impaired extension in all digits (Fig. 2B). The contractures were painless. No nail or tongue abnormalities were observed and neurological examination was normal.

Routine investigations were within normal limits, with no changes in chronic B12 deficiency, except a low serum B12 concentration of 100 pg/ml (normal 160–900

pg/ml) and mild macrocytosis. Ht=37.5%, Hb=12.5 g/dl, MCV=96 fl (normal=78–95 fl), PLT=250000, PT=13.5 s, INR=1, APTT=35.6 s. Serum folate, Zn, ferritin, TIBC, T3, T4, TSH, DHEA, DHEA-S and ACTH were all within normal limits. The anti-intrinsic factor antibodies, anti-parietal cell antibodies, anti-microsomal thyroid and anti-thyrospherine antibodies, anti-gliadin and anti-tissue transglutaminase antibodies, anti-dsDNA, anti-ENA, RNP, anti-SM, SSA(Ro), SSB(Lo), antiJO1 and Ra-test were negative. Plain film radiological studies of her hands were normal, as was electromyography. The patient refused to undergo upper gastrointestinal endoscopy.

Skin punch biopsies 4 mm in diameter were performed on her right crural and tibial areas. Microscopy showed increased numbers of basal cell layer melanocytes, as well as increased melanin granules in the basal layer and supral basal layer (Fontana stain). Multiple clusters of vessels CD34-positive (Fig. 3a,b) with a few lymphocytes and plasmacytes around them were observed in the dermis, as well as free melanin granules. Moreover, an increased number of fibroblasts and some giant cells were noted in the reticular dermis. Distortion of collagen fibres was found. Orcein (Shikata) staining revealed fragmented elastic fibres in the reticular dermis. There was an increased number of mast cells around the vessels. Vascular endothelial growth factor (VEGF) was weakly expressed by some endothelial and plasma cells. Perl's technique for haemosiderin was negative.

On the basis of the history and laboratory investigations the hyperpigmentation was attributed to vitamin

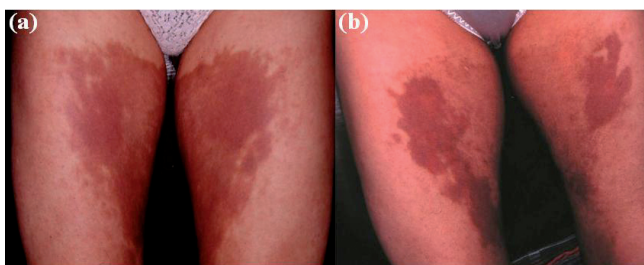


Fig. 1. (a) Brown colour with red hue on the inner thighs. (b) Decreased hyperpigmentation 3 months after treatment. Note the residual reddish hue.

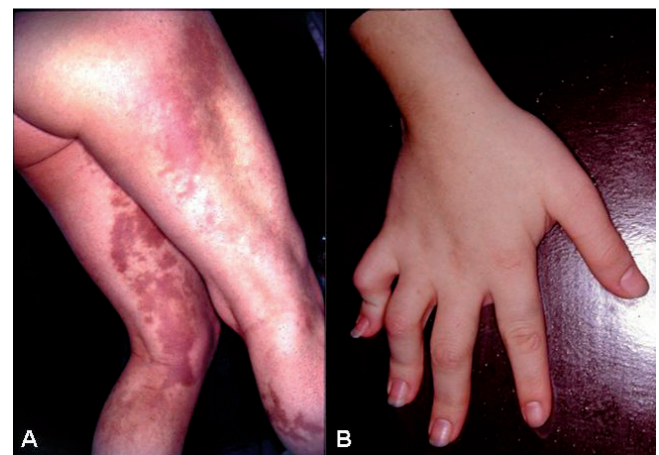

Fig. 2. (A) Hyperpigmentation of the lateral sides of the legs. (B) Distortion of the fingers.

B12 deficiency. The patient was treated with intramuscular B12 (1 mg daily for 7 days, 1 mg/week for 3 weeks and 1 mg/month for 3 months, for maintenance). Parenteral therapy was followed by oral cyanocobalamin supplementation of 1000 µg daily. Furthermore, the patient adopted a well-balanced diet, rich in red meat and milk products.

A remarkable improvement in the degree of her hyperpigmentation was noted 3 months after treatment. First the brownish and then the reddish parts of the hyperpigmentation diminished. (Fig. 1b). One year after treatment, she just follows a well-balanced diet, serum B12 concentration has reached 430 pg/ml, and the hyperpigmentation is gradually resolving.

DISCUSSION

Vitamin B12 deficiency may be associated with a number of pigment changes. Typically, these involve hyperpigmentation, mostly localized in the dorsum of the hands, fingers and feet and sometimes in skin folds and mucosal surfaces. The skin hyperpigmentation may be associated with finger-nail pigment changes and premature grey hair, both reversible after treating the anaemia (1–3). In the majority of Caucasian cases, the pigment changes are spotty or reticulated, usually involving different parts of the body rather than being generalized (1–3). To our knowledge, co-existence of growth hormone deficiency and skin hyperpigmentation has not been reported previously.

This case has 2 interesting clinical features. First, the presence of disfigurement of all her fingers and, secondly, the reddish hue of the hyperpigmentation, which diminished after treatment with vitamin B12.

Megaloblastic anaemia has been reported to be associated with rheumatoid arthritis and human degenerative bone arthritis, but, to our knowledge, not with distortion of the fingers of the type observed in our patient (4).

The increased number of dermal blood vessels was considered to be responsible for the reddish hue. More-

over, vascular endothelial growth factor was weakly expressed by some endothelial and plasma cells. This is in accordance with reports suggesting that a weak or inconstant expression of VEGF is observed in benign anaemias, including B12 deficiency (5, 6). Therefore, chronic B12 deficiency or another angiogenetic factor may have been promoting the observed angiogenesis, which was reversible after treatment with B12. This was clinically established on the basis of diminishing skin redness.

Another histopathological finding was the increased mast cell number. Mast cells have been shown to accompany angiogenesis (7). Moreover, we observed an increased number of fibroblasts, distortion of collagen and fragmented elastic fibres in the reticular dermis. It is reported that fibroblasts in patients with megaloblastic anaemia present genetic deformations and fail to synthesize some enzymes and amino acids, such as methionine and serine (8, 9).

Reversible skin hyperpigmentation is a well-known clinical finding in vitamin B12 deficiency. In our case, vitamin B12 was also associated with reversible angiogenesis of the skin. Further investigation is needed to evaluate the relationship between vitamin B12 deficiency and angiogenesis.

REFERENCES

- Hoffman CF, Palmer DM, Papadopoulos D. Vitamin B12 deficiency: a case report of ongoing cutaneous hyperpigmentation. *Cutis* 2003; 71: 127–130.
- Mori K, Ando I, Kukita A. Generalized hyperpigmentation of the skin due to vitamin B12 deficiency. *J Dermatol* 2001; 28: 282–285.
- Lee SH, Lee WS, Whang KC, Lee SJ, Chung JB. Hyperpigmentation in megaloblastic anemia. *Int J Dermatol*, 1988; 27: 571–575.
- Wilhelmi G. Potential influence of nutrition with supplements on health and arthritic joints. Nutritional quantity, supplements, contamination. *Z Rheumatol* 1993; 52: 191–200.
- Vacca A, Ria R, Ribatti D, Semeraro F, Djonov V, Di Raimondo F, Dammacco F. A paracrine loop in the vascular endothelial growth factor pathway triggers tumor angiogenesis and growth in multiple myeloma. *Haematologica* 2003; 88: 176–185.
- Vacca A, Frigeri A, Ribatti D, Nicchia GP, Nico B, Ria R, et al. Microvessel overexpression of aquaporin 1 parallels bone marrow angiogenesis in patients with active multiple myeloma. *Br J Haematol* 2001; 113: 415–421.
- Crivellato E, Beltrami CA, Mallardi F, Ribatti D. The mast cell: an active participant or an innocent bystander? *Histol Histopathol* 2004; 19: 259–270.
- Fowler B, Whitehouse C, Wenzel F, Wraith J. Methionine and serine formation in control and mutant cultured fibroblasts: Evidence for methyl trapping and characterization of Remethylation defects. *Pediatr Res* 1997; 41: 145–151.
- Gravel R, Mahoney M, Ruddle F, Rosenberg L. Genetic complementation in heterokaryons of human fibroblasts defective in cobalamin metabolism. *Proc Nat Acad Sci* 1975; 72: 3181–3185.

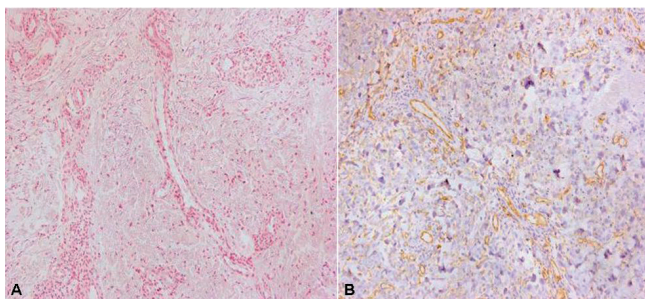


Fig. 3. (A) Multiple clusters of vessels and a few lymphocytes and plasmacytes around them in the dermis (haematoxylin-eosin (H&E) ×200). (B) Increased number of vessels and CD34-positive endothelial cells (immunohistochemistry ×200).