Acute Myocardial Infarction Due to Stent Thrombosis After Administration of Intravenous Epinephrine for Anaphylaxis

Jung Soo Park, Jin Hong Min, Jun Ho Kang, Yong Nam In

Department of Emergency Medicine, Chungbuk National University Hospital, Cheongju-si, Chungbuk 361-763, Republic of Korea

To the Editor: The guidelines of several collaborating organizations recommend epinephrine injection for prompt initial treatment of anaphylaxis.[1] The dose and route of administration are generally based on the severity of symptoms and the rapidity with which a response is desired. Although, epinephrine is widely used to treat anaphylaxis, reports of severe complications such as acute coronary syndrome, arrhythmia, and intracranial bleeding are rare.[2]

A 50-year-old man was admitted to the hospital Emergency Department complaining of weakness, clamminess, and angioedema of the face and tongue, after a bee sting on the proximal tibia area. Upon admission, his consciousness and electrocardiography (ECG) results were normal but his blood pressure was 75/50 mmHg, leading to a diagnosis of anaphylaxis. He was immediately administered 0.1 mg epinephrine at a 1:100,000 dilutions intravenously. This was done by placing 0.1 mg of epinephrine (0.1 ml of the 1:1000 dilution) in 10 ml of normal saline solution and infusing it over 5 min. He was also given intravenous methylprednisolone (125 mg), intravenous chlorpheniramine maleate (4 mg), and intravenous ranitidine (100 mg). When 0.04 mg of epinephrine was intravenously infused, the patient began to complain of severe chest pain. ECG revealed ST elevation in leads I, aVL, and V2-5 and ST depression and T wave inversion in leads III and aVF, correlating to reciprocal changes of anterolateral ischemia [Figure 1]. The first and second doses of 0.4 mg sublingual nitroglycerin were administered with minimal effect. Therefore, the patient was then administered intravenous nitroglycerin, but his pain did not decrease (he maintained a score of 10/10 on the visual assessment scale for pain). He had a significant history of coronary artery disease and had undergone percutaneous coronary intervention to the proximal left anterior descending artery (LAD) with bare-metal stents 7 years previously. Two years following the intervention, he had developed in-stent restenosis in the LAD stent, which was treated by further percutaneous coronary intervention with 3 overlapping drug-eluting stents. Due to ongoing chest pain, emergent cardiac catheterization was performed. This revealed total occlusion in the proximal LAD stent and 90% stenosis with tissue growth in the mid-stent (TIMI 0) [Figure 2]. Thus, we were not able to perform intravascular ultrasound in the thrombosed stent. Percutaneous coronary intervention was then performed by stent implantation after balloon angioplasty, but there was evidence of stent restenosis in the mid-LAD. The postpercutaneous coronary intervention included conventional medical management with dual antiplatelet agents. On the second day of hospitalization, an allergen-specific immunoglobulin E (IgE) blood test was performed. Total IgE was 226 kU/L, with an upper normal limit of 113 kU/L. In particular, a specific IgE value of 1.26 kUA/L was found for yellow jacket venom. Five days later, the patient was discharged without any complications.

Acute myocardial infarction associated with anaphylaxis is classified into two types, Kounis syndrome and myocardial infarction induced by epinephrine used in the treatment of anaphylaxis. Jackson *et al*. have reported the occurrence of acute coronary stent thrombosis after the administration of intramuscular epinephrine for anaphylaxis due to the ingestion of peanuts.[3] Further, Kasim *et al*. have reported the occurrence of coronary thrombosis after the administration of intramuscular epinephrine for anaphylaxis due to wasp stings.[4] In these cases, the proposed pathophysiology was as follows: In humans, exogenous epinephrine promotes platelet aggregation

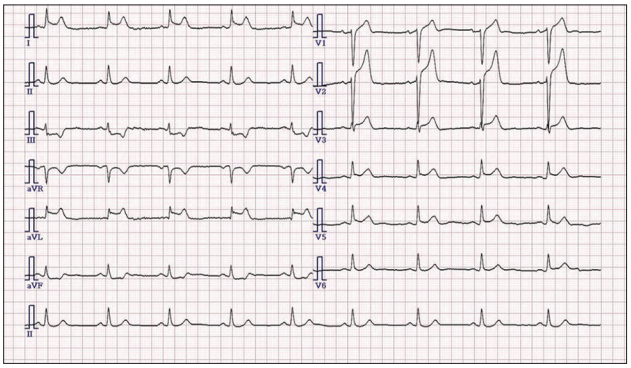

Figure 1: Twelve-lead electrocardiography obtained during chest pain demonstrating ST-segment elevation in the anterolateral leads.

Address for correspondence: Prof. Jin Hong Min, Department of Emergency Medicine, Chungbuk National University Hospital, Cheongju-si, Chungbuk 361-763, Republic of Korea
E-Mail: laphir2006@naver.com

Received: 01-07-2015 **Edited by:** Peng Lyu
How to cite this article: Park JS, Min JH, Kang JH, In YN. Acute Myocardial Infarction Due to Stent Thrombosis After Administration of Intravenous Epinephrine for Anaphylaxis. Chin Med J 2015;128:2692-3.

Access this article online

Quick Response Code:

Website: www.cmj.org

DOI: 10.4103/0366-6999.166020

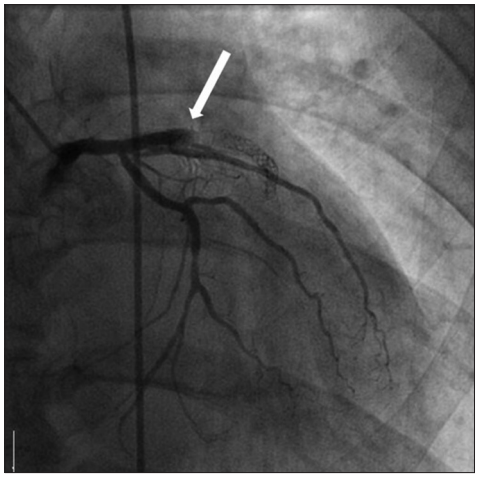

Figure 2: Right anterior oblique view at emergency coronary angiography showing proximal stent area occlusion of the left anterior descending (white arrow).

by increasing platelet production from thromboxane B2, heightening the sensitivity of platelets to ADP and promoting the thrombin-induced binding of platelets to fibrinogen. Interestingly, platelets in patients with angina are more sensitive to increased endogenous serum catecholamine levels and thus, more prone to aggregation compared to normal controls.[5]

We are concluded that acute myocardial infarction in our patient occurred due to acute stent thrombosis caused by exogenous epinephrine administration. To our knowledge, this is the first reported case of acute stent thrombosis after the intravenous administration of epinephrine for anaphylaxis.

Financial support and sponsorship

Nil.

Conflicts of interest

There are no conflicts of interest.

References

1. Simons FE, Ardusso LR, Bilò MB, Cardona V, Ebisawa M, El-Gamal YM, *et al.* International consensus on (ICON) anaphylaxis. World Allergy Organ J 2014;7:9.
2. Senthilkumaran S, David SS, Jena NN, Thirumalaikolundusubramanian P. Epinephrine-induced myocardial infarction in severe anaphylaxis: Is ß-blocker a bad actor or bystander? Am J Emerg Med 2013;31:1410.
3. Jackson CE, Dalzell JR, Hogg KJ. Epinephrine treatment of anaphylaxis: An extraordinary case of very late acute stent thrombosis. Circ Cardiovasc Interv 2009;2:79-81.
4. Kasim S, AbuBakar R, McFadden E. Anaphylaxis from wasp stings inducing coronary thrombus. Case Rep Cardiol 2012;2012:701753.
5. Wallén NH, Held C, Rehnqvist N, Hjemdahl P. Effects of mental and physical stress on platelet function in patients with stable angina pectoris and healthy controls. Eur Heart J 1997;18:807-15.