

ANATOMICAL EVALUATION OF LUMBAR VERTEBRAL CANAL IN INDIAN POPULATION

Balu Londhe ^{*1}, Rajendra Garud ².

^{*1} Assistant Professor, Department of Anatomy, Bharati Vidyapeeth (Deemed to be University) Medical College, Pune, Maharashtra, India.

² Professor and Head of Department of Anatomy, Bharati Vidyapeeth (Deemed to be University) Medical College, Pune, Maharashtra, India.

ABSTRACT

Introduction: Low backache is one of the most common symptoms of lumbar canal stenosis and it developed an interest among anatomists to do osteological analysis of lumbar canal. The aim of the current study was to create the morphometric database of lumbar canal dimensions in context of its applied clinical implications.

Materials and Methods: A dry bone study was carried out on 47 adult human lumbar vertebral sets obtained from various medical colleges in Pune District of Maharashtra. Anteroposterior (LCAP) and transverse (LCT) diameters of lumbar canal were measured by 'Digital Vernier Caliper with 0.01 mm precision'. The data analysis was done in SPSS Version 20 and 'ANOVA' test was applied to evaluate statistical differences.

Results: Lumbar canal antero-posterior (LCAP) diameters decreased from L1 to L5 vertebrae whereas there was gradual increase in Lumbar canal transverse (LCT) diameter from first to fifth lumbar vertebra.

Conclusion: The present study reported statistically significant differences in the dimensions of lumbar canal of L1 to L5 in Indian population. This morphometric baseline data can be utilized in surgical management of low back pain as a result of lumbar canal stenosis.

KEY WORDS: Antero-posterior diameter, Dry bone study, Lumbar canal, Lumbar canal stenosis, Transverse diameter.

Corresponding Author: Dr. Balu Londhe, Assistant Professor, Department of Anatomy, Bharati Vidyapeeth (Deemed to be University) Medical College, Pune, Maharashtra, India.

E-Mail: dr.lbaloo@gmail.com

Access this Article online	Journal Information
Quick Response code  DOI: 10.16965/ijar.2019.352	International Journal of Anatomy and Research ICV for 2016 90.30 ISSN (E) 2321-4287 ISSN (P) 2321-8967 https://www.ijmhr.org/ijar.htm DOI-Prefix: https://dx.doi.org/10.16965/ijar 
	Article Information
	Received: 26 Nov 2019 Peer Review: 26 Nov 2019 Revised: None
	Accepted: 25 Dec 2019 Published (O): 05 Jan 2020 Published (P): 05 Jan 2020

INTRODUCTION

Evolution of human erect posture and bipedal gait coupled with modern lifestyle is often reflected as stress on the vertebral column. The lumbar region of vertebral column being the most common site of expression of this stress in the form of neuropathy. Morphological bony changes in vertebral column due to age and decline in activity of spinal muscles leads to alter in vertebral column mobility, particularly in lumbar region which contributes less than third of the length of column. These changes are affected

by internal and external factors.

The lumbar vertebral canal is triangular, larger than at thoracic levels but smaller than at cervical levels. The first lumbar vertebral foramen contains the conus medullaris of spinal cord, while lower foramina contain the cauda equina and spinal meninges. Variations occur in sagittal and coronal dimensions of the lumbar vertebral canal, both within and between normal populations. The rigid bony wall of the canal is unable to expand during movements of lumbar column

and hence narrowing of this part of the canal compresses structures in it, causing various signs of low backache as well as pain or abnormal sensations in the lower limb and other neurological manifestations [1].

The vertebral column bears the weight of the trunk and upper limbs and transmits it to the lower limbs. This weight transmission, subjects the vertebral column to vertical compressive forces, the magnitude of which gradually increases from the cervical to the lumbar vertebral levels. This mechanism substantiates the gradually increasing size of the vertebrae from cervical to lumbar regions. Low backache is a common problem which affects all classes of society; rich and poor, white and black, males and females. One of the cause of low backache is narrowing of lumbar canal [2].

Lumbar canal stenosis' (LCS) is one of the age-related painful manifestation of lumbar vertebral column. LCS may be clinically presented in the form of neurogenic claudication as a result of central canal narrowing or radicular signs due to narrowing of intervertebral foramina [3]. Even though, symptomatology and detailed clinical examination are helpful to diagnose LCS, anatomical knowledge is necessary for its adequate management [3].

'Low back pain' (LBP) is seen as occupational hazard and also in general population in both rural and urban setting with varying degree of debilitation. Narrowing of lumbar canal may be due to multiple causes which aroused an interest of anatomists to perform morphometry [4].

Normal vertebral column movements can widen or narrow the foramen, based on the movements executed. The dynamic and postural factors are proven to influence the dimensions of lumbar canal [3]. Compression of the nerve roots of cauda equina due to narrowing of lumbar canal is observed by many studies [5,6].

Morphometric study of spinal canal in Western and African population done by researchers [2]. Progressive degenerative changes leading to LSS has been documented as the principal causes of LBP. Hence, the main objective of the present study was morphometry of lumbar canal in Indian population in context of its applied clinical implications.

MATERIALS AND METHODS

The current study contained 47 dry, human adult lumbar vertebral sets (L1 to L5) obtained from (1) B J medical college, (2) Kashibai Navale Medical College and (3) Bharati Vidyapeeth Medical College in Pune District of state of Maharashtra after due permission from the respective Institutes. The bones with deformity or degenerative changes were excluded from the study. Subsequently, these vertebral sets were subjected to direct external morphometric assessment of lumbar canal. The measurements were conducted by 'Digital Vernier Caliper with 0.01 mm. precision' (Fig.1). To avoid intra and inter-observer variations, all measurements of canal were performed in two sittings. They were as follows;

Anteroposterior (LCAP) diameter - Maximum distance between posterior surface of the body to the junction of laminae (Fig.1).

Transverse (LCT) diameter - Maximum transverse distance of the canal (Fig. 2).

Fig.1: Lumbar canal Antero-posterior measurement **LCAP** – Lumbar canal Antero-posterior.

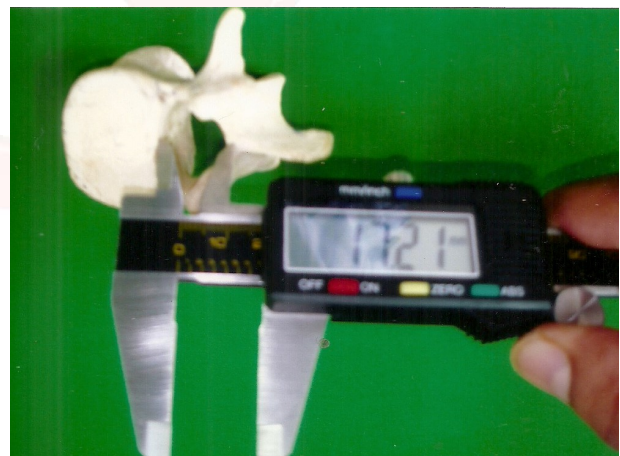
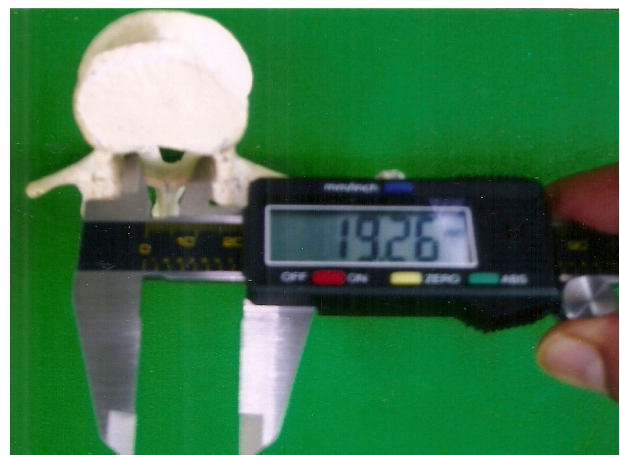

Fig. 2: Lumbar canal Transverse measurement. **LCT** – Lumbar canal Transverse.



Entire data was processed and analysed in SPSS Version 20 (SPSS Inc., Chicago, IL, USA). Mean and Standard Deviation of all observations were determined. Two tailed p value of 0.05 was taken as statistically significant. 'ANOVA' test was administered to evaluate statistical differences.

RESULTS

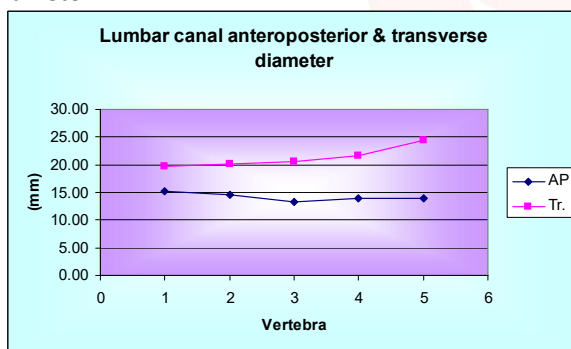
Measurements of Antero-posterior (LCAP) and Transverse (LCT) diameters of Lumbar canal of L1 to L5 are delineated in Table 1. and Fig.3. There was a gradual decrease in LCAP from first to last lumbar vertebra. LCT was enhanced from L1 to L5.

Table 1: Dimensions of Lumbar Canal (L1 to L5).

Vertebra		LCAP (mm)	LCT (mm)
L 1	Mean	15.2017	19.74
	Std. Deviation	1.2097	1.6415
L2	Mean	14.6019	20.096
	Std. Deviation	1.3421	1.6386
L3	Mean	13.1991	20.4928
	Std. Deviation	3.2315	2.4185
L4	Mean	13.0251	21.6989
	Std. Deviation	1.2968	2.3898
L5	Mean	13.0177	24.3449
	Std. Deviation	1.4183	2.0356

LCAP – Lumbar canal Antero-posterior diameter, LCT – Lumbar canal Transverse diameter

Fig. 3: Lumbar Canal Antero-posterior and Transverse diameter.



LCAP – Lumbar canal Anteroposterior, LCT – Lumbar Canal Transverse.

ANOVA test revealed highly statistically significant difference in both diameters of lumbar canal (Table 2).

Table 2: Dimensions of Lumbar Canal and its significant differences (L1 to L5).

		F-value	p-value	Significance
Lumbar Canal	LCAP	7.66	0	HS
	LCT	38.9	0	HS

LCAP – Anteroposterior diameter of lumbar canal, LCT – Transverse diameter of lumbar canal, p<0.01 indicates highly significant difference.

DISCUSSION

Morphometric studies of the lumbar vertebral canal report racial and ethnic variation, apart from age and sex differences in the canal size. The present study done in a Indian Community, confirms that there is considerable difference in the canal size, as observed in both transverse and antero- posterior diameters of the canal, similar to that noticed between different populations. It is also to be noted that the canal size in Indians, is smaller than that in the other races. The antero- posterior diameter of the lumbar canal gradually decreases from L1 to L5, the widest being at L₁ level. First lumbar vertebral foramen contains enlargement of spinal cord and conus medullaris, requires large size of canal to accommodate these structures which ensures protection of the contents during movement of lumbar column.

This region also shows a change in the curvature of the lumbar spine from thoracic convexity to lumbar concavity. This tends to displace the lower end of the spinal cord dorsally in the erect posture, and so the antero -posterior diameter has to be quite large enough to accommodate it. Lumbar spinal stenosis (LSS) is common with advancing age and formation of osteophytes around canal margins leading to low back pain. There are other causes of backache but narrowing of canal has been documented a pivotal role in it. Hence, the objective of present study to define LSS by morphometric Antero-posterior (AP) and Transverse (TD) measurements of lumbar canal [7]. An estimation of size of lumbar canal is an essential diagnostic component for low backache. Its configuration is determined by the structures bounding the successive vertebral foramina and any changes in the diameter of the canal might be associated with low-back pain [8]. In this study, the mean LCAP diameter showed different values throughout lumbar canal (Table 1) and (Fig. 3).

The mean LCAP diameter indicated a drop from 15.20 mm at L1 to 13.01 mm at L5 (Table 1). A comparable finding was noted in dry bone study conducted by El Rakhway M [8] who reported an increase from 14.9 mm at L1 to 15.6 mm at L5 with slight drop at L3. Poostacchini petal [9] in a morphometric study of 121 skeletons (63 Italians and 58 Indians) found that the mean AP

diameter to be significantly greater in Italian skeletons. Hinck et al [10] measured the AP diameter of spinal canal on plain radiographs in western population. The mean AP diameter in his study of 49 adults was gradually decrease from first to fifth vertebra which corresponds to present study with higher values.

Amanoo Kuofi HS also mentioned similar contrast findings in his study. [11]. In present study, transverse (LCT) diameter show uniformly cranio – caudal increase from 19.7 mm at L1 to 24.34 mm at L5. This is because of pedicles diverge increasingly from L1 to L5. According to Urrutia V E 2009 the inter-pedicle distance was reported as smaller at L1 level (22.4 mm) and larger at L5 level (29.7 mm). In another study conducted by Tan S H et al 2004 the inter-pedicle distance increases from 19.4 mm at L1 to 23.4 mm at L5 level. These findings are close to the present study. However, a study carried out at Bangalore reported steady decrease in LCT with high degree of variation [3]. Yet another study showed fluctuations with drop in LCT from L1 to L4 and subsequently an increase at L5 [11].

There are several published studies on lumbar canal dimensions which have been implemented on various populations [9,10,12,13]. They reported variations in canal measurements. Singh J et al [14] in 2013 noted that LCAP gradually decreases and LCT increases from L1 to L5 in Indian population. Jones, Thomson, Verbiest and Schaik [6] studied lumbar canal by ‘imaging techniques’ and Steve Eisensten [12] studied lumbar column in dried specimen. Accepting slightly higher values found by imaging techniques, Steve Eisensten suggested anteroposterior diameter less than 15 mm. and transverse diameter less than 20 mm. as stenotic. In the present study, mean anteroposterior diameter of lumbar canal is about 13 mm. and transverse diameter significantly increase from L1 to L5 reaching maximum about 24 mm in L5. Values of transverse diameter in the present study appear to be more than transverse diameter quoted by Steve Eisensten. This may be explained by the fact that the transverse pedicle angle in white population (Olsewki) [15] is less than the similar measurements in the present study. In other study in Nepal by Shresths B and Dhungana [16] on X rays also had similar

values of LCAP and LCT. Our findings are similar these studies. We have compared our values of these measurements with Caucasoid, Zulu Negroid and Sotho Negroid [17]. (Table 3).

Table 3: Measurements in millimetres.

Population	Diameter	L 1	L 2	L 3	L 4	L 5
Caucasoid	A. P.	18	17	16	16	18
	Trans.	23	24	23	24	26
Zulu Negroid	A. P.	16	15	15	15	16
	Trans.	21	22	22	23	26
Sotho Negroid	A. P.	16	15	14	15	16
	Trans.	21	21	22	23	25
Indian – Present study	A. P.	15.2	14.6	13.9	13.02	13.01
	Trans.	19.7	20.9	20.49	21.69	24.34

Comparison of Lumbar canal Antero-posterior (LCAP) and Lumbar Canal Transverse (LCT) diameters.

This morphometric database of lumbar canal is extremely valuable and must be cautiously addressed with specially in management of low backache cases due to spinal canal stenosis. These population specific differences could be ascribed to racial, ethnic or environmental aspects.

Multiple techniques like radiography, myelography, computed tomography (CT), magnetic resonance imaging (MRI) have been utilized to measure the dimensions of lumbar canal. However, very few studies have been carried out which are based on direct measurements. The present study used direct measurement method to assess the lumbar canal parameters as there is more accuracy and reliability with this methodology in estimating lumbar canal dimensions. Even though, the current study revealed highly statistically significant difference in anteroposterior and transverse diameters of lumbar canal, gender specific differentiation could not be done in the study. One of the major limitations of study was limited sample size as large sample size is required to generalize the study results.

CONCLUSION

The present dry bone study reported statistically significant differences in the Antero-posterior and. Transverse dimensions of lumbar canal of L1 to L5 in Indian population. A large community based study is needed to further confirm

the findings. This morphometric baseline data can be utilized in management of low back pain as a result of lumbar canal stenosis.

Conflicts of Interests: None

REFERENCES

- [1]. Devi R, Rajagopalan N. Dimensions of lumbar vertebral canal. *Indian J Orthop.* 2003; 37:(3):13.
- [2]. Abuelnour MAA, Hamdan NSM. Morphometric study of the lumbar spinal canal and lumbar stenosis in Sudanese: *Sch. J. App. Med. Sci.* Dec 2016; 4(12C): 4372-4377.
- [3]. Devi R, Rajagopalan N. Morphometry of lumbar intervertebral foramen. *Indian J Orthop.* 2005;39(4): 145-47.
- [4]. Azu O, Komolafe OA, Ajayi SA, Naidu EC, Abiodun A. Morphometric study of lumbar vertebrae of Adult South African subjects. *Int J Morphol.* 2016; 34(4): 1345- 51.
- [5]. Schlesinger EB, Taveras JM. Factors in the production of "cauda equina" syndromes in lumbar discs. *Trans Am Neurol Assoc.* 1953;78: 263-68.
- [6]. Verbiest H. A radicular syndrome from developmental narrowing of the lumbar vertebral canal. *J Bone Joint Surg.* 1954;36: 230-237.
- [7]. Chouhan BKS, Thukral BB. Lumbar spinal stenosis and morphometry of lumbar vertebral canal. *Journal of the Anatomical Society of India.* 2016;65(1): 33-37.
- [8]. El Rakhway M. Lumbar vertebral canal stenosis: concept of morphometric and radiometric study of the human lumbar vertebral canal. *Anatomy* 2010;4(4): 51-62.
- [9]. Postacchini F, Ripani M, Carpano S. Morphometry of the lumbar vertebrae: an anatomic study in two Caucasoid ethnic groups: *Clin Orthop Relat Res.* 1983;172: 296-303.
- [10]. Hinck VC, Clark WM Jr, Hopkins CE. Normal interpedicular distances (minimum and maximum) in children and adults: *Am J Roentgenol.* 1966;97(30): 141-53.
- [11]. Amonoo-Kuofi HS. The sagittal diameter of the lumbar vertebral canal in normal adult Nigerians. *J Anat.* 1985;140: 69-78.
- [12]. Eisenstein MG. The morphometry and pathological anatomy of the lumbar spine in South Africa Negroes and Caucasoids with specific reference to spinal stenosis. *J Bone Joint Surg Br.* 1977;59:173-180.
- [13]. Piera V, Rodriguez A, Cobos A, Hernandez R, Cobos P. Morphology of lumbar vertebral canal. *Acta Anat.* 1988;131: 35- 40.
- [14]. Singh J, Pahuja K, Khatri JK. Morphometric analysis of lumbar vertebrae in north Indian population. *Asian J. Pham.Hea.Sci.* 2013;3(4): 830-834.
- [15]. Olsewski JM, Simmons EH, Kallen FC, Mendel FC, Severin CM, Berens DL. Morphometry of the lumbar spine: anatomical perspectives related to transpedicular fixation: *J Bone Joint Surg. Am.* 1990;72(4):5419.
- [16]. Shrestha B, Dhungana S. Measurement of transverse and sagittal diameter of the lumbar vertebral canal in people from Western region of Nepal. *Int J Infect Microbiol.* 2013;2(2):55-58.
- [17]. Mohammed Tall, Mamoudou Savadogo, Amadou Ndiassé, Adama Ouedraogo, Herve Pilabre, Issouf Savadogo et.al. Morphometric study of lumbar spray in the African Black West Subjects. *Open journal of Orthopedics.* 2018;8(5):190-199.

How to cite this article:

Balu Londhe, Rajendra Garud. ANATOMICAL EVALUATION OF LUMBAR VERTEBRAL CANAL IN INDIAN POPULATION. *Int J Anat Res* 2020;8(1.1):7251-7255. DOI: 10.16965/ijar.2019.355