

Protective Effect of *Wrightia tinctoria* Bark Triterpenoidal Fraction on Carbon Tetrachloride-Induced Acute Rat Liver Toxicity

P. BIGONIYA and A. C. RANA

For author affiliations, see end of text.

Received June 6, 2009; Revised December 16, 2009; Accepted February 9, 2010

This paper is available online at <http://ijpt.iuims.ac.ir>

ABSTRACT

The present investigation aims at assessing the hepatoprotective effect of triterpene fraction isolated from the stem bark of *Wrightia tinctoria* (containing lupeol, β -amyirin and β -sitosterol) on CCl_4 -induced hepatotoxicity in the rat. CCl_4 (1.5 mg/kg, i.p) is a potent hepatotoxic agent which causes peroxidative degeneration of membrane lipids with the potential outcome of fatty degeneration. The peroxidative products induce hypoperfusion of the membrane and cytosolic enzymes appear in the blood, elevation of serum marker enzymes namely SGPT, SGOT and ALP and decrease in hepatic glutathione and SOD. The hepatoprotection of triterpene is compared with silymarin, a well known standard hepatoprotectant. Pretreatment with triterpene fraction (125, 250 and 400 mg/kg, p.o. once a day for 4 days before CCl_4 and continued further 3 days) attenuated the CCl_4 -induced acute increase in serum SGPT, SGOT and ALP activities and considerably reduced the histopathological alterations. Further, triterpene fraction reduced thiopentone-induced sleeping time, suggesting the protection of liver metabolizing enzymes. Triterpenes administration changed the tissue redox system by scavenging the free radicals and by improving the antioxidant status of the liver replenished the depleted hepatic GSH and SOD. Triterpene pretreatment improves bromosulphalalin clearance of the CCl_4 -intoxicated liver and also increases the cellular viability. These effects substantiates protection of cellular phospholipid from peroxidative damage induced by highly reactive toxic intermediate radicals formed during biotransformation of CCl_4 . Triterpene fraction afforded protection against the hepatic abnormalities due to presence of lupeol and β -amyirin. This study supports the traditional use of *W. Tinctoria* bark in liver diseases.

Keywords: *Wrightia tinctoria*, Triterpene, Lupeol, β -amyirin, Hepatoprotective

Use of herbal drugs in the treatment of liver diseases is very common in the world. Liver is a primary organ involved in metabolism of food and drugs. Liver disorders are mainly caused by toxic chemicals, such as antibiotics chemotherapeutic agents, peroxidised oil, aflatoxin, Carbon tetrachloride (CCl_4), chlorinated hydrocarbons etc. Excess consumption of alcohol, infections and autoimmune disorders also can cause liver disease. Most of the hepatotoxic chemicals damage liver cells mainly by inducing lipid peroxidation and by generation of reactive oxidative intermediates in liver [1].

Nature has best owed us with a large number of medicinal plants, some of which are yet to be explored and validated for their medicinal value. Triterpenoids are well reported to have hepatoprotective activity. Following are few examples of its vast resources, like

Betula cortex, *Silybum marianum*, *Phyllanthus niruri*, *Panax ginseng*, *Protium heptaphyllum*, *Terminalia catappa*, *Combretum quadrangulare* which are reported to have well defined hepatoprotective activity [2-5]. *Wrightia tinctoria* (Roxb.) R.Br. is a small deciduous tree of the family Apocynaceae distributed in Central India, Burma and Timor. This plant is extensively used in the Indian system of medicine. Bark and seeds are antidiysenteric, carminative, astringent, aphrodisiac and diuretic, used in flatulence, stomach pain, bilious affections and jaundice. Fresh leaves are pungent and are chewed for relief from tooth ache [6]. Oil emulsion of *W. tinctoria* pods is used to treat psoriasis and also have fungicidal activity against *Pityrosporum ovale* recovered from dandruff [7]. Ethyl acetate, acetone and methanol extracts of *W. tinctoria* bark showed antinociceptive activity in mice [8] and wound healing

Triacontanol and tryptanthrin have been isolated from *W. tinctoria* leaves [13]. The mature powdered pods of *W. tinctoria* show co-occurrence of β -amyirin, ursolic acid and oleanolic acid along with β -sitosterol [14]. Methanol extract of the immature seedpods contains cycloartenone, β -amyirin, cycloeucaleanol and β -sitosterol and fifth one was identified as wrightial, a new terpene [15]. A new sterol 14 α -methylzymosterol in addition to four rare plant sterols, desmosterol, clerosterol, 24-methylene-25-methylcholesterol and 24-dehydropollinastanol have been isolated from *W. tinctoria* seeds [16]. The stem bark of *W. tinctoria* contains β -amyirin, lupeol, β -sitosterol and a new triterpenoid [17]. Triterpenes are biologically active secondary plant substances that display antimicrobial, hepatoprotective and anti-inflammatory effects [2]. Traditionally *W. tinctoria* is used in bilious affections and jaundice, phytochemical studies are already reported in bark but there is no scientific basis of its use in liver, as phytopharmacological effect on liver disorder is not reported. The present study was taken up with the aim of assessing hepatoprotective activity of the purified and enriched triterpenoidal fraction of *W. tinctoria* bark.

MATERIALS AND METHODS

Plant material

W. tinctoria bark was collected from Hoshangabad district of Madhya Pradesh, India September 2004. The plant was identified with the help of available literature and authenticated by Dr. A. P., Shrivastava, Principal, P K S Govt. Ayurveda College and Institute, Bhopal, India. A voucher specimen was deposited in the herbarium of department (Herbarium No. Bigoniya 1084).

Isolation and purification of *W. tinctoria* bark triterpenoidal fraction

Air dried, powdered bark was exhausted by cold percolation with petroleum ether. The percolate was evaporated under 40°C up to 1/10 of initial volume, a colourless crystalline solid deposited. The supernatant liquor was decanted and concentrated to 1/4 volume, which again deposited a very sticky and rubbery material. The clear supernatant was decanted and completely evaporated using a rotary vacuum evaporator (Superfit, India). Refluxing on a water bath with benzene and N/10 alcoholic potassium hydroxide for 15 hours saponified this residue. The solvents were removed under reduced pressure, washed with large amount of water, which separates a bulky solid, filtered and dried (unsaponifiable matter, yield 1.28%). This was crystallized alternatively from petroleum ether and alcohol repeatedly which eliminates most of the sticky material (pale yellow crystals, yield 0.65%). This

crystalline material was extracted with boiling methanol and insoluble sterol fraction gives following color reactions described in the literature for triterpene: in Salkowski reaction yellow colour in the sulphuric acid layer, in Hasse's test brown precipitate changing to yellow, in Noller's test with thionyl chloride containing 0.01% anhydrous stannic chloride gives reddish-violet colour changing to purple, in the Liebermann-Burchard test violet colour [18]. The resulting highly purified triterpene fraction (TF) in the form of dry crystals contains lupeol and β -amyirin as the major compound, along with β -sitosterol and other triterpene. The triterpene fraction on application of suitable fractionation technique yields β -amyirin acetate (yield 0.03%; m.p. 238-40°C), lupeol benzoate (yield 0.028%; m.p. 266-70°C) and β -sitosterol (yield 0.004%; m.p. 132-34°C). All these was authenticated by co-TLC with authentic samples of lupeol, β -amyirin and β -sitosterol in petroleum ether:benzene:chloroform (1:1:1) solvent system. The identity has been established by colour reactions, elementary analysis, optical rotation and mixed melting point with authentic sample [17].

Experimental Animals

Laboratory-bred Wister albino rats of both sexes (150 – 200 g) maintained under standard laboratory conditions at 22 \pm 2°C, relative humidity 50 \pm 5% and photoperiod (12-h dark and light), were used for the experiment. Commercial pellet diet (Hindustan Lever, India) and water were provided *ad libitum*. Experimental protocol was approved by the Institutional Animal Ethical Committee (approved body of Committee for the Purpose of Control and Supervision of Experiments on Animals, Chennai, India) of Dr. H.S. Gour University, Sagar, India and care provided to the animal was as per the WHO 'guidelines for the care and use of animals in scientific research'.

Determination of LD₅₀

Acute oral toxicity of the triterpenoid fraction was determined following the acute toxicity class method (OECD guideline No. 423) and revised Up & Down method (OECD guideline No. 425). A Limit test was performed to categorize the toxicity class of the compound and then Main test was performed to estimate the exact LD₅₀. The animals (nulliparous and non-pregnant female Wistar albino rats) were fasted overnight with free access to water, weighed and a single dose of the test substance was administered. Animals were observed individually during first 30 minutes, periodically during 48 hours with special attention given during first 4 hours (short-term toxicity) and daily thereafter for total of 14 days (short-term toxicity). The limit test was started from 2000 mg/kg dose. LD₅₀ was found greater than the test dose so the test substance could be classified in the hazard classification as class 5, 2000 mg/kg < LD₅₀ < 5000 mg/kg in the Globally Harmonized System (GSH). LD₅₀ of the triterpenoid fraction was found to 3165.25 mg/kg from

Hepatoprotective activity study

In view of multiplicity and complexity of the liver functions, it is obvious that no single test can establish the disturbances in liver function. Thus, a battery of liver function test was employed for accurate diagnosis, to assess the severity of damage, to judge prognosis and to evaluate therapy.

The rats were divided into six groups of six animals each. Animals of group I- vehicle control, group II- negative control (Carbon tetrachloride, 1.5 mg/kg, i.p), group III- silymerin (20 mg/kg), group IV, V and VI were administered *W. tinctoria* triterpenoidal fraction (WTTF) at a dose of 125, 250 and 400 mg/kg, p.o. respectively. Vehicle used for WTTF was propylene glycol and Tween 80 in 4:1 ratio. All the animals of group I, III and IVth to IXth were treated with different doses of vehicle, silymerin and WTTF for four days. On 4th day 2 hrs after drug administration all animals including group II were treated with CCl₄ in liquid paraffin (1:1) in a dose of 1.5 ml/kg i.p. Drug treatment schedule was repeated for further three days. All the hepatoprotective parameters were assessed on last day (7th day) 2 hours after drug administration.

Thiopentone-induced sleeping time

Sleeping induced by short acting barbiturate is significantly prolonged in the event of any hepatic damage and this can be used as a measure of the function of the drug metabolizing enzymes. On 7th day a single dose of thiopentone (4 mg/kg, i.p.) was given to the animals and the time between loss of the righting reflex and its recovery was taken as duration of thiopentone induced sleeping time [20].

Effect on serum biochemical parameters

On 7th day of treatment, all the animals were sacrificed to collect liver and blood samples. Blood samples were centrifuged at 3000 rpm for 5 minutes, serum was collected and analyzed for estimation of biochemical parameters, i.e. alkaline phosphatase [21], glutamate pyruvate transaminase and glutamate oxaloacetate transaminases [22], total and direct bilirubin [23], total protein [24], albumin [25], cholesterol [26] and triglyceride [27].

Estimation of free radical scavenging ability of liver

Free radical-mediated cell injury plays an important role in chemical induced hepatotoxicity. Liver tissues excised, weighed, homogenized and supernatant used for estimation of free radical scavenging ability. Glutathione reduces H₂O₂ directly to water or react directly with the free radicals such as •O₂, •OH, •O⁻ by a radical transfer process, which yields thiol radicals. This thiol radical presents in glutathione forms a colored complex with DTNB which is measured colorimetrically at 412 nm [28]. Lipid peroxidative

degradation of biomembranes is one of the principal causes of hepatotoxicity of CCl₄ [29]. Thiobarbituric acid reactive substance of lipid peroxidation (malondialdehyde) was determined following the method of Okhawa *et. al.* [30]. Superoxide dismutase was estimated as per the method of Misra and Fridovich [31].

Histopathological Studies of liver

The isolated liver slices were fixed in Aqua Bouin's fluid and processed for histopathological assessment of liver damage following method of Nanji *et al.* [32].

Viability study of liver cells

Loss of cell viability is most often measured as loss of membrane integrity. This event may be primarily due to necrosis or secondarily due to apoptosis. Trypan blue exclusion is a cell viability assay based on the ability of the liver cells to exclude the trypan blue and uptake of the dye by the dead cells due to alteration in the membrane permeability. Viability was measured by trypan blue exclusion test following the method of William *et. al.* [33].

Bromosulphthalein uptake test

It is generally agreed that in the passage of bromosulphthalein (BSP) from the plasma to the bile, it undergoes storage, metabolism, and excretion by the liver. It is well documented that CCl₄ produces morphological and functional changes in the liver. Bromosulphthalein clearance test is the most sensitive and dependable method to assess the physiological status of liver function. The test indicates the excretory function of the liver. The abnormal functional effects produced by CCl₄ are easily demonstrated by the retention of BSP. Liver slices kept in ice cold phosphate buffer (0.2 M) at pH 7.4 were incubated in media (KCl: 10 mM, MgSO₄: 1 mM, NaCl: 1 mM in phosphate buffer) containing 30 µg BSP/ml at 38°C. An aliquot of reaction mixture was analyzed after 10, 20 and 30 minutes to determine the concentration of BSP in the media at 580 nm [34].

Statistical analysis

All data were presented as means ± SEM. Experimental data was analysed using one-way ANOVA followed by Student's *t*-test to compare the difference between the control and treated values. *P* value <0.05 were considered significant. Graph Pad Prism Version 3.02 was used for statistical calculations.

RESULTS

Thiopentone-induced sleeping time

W. tinctoria triterpenoidal fraction showed statistically extremely-significant (*p*<0.001) hepatoprotective activity (94.06%) by reducing the sleeping time to 20.95 ± 1.87 min compared to 65.72 ± 2.43 min of negative control at 1000 mg/kg dose (Table 1)

Table 1. Hepatoprotective effect of *W. tinctoria* triterpenoidal fraction on thiopentone-induced sleeping time against CCl₄-induced liver damage on rats

Treatment (mg/kg, p.o.)	Sleeping time in min.	% Hepatoprotection
Vehicle control	17.06 ± 1.50	---
CCl ₄ (1.5, i.p)	65.72 ± 2.43	---
Silymerin (20)	20.56 ± 1.08 ^c	94.86
WTTF (125)	33.58 ± 2.14 ^c	64.00
WTTF (250)	22.42 ± 2.03 ^c	91.03
WTTF (400)	20.95 ± 1.87 ^c	94.06

n = 6. Percentage of hepatoprotection was calculated using the equation: $H = [1 - (T - V / C - V)] \times 100$. Where T is mean value of group treated with test drug and C is mean value of group treated with CCl₄ alone and V is the mean value of control animals. ^cp<0.001 when compared to negative control (CCl₄-treated) group.

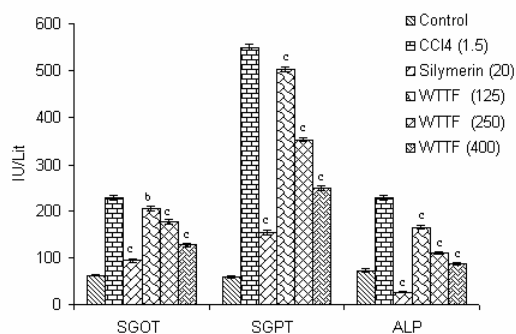
Table 2. Effect of *W. tinctoria* triterpenoidal fraction on serum biochemical parameters of CCl₄-treated rats

Treatment (mg/kg, p.o.)	Cholesterol mg/dL	Tri-glyceride mg/dL	Protein gm/dL	Albumin gm/dL	Bilirubin (mg/dL)	
					Total	Direct
Vehicle (control)	152.60 ± 3.60	113.50 ± 4.55	8.88 ± 0.34	3.57 ± 0.65	0.75 ± 0.04	0.41 ± 0.02
CCl ₄ (1.5, i.p)	68.92 ± 3.55	220.05 ± 5.72	5.85 ± 0.40	1.52 ± 0.35	8.36 ± 0.79	5.28 ± 0.68
Silymerin (20)	72.57 ± 3.21 ^{ns}	131.54 ± 4.32 ^c	8.46 ± 0.24 ^a	2.58 ± 0.35 ^{ns}	0.55 ± 0.02 ^c	1.15 ± 0.22 ^c
WTTF (125)	81.72 ± 3.08 ^a	200.65 ± 4.25 ^{ns}	6.52 ± 0.58 ^{ns}	1.48 ± 0.22 ^{ns}	5.69 ± 0.62 ^b	3.43 ± 0.45 ^{ns}
WTTF (250)	104.02 ± 3.61 ^c	148.51 ± 3.06 ^c	6.97 ± 0.18 ^{ns}	1.98 ± 0.44 ^{ns}	2.92 ± 0.14 ^c	2.02 ± 0.15 ^a
WTTF (400)	142.62 ± 4.37 ^c	126.12 ± 3.58 ^c	7.61 ± 0.52 ^{ns}	2.52 ± 0.17 ^{ns}	1.12 ± 0.13 ^c	1.25 ± 0.26 ^a

n = 6. ^ap<0.05, ^bp<0.01, ^cp<0.001 and ns = not significant when compared to negative control (CCl₄-treated) group.

Effect on Serum biochemical parameters

Hepatotoxin CCl₄ get converted into CCl₃O⁻ by liver enzymes and attacks the unsaturated fatty acids of cell membrane in presence of oxygen consequently give rise to lipid peroxides which alters the functional integrity of liver mitochondria leading to liver damage. The levels of marker enzymes SGOT, SGPT and ALP were found to be elevated in cytoplasm as well as in blood. Serum triglyceride and bilirubin (total and direct) level elevated, on the other hand serum total protein, albumin and cholesterol level decreased. WTTF treatment significantly (*p*<0.001 & 0.01) decreased SGOT, SGPT and ALP levels of treated animals at all the tested doses compared to negative control group (Fig 1). Triglyceride level was also decreased at 250 and 400 mg/kg dose which is extremely significant (*P*<0.001). WTTF significantly (*p*<0.001 & 0.01) increased cholesterol level of serum at 250 and 400 mg/kg.

**Fig 1.** Effect of *W. tinctoria* triterpenoidal fraction on serum biochemical parameters of CCl₄ treated rats. n = 6, ^bp<0.01, ^cp<0.001 when compared to negative control (CCl₄-treated) group.

Triterpene treatment did not have any significant effect towards normalization of serum protein and albumin level in treated animals. WTTF significantly decreased serum total bilirubin (*P*<0.001) and direct bilirubin (*P*<0.01) at 250 and 400 mg/kg dose (Table 2).

Estimation of liver free radical scavenging ability

CCl₄ intoxication reduced superoxide dismutase enzyme level expressed in unit/mg of protein in liver tissue reported in Table 3. WTTF treatment showed significant enhancement ability of SOD only at 400 mg/kg dose. WTTF at 1000 mg/kg dose showed extremely significant (*p*<0.001) reduction in lipidperoxidase and elevation of glutathione.

Histopathological parameters

WTTF treatment showed hepatoprotection by reducing the liver weight of CCl₄ intoxicated animals. Liver weight/100 gm of body weight for vehicle control,

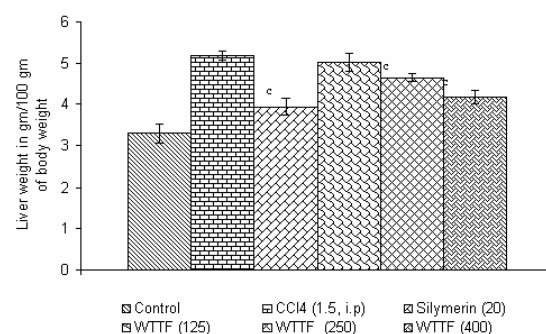
**Fig 2.** Effect of *W. tinctoria* triterpenoidal fraction on relative liver weight of CCl₄-treated rats. n = 6, ^cp<0.001 when compared to negative control (CCl₄-treated) group.

Table 3. Effect of *W. tinctoria* triterpenoidal fraction on free radical scavenging ability of CCl₄-treated rat liver

Treatment (mg/kg, p.o)	Superoxide dismutase unit/mg of protein	Lipid peroxidase nmol/gm of protein	Glutathione µg/gm of liver
Vehicle (control)	5.72 ± 0.87	3.43 ± 0.68	22.26 ± 1.92
CCl ₄ (1.5, i.p.)	1.53 ± 0.22	32.97 ± 1.75	7.46 ± 0.67
Silymerin (20)	4.53 ± 0.62 ^a	5.59 ± 0.60 ^c	19.65 ± 1.40 ^c
WTTF (125)	1.35 ± 0.42 ^{ns}	30.17 ± 1.22 ^{ns}	9.05 ± 1.11 ^{ns}
WTTF (250)	2.01 ± 0.36 ^{ns}	24.15 ± 1.73 ^b	13.26 ± 1.02 ^a
WTTF (400)	4.35 ± 0.31 ^a	8.12 ± 0.87 ^c	20.08 ± 2.14 ^c

n = 6. ^a*p*<0.05, ^b*p*<0.01, ^c*p*<0.001 and ns = not significant when compared to negative control (CCl₄-treated) group.

Table 4. Effect of *W. tinctoria* triterpenoidal fraction on viability of CCl₄-treated rat liver cells

Treatment (mg/kg, p.o)	Number of cell counted	Number of viable cell	Percent viable cell
Vehicle control	212.33 ± 4.25	197.45 ± 2.33	92.99
CCl ₄ (1.5, i.p.)	205.54 ± 4.78	126.55 ± 2.79	61.56
Silymerin (20)	207.55 ± 4.22	182.43 ± 3.43 ^c	87.89
WTTF (125)	206.85 ± 5.42	134.76 ± 3.12 ^c	65.14
WTTF (250)	210.00 ± 3.27	168.25 ± 3.75 ^c	80.26
WTTF (400)	208.25 ± 3.04	177.12 ± 2.68 ^c	85.05

n = 6. The viability was calculated as percentage from the following equation: % of viable cells = no. of cells excluding dye/total no. of cells counted × 100. ^c*p*<0.001 when compared to negative control (CCl₄-treated) group.

negative control, Silymerin and WTTF (1000 mg/kg) were 3.29, 5.18, 3.94 and 4.18 gm respectively (Fig 2).

Liver sections of vehicle control animals indicate normal appearance of hepatic parenchyma. CCl₄-treated animals showed degenerative changes, bile duct hyperplasia, zonal necrosis plus extensive diffuse vacuolar degeneration engorged with blood and microvesicular fatty changes in hepatocytes which indicates completely damaged cytoarchitecture of liver. Silymerin-treated animals showed slightly altered hepatic parenchyma with focal necrosis, lobular necrosis, centrilobular necrosis and sinusoidal dilation with slightly altered hepatic parenchyma

WTTF (400 mg/kg) treatment showed sinusoidal dilation with mild focal coagulative necrosis and slightly altered hepatic parenchyma. Histopathological observations and photomicrographs of liver slices were shown in Fig 3.

Viability of liver cells

WTTF treatment at all the tested doses showed extremely significant (*p*<0.001) hepatoprotection against CCl₄ by increasing the viable liver cell count. Silymerin showed 87.89% of viable cell compared to 61.56% of negative control and 92.99% of vehicle control respectively as shown in Table 4. WTTF at 400 mg/kg dose showed 85.05% viable liver cell.

Bromosulphthalein uptake test

Liver slices of WTTF treated animals showed statistically extremely significant (*P*<0.001) hepatoprotection (78.60%) at 1000 mg/kg dose. It showed 90.33 ± 5.72 µg of BSP uptake per gm of liver tissue compared to 42.11 ± 2.38 µg of CCl₄ treated group (Fig 4).

DISCUSSION

Viral hepatitis is a common disease in the world, especially in developing countries. However, there are no effective drugs for the treatment of this disease. In

recent years scientists have carried out a considerable amount of research on traditional medicine in an attempt to develop new drugs for hepatitis. Toxic liver injury produced by drugs and chemicals may virtually mimic any form of naturally-occurring liver disease. In fact, any patient presenting with liver disease or unexplained jaundice is thoroughly questioned about history of drug intake or exposure to chemicals. Hepatotoxicity from drugs and chemicals is the commonest form of iatrogenic disease. Cameron and Karunarathe reported liver injury due to oral administration of carbon tetrachloride [35]. CCl₄-induced liver damage in experimental animals is a commonly used model for the screening of hepatoprotective drugs. The hepatotoxic effects of CCl₄ are largely due to biotransformation by the cytochrome P-450 system to active metabolite, trichloromethyl radical [36]. Covalent binding of the trichloromethyl radical to cell protein is considered the initial step in a chain of events that eventually leads to lipid peroxidation of the cell membrane and endoplasmic reticulum. Lipid peroxidation in turn gives products like malondialdehyde (MDA) that cause damage to the membrane. The peroxidative products induce hypoperfusion of the membrane and finally cytosolic enzymes appear in the blood [37]. This is evidenced by an elevation in the serum marker enzymes namely SGPT, SGOT and ALP.

Estimation of the serum enzymes is a useful quantitative marker of the extent and type of hepatocellular damage. In CCl₄ toxicity, liver lesion develops within one-two hours, however late toxic effects may appear after a delay of several hours or two to three days. Liver toxicants cause disturbances in synthesis and metabolism of triglycerides, cholesterol and lipoproteins, thus damaging the basic resource for living cells. The increased triglyceride content in the blood is in correlation with the fatty degeneration of the liver [38]. The lowering of different serum marker enzyme level is a definite indication of hepatoprotective

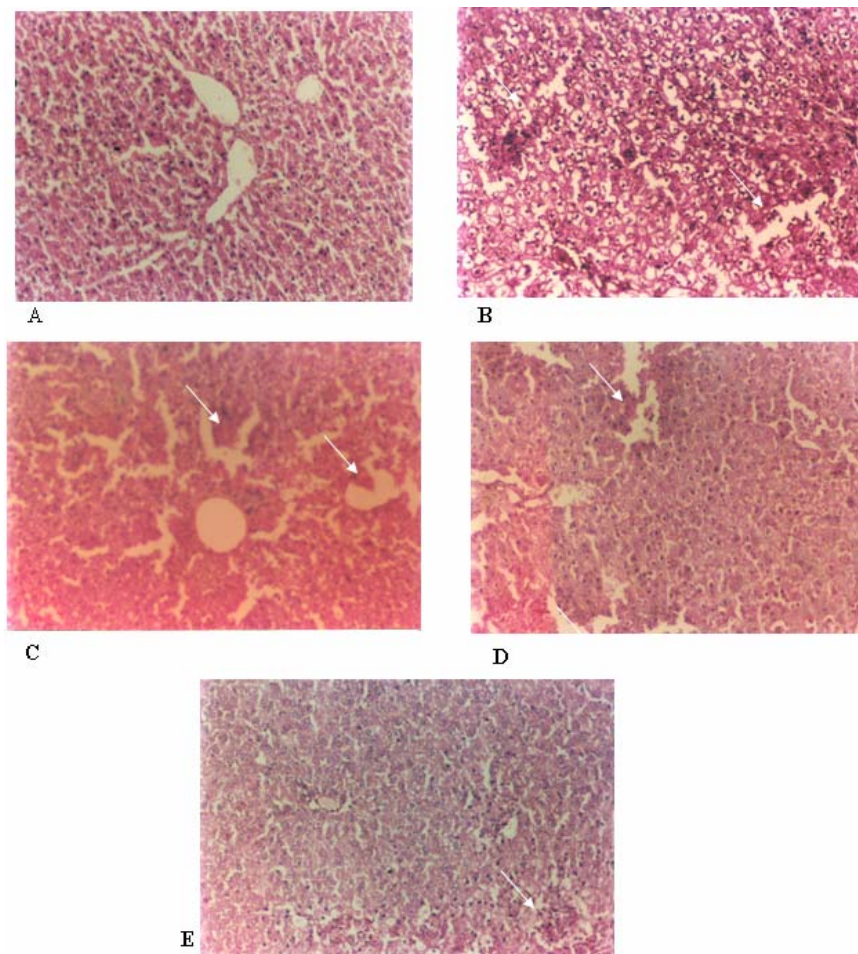


Fig 3. Assessment of CCl_4 -induced hepatotoxicity by histopathology in Haematoxylin-eosin stained liver sections. **A.** Section from normal liver tissue. **B.** Three days after CCl_4 intoxication, liver tissue showing zonal necrosis, extensive diffuse vacuolar degeneration engorged with blood and microvesicular fatty changes in hepatocytes. **C.** Silymerin treated liver tissue showed focal necrosis, lobular necrosis and sinusoidal dilation with slightly altered hepatic parenchyma. **D.** WTTF (250 mg/kg) pretreatment showed focal coagulative necrosis, lobular necrosis, mild fatty vacuolation and dilated sinusoids. **E.** WTTF (400 mg/kg) treatment showed mild portal inflammation and focal necrosis with normal hepatocyte (10X).

Hypoalbuminaemia is most frequent in the presence of advanced chronic liver diseases. Hence decline in total protein content can be deemed as a useful index of the severity of cellular dysfunction in chronic liver diseases. The lower level of total proteins recorded in the serum of CCl_4 treated rats reveals the severity of hepatopathy. WTTF treatment did not show any significant effect to attain normal protein content of CCl_4 intoxicated rats. These results signify that the WTTF may not have effect on cellular regeneration of macromolecules. The tendency of these enzymes to return towards a near normal level in WTTF treated rats is a clear manifestation of antihepatotoxic effect of *W. tinctoria*.

Hyperbilirubinaemia can result from impaired hepatic uptake of unconjugated bilirubin. Such a situation can occur in generalized liver cell injury.

Certain drugs like rifampin and probenecid interfere with the net uptake of bilirubin by the liver cell and may produce a mild unconjugated hyperbilirubinaemia [39]. Both total and direct bilirubin level rise in disease of hepatocytes, obstruction to biliary excretion into deodenum, hemolysis, in defects of hepatic uptake and conjugation of bilirubin pigment such as in Gilbert's disease. WTTF treatment significantly reduced the elevated serum level of total and direct Bilirubin.

Liver toxicity increases liver weight, as in paracetamol intoxication, fatty changes occur and there is a fall in serum lipids. Avadhoot and Rana and Bhanwara et al. reported this as a parameter in ascertaining the hepatoprotective effect of drugs [40-41]. Animals of negative control group significantly lost their body weight and showed reduced food consumption as compared to control group. WTTF treatment showed a significant reversal towards loss of body weight. These findings suggest that *W. tinctoria* TF administration significantly neutralized the toxic effect of CCl_4 and helped in regeneration of

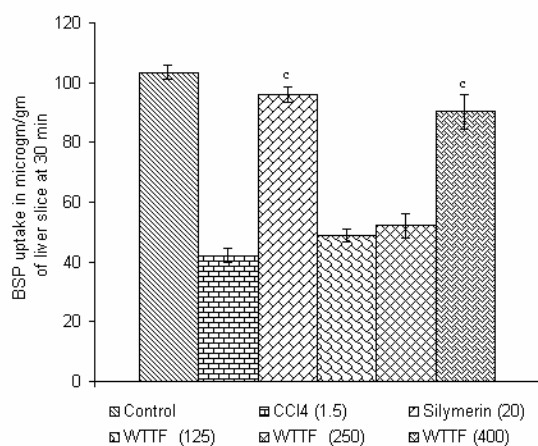


Fig 4. Effect of *W. tinctoria* triterpenoidal fraction on BSP uptake of CCl₄ treated rat liver slices. n = 6. *p<0.001 and ns = not significant when compared to negative control (CCl₄-treated) group.

Hepatic damage is a measure of activity of hepatic microsomal drug metabolizing enzymes. Intoxicated liver prolongs duration of sleeping time for hexobarbitone, thiopentone, zoxazolamine and pentobarbitone in animals. Thiopentone induced sleeping time in animals with liver intoxication is increased as the enzyme responsible for metabolism of thiopentone is reduced or destroyed [42]. Therefore, protective effect exhibited by *W. tinctoria* TF may be due to protection of hepatic drug-metabolizing enzymes as evidenced from decrease in thiopentone-induced sleeping in treated animals.

CCl₄ intoxication reduces the number of viable cell as highly reactive CCl₃[•] radical-induced lipid peroxidation disturbs Ca²⁺ homeostasis and finally results in cell death [37]. WTTf treatment significantly increased the number of viable hepatocytes which may be attributed to the inhibition of toxin induced free radical generation and in turn stabilizing the cell membrane. WTTf significantly increased glutathione and SOD. Increase in glutathione activity indicated that WTTf helps in the restoration of vital molecules such as NAD, cytochrome and glutathione. Restoration of SOD can help in cellular defense mechanism by preventing cell membrane oxidation. WTTf significantly decreased lipid peroxidation. By virtue of this antioxidant activity, the Triterpene fraction preserved the structural integrity of the plasma cellular membrane of the hepatocytes and protected it from breakage by the reactive metabolites produced. WTTf at higher dose have significantly improved the capacity of the damaged liver to take up BSP. This increased uptake of BSP by the liver slices showed it enhanced capacity to excrete the dye from the blood.

The histopathological studies are direct evidence of efficacy of drug as hepatoprotective agent. Simultaneous treatment of WTTf with CCl₄ exhibited less damage to the hepatic cells as compared to the rats treated with CCl₄ alone. Hepatic cells adjoining to

intralobular vein show atrophy. Almost negligible damage to a few hepatocytes present in the close vicinity of intralobular vein was observed. Endothelium lining was almost smooth except at one or two places. Hepatocytes showed normal appearance, only some cells showed higher number of vacuoles in the cytoplasm. Although WTTf did not appear to bring a complete reversal of drug-induced injury in the liver but had minimized the effect of CCl₄. The histopathological observations showed a faster regeneration of hepatic cells which seem to suggest the possibility of WTTf being able to condition the hepatic cells to a state of accelerated regeneration, thus decreasing the leakage of SGPT, SGOT and ALP into the circulation [43].

In conclusion, the observed protective effect of *W. tinctoria* triterpenoidal fraction against hepatotoxins may be attributed to the presence of lupeol and beta-amyrin. The curative action on hepatic injury by the *W. tinctoria* TF may be due to the presence of active compounds which prevents liver plasma membrane alteration or promote repair of the liver cells. Plants containing Triterpenoidal constituents are reported to have hepatoprotective activity against ethanol-, paracetamol-, cadmium-, ter-butyl hydroperoxide-, galactosamine-, aflatoxin- and carbon tetrachloride-induced hepatotoxicity [4,5]. Hepatoprotective effect of WTTf on liver injury may be due to its free radical scavenger and antioxidant action. Lupeol and alpha- and beta-amyrin had been reported to have hepatoprotective activity against cadmium-induced hepatotoxicity and acetaminophen-induced liver injury which is predominantly attributed to its antioxidant activity [44,45,3]. In brief, this study supports the traditional use of *W. Tinctoria* bark as an herbal remedy for jaundice and other liver disorders suggesting the feasibility of developing herbal formulation and clinical studies.

ACKNOWLEDGEMENT

This study was supported by the AICTE, New Delhi, by providing National Doctoral Fellowship (Dr. P. Bigoniya) to one of the authors. The authors are thankful to M/S Ranbaxy Laboratories Ltd., Devas (India) for providing the gift sample of silymerin used for the study.

REFERENCES

1. Harsh M. The liver, biliary tract and exocrine pancreas. In: Textbook of Pathology, 4th ed. New Delhi: Jaypee Brothers Medical Publishers (P) Ltd.; 2000. pp. 22-24 and 669-30.
2. Laszczyk M, Jager S, Simon-Haarhaus B, Scheffler A, Schempp CM. Physical, chemical and pharmacological characterization of a new oleogel-forming triterpene extract from the outer bark of birch (betulae cortex). *Planta Med* 2006; 72:1389-95.
3. Oliveira FA, Chaves MH, Almeida FR, Lima RC Jr, Silva RM, Brito GA, et al. Protective effect of alpha- and beta-amyrin, a triterpene mixture from Protium heptaphyllum (Aubl.) March. trunk wood resin, against acetaminophen-induced liver injury in mice. *J Ethnopharmacol* 2005; 98:103-8.
4. Yoshikawa M, Morikawa T, Kashima Y, Ninomiya K, Matsuda H. Structures of new dammarane-type Triterpene Saponins from the flower buds of Panax notoginseng and hepatoprotective effects of principal Ginseng Saponins. *J Nat Prod* 2003; 66:922-7.

5. Tran QL, Adnyana IK, Tezuka Y, Harimaya Y, Saiki I, Kurashige Y, *et al.* Hepatoprotective effect of majonoside R2, the major saponin from Vietnamese ginseng (*Panax vietnamensis*). *Planta Med* 2002; 68:402-6.
6. Kirtikar KR, Basu BD. *Indian Medicinal Plants*. 2nd and reprint ed. Delhi: Jayyed Press; 1975. p. 1581 (vol 11).
7. Krishnamoorthy JR, Ranganathan S. Antipityrosporom ovale activity of an herbal drug combination of *Wrightia tinctoria* and *Hibiscus rosasinensis*. *Ind J Dermatol* 2000; 45:125-6.
8. Reddy YSR, Venkatesh S, Ravichandran T, Murugan V, Suresh B. Antinociceptive activity of *Wrightia tinctoria* bark. *Fitoterapia* 2000 73:421-3.
9. Veerapur VP, Palkar MB, Srinivasa H, Kumar MS, Patra S, Rao PG.M, *et al.* The effect of ethanol extract of *Wrightia tinctoria* bark on wound healing in rats. *J Nat Remedies* 2004; 4:155-9.
10. Bigoniya P, Rana AC, Agrawal GP. Evaluation of the antiulcer activity of hydro-alcoholic extract of *Wrightia tinctoria* bark in experimentally induced acute gastric ulcers on rat. *Nigerian. J Nat Prod Med* 2006; 10:36-40.
11. Bigoniya P, Shukla A, Agrawal GP, Rana AC. Pharmacological screening of *Wrightia tinctoria* bark hydro-alcoholic extract. *Asian J Exp Sci* 2008; 22:235-44.
12. Bigoniya P, Rana AC, Lariya S. Immunomodulatory activity of *wrightia tinctoria* bark alcoholic extract on rats. *Curr Pharma Res J* 2010; In press.
13. George V, Koshy AS, Singh OV, Nayar MNS, Pushpangadan P. Tryptanthrin from *Wrightia tinctoria*. *Fitoterapia* 1996 LXVII(6):553-4.
14. Rao MN, Rao EV, Rao VS. Occurrence of oleanolic acid in the pods of *Wrightia tinctoria* Br. *Curr Sci* 1968; 22:645.
15. Ramchandra P, Basheermya M, Krupadanam GLD, Srimannarayana G. Wrightial, a new terpene from *Wrightia tinctoria*. *J Nat Prod* 1993; 56:1811-2.
16. Akihisa T, Ahmad I, Singh S, Tamura T, Matsumoto T. 14 α -methylzymosterol and other sterols from *Wrightia tinctoria* seeds. *Phytochemistry* 1988; 27:3231-4.
17. Rangaswami S, Nageswara RM. Crystalline chemical components of the bark of *Wrightia Tinctoria* Br. *Proc Ind Acad Sci* 1963; 57(A):115-20.
18. Paech T, Tracy MV. *Modern Methods in Plant Analysis*. Berlin: Springer Verlag; 1955. p. 387.
19. Diener W, Mischke U, Kayser D, Schlede E. The evaluation of the OECD modified version of acute toxicity class method (oral). *Arch Toxicol* 1995; 69:729-34.
20. Singh B, Saxena AK, Chandan BK, Bhardwaj V, Gupta VN, Suri OP, Handa SS. Hepatoprotective activity of indigtone bioactive fraction from *Indigofera tinctoria* Linn. *Phytother Res* 2001; 15:294-7.
21. Kind PRN, King EJ. In: Varley H, Gowenlock AH, Bell M, editor. *Method of Practical Clinical Biochemistry*. London: Heinman; 1980. p. 899-900.
22. Reitman S, Frankel S. A colorimetric method for determination of serum glutamic-oxaloacetic and glutamic-pyruvic transaminases. *Am J Clin Pathol* 1957; 28:56-63.
23. Jendrassik L, Gorf P. Vereinfachte photometrische Methoden zur Bestimmung des Blutbilirubins. *Biochem Zeitsch* 1938; 297:81-9.
24. Lowry OH, Rosenbrough NJ, Farr AL, Randall RJ. Protein measurement with folin phenol reagent. *J Biol Chem* 1951; 193:265-75.
25. Keyser JW. Rapid estimation of albumin and total protein in small amounts of blood serum. *Clinica Chimica acta; Int J Clin Chem* 1961; 6:445-7.
26. Allain CC, Poon LS, Chan CS, Richmond W, Fu PC. Enzymatic determination of total serum cholesterol. *Advan Clin Chem* 1974; 20:470-5.
27. McGowan MW, Artiss JD, Strandbergh DR, Zak B. A peroxidase-coupled method for the colorimetric determination of serum triglycerides. *Advan Clin Chem* 1983; 29:538-42.
28. Tietze F. Enzymic method for quantitative determination of nanogram amounts of total and oxidized glutathione: applications to mammalian blood and other tissues. *Anal Biochem* 1969; 27:502-22.
29. Shenoy AK, Somayaji SN, Bairy KL. Hepatoprotective effects of *Ginko biloba* against carbon tetrachloride induced hepatic injury in rats. *Ind J Pharmacol* 2001; 33:260-6.
30. Ohkawa H, Ohishi N, Yagi K. Assay for lipid peroxidation in animal tissues by thiobarbituric acid reaction. *Anal Biochem* 1979; 95:351-8.
31. Misra HP, Fridovich I. The role of superoxide anion in the autoxidation of epinephrine and a simple assay for superoxide dismutase. *J Biol Chem* 1979; 247:3170-5.
32. Nanji AA, Jakelainen K, Fotouhinia M, Rahemtulla A, Thomas P, Tipoe LG, *et al.* Increased severity of alcoholic liver injury in female rats: Role of oxidative stress, endotoxin and chemotoxin. *Am J Physiol Gastrointestinal Liver Physiol* 2002; 281:G1348-56.
33. William GM, Elizebeth K, Weisburger HJ. Isolation of long term cell culture of epithelial like cells from rat liver. *Exp Cell Res* 1971; 69:106-12.
34. Rajan R, Subrahmanyam K. Uptake of sodium phenol tetrabromophthalein (bromsulphalein) by rat liver slices under different conditions. *Ind J Exp Biol* 1965; 24:100-3.
35. Cameron GR, Karunarathe WAE. The pathogenesis of liver injury in carbon tetrachloride and thioacetamide poisoning. *J Pathol Bacteriol* 1936; 81:107-17.
36. Johnston DE, Kroening C. Mechanism of early carbon tetrachloride toxicity in cultured rat hepatocytes. *Pharmacol Toxicol* 1998; 83:231-9.
37. Recknagel RO, Glende EA Jr, Dolak JA, Waller RL. Mechanism of carbon tetrachloride toxicity. *Pharmacol Ther* 1989; 43:139-45.
38. Gergely J, Kulcsar A, Harsfalvi J. Changes in fat metabolism in acute carbon tetrachloride intoxication of rats. *Acta Pharm Hung* 1995; 65:3-4.
39. Rubin EL. The liver and biliary system. In: Lippincott Williams and Wilkins, editor. *Essential Pathology*. 3rd ed. U.S.A.: Wolters Kluwer Company; 1995. p. 393-440.
40. Avadhoot Y, Rana, AC. Hepatoprotective effect of *Vitex negundo* against carbon tetrachloride induced liver damage. *Arch Pharmacol Res* 1991; 14:96-8.
41. Bhanwara S, Singh J, Khosla P. Effect of *Azadirachta indica* (NEEM) leaf aqueous extract on paracetamol-induced liver damage in rats. *Ind J Physiol Pharmacol* 2000; 44:64-8.
42. Singh B, Saxena AK, Chandan BK, Agrawal SG, Anand KK. *In vivo* hepatoprotective activity of active fraction from ethanolic extracts of *Eclipta alba* leaves. *Ind J Physiol Pharmacol* 2001; 45:435-41.
43. Hewawasam RP, Jayatilaka KAPW, Pathirana C, Mudduwa LKB. Protective effect of *Asteracantha longifolia* extract in mouse liver injury induced by carbon tetrachloride and paracetamol. *J Pharm Pharmacol* 2003; 55:1413-8.
44. Prasad S, Kalra N, Shukla Y. Hepatoprotective effects of lupeol and mango pulp extract of carcinogen induced alteration in Swiss albino mice. *Mol Nutr Food Res* 2007; 51:352-9.
45. Sunitha S, Nagara J, Varalakshmi P. Hepatoprotective effect of lupeol and lupeol linoleate on tissue antioxidant defence system in cadmium-induced hepatotoxicity in rats. *Fitoterapia* 2001; 72:516-23.

CURRENT AUTHOR ADDRESSES

P. Bigoniya, Radharaman College of Pharmacy, Ratibad, Bhopal, M.P. India. E-mail: p_bigoniya2@hotmail.com (Corresponding Author)

A. C. Rana, Department of Pharmaceutical Sciences, Dr H. S. Gour University, Sagar- 470003, Madhya Pradesh, India.