

An Unusual Presentation of Opioid Induced Cerebral Infarction

Mujeeb-Ur-Rehman Abid Butt¹ and Reeja Nadir²

ABSTRACT

Opioid induced cerebral infarction is one of the most dreadful complications encountered in clinical practice. A 30-year known hypertensive male presented to the emergency department of Shalamar Hospital, Lahore, Pakistan, with altered state of consciousness. He had been in his usual state of health a day before the presentation. On examination he was afebrile, his GCS was 3/15 having pinpoint pupils with absent doll's eye movements. His blood pressure was 90/60 mmHg, pulse rate was 62/minute, and respiratory rate was 10/minute. His right plantar was upgoing. He was resuscitated in emergency and was placed on ventilator due to hypoxemia. Computed tomography (CT) of brain revealed bilateral internal capsule hypodensities and bilateral frontal lobe infarction. His urinary toxicological screening revealed extremely high concentrations of opioids and benzodiazepine. Patient made an uneventful recovery with antidote and supportive care.

Key Words: Opioids. Benzodiazepine. Intoxication. Cerebral infarction.

INTRODUCTION

United States National Health Survey 2007 revealed that around one million people visited emergency department (ED) in the United States with drug abuse.¹ In 2010, around 99,000 to 253,000 people died worldwide of illicit drug usage and the opioids were the most common offending agents out of this huge number.² Though opioids are approved by the Food and Drug Administration (FDA) for the treatment of pain,³ but 8.1% of the general population is suffering from opioid abuse disorder and 16% of active pain patients were found to be abusing their medications.⁴ Drug abusers of 15 years to 44 years of age are 6.5 times more predisposed to have a stroke. In comparison with amphetamines, opiates have 16 times lesser incidence of hemorrhagic and 5 times lesser incidence of ischemic stroke. Heroin is reported to be mostly associated with ischemic strokes.¹

We report a case of bilateral frontal lobes and internal capsule infarctions with opiate intoxication.

CASE REPORT

A 30-year male was found unconscious in the morning around 9:00 a.m. at home and was brought to the hospital. He was in his usual state of health till evening, before presenting to the emergency department of Shalamar Hospital, Lahore. The family reported that he runs his own pharmacy and after closing his store

around 12 midnight, he religiously visits a nearby mausoleum for a short time span, at least three to four times a week. He then goes to bed and normally wakes up at 9:00 a.m. Further history revealed that on the day of admission to the hospital, he came back from the mausoleum around 5:00 am and went to sleep but did not wake up afterwards. He had four siblings with one brother having hypertension. He had been a smoker and was diagnosed as hypertensive 2 years ago with poor compliance to antihypertensive drugs. Few weeks back, he had complaints of severe pain in his right shoulder due to a road traffic accident. The drug history included Amlodipine 5 mg, Tramadol 50 mg on as and when required basis for the shoulder pain and Bromazepam 3 mg for insomnia.

At the time of entry to the hospital, his GCS was 3/15, pulse was 62/minute, blood pressure was 90/60 mmHg and respiratory rate was 10/minute. He was afebrile, blood sugar was 130 mg/dL and oxygen saturation 60% on pulse oximeter. Chest was clear on auscultation and abdominal examination revealed no visceromegaly, whereas bowel sounds were sluggish. Central nervous system examination revealed pinpoint pupils, absent doll's eye movements, and brisk tendon reflexes in lower limbs. His right side plantar was upgoing, while the left was equivocal. During his stay in the emergency department, patient developed an episode of tonic-clonic fit for which injection dormicum 5 mg followed by injection diazepam 5 mg were administered. Patient was resuscitated in emergency and immediately shifted to Intensive Care Unit because of hypoxemia. His airway was secured and was placed on ventilator.

Treatment was started with repeated dosages of Naloxone adjusted as per response of respiratory depression and pupillary size. At the time of entry to intensive care unit, arterial blood gases (ABG's) revealed pH of 7.31, PaCO₂ of 49 mmHg, PaO₂ of 68 mmHg, and HCO₃ at 26 mmol/L, which highlighted

Department of Medicine¹ / Clinical Dietitian², Shalamar Medical and Dental College, Shalamar Hospital, Lahore, Pakistan.

Correspondence: Prof. Mujeeb-Ur-Rehman Abid Butt, Consultant Physician and Head of Medicine Department, Shalamar Medical and Dental College, Shalamar Hospital, Lahore.

E-mail: mujeeb_b@yahoo.com

Received: July 29, 2015; Accepted: December 30, 2015.

ventilatory failure. Baseline investigations including complete blood count, liver function test, renal function test, and thyroid function tests were normal. Viral serology for hepatitis was found negative. His urinary toxicological screening revealed extremely high concentrations of opioids and benzodiazepine while nil urinary cocaine was found (Table I). His chest X-ray was normal. To rule out intracranial infective process while the toxicological report was awaited, lumbar puncture was done. Cerebrospinal fluid (CSF) analysis revealed normal CSF opening pressure with cell count of 5/cmm,

Table I: Urinary toxicological screening and cardiac markers.

Urine toxicology report		
Amphetamine	Negative	Cut Off value 1000 ng/ml
Urinary Cannabinoids	Negative	Cut Off value 50 ng/ml
Urinary Barbiturates	Negative	Cut Off value 200 ng/ml
Urinary Benzodiazepines	Positive	Cut Off value >900 ng/ml 200 ng/ml
Urinary Opiates	Positive	Cut Off value >3800 ng/ml 2000 ng/ml
Cardiac enzymes		
AST	155 U/L	5.0-40.0 U/L
CK-MB	15 IU/L	Up to 25 IU/L
CPK	372 U/L	Up to 190 U/L
LDH	527 U/L	Up to 460 U/L
Troponin I		
20-2-2014	22-2-2014	04-03-2014
2.53 ng/dl	0.900 ng/dl	<0.012 ng/dl

<0.08 : low risk; 0.09-0.2: Increased cardiovascular risk; > 0.3: Acute myocardial inflection

80% lymphocytes, and 20% neutrophils. CSF glucose was 89 mg/dl while blood glucose was 125 mg/dl. CSF protein level was 54 mg/dl with range of 25 - 40 mg/dl. No organism was seen on Gram and ZN staining. Computed tomography (CT, Figure 1) done twice revealed bilateral frontal lobe infarctions which appeared old one while bilateral internal capsule hypodensities resembling fresh infarctions. His electrocardiography (ECG) on day 1 revealed ST segment elevation in leads V1 to V3. On the third day of admission, his ECG showed no abnormality. His cardiac markers are shown in Figure 1. Echocardiography done on day-2 revealed mild left ventricular hypertrophy and early diastolic dysfunction with no segmental wall motion abnormality.

Patient was managed with Naloxone, Aspirin, Rosuvastatin, subcutaneous Enoxaparin 40 mg and general supportive care with which he made an uneventful recovery. Patient was extubated on the 3rd day of admission and was discharged to home after 1 week of admission. Urinary opiate turns out to be negative prior to discharge from the hospital while benzodiazepine was still found in urinary toxicological screening. His cardiovascular status was assessed by cardiologist and no further intervention was recommended. Upon follow-up after a week of discharge from the hospital, patient's GCS was 15/15 and he scored 21/30 on mini mental scale examination (MMSE). He was bradykinetic, had poor orientation, and recall of recently learnt nouns along with impairment of remote memory. He had low mood and decreased spontaneous speech with no suicidal ideation. Cranial nerves were intact. Power was 5/5 in all limbs. Planters were up-going bilaterally and the reflexes were brisk.

DISCUSSION

Opiates are drugs derived naturally from poppy plants whereas opioids are the chemicals, either chemically synthesized or derived from the poppy plant. Commonly known opioids include morphine, dimorphine/diacetylmorphine, commonly known as heroin, methadone, buprenorphine, codeine, tramadol, fentanyl, oxycodone and hydrocodone.^{5,6} There are three classes of opioid receptors which influence pain perceptions and euphoria and are also involved in the regulation of breathing.⁶

This patient fulfilled the criteria for diagnosing opioid intoxication by Diagnostic and Statistical Manual of Mental Disorders (DSM-5) which includes recent use of an opioid, clinically significant psychological changes, pupillary constriction because of severe overdose and any one of the symptoms like drowsiness/coma, slurred speech, impaired attention or memory loss, provided these features are not attributable to another medical conditions.⁷

Heroin tends to cause hypotension from decreased peripheral vascular resistance, bradycardia; and if taken

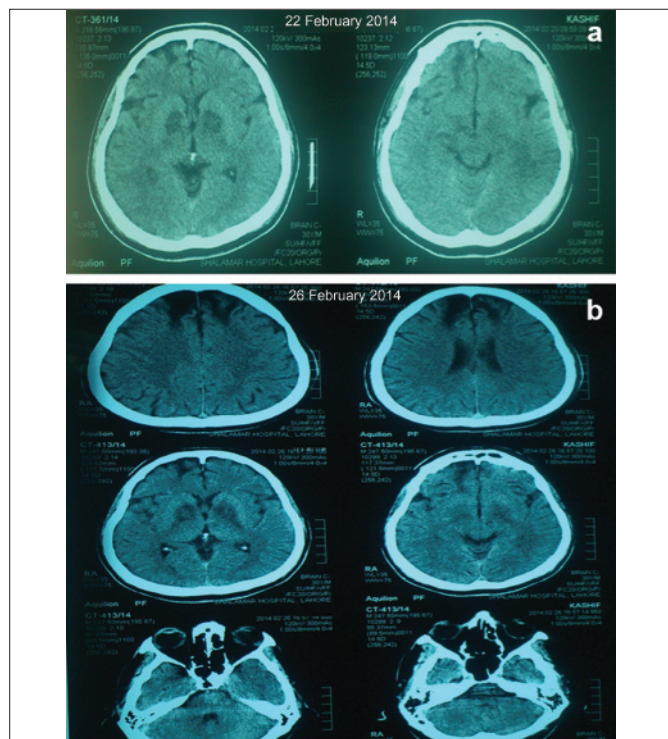


Figure 1: CT scan of the patient.

in excess, leads towards lethal respiratory depression and eventually to cerebral hypoxia.^{1,5} Latter manifests as infarctions in the water-shed areas of brain distributed at the junction of three cerebral arteries perfused regions, as evident in this case where the infarctions are seen at the junction of anterior and middle cerebral arteries/territories in frontal lobes.

Heroin may be taken in different ways: intravenously, subcutaneously, smoked, sniffed, or inhaled.⁸ Heroin intoxication that occurs through inhalation of fumes when it is burnt on an aluminum foil and the fumes are inhaled through a straw, procedure commonly known as "Chasing a Dragon", characteristically leads to toxic leukoencephalopathy. Latter progress through three stages clinically depending upon the degree of intoxication; and it includes cerebellar signs, motor restlessness, pyramidal and pseudopyramidal signs. Small proportion of patients develops spasms, hypotonic paralysis and ultimate death.⁹ It manifests radiologically on plain CT scan as hypodense foci in cerebellum and posterior limbs of internal capsule, as could be seen in this case. Reasons for such pathological changes might be due to impurities that get heated while "chasing the dragon". No history of heroin intoxication was found in our case through this route. Histopathology of such lesions reveals spongiform leukoencephalopathy.

Irrespective of the cause of cerebral hypoxia, certain sequels are characteristically seen including cognitive impairment, parkinsonism, cerebellar ataxia, myoclonus, epilepsy, and persistent vegetative state.¹⁰ Bradykinesia

and cognitive impairment were found on subsequent follow-up of this patient.

REFERENCES

1. Esse K, Fossati-Bellani M, Traylor A, Martin-Schild S. Epidemic of illicit drug use, mechanism of action/addiction and stroke as a health hazard. *Brain Behav* 2011; **1**:44-54.
2. World Drug Report. Vienna: United Nations publication; 2012 p.1-112.
3. Fareed A, Stout S, Casarella J, Vayalapalli S, Cox J, Drexler K. Illicit opioid intoxication: Diagnosis and treatment. *Substance abuse. Res Treat* 2011; **5**:17-25.
4. Benyamin RM, Trescot A, Datta S, Buenaventura R, Adlaka R, Sehgal N, *et al*. Opioid complications and side effects. *Pain Physician J* 2008; **11**:S105-20.
5. Rosenblum AA, Marsch L, Joseph HK, Portenoy R. Opioids and the treatment of chronic pain: Controversies, current status, and future directions. *Exp Clin Psychopharmacol J* 2008; **16**:405-16.
6. Discussion paper UNODC/WHO Opioid overdose: Preventing and reducing opioid overdose mortality. Vienna: United Nations; 2013 p.4-28.
7. Diagnostic and Statistical Manual of Mental Disorders: DSM-V. Washington, DC: *American Psychiatric Association*; 2013.
8. Enevoldson T. Recreational drugs and their neurological consequences. *J Neurol Neurosurg Psychiatry* 2004; **75**:iii9-iii15.
9. Keogh CT, Andrews GD, Spacey SE, Forkheim KA, Graeb D. Neuroimaging features of heroin inhalation toxicity: Chasing the dragon. *AJR* 2003; **180**:847-50.
10. Garrido M, Bayarri J. Hypoxic encephalopathy. *Miscellanea on encephalopathies - A second look* 2012; 149-66.

