

CASE REPORT

Cemented total hip arthroplasty with retention of some existing hardware

Fernando Monteiro Judas, Joana Bento Rodrigues, Francisco Manuel Lucas, João Paulo Freitas

Department of Orthopaedics, CHUC, Coimbra, Coimbra, Portugal

Correspondence to
Dr Fernando Monteiro Judas,
fernandojudas@gmail.com

Accepted 9 June 2014

SUMMARY

We report a case of a 63-year-old man who presented an end stage hip osteoarthritis 42 years after a proximal femoral osteotomy performed for the treatment of an intracapsular femoral neck fracture. A cemented total hip arthroplasty was implanted using a standard posterior approach. The osteotomy hardware was totally covered with a new cortical bone formation. A layer of bone tissue was removed, the screw heads were broken and the nail plate was also removed. The screw threaded portions were retained because they did not interfere with cemented femoral stem implantation. Fourteen years after total hip arthroplasty, the patient reported no pain and expressed high satisfaction with the surgery. The hip radiograph showed wear of the polyethylene cup and no periprosthetic osteolysis. Retention of hardware can be considered, especially in patients who have had hardware for several years, without any negative symptoms.

BACKGROUND

Several problems may be encountered in inserting the femoral stem for total hip arthroplasty (THA) following previous femoral valgus osteotomy.

Anatomical changes to the femur and removal of osteotomy hardware can cause important technical difficulties. Fluoroscopic examination may be required to visualise the maximum angulation present in a distorted proximal femur, and careful preoperative planning with standard radiographs and CT are necessary. A femoral osteotomy or a transfemoral approach may be necessary for femoral stem implantation. THA with concurrent femoral osteotomy is a technically demanding procedure.^{1–3}

Extraction of an internal fixation device during the conversion of a failed intertrochanteric osteotomy to a THA may lead to excessive trauma of the femoral shaft, because the implants are often covered with bone tissue. Patience and caution may be required to avoid intraoperative bone fractures and to limit the amount of host bone destruction.

In an attempt to bypass the risk of complications, THA can be performed leaving the internal fixation material in place. Although, theoretically, the coexistence of different metals in the femoral shaft should be avoided, in practice it does not appear to create a problem for patients. This may be attributed to insulation of the dissimilar materials by the bone cement.⁴

Proximal femoral osteotomy is a valuable surgical option in the treatment of a variety of conditions

affecting the hip, but some patients will subsequently require THA. Little has been written, however, concerning the technical difficulties, operative complications and outcome of hips which were converted to a THA after a previous femoral osteotomy.

The main purpose of this paper was to show clinical and radiographic outcomes of a cemented THA at 14 years' follow-up, performed with retention of some existing osteotomy hardware.

CASE PRESENTATION

A 63-year-old man, hairdresser by trade, in January 2000 visited our department presenting a constant severe pain referred to the right groin exacerbated by movement and resistant to analgaesic medication. He walked with two forearm crutches; his body mass index was 25.

Forty-two years earlier, the patient underwent a valgus femoral osteotomy for the treatment of a traumatic displaced fracture of the femoral neck (figure 1), level 2, type B2, according to the HUC classification.⁵ The osteotomy was fixed with a Smith Peterson nail and MacLaughlin plate. The postoperative course was uneventful. Fracture and osteotomy consolidation were observed with no complications.

In January 2000, the radiographs showed an advanced osteoarthritis of the right hip (figure 2). A cemented THA was performed with a cobalt-chrome femoral head articulating with an ultra-high-molecular-weight polyethylene (UHMWPE) liner, using a standard posterior approach.

During surgery, following hip dislocation, the plate and four head screws were found totally covered with a new cortical bone formation. Using chisels, osteotomes and gouges, the layer of bone tissue was removed, the heads of the screws were broken and the plate was also removed. The threaded portions of the screws were left in place. The Smith Peterson nail was easily removed.

After cutting the femoral neck we explored and reamed the femoral canal. The threaded portion of the screws did not interfere with the femoral stem trial. A cemented cup of UHMW polyethylene and a cemented straight femoral stem (diameter 15) were implanted using the standard technique.

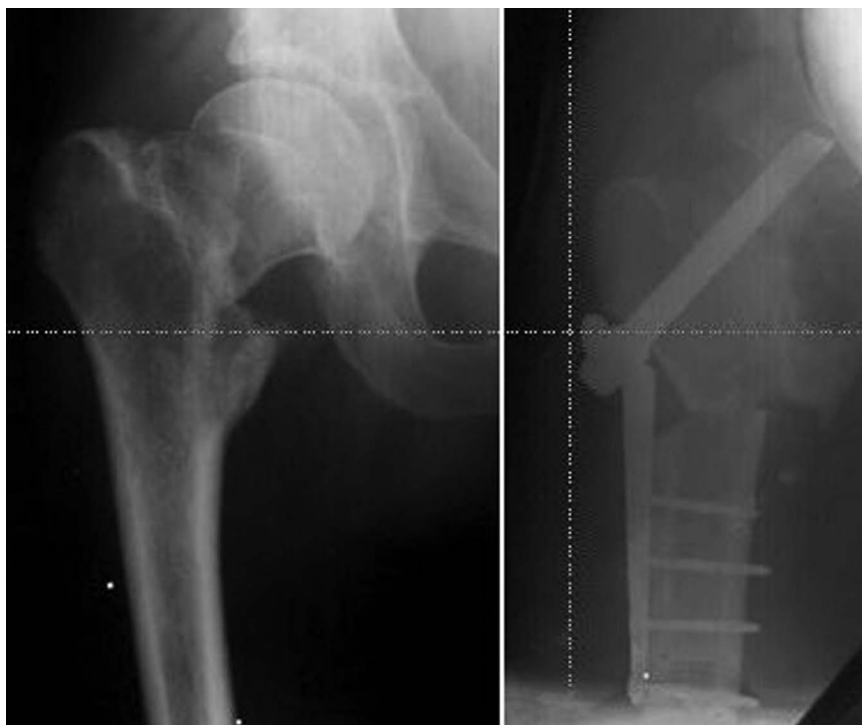Removal of the plate originated a moderate bone loss. For this reason, the femoral head was fragmented and the lateral femoral cortex was reinforced with morsellised cancellous bone autografts.

No complications were reported in the perioperative course or during the 4 days of the



To cite: Judas FM, Rodrigues JB, Lucas FM, et al. *BMJ Case Rep* Published online: [please include Day Month Year] doi:10.1136/bcr-2014-204821

Figure 1 Traumatic fracture of right femoral neck, in 1958. Femoral valgus osteotomy and osteosynthesis with a MacLaughlin plate and a Smith Peterson nail.

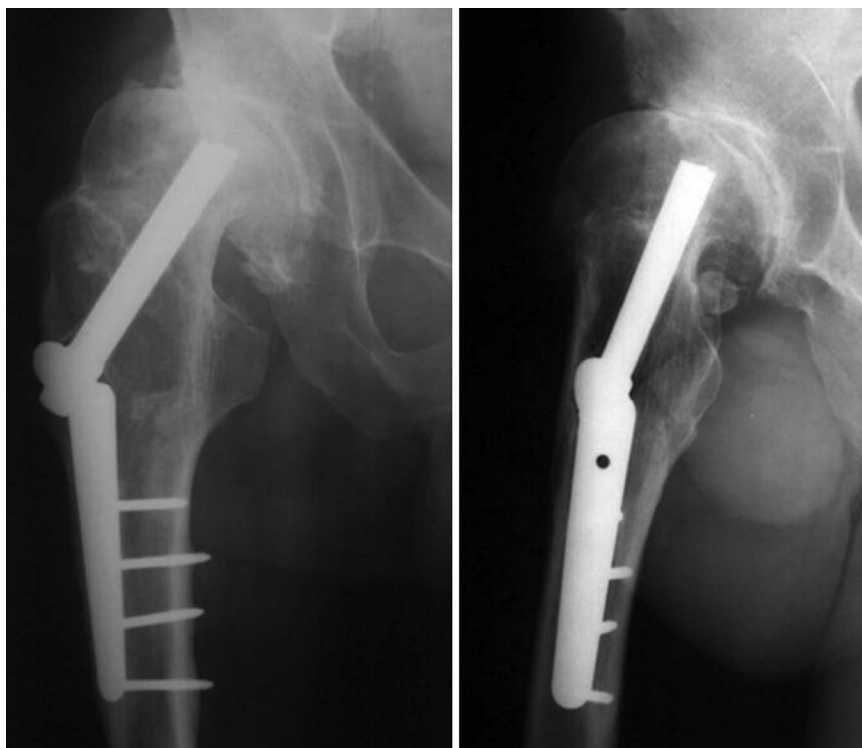


hospitalisation period. At 1 month postoperatively the patient was clinically able to walk without external support.

OUTCOME AND FOLLOW-UP

At 6 months after surgery the patient presented an asymptomatic hip, with no limitations in his social and professional life. The hip radiograph showed a satisfactory orientation of the prosthesis and some heterotopic ossification. The bone autografts were incorporated (figure 3).

Figure 2 Preoperative anteroposterior and lateral radiographs of the right hip, depicting advanced hip osteoarthritis 42 years after the femoral osteotomy.



At 14 years' follow-up, the patient presented a stable and asymptomatic hip and expressed high satisfaction with the surgery result. The hip radiograph showed wear of the polyethylene cup and no periprosthetic osteolysis. For this reason, it was possible to observe superior femoral head displacement from the centre of the acetabular cup (figure 4).

DISCUSSION

Our patient underwent a THA for the treatment of a failed intertrochanteric osteotomy. The preoperative planning included

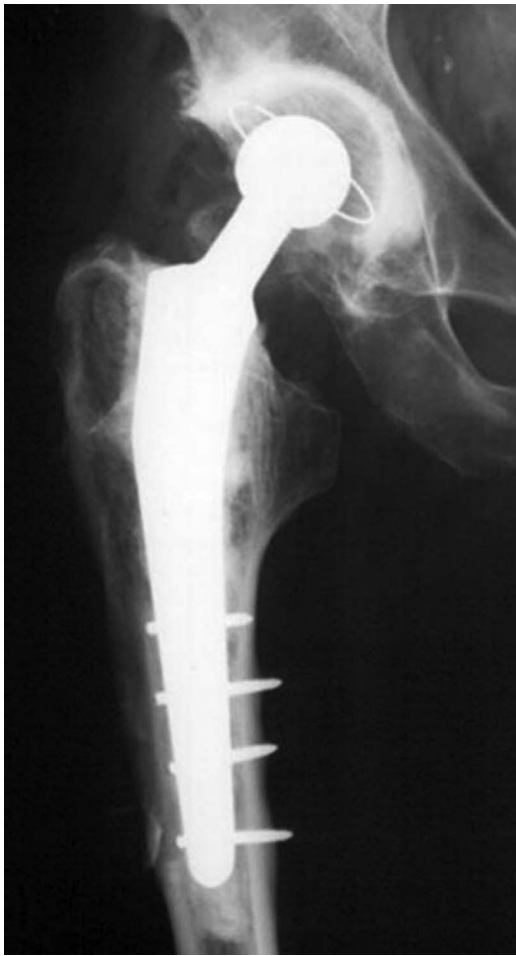

Figure 3 Postoperatively anteroposterior total hip arthroplasty radiograph at follow-up period of 6 months. The implant was stable with a satisfactory position, and it was possible to observe a bone remodelling process in the lateral femoral cortex.

removal of the osteotomy hardware and implantation of a cemented THA. The heads of the screws, the nail and the plate were removed, and after the cut of the femoral neck, the permeability of the femoral canal was explored. The screw threaded portions were retained because they did not interfere with the cementation of the femoral stem.

THA, when performed after an intertrochanteric osteotomy, is known to have a high short-term incidence of complications and infection.⁶ The operation can be technically demanding because of the distortion of the proximal femur. A wide range in variation exists when dealing with deformity of the proximal femur. Deformities can be found at the greater trochanter, femoral neck, metaphysis or diaphysis.⁷

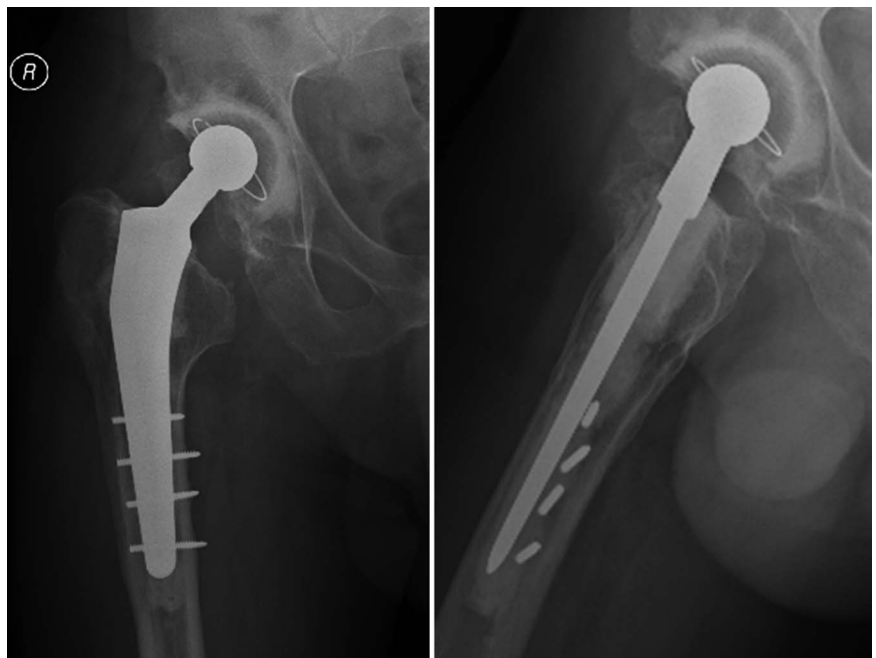
Varus and valgus osteotomies may distort the neck-shaft angle and the proximal femur which will influence the selection of femoral size and head/neck offset. Varus/valgus osteotomies can be combined with flexion/extension or medial/lateral displacement of the proximal segment relative to the femoral shaft. A proximal femoral osteotomy to realign the bone may be required before insertion of the femoral component. Rotational osteotomies may distort the anteversion and site of insertion of the stem.^{7,8}

Difficulties can also occur when the internal fixation is removed at the time of THA. These difficulties can lead to longer operative times and more intraoperative blood loss. Prior to removing any femoral hardware, the exposure should be completed and the hip dislocated, namely in stiff hip osteoarthritis. This limits the potential for intraoperative fracture to occur at the site of weakened bone from prior hardware.⁷

Removal of the metallic plates and screws is not always an easy task. Hardware that is not in the way of the arthroplasty or that does not compromise the fixation of the femoral stem may be left in place, especially in patients who have had hardware for several years without any negative symptoms.⁹

For safe implant removal during THA procedures, it is essential to use appropriate surgical techniques and equipment, including high-speed burr, metal-cutting burrs and wheels, and

Figure 4 At follow-up period of 14 years, the anteroposterior total hip arthroplasty radiograph showed wear of the polyethylene cup and no periprosthetic osteolysis. The lateral radiograph showed the relationship between the cemented femoral stem and the residual threaded portions of the metallic screws.



broken screw removal set. If the femoral canal is not permeable, removal of the screws by endomedullary approach would enable the femoral stem implantation.¹⁰ In addition, dense cancellous bone in the femoral canal at the level of the healed osteotomy requires careful reaming to avoid femoral perforation or fracture.

The presence of cortical holes can decrease the quality of cement–bone interdigitation, and small penetrations of cement through screw holes may act as stress risers in the mantle. Extravasation of cement from empty screw holes must be prevented, because it jeopardises the femoral reconstruction and, consequently, the durability of stem fixation is compromised. All stress risers, such as previous screw holes, should be bypassed with the intramedullary stem by two cortical diameters.⁷ Care must also be taken to avoid fracture due to stress concentration from a rasp or femoral component in relation to holes left by metal implants.

Removal of the osteosynthesis material may lead to bone loss, which can be reconstructed using cancellous bone autografts to reinforce the lateral femoral cortex. This is a strongly recommended procedure because autografting remains the gold standard for replacing bone loss, and cancellous bone grafts are almost totally revascularised and replaced by new host living bone.^{11 12}

Revision and modular femoral stems may eventually be needed for the treatment of intraoperative femoral fractures or bypass cortical perforations caused by screw removal.⁵

Although hardware removal is commonly performed, there is limited data to indicate whether this is necessary. Some investigators recommend the removal of internal fixation soon after union of the osteotomy in order to avoid intraoperative risks and complications with hardware removal. However, there is no compelling evidence to suggest that early removal of the implant is advantageous for the outcome of subsequent THA.⁸ If removal of osteotomy hardware is complex, surgery can be performed in two stages, with the THA being done after the soft tissues and cortical bone defects have healed.³

Surgeons and patients should be aware of appropriate indications and must have realistic expectations of the risks and benefits of implant removal. In this context, studies have shown that increased duration of hardware retention reduces refracture rates.¹³

Benke *et al*¹⁴ reviewed 105 patients who had osteotomy conversions with a minimum follow-up of 1 year (mean 4.7). Their infection rate was 8.6% with technical difficulties in 17.1%, necessitating the removal of the prosthesis in four cases. This is in line with the general view that infection rates are higher in revision procedures.

Patients who have had a previous osteotomy can achieve considerable clinical improvement after THA. However, the literature contains contradictory evidence as to whether previous proximal femoral osteotomy impairs the long-term outcomes of THA.

At a mean follow-up of 10 years of 215 hip replacements after previous osteotomy, Ferguson *et al*⁶ reported that 39 hips had been revised (18.1%), there was probable loosening in 19.5% of stems and 12.6% of cups and possible loosening in 11.4% of stems and 7.2% of cups. The cumulative probability of failure at 10 years was 20.6%.

Haverkamp *et al*¹⁵ suggested that the long-term outcome of a cemented THA was not impaired by a previous well-performed osteotomy. Cemented or cementless femoral reconstruction demonstrated reliable and durable results in conversion of femoral osteotomy to THA, with existing hardware or femoral

deformity.^{16 17} In cases where removal of the osteosynthetic device is expected to lead to severe trauma of the femur, it is no disadvantage to perform the THA leaving the internal fixation material in place.⁴

In this report, the last clinical and radiological evaluation showed a satisfactory result at a follow-up period of 14 years. The patient reported no pain and expressed high satisfaction with the surgery. The radiograph showed wear of the polyethylene cup and no periprosthetic osteolysis.

This result demonstrated the validity of cemented THA for the treatment of hip osteoarthritis following femoral valgus osteotomy, despite the wear of the bearing surfaces. In the long term, aseptic loosening induced by bearing surface wear is the most common means of failure of THA. Currently, it is an inevitable problem common to all hip endoprostheses.

In conclusion, it is important to emphasise that, in our case, a very satisfactory long-term result was obtained, despite total hip replacements following previous proximal femoral osteotomy having been reported with much higher incidence of complications. The rate of complications can be reduced by removing fewer implants during the hip replacement. The long-term outcome of a cemented THA is not impaired by the retained hardware.

Learning points

- ▶ Total hip arthroplasty performed after proximal femoral osteotomy may be a demanding operation, due to the removal of the osteotomy hardware and the correction of femoral deformities.
- ▶ The risk of complications is higher including infection, rasp perforation of the femoral canal, bone fractures during and after the operation, malposition of the stem and host bone destruction.
- ▶ Despite the technical difficulties and risks, hip arthroplasty can be achieved with acceptable risk and has good long-term results when minimal existing implants are removed.

Contributors All doctors have been involved in writing the case or at the time of operation.

Competing interests None.

Patient consent Obtained.

Provenance and peer review Not commissioned; externally peer reviewed.

REFERENCES

- 1 Delbarre JC, Hulet C, Schiltz D, *et al*. Total hip arthroplasty after proximal femoral osteotomy: 75 cases with 9-year follow-up. *Rev Chir Orthop* 2002;88:245–56.
- 2 Papagelopoulos PJ, Trousdale RT, Lewallen DG. Total hip arthroplasty with femoral osteotomy for proximal femoral deformity. *Clin Orthop* 1996;332:151–62.
- 3 Harkess JW, Crockarell JR. Arthroplasty of the hip. In: Canale ST, Beaty JH, eds. *Campbell's operative orthopaedics*. Vol 1. 11th edn. Philadelphia, PA: Mosby Elsevier, 2008:385–6, Chap 7.
- 4 Papapolychroniou T, Vafiadis J, Zacharopoulos K, *et al*. Coexistence of dissimilar metals after conversion of intertrochanteric osteotomy to total hip arthroplasty. 18 patients followed for 5–20 years after conversion. *Acta Orthop Scand Suppl* 1997;275:38–41.
- 5 Proença A, Judas F, Cabral R, *et al*. *Revision surgery of hip prostheses, osteolysis. Reconstruction with bone allografts*. Coimbra: Orthopaedics Department of Coimbra University Hospitals, 1996.
- 6 Ferguson GM, Cabanela ME, Ilstrup DM. Total hip arthroplasty after failed intertrochanteric osteotomy. *J Bone Joint Surg* 1994;76B:252.

- 7 Springer BD. Complex primary total hip arthroplasty. In: Parvizi J, Klatt BA, eds. *Essentials in total hip arthroplasty*. Slack Incorporated, 2013: 253–63, Chap 29.
- 8 Boos B, Krushell R, Ganz R, *et al*. Total hip arthroplasty after previous proximal femoral osteotomy. *J Bone Joint Surg Br* 1997;79-B:247–53.
- 9 Vail TP, Glisson RR, Dominguez DE, *et al*. Position of hip resurfacing component affects strain and resistance to fracture in the femoral neck. *J Bone Joint Surg Am* 2008;90:1951–60.
- 10 Dietz MJ, Chase S, Burke DW, *et al*. Novel technique for removal of a broken intracortical screw during THA. *Orthopedics* 2013;36:846–9.
- 11 Judas F. *Contribution to the study of morselized bone allografts and biomaterials* [PhD thesis]. Coimbra University, 2002.
- 12 Williams A, Szabo RM. Bone transplantation. *Orthopaedics* 2004;27:488–95.
- 13 Busam ML, Esther RJ, Obremskey WT. Hardware removal: indications and expectations. *J Am Acad Orthop Surg* 2006;14:113–20.
- 14 Benke GJ, Baker AS, Dounis E. Total hip replacement after upper femoral osteotomy: a clinical review. *J Bone Joint Surg Br* 1982;64-B:570–1.
- 15 Haverkamp D, de Jong PT, Marti RK. Intertrochanteric osteotomies do not impair long-term outcome of subsequent cemented total hip arthroplasties. *Clin Orthop* 2006;444:154–60.
- 16 Iwase T, Hasegawa Y, Iwasada S, *et al*. Total hip arthroplasty after failed intertrochanteric valgus osteotomy for advanced osteoarthritis. *Clin Orthop* 1999;364:175–81.
- 17 Mortazavi SM, Restrepo C, Kim PJ, *et al*. Cementless femoral reconstruction in patients with proximal femoral deformity. *J Arthroplasty* 2011;26:354–9.

Copyright 2014 BMJ Publishing Group. All rights reserved. For permission to reuse any of this content visit <http://group.bmj.com/group/rights-licensing/permissions>.
BMJ Case Report Fellows may re-use this article for personal use and teaching without any further permission.

Become a Fellow of BMJ Case Reports today and you can:

- ▶ Submit as many cases as you like
- ▶ Enjoy fast sympathetic peer review and rapid publication of accepted articles
- ▶ Access all the published articles
- ▶ Re-use any of the published material for personal use and teaching without further permission

For information on Institutional Fellowships contact consortiasales@bmjgroup.com

Visit casereports.bmj.com for more articles like this and to become a Fellow