CASE REPORT JSLS

Pregnant Noncommunicating Rudimentary Uterine Horn with Placenta Percreta

Emmanuelle Henriet, MD, Horace Roman, MD, Joel Zanati, MD, Bernard Lebreton, MD, Jean-Christophe Sabourin, MD, PhD, Marpeau Loic, MD, PhD

ABSTRACT

Background: To report a placenta percreta in a 7-week gestational rudimentary noncommunicating uterine horn pregnancy.

Methods: A 28-year-old woman with no complaints presented with a rudimentary uterine horn pregnancy at 7-weeks gestation. The diagnosis was suspected by ultrasonography and diagnosed by laparoscopy. Laparoscopic excision of the rudimentary uterine horn and ipsilateral salpingectomy were performed, as well as biopsy of several peritoneal endometriosis lesions.

Results: A 7-week gestation pregnancy with placenta percreta was identified in the rudimentary uterine horn. No communication was found with the right unicornuate uterus. Endometriosis was confirmed. Clinical outcome was favorable.

Conclusion: Placenta percreta may occur in rudimentary uterine horn pregnancies, but accidents may be avoided by an early diagnosis and surgical management. However, in young women who desire pregnancy, planned laparoscopic resection of a rudimentary uterine horn revealed accidentally should be discussed.

Key Words: Rudimentary uterine horn, Pregnancy, Placenta percreta, Placenta accreta, Endometriosis, Laparoscopy, Ultrasonography.

Department of Gynecology and Obstetrics, University Hospital Rouen, France (Drs Henriet, Roman, Zanati, Lebreton, Loic).

Department of Pathology, University Hospital Rouen, France (Dr Sabourin).

Address reprint requests to: Horace Roman, MD, Department of Obstetrics and Gynecology, University Hospital Rouen, 1 rue de Germont, 76031 Rouen, France. Telephone: 33 232 888 745, Fax: 33 235 981 149, E-mail: horace.roman@gmail.com

INTRODUCTION

Pregnancy in a rudimentary noncommunicating uterine horn has already been described in the literature.[1–8] Only 9 cases have been reported of a placenta accreta in a pregnant rudimentary uterine horn, but this situation led to hemorrhagic rupture of the uterus in 8 women.[1,3] In the literature, pregnant rudimentary uterus ruptures, with or without placenta accreta, tend to occur during the second or third trimester of pregnancy, and in most cases the consequent hemorrhage threatens women's lives.[1,3–5,7] However, early diagnosis may be possible and would allow the resection of the rudimentary uterine horn with scarce maternal morbidity.[6] We report the case of a rudimentary uterine horn pregnancy with a placenta percreta revealed and managed laparoscopically at 7-weeks gestation, with favorable outcomes, and we argue for the laparoscopic removal of rudimentary uterine horns when they are revealed in young women who desire further pregnancies.

CASE REPORT

A 28-year-old, healthy, nulliparous woman underwent a routine pelvic ultrasound examination at 7-weeks gestation. As regards her antecedents, she had a right ectopic fallopian pregnancy 4 months previously that had been treated laparoscopically at another establishment. She was not aware of any particular findings during this surgical procedure that led to the removal of the ectopic pregnancy by a right salpingotomy.

The ultrasound examination revealed an image, suggesting a left ectopic pregnancy measuring 3cm with Doppler embryo heart activity. However, a pseudo-pattern of asymmetrical bicornuate uterus was noted as well as a gestational sac surrounded by myometrial tissue and completely separated from the uterine cervix. No communication with the contralateral uterine cavity could be found. These arguments suggested a rudimentary noncommunicating horn pregnancy. The β-human chorionic gonadotropin titer was 10,091 μUI/mL. Even though the woman was free of pain, a surgical procedure was proposed because of the expected risk of rudimentary uterus rupture.

The laparoscopy was carried out using one umbilical ancillary 12-mm trocar and 3 ancillary 5-mm trocars placed downward. The peritoneal cavity was free of any blood or liquid collection. A right unicornuate uterus with a seemingly normal right fallopian tube and a left pregnant rudimentary uterus with a normal fallopian tube were present **(Figure 1)**. The 2 uteri were linked by a fibrous, less congestive flap. The pelvic peritoneum had several disseminated, red, congestive, nodular lesions that appeared to be endometriotic implants. No apparent signs of uterine rupture were revealed. A left hysterectomy with left salpingectomy using a classical procedure (bipolar coagulation and section by scissors of the mesosalpinx, fibrous flap and board ligament) was carried out. The procedure took 45 minutes, and no incidents were encountered. Biopsies were performed on 2 endometriotic lesions, the other being coagulated. Postoperative outcomes were favorable, and the woman was discharged 3 days later. Abdominal ultrasound examination showed that both kidneys were present.

Histopathologic examination revealed a rudimentary left horn uterus with a 2-cm pregnancy of 7-week's gestation. There was no communication with the right unicornuate uterine cavity. The chorioamniotic sac contained the embryo and the placenta infiltrating through the primitive müllerian myometrium. The placental infiltration had completely pierced the myometrium thickness and was found exteriorized on the anterior uterine side. This finding corresponded to a placenta percreta **(Figure 2)**.

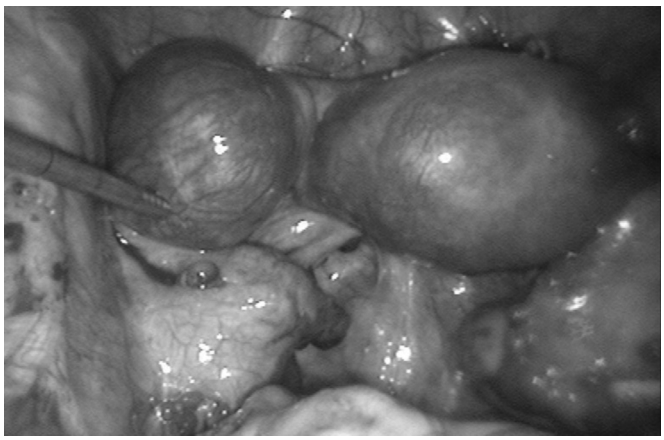

Figure 1. Left pregnant rudimentary uterine horn with a normal fallopian tube, linked by a fibrous flap to the right unicornuate uterus. The pelvic peritoneum has several disseminated, red, congestive, nodular endometriotic lesions.

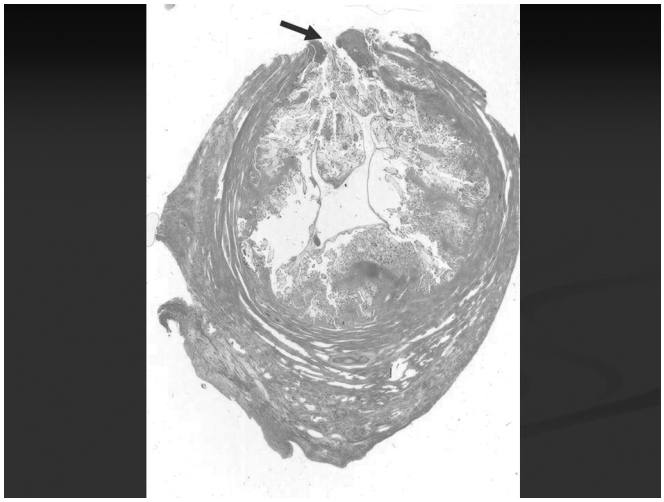

Figure 2. Placenta percreta in the rudimentary uterine horn (the arrow shows the complete piercing of the uterine myometrium thickness).

DISCUSSION

This case report is peculiar not only because of the rarity of the pathology, but also due to the onset of circumstances and early management of the pregnancy, avoiding any hemorrhagic incident. To our knowledge, in the literature, few cases have been reported of pregnant rudimentary uterine horn where pregnancy had not led to a symptomatic uterine rupture.[1,2,6] In 2 similar cases, the pregnant rudimentary uterine horn diagnosis was carried out early by MRI examination.[6] Despite the high accuracy of MRI, we considered that it was not necessary in this case because of both the strong ultrasound presumption of pregnant rudimentary uterus and the decision to carry out a laparoscopic procedure anyway. Otherwise, we agree that MRI is useful in preoperative assessment when the ultrasonography is not able to affirm a rudimentary uterine horn pregnancy and to rule out an ectopic pregnancy.

Early diagnosis allows safe laparoscopic removal of the pregnant rudimentary uterus with rapid favorable outcomes. In the literature, the laparoscopic procedure often had not been done in circumstances of severe hemoperitoneum due to uterine rupture with major threats to the woman's life.[2–5,7] Even though in the literature uterine rupture is reported to mainly occur during the second trimester of pregnancy, we consider that no safe bet can be made on the pregnant rudimentary uterine horn capacity to relax during the first trimester. Subsequently, we consider that a prompt surgical procedure ought to be resorted to without delay.

Peritoneal endometriosis is often associated with obstructive malformations of the genital tract,[9] and this finding is an argument in favor of the pathogenic menstrual blood reflux theory of endometriosis. It is worth noting that despite the extended peritoneal area involved in active endometriosis and the antecedent of right salpingotomy, pregnancy could occur in the left rudimentary uterine horn. It appears that 2 mechanisms may be involved in the occurrence of this pregnancy.[4,8] The first supposes that spermatozoons go up to the peritoneum by the right permeable fallopian tube, transmigrate intraperitoneally and fecundate the ovule that had been released either by the left or right ovary. Nahum et al[8] showed that intraperitoneal sperm and ovum transmigration appears to occur respectively in 50% and 40% of all cases of human pregnancy. However, several authors[10] suggest that peritoneal endometriosis would be harmful to spermatozoic mobility and survival. An alternative hypothesis is that fertilization might have occurred within the peritoneal cavity with subsequent intraperitoneal transmigration of the resulting fertilized ovum and contralateral tubal pick up.[8] Whatever the mechanism, the onset of pregnancy despite these unfavorable circumstances may be considered worthy of speculation.

The placenta accreta is seemingly frequently found in rudimentary uterine horn pregnancies. On the strength of cases previously reported in the literature, Oral et al[3] estimated that the prevalence of placenta accreta in rudimentary uterine horn pregnancies may be greater than 10%. The hemorrhagic risk due to placenta accreta and that of spontaneous uterine rupture due to the thinness of the myometrium represent in our opinion 2 sufficient arguments to recommend the immediate surgical removal of a pregnant rudimentary uterine horn as soon as its diagnosis is carried out. This attitude allows a safe laparoscopic procedure with rapid favorable outcomes and avoids hemorrhagic injuries requiring emergency surgical procedures by laparotomy.

On the basis of the high rate of spontaneous sperm transmigration across the peritoneal cavity, Nahum et al[8] had recently suggested that salpingectomy should be preferable to the salpingotomy in women with ectopic pregnancy and unilaterally damaged fallopian tube to avoid recurrences. Similarly, on the basis of the major risk related to the pregnancies located in a rudimentary uterine horn, we ought to go forward and suggest laparoscopic removal of rudimentary uterine horns when they are revealed in young women with a desire for further pregnancies. In our opinion, the option of a planned laparoscopic procedure is always less morbid than whatever surgical procedure is carried out in pregnancy circumstances.

References:

1. Heinonen PK. Clinical implications of the unicornuate uterus with rudimentary horn. *Int J Gynaecol Obstet.* 1983;21(2):145–150.

2. Chou MM, Ho ES, Lin SK, et al. Term pregnancy in a noncommunicating rudimentary horn of an unicornuate uterus: a case report. *Zhonghua Yi Xue Za Zhi (Taipei).* 1999;62(6):383–387.

3. Oral B, Guney M, Ozsoy M, Sonal S. Placenta accreta associated with a ruptured pregnant rudimentary uterine horn. Case report and review of the literature. *Arch Gynecol Obstet.* 2001; 265(2):100–102.

4. Daskalakis G, Pilalis A, Lykeridou K, Antsaklis A. Rupture of noncommunicating rudimentary uterine horn pregnancy. *Obstet Gynecol.* 100(5 Pt 2):1108–1110, 2002.

5. Nishi H, Funayama H, Fukumine N, et al. Rupture of pregnant noncommunicating rudimentary uterine horn with fetal salvage: a case report. *Arch Gynecol Obstet.* 2003;268(3):224–226.

6. Tsafrir A, Rojansky N, Sela HY, Gomori JM, Nadjari M. Rudimentary horn pregnancy: first-trimester prerupture sonographic diagnosis and confirmation by magnetic resonance imaging. *J Ultrasound Med.* 2005;24(2):219–223.

7. Jerbi M, Trimech A, Choukou A, et al. [Rupture of rudimentary horn pregnancy at the 18th week of gestation: a case report]. *Gynecol Obstet Fertil.* 33(7–8):505–507, 2005.

8. Nahum GG, Stanislaw H, McMahon C. Preventing ectopic pregnancies: how often does transperitoneal transmigration of sperm occur in effecting human pregnancy? *BJOG.* 2004;111(7): 706–714.

9. Ugur M, Turan C, Mungan T, et al. Endometriosis in association with müllerian anomalies. *Gynecol Obstet Invest.* 1995; 40(4):261–264.

10. Oral E, Arici A, Olive DL, Huszar G. Peritoneal fluid from women with moderate or severe endometriosis inhibits sperm motility: the role of seminal fluid components. *Fertil Steril.* 1996; 66(5):787–792.