

## Ovarian dermoid cysts: ultrasonographic findings

Călin Moș<sup>1</sup>

<sup>1</sup>University of Oradea, Faculty of Medicine and Pharmacy, Romania

### Abstract

Dermoid cysts or mature cystic teratoma present various and complex ultrasonographic aspects. That is why the ultrasonographic diagnosis may be difficult and lead to confusion. Yet, a thorough analysis of all ultrasound features that characterize dermoid cysts can lead in the vast majority of the cases to an exact diagnosis. The purpose of this paper is to present the ultrasonographic findings of the dermoid cysts.

**Key words:** ovarian dermoid cyst, mature cystic teratoma, ultrasonography

### Rezumat

Chistele dermoide sau teratoamele chistice mature au de cele mai multe ori un aspect ecografic foarte variat și complex. Din această cauză în diagnosticul ultrasonografic pot să apară dificultăți și confuzii. Totuși o analiză atentă a tuturor aspectelor ecografice care caracterizează chistele dermoide poate să ducă în marea majoritate a cazurilor la un diagnostic exact. Scopul acestui pictorial este de a prezenta modificările ecografice care caracterizează chistele dermoide.

**Cuvinte cheie:** chist dermoid ovarian, teratom chistic matur, ecografie

Ovarian germinal tumors have various histological origins. They classify into: dermoid cyst, monodermal teratoma, struma ovarii and immature teratoma. Out of all these the dermoid cyst or the mature cystic teratoma represents the most frequently encountered, the most often operated and the most known ovarian neoplasm [1,2].

Dermoid cysts originate in the pluripotent germ cells [3]. They form from a single germ cell after the first meiotic division [4]. Dermoid cysts are composed of well-differentiated tissues of at least two of the three types of germinal cells (ectoderm, mesoderm and endoderm). They always contain mature ectodermal tissues (skin, brain), in over 90% of cases they contain mesodermal tissues (muscles, fat, bone, cartilage), and in most cases they also contain endodermal tissues (ciliated, gastrointestinal mucinous or bronchial epithelium, thyroidian tissue) [3,5,6].

On the surface dermoid cysts are covered by compressed ovarian stroma, usually hyalinized. The cyst wall is made of squamous epithelium. In this epithelium hair

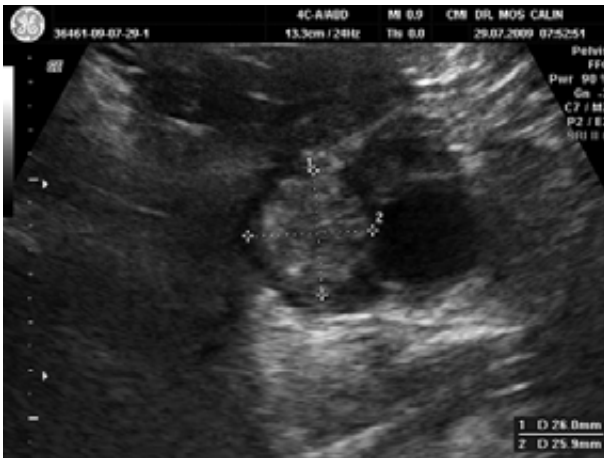follicles, sweat glands, muscles and other tissues can be found [7,8]. Inside the cyst there could be identified fat, sebaceous secretions, hair follicles, hair, and in about 30% of cases organ-like structures (teeth, bone fragments) [9].

The size of a dermoid cysts may be extremely variable. They can be found accidentally when they measure just around 1 cm and are situated inside the ovary without causing ovarian distortion (fig 1) [10]. But they can also have gigantic dimensions of up to 30-40 cm (fig 2). Usually, when they are discovered, dermoid cysts measure under 10 cm. Often times they are asymptomatic and have a slow growth rate of 1,8 mm/year. That is why some authors recommend a non-surgical management if size is not over 6 cm [11].

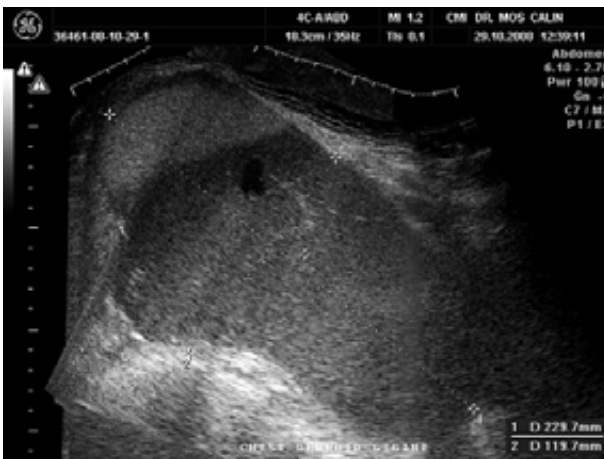
In approximately 80% of the cases dermoid cysts occur in young patients between 20 and 30 years of age [12]. Ovarian dermoid cysts are also the most frequently encountered ovarian neoplasms in children [13]. They represent about 18-20% of all benign ovarian tumours. The tumours are usually unilateral, but in 10-15 % of the situations they can be bilateral (fig 3) [5,6].

Due to the fact that they are often pediculate and because of their rich content in fat, dermoid cysts are frequently situated superior to the uterine fundus [14,15].

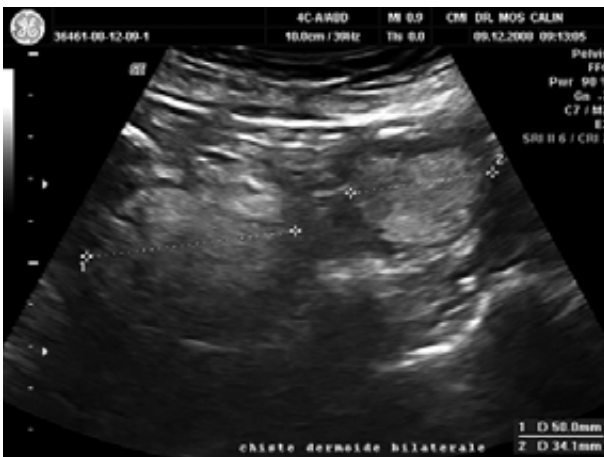Address for correspondence: Dr. Călin Moș  
Str. Andrei Șaguna nr.1  
Beiuș, jud. Bihor, România  
e-mail: drcalinmos@yahoo.com



**Fig 1.** Hyperechoic, small ovarian dermoid cyst. Near the dermoid cyst there is an ovarian follicle present.



**Fig 2.** Panoramic view of an over 20 cm gigantic dermoid cyst.

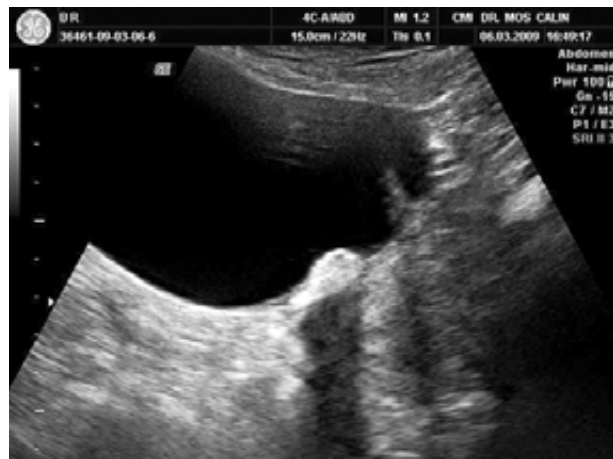

**Fig 3.** Bilateral dermoid cysts.

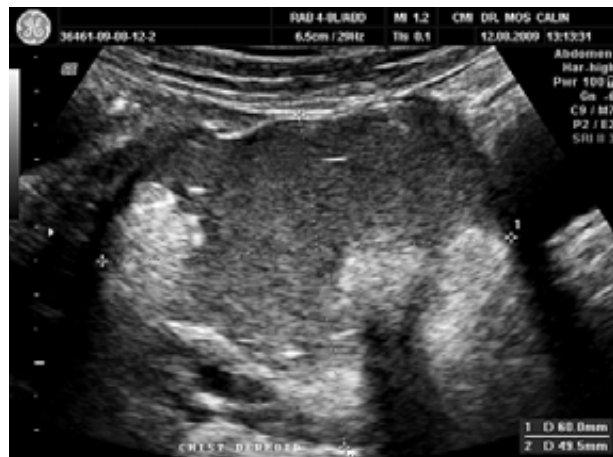The most typical ultrasonographic aspects of dermoid cysts are:

1. **The dermoid plug (Rokitanski nodule)** is probably the most characteristic aspect of the dermoid cysts [16]. It consists of nodular, pediculate, dense, parietal structure that forms on the cyst's interior surface and which bulges inside it [5]. A dermoid cyst may contain one or more Rokitanski nodules. The dermoid plug may contain bones, teeth, but also hair that can extend into the cyst's cavity. The ultrasound appearance is that of an hyperechoic nodular structure, usually with distal acoustic shadow, situated near the cyst wall (fig 4-9) [5,14,17,18].

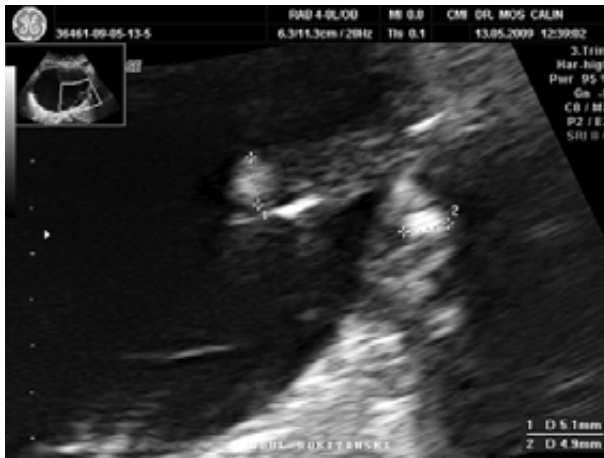The shadowing may be caused by a calcification or by a sebum and hair conglomerate [5,17,18]. After puberty both Rokitanski nodule and the acoustic shadow appear in over 70% of the cases. Before puberty the echoic nodule appears in about 40% of cases and the acoustic shadow



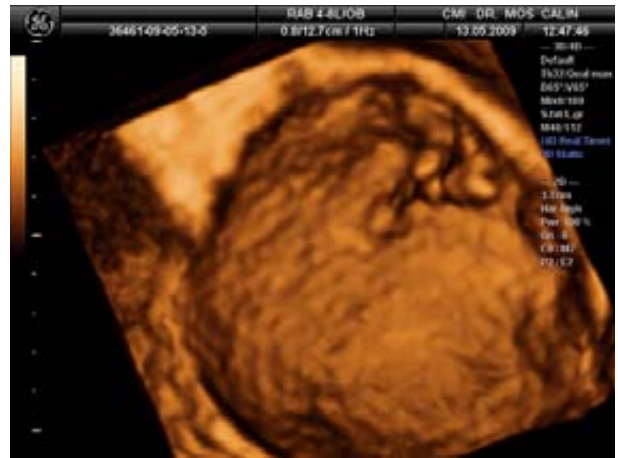
**Fig 4.** Calcified parietal nodule with acoustic shadowing determined by the Rokitanski nodule (dermoid plug) inside a transonic dermoid cyst.



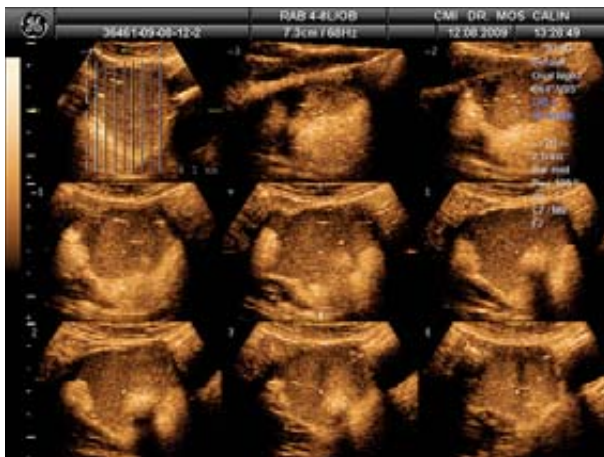**Fig 5.** Rokitanski nodule inside a complex dermoid cyst.



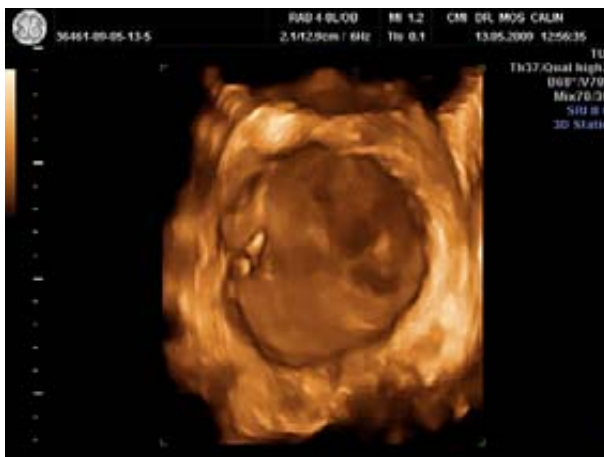
**Fig 6.** Delicate calcifications in a dermoid plug with fine, echoic lines emerging from it (dermoid mesh).



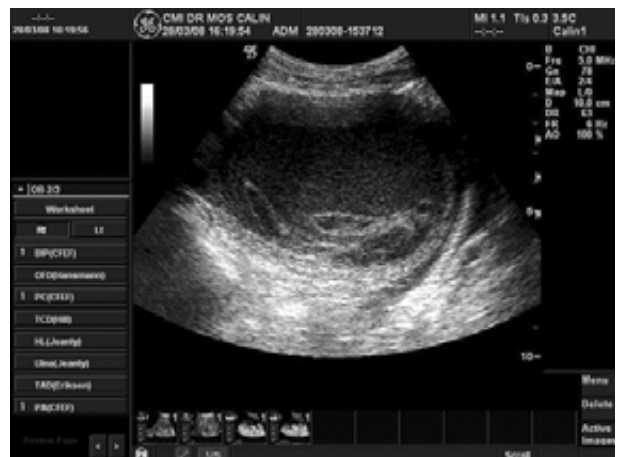**Fig 9.** Several dense irregularities in the dermoid plug demonstrated on a 4D ultrasound image of a mature cystic teratoma.



**Fig 7.** Several ultrasonographic sections through a dermoid cyst, demonstrating its polymorphic structure.



**Fig 8.** A 4D ultrasonographic image with clear visualisation of a tooth inside the dermoid plug.



**Fig 10.** Fine, long echoic lines in a dermoid cyst.

ow in only 15 % of the dermoid cysts [14]. The dermoid plug may be found as a single manifestation of a dermoid cyst in 16% of the situations [18].

(2.) The **dermoid mesh** corresponds to the presence of hair inside the cyst. The ultrasonographic appearance may be that of long, echoic lines or that of point-like echoic images inside the lesion depending on the view (fig 10-13) [5,16,17,18].

The fibrin threads inside of hemorrhagic cysts could mimic this aspect. But only in 1% of the cases this finding appears isolated, without being accompanied by other signs characteristic to dermoid cysts [18].

(3.) “**Tip of the iceberg**” sign – in some cases only the contour of the cyst may be seen because of the distal acoustic shadow. In these circumstances an accurate measurement of the cyst is difficult or impossible to determine (fig 14,15).



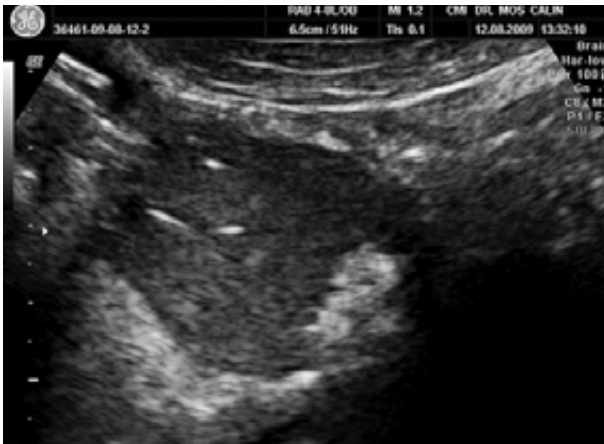


Fig 11. Hyperechoic lines produced by presence of hair.

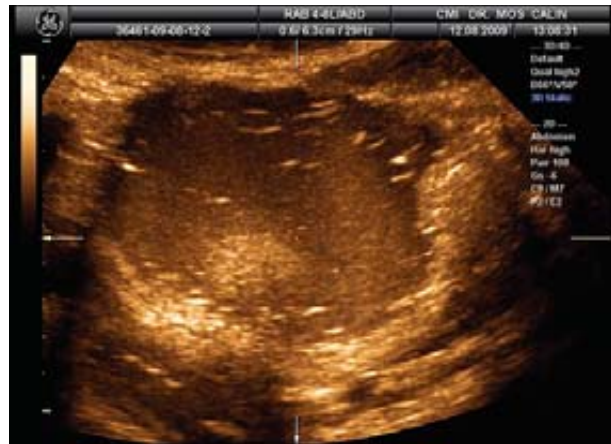

Fig 13. Dermoid mesh

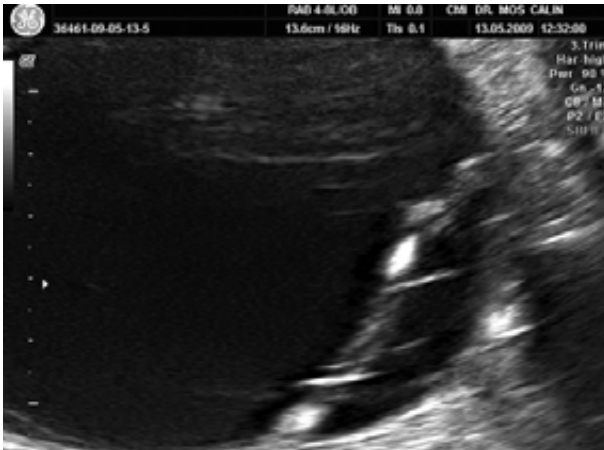

Fig 12. A dermoid mesh with fine, barely visible lines emerging from the Rokitanski nodule.

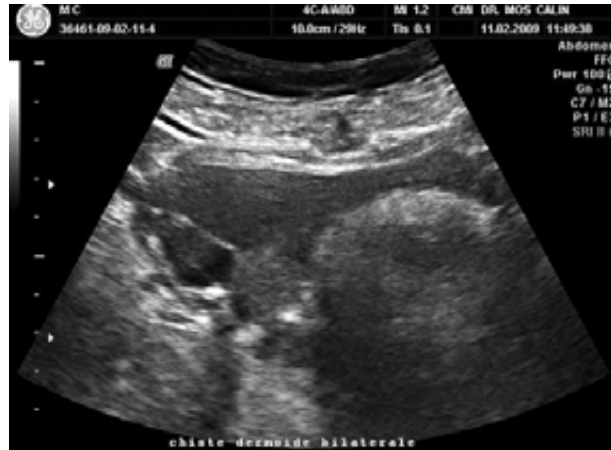

Fig 14. The „tip of the iceberg” sign: the anterior wall of the lesion is well visible, but inside the dermoid cyst there is significant acoustic shadowing that makes the posterior wall of the cyst impossible to visualize.

In 16% of cases this sign is the only ultrasonographic manifestation of a dermoid cyst [18]. The acoustic shadowing given by the hyperechogenicity of the structures inside the cyst may be diffuse if it involves the whole cyst or it may be limited to a part of the cyst. Only 8% of dermoid cysts contain hyperechoic structures without distal acoustic shadow [14].

There are three types of tissues that can produce acoustic shadowing: calcified structures (bones, teeth), hair conglomerates inside the cyst cavity and the fat within the Rokitanski nodule [17].

(4.) Sometimes a tendency towards **sedimentation** occurs within the serous components of the dermoid cyst and the sebum, producing an ultrasound visible interface that changes position with gravity (fig 16,17) [16,15]. A fluid-fluid level within an adnexal mass does not have diagnostic value for a dermoid cyst. This finding must be interpreted within the context of other associated criteria [18].

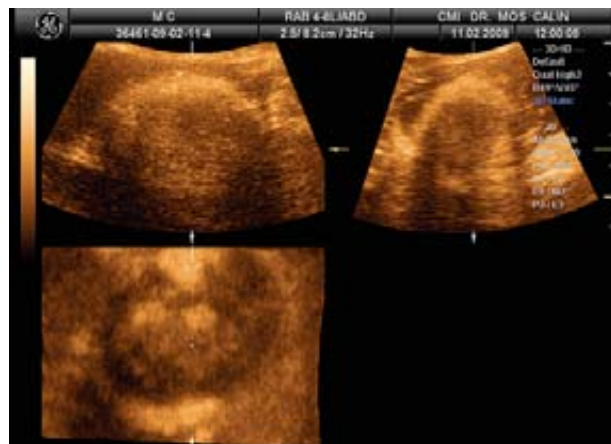

Fig 15. A 3D image in three orthogonal planes. In case of very dense cysts the „tip of the iceberg” sign is noticed when the cyst is visualized in planes A and B, while a plane C reconstruction offers a better view of the external contour of the cyst.

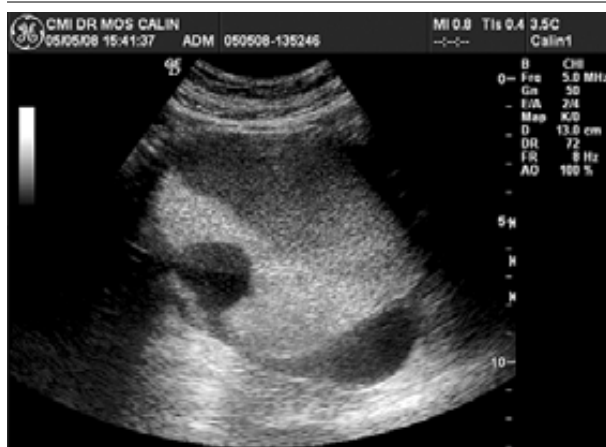

Fig 16. Fluid-fluid levels inside dermoid cysts (2D images).

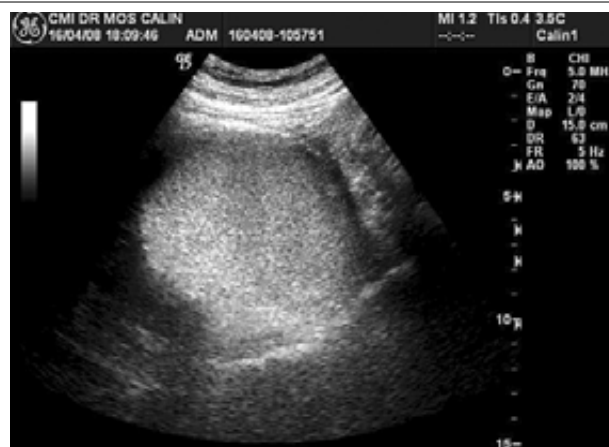

Fig 18. The echoic „white ball” aspect, filling almost the whole cystic cavity.

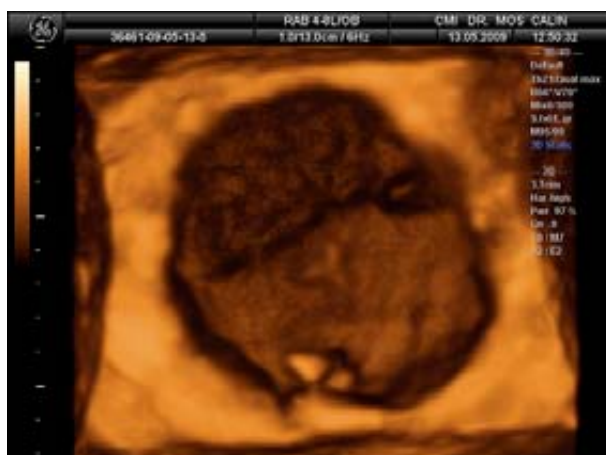

Fig 17. Fluid-fluid levels inside dermoid cysts (3D images).

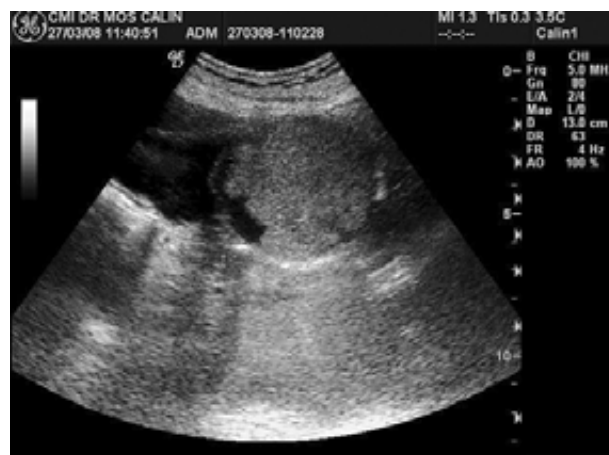

Fig 19. Relatively homogeneous, echoic mass, but with polycyclic contour, filling an important part of the cyst’s cavity.

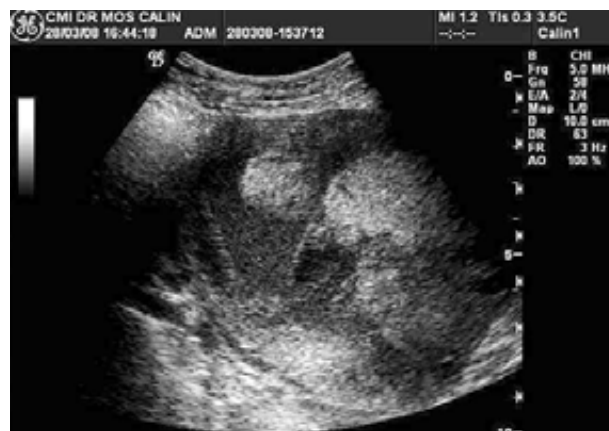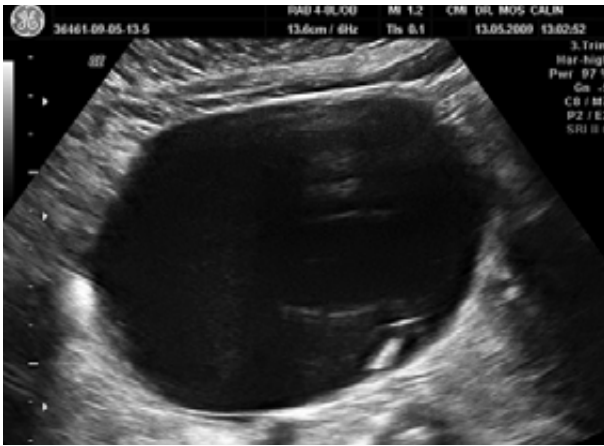


Fig 20. Adipose material spheres floating within the cyst.

(5.) The echoic “white ball” aspect may occupy sometimes the entire cystic cavity (fig 18). The histopathologic exam of the entirely echoic dermoid cysts shows a content containing mainly hair, fat and sebaceous material [7,19]. Other times an echoic, relatively homogenous and lobulated mass that fills a part of the cyst cavity is visualised (fig 19). Not so often within the dermoid cyst may be seen echoic spheres produced by fat material conglomerates that float inside the cyst. They do not present acoustic shadow or a tendency towards sedimentation (fig 20) [20,21].

Since 1998 Patel *et al.* described the following ultrasonographic features as being specific for dermoid cysts: a) the presence of an echogenicity with acoustic shadow, b) diffuse or regional shining echoes, c) hyperechoic lines and dots, and d) the presence of a fluid-fluid level. He demonstrated that about ¾ of the dermoid cysts show at least two of the above characteristics, while no other adnexal mass presents more than one of these features. So, the presence of two characteristics indicates a posi-

tive predictive value of 100% [18]. Mais *et al.* consider that mature cystic teratomas may be diagnosed through endovaginal ultrasonography with a 99% specificity and only a 50% sensitivity [22].



**Fig 21.** An almost completely transonic dermoid cyst. There is only one small echogenic image near the cyst's wall, but without acoustic shadow.

About 2/3 of dermoid cysts are usually easy to recognise on ultrasound because of the polymorph aspect of complex masses that consist of both hyperechoic and hypoechoic components [14]. Most teratomas (about 65%) contain extremely intense echogenicity. No other tumour has this feature [23]. Around 10-15% of the cystic mature teratomas are entirely echoic, but without intense hyperechoic structures [24].

Another 10-15 % of the dermoid cysts are anechoic or show a predominantly cystic pattern and cannot be easily differentiated from other cystic masses (fig 21) [22]. Even transonic lesions contain parietal nodules on the histopathological analysis, but sometimes these nodules are too small (under 3-4 mm) to be detected ultrasonographically. Also even if the cyst has a mixed content the absence of a significant interface between sebum and fluid may represent the explanation of the purely transonic aspect [15].

### Bibliography:

- Koonings PP, Campbell K, Mishell DR Jr, Grimes DA. Relative frequency of primary ovarian neoplasms: a 10-year review. *Obstet Gynecol* 1989;74:921-926.
- Whitecar MP, Turner S, Higby MK. Adnexal masses in pregnancy: a review of 130 cases undergoing surgical management. *Am J Obstet Gynecol* 1999;181:19-24.
- Bazot M, Cortez A, Sananes S, Boudghène F, Uzan S, Bigot JM. Imaging of dermoid cysts with foci of immature tissue. *J Comput Assist Tomogr* 1999;23:703-706.
- Linder D, McCaw BK, Hecht F. Parthenogenic origin of benign ovarian teratomas. *N Engl J Med* 1975;292:63-66.
- Outwater EK, Siegelman ES, Hunt JL. Ovarian teratomas: tumor types and imaging characteristics. *Radiographics* 2001;21:475-490.
- Caruso PA, Marsh MR, Minkowitz S, Karten G. An intense clinicopathologic study of 305 teratomas of the ovary. *Cancer* 1971;27:343-348.
- Blackwell WJ, Dockerty MB, Mason JC, Mussey RD. Dermoid cysts of the ovary: their clinical and pathological significance. *Am J Obstet Gynecol* 1946;51:151-172.
- Talerman A. Germ cell tumors of the ovary. In: Kurman RJ (ed) *Blaustein's pathology of the female genital tract*. 4th ed. New York, Springer-Verlag, 1994:849-914.
- Matz MH. Benign cystic teratomas of the ovary. *Obstet Gynecol Surv* 1961;16:591-605.
- Valentin L, Callen PW. Ultrasound evaluation of the adnexa (ovary and fallopian tube). In: Callen PW (ed) *Ultrasonography in obstetrics and gynecology*. Saunders-Elsevier, 5th edition 2008:968-985.
- Caspi B, Appelman Z, Rabinerson D, Zalel Y, Tulandi T, Shoham Z. The growth pattern of ovarian dermoid cysts: a prospective study in premenopausal and postmenopausal women. *Fertil Steril* 1997; 68:501-505.
- Comerci JT Jr, Licciardi F, Bergh PA, et al. Mature cystic teratoma: a clinicopathologic evaluation of 517 cases and review of the literature. *Obstet Gynecol* 1994;84:22-28.
- Brown MF, Hebra A, McGeehin K, Ross AJ III. Ovarian masses in children: a review of 91 cases of malignant and benign masses. *J Pediatr Surg* 1993;28:930-933.
- Sisler CL, Siegel MJ. Ovarian teratomas: a comparison of the sonographic appearance in prepubertal and postpubertal girls. *AJR Am J Roentgenol* 1990;154:139-141.
- Fleischer AC, Entman SS. Sonography evaluation of pelvic masses with transabdominal and/or transvaginal sonography. In: Fleischer AC, Manning FA, Jeanty P, Romero R (eds) *Sonography in obstetrics and gynecology. Principles and practice*. McGraw-Hill, 6th edition 2001:883-911.
- Sheth S, Fishman EK, Buck JL, Hamper UM, Sanders RC. The variable sonographic appearances of ovarian teratomas: correlation with CT. *AJR* 1988;151:331-334.
- Quinn SF, Erickson S, Black WC. Cystic ovarian teratomas: the sonographic appearance of the dermoid plug. *Radiology* 1985;155: 477-478.
- Patel MD, Feldstein VA, Lipson SD, Chen DC, Filly RA. Cystic teratomas of the ovary: diagnostic value of sonography. *AJR Am J Roentgenol* 1998;171: 1061-1065.
- Surratt JT, Siegel MJ. Imaging of pediatric ovarian masses. *Radiographics* 1991;11:533-548.
- Muramatsu Y, Moriyama N, Takayasu K, Nawano S, Yamada T. CT and MR imaging of cystic ovarian teratoma with intracystic fat balls. *J Comput Assist Tomogr* 1991;15:528-529.
- Kawamoto S, Sato K, Matsumoto H, et al. Multiple mobile spherules in mature cystic teratoma of the ovary. *AJR* 2001;176:1455-1457.
- Mais V, Guerriero S, Ajossa S, et al. Transvaginal sonography in the diagnosis of cystic teratoma. *Obstet Gynecol* 1995;85:48-52.
- Moyle JW, Rochester D, Sider L, Shrock K, Krause P. Sonography of ovarian tumors: predictability of tumor type. *AJR* 1983;141:985-991.
- Surratt JT, Siegel MJ. Imaging of pediatric ovarian masses. *Radiographics* 1991;11:533-548.