Neurol Med Chir (Tokyo) 43, 369～373, 2003

Traumatic Carotid-Cavernous Fistula Identified by Three-dimensional Digital Subtraction Angiography

—Technical Note—

Fujimaro ISHIDA, Tadashi KOJIMA, Kenji KAWAGUCHI*, Tamotsu HOSHINO*, Kenichi MURAO**, and Waro TAKI*

Department of Neurosurgery, Mie Prefectural General Medical Center, Yokkaichi, Mie;
**Department of Neurosurgery, Mie University School of Medicine, Tsu, Mie;*
***Department of Neurosurgery, National Cardiovascular Center, Suita, Osaka*

Abstract

Conventional digital subtraction angiography (DSA) identified a right carotid-cavernous fistula (CCF). Three-dimensional DSA (3D-DSA) was used to evaluate the CCF before treatment. The 3D-DSA images showed the anatomical relationship of the parent artery and the veins, which was difficult to understand on conventional DSA. The endoscopic image revealed the fistula and cavernous sinus. The direction and location of the fistula could be confirmed. However, the size of the fistula significantly varied depending on the adjustment of the window thresholds, so the balloon size could not be selected based on the images. Catheterization and subsequent embolization of the cavernous sinus with a detachable balloon via the femoral artery was successfully accomplished by referring to the 3D-DSA images.

Key words: carotid-cavernous fistula, three-dimensional digital subtraction angiography, endoscopic imaging

Introduction

Carotid-cavernous fistula (CCF) most commonly occurs on the horizontal and posterior ascending intracavernous segments of the internal carotid artery (ICA).[5] Many methods have been used to confirm the location of the fistula. Vertebral angiography with compression of the carotid artery in the neck is useful in the presence of collateral circulation through the posterior communicating artery. If the posterior communicating artery is too small, the fistula can be identified by using a double lumen catheter to inflate a proximal balloon in the cervical ICA, and passing contrast material through the other lumen.[2,3]

Digital subtraction angiography (DSA) is currently the standard for the diagnosis of direct CCF. Recent developments in noninvasive techniques, such as spiral computed tomography (CT) and magnetic resonance (MR) angiography now allow the simple and safe diagnosis of CCF. Spiral CT angiography is useful for evaluating the presence of a CCF in a suggestive clinical context, but cannot depict the topography of the shunt in CCF because of the lower spatial resolution.[4] MR angiography is useful for demonstrating the abnormal flow of CCF.[7,11] However, these noninvasive techniques cannot provide any information about the fistula. This report describes the usefulness of three-dimensional DSA (3D-DSA) for the endovascular treatment of CCF in comparison to conventional DSA.

Received September 6, 2002; Accepted March 3, 2003

Neuroimaging Technique

A 56-year-old man was admitted to our hospital with diplopia and exophthalmos on the right one month after suffering head trauma in a motor vehicle accident. Neurological examination on admission revealed limitation of external rotation of eye movement, exophthalmos with mild chemosis on the right, and audible bruit over the eye. On admission to our hospital, conventional DSA demonstrated a CCF (Fig. 1). Right internal carotid angiography showed a high-flow CCF draining into the ipsilateral cavernous sinus, laterally into the sylvian veins, and

posteriorly into the inferior petrosal sinus.

Following conventional DSA, 3D-DSA was performed using an Advantx LCN Puls DSA unit (GE Medical Systems, Milwaukee, Wis., U.S.A.). Fast rotational spin angiography was performed with a 200-degree rotation of the C-arm in 5 seconds. The exposure was 8.8 frames per second and each frame had 512 × 512 pixels. After obtaining 44 mask images, 20 ml of contrast material was injected into the right cervical ICA via a selected positioned catheter. 3D surface rendering images and endoscopic images were made using an Advantage 3.1 workstation (GE Medical Systems). The 3D surface rendering images depicted the draining veins of the CCF very clearly, including the cavernous sinus, sylvian veins, and inferior petrosal sinus (Fig. 2). The endoscopic images provided the precise endoluminal orientation of the fistula (Fig. 3). The workstation could show viewing points on the 3D surface rendering image and the virtual endoscopic image simultaneously (Fig. 4). Using this function, each small opening in the cavernous sinus could be detected. The direction and location of the fistula were fully confirmed, but since the size of the fistula significantly varied depending on the adjustment of the window thresholds, the precise balloon size could not be selected based on the endoscopic images.

The CCF was occluded using a detachable balloon via a transarterial route. The patient was heparinized to more than double the baseline activated clotting time. A gold-valve balloon (Nycomed, Paris, France) mounted on a red and black coaxial 2F/3F catheter system (Nycomed) was passed through a 9F Brite tip catheter (Cordis, Miami, Fla., U.S.A.) past

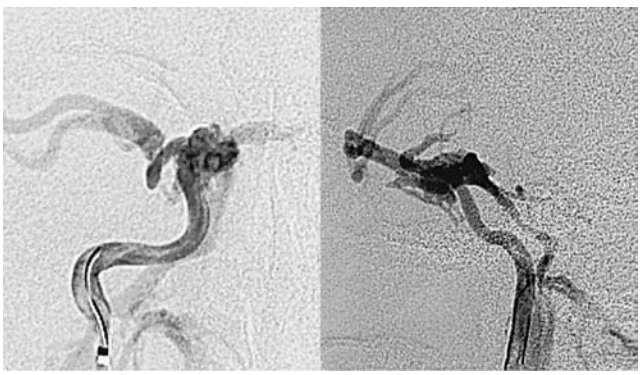

Fig. 1 Right carotid angiograms revealing a high-flow carotid-cavernous fistula, the cavernous sinus, and multiple venous drainage channels, including the sylvian veins, inferior petrosal sinus, and pterygoid plexus.

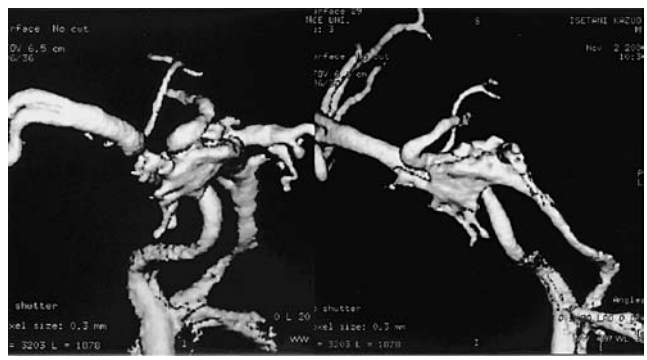

Fig. 2 Three-dimensional digital subtraction angiography surface rendering images demonstrating the three-dimensional anatomical relationship between the internal carotid artery and venous structures.

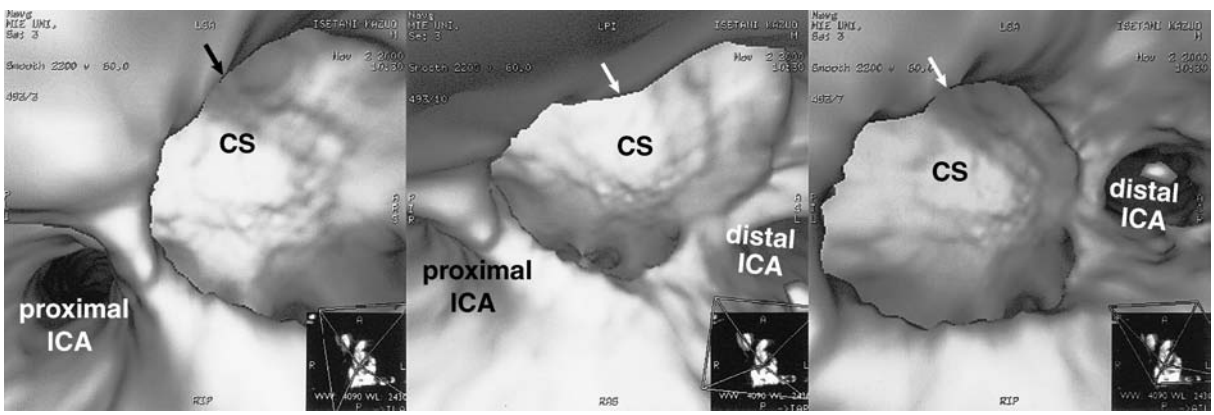

Fig. 3 Three-dimensional digital subtraction angiography virtual endoscopic images showing the fistula (*arrow*) appearing as the orifice of internal carotid artery (ICA) between the proximal and distal ICA, and the cavernous sinus (CS) observed through the fistula from inside the ICA.

Fig. 4 Simultaneous three-dimensional digital subtraction angiography surface rendering image and virtual endoscopic image showing the accurate endoluminal orientation and each direct opening in the cavernous sinus (CS), such as the sphenoparietal sinus and pterygoid plexus. The viewpoints are indicated by *arrows* on the workstation view.

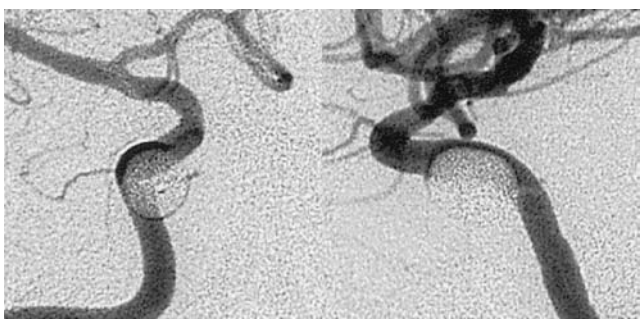

Fig. 5 Postoperative right carotid angiograms showing complete occlusion of the carotid-cavernous fistula and moderate compromise of the parent internal carotid artery.

the cervical ICA and into the fistula easily and safely by referring to the additional 3D-DSA images. Repeated balloon deflation and inflation were needed to achieve a satisfactory stable position for the balloon within the fistula. Using a second safety balloon,[9] the gold-valve balloon was detached in place, resulting in complete occlusion of the CCF and moderate compromise of the parent ICA (Fig. 5). The patient's symptoms resolved immediately within a few hours of the procedure.

Discussion

To achieve complete closure of the CCF with detachable balloons,[6,8,12] it is important to obtain detailed information about the fistula, including the location, the direction, and the size. MR angiography can demonstrate the abnormal venous flow of CCF, but misidentification of normal cavernous sinus or inferior petrosal sinus venous signals on 3D time-of-flight MR angiography is common.[11] 3D-CT angiography seems to be a reliable first-line diagnostic tool for evaluating the presence of a CCF, but cannot provide information about the blood-flow characteristics within the fistulas.[4] These techniques have limited usefulness to directly depict the features of the shunt in CCFs. 3D-DSA is valuable for the clinical assessment of intracranial aneurysm and arterial stenosis, but the usefulness for CCFs is not known.[1,10,13]

In this case, the traumatic CCF was evaluated by conventional DSA with the addition of images enhanced by 3D surface and endoscopic volume rendering using a workstation. The 3D virtual endoscopic images could depict the fistula directly. Referring to these endoscopic images, the anatomical orientation of the fistula was easily understood without requiring other techniques. 3D-DSA is superior to conventional DSA to identify the location and direction of the fistula. However, the size of the fistula could not be measured on the 3D-DSA images. The fistula may vary in size from 1 to 5 mm or more, with an average of 3 mm angiographically.[5] Since the window threshold level made accurate measurement from the 3D-DSA images impossible, the balloon size could not be selected based on the images. The additional information from the 3D-DSA images allowed the successful catheterization and subsequent embolization of the CCF with a detachable balloon via the femoral artery.

In conclusion, 3D-DSA provides more accurate information about the CCF than only conventional DSA. 3D-DSA is a useful imaging technique for understanding the relationship of the 3D anatomical vascular structures of the CCF.

References

1) Anxionnat R, Bracard S, Ducrocq X, Trousset Y, Launay L, Kerrien E, Braun M, Vaillant R, Scomazzoni F, Lebedinsky A, Picard L: Intracranial aneurysms: clinical value of 3D digital subtraction angiography in the therapeutic decision and endovascular treatment. *Radiology* 218: 799–808, 2001
2) Berenstein A, Kricheff II: Balloon catheters for investigating carotid cavernous fistulas. *Radiology* 132: 762–764, 1979
3) Cares HL, Roberson GH, Grand W, Hopkins LN: A safe technique for the precise localization of carotid-cavernous fistula during balloon obliteration. Technical note. *J Neurosurg* 49: 146–149, 1978
4) Coskun O, Hamon M, Catroux G, Gosme L,

Courtheoux P, Theron J: Carotid-cavernous fistulas: diagnosis with spiral CT angiography. *AJNR Am J Neuroradiol* 21: 712–716, 2000

5) Debrun G, Lacour P, Vinuela F, Fox A, Drake CG, Caron JP: Treatment of 54 traumatic carotid-cavernous fistulas. *J Neurosurg* 55: 678–692, 1981

6) Debrun GM, Vinuela F, Fox AJ, Davis KR, Ahn HS: Indications for treatment and classification of 132 carotid-cavernous fistulas. *Neurosurgery* 22: 285–289, 1988

7) Hirai T, Korogi Y, Hamatake S, Ikushima I, Sugahara T, Sigematsu Y, Higashida Y, Takahashi M: Three-dimensional FISP imaging in the evaluation of carotid cavernous fistula: comparison with contrast-enhanced CT and spin-echo MR. *AJNR Am J Neuroradiol* 19: 253–259, 1998

8) Lewis AI, Tomsick TA, Tew JM Jr: Management of 100 consecutive direct carotid-cavernous fistulas: results of treatment with detachable balloons. *Neurosurgery* 36: 239–244, 1995

9) Masaryk TJ, Perl J 2nd, Wallace RC, Magdinec M, Chyatte D: Detachable balloon embolization: concomitant use of a second safety balloon. *AJNR Am J Neuroradiol* 20: 1103–1106, 1999

10) Missler U, Hundt C, Wiesmann M, Mayer T, Bruckmann H: Three-dimensional reconstructed rotational digital subtraction angiography in planning treatment of intracranial aneurysms. *Eur Radiol* 10: 564–568, 2000

11) Ouanounou S, Tomsick TA, Heitsman C, Holland CK: Cavernous sinus and inferior petrosal sinus flow signal on three-dimensional time-of-flight MR angiography. *AJNR Am J Neuroradiol* 20: 1476–1481, 1999

12) Taki W, Handa H, Miyake H, Kobayashi A, Yonekawa Y, Yamamura K, Suzuki M, Ikada Y: New detachable balloon technique for traumatic carotid-cavernous sinus fistulae. *AJNR Am J Neuroradiol* 6: 961–964, 1985

13) Unno N, Mitsuoka H, Takei Y, Igarashi T, Uchiyama T, Yamamoto N, Saito T, Nakamura S: Virtual angioscopy using 3-dimensional rotational digital subtraction angiography for endovascular assessment. *J Endovasc Ther* 9: 529–534, 2002

Address reprint requests to: F. Ishida, M.D., Department of Neurosurgery, Mie Prefectural General Medical Center, 5450–132 Hinaga, Yokkaichi, Mie 510–8561, Japan.
e-mail: nsfuji@khaki.plala.or.jp

Commentary on this paper appears on the next page.

Commentary

The authors have demonstrated the elegance of three-dimensional rotational digital subtraction angiography in evaluating the angio-architecture of a traumatic carotid cavernous fistula. The advantages of three-dimensional rotational angiography have rapidly become apparent since this technique was introduced. We have found the technique to be particularly useful in the evaluation of intracranial aneurysms that are being considered for endovascular or surgical treatment. The precise anatomy of the neck of the aneurysm is essential in determining if endovascular therapy is a reasonable therapeutic option. By rotating the angiographic images, vascular lesions can be viewed from multiple angles, including a simulation of the proposed operative approach. Despite the demonstrated usefulness of three-dimensional rotational angiography in the evaluation of intracranial aneurysms, its use in the evaluation of traumatic carotid cavernous fistulas has not been well studied. The current report includes the elegant images that are useful in guiding endovascular therapy.

Daniel L. Barrow, M.D.
Department of Neurosurgery
The Emory Clinic
Atlanta, Georgia, U.S.A.

Ishida et al. have described their experience using three-dimensional digital subtraction angiography (3D-DSA) and virtual endoscopic (VE) imaging for identifying a traumatic carotid-cavernous fistula (CCF). They concluded that 3D-DSA could provide more information for understanding the anatomical vascular relationship of the CCF and 3D VE images could demonstrate the anatomical orientation of the fistula. Compared with other modalities including two-dimensional DSA, the clinical usefulness of 3D-DSA has been well known in intracranial aneurysms and occlusive vascular diseases. It is interesting that 3D-DSA and VE imaging were used in the clinical assessment of a traumatic CCF. It is expected with recent technological developments that 3D-DSA and VE imaging could be applied to various cerebrovascular diseases.

Dae Hee Han, M.D.
Department of Neurosurgery
College of Medicine
Seoul National University
Seoul, R.O.K.