

Some hematological changes in chickens infected with ectoparasites in Mosul

T. M. Al-Saffar and E. D. Al-Mawla

Department of Internal and Preventive Veterinary Medicine, College of Veterinary Medicine,
University of Mosul, Mosul, Iraq

(Received January 20, 2008; Accepted December 16, 2008)

Abstract

The study was conducted to identify different ectoparasites infesting 280 chicken (native breed out door house reared layers, 6 months – 2 years old), from various regions of Mosul city (poultry market, Hadba' Flock, and six flocks at Kogialli village), for one year. Total percentage of ectoparasites in chickens were 19.3 % of which (54 positive case out of 280 chicken) 81% were single infections and 19 % mixed infections. Lice infestation (12.5 %) and four types of chewing lice were classified (*Menacanthus stramineus*, *Cuclotogaster hetrographus*, *Goniocotus gallinae*, and *Columbicola columbae*). One species of flies (1.4%) (*Pseudolynchia canariensis*). One species of mites (4.3%) (*Dermanyssus gallinae*) were seen. One species of soft ticks (6.8%) (*Argas persicus*) were seen. Parasitological findings of skin and feathers examination for all types of ectoparasites on chicken showed three degrees of infestation depending on the number of these ectoparasites on each bird (low degree 1–50/ bird, moderate degree 51–100/ bird, and heavy degree more than 100/ bird). Clinical signs of the infected chicken with ectoparasites especially severe infection were itching, annoyance, loss of sleep, general weakness, loss of appetite, restless, allergy, drop of egg production in layers and anemia. It clear from results of blood examinations the presence of anemia in infected birds blood sucking ectoparasites with significant decrease in PCV % , TRBC and Hb concentration in chicken especially in severe (heavily) infestation with soft ticks and mites. Results also showed increase in total white blood cells (Leucocytosis) with increase in heterophils, and eosinophils in infected chicken with ticks, mites and lice, with bad nutrition and unhygienic management as compared with non-infected chicken control group.

Keywords: Chicken, Insects, Hematology

Available online at <http://www.vetmedmosul.org/ijvs>

بعض التغيرات الدموية في الدجاج المصاب بالطفيليات الخارجية في الموصل

طلال محمود الصفار، إيمان دحام المولى

فرع الطب الباطني والوقائي، كلية الطب البيطري، جامعة الموصل، الموصل، العراق

الخلاصة

تضمن هذا البحث الاستقصاء عن طبيعة وتشخيص الطفيليات الخارجية للدجاج ومدى تأثيراتها الدموية. وقد تم في هذه الدراسة فحص (٢٨٠) طيرا من الدجاج المحلي لغرض تشخيص وتصنيف الأنواع المختلفة من الطفيليات الخارجية التي تصيب الدجاج المحلي ذو التربية المنزلية في عدة مناطق وحقول في مدينة الموصل لمدة سنة. ان النسبة الكلية للاصابة بجميع انواع الطفيليات الخارجية (٥٤) حالة اصابة من مجموع (٢٨٠) من الدجاج وتمثل (١٩,٣%) وتشمل القمل العاض (١٢,٥%)، أربعة أجناس مختلفة، ونوع واحد من

الذباب (٤,١%)، نوع واحد من اللحم (٣,٤%)، حشرة الفاش الأحمر، ونوع واحد من القراد اللين (٨,٦%). أظهرت النتائج أن (٨١%) من الإصابات كانت مفردة بجنس أو نوع واحد من الطفيليات الخارجية و١٩% مختلطة الإصابة أي جنس أو أكثر من الطفيليات الخارجية على نفس الطير. أظهرت عينات الجلد والريش للإصابات الطفيلية لجميع الأنواع وجود ثلاث درجات من شدة الإصابات استنادا على عدد الطفيليات الخارجية لكل طير (١): الإصابة الخفيفة ١ - ٥٠ طفيلي / طير والإصابة المعتدلة ٥١ - ١٠٠ طفيلي / طير و الإصابة الشديدة أكثر من ١٠٠ طفيلي / طير وخاصة في التربية المنزلية غير الصحية مع سوء التغذية. أما الأعراض السريرية في الدجاج المصاب بالطفيليات الخارجية وخاصة الشديدة الإصابة فشملت الحكة، الإزعاج، قلة النوم، الضعف العام، فقدان الشهية، عدم الراحة، والحساسية، قلة إنتاج البيض في الإناث، وفقر الدم. أوضحت نتائج فحوصات الدم وجود فقر دم في الطيور المصابة بالطفيليات الخارجية الماصة للدم (القراد واللحم) مع انخفاض في نسبة حجم الخلايا الدموية المرصوصة (PCV%) وانخفاض العدد الكلي لخلايا الدم الحمراء (Erythrocyte Count) أو انخفاض في نسبة الهيموكلوبين (Hb) وخاصة في الدجاج المصاب بالطفيليات الخارجية شديدة الإصابة مقارنة بالدجاج غير المصاب مجموعة السيطرة. كما لوحظ زيادة في العدد الكلي لخلايا الدم البيضاء (Leucocytosis) وزيادة في المتغيرات (Hetrophilia) وكذلك نسبة الخلايا الحمضة (Eosinophilia) في الدجاج المصاب بالقراد واللحم والقمل، مع سوء التغذية والتربية غير الصحية مقارنة بمجموعة السيطرة .

Introduction

Several species of flies, lice, mites and soft ticks are important ectoparasites that infest poultry(2). They cause discomfort, irritation, loss of plumage, stunted growth, decrease egg production in layers and anemia (3). External parasites may also serve as carriers of bacterial, viral or protozoal diseases from one bird to another(4).

Biting or chewing lice are probably the most common and widespread avian ectoparasites (5, 6, 7), these are *Menacanthus stramineus*, common body louse of chicken, *Goniocotes gallinae* (fluff louse), *Cucloto-gaster heterographes*, (head louse) and *Columbicola columbae* (wing louse), they spend their entire life cycle on the host and cause irritation by feeding on skin and feathers and in heavy infestation can be injurious especially in cold weather (3, 4, 6).

Deremanyssus gallinae, red mite of poultry and one species of flies *Pseudolynchia canariensis* were frequently infesting chicken (3, 7). Soft ticks *Argas persicus* was found to be the most ectoparasite infecting chicken and is widely distributed in tropical and subtropical areas (3, 7, 8). Soft ticks *Argas Persicus* cause anemia, anorexia, weight loss, depressed egg output (2, 4, 5). This ectoparasite feeds on blood for a short period at night hidden in cracks and surfaces (3, 4). *Deremanyssus gallinae* is widely distributed throughout the world infest chicken and other birds it is non-burrowing mite and can be serious pests due to their blood sucking habits (7, 8).

The extent of damage caused by ectoparasite depends on the numbers of parasites, nutritional status of the host and intercurrent disease (3, 4, 5). House-reared chicken are particularly exposed to ectoparasitic infestation as they are kept for longer periods thus allowing the parasite to complete its life cycle (7, 8), whether on the host or in its environment. The most common cause of anemia in birds is blood sucking ectoparasites (8, 9). Heavy infestation with blood sucking ectoparasites such as soft ticks or mites can lead to blood loss anemia in birds (9, 10), PCV is the quickest and most practical method for evaluation the red cell mass of birds (10). Leucocytosis refers to an absolute increase in the total number of white blood cells in circulation, caused by inflammation, resulting from parasitic infections (9, 10).

Materials and Methods

Collection of ectoparasites: Individual examination of each bird (280 chickens) samples were taken randomly from each bird from vent, head, neck, breast, back, comb, and wing, by using eye lense 4X, comb, brush and fine forceps with good light source. Any suspected parasites or material are kept in small Petri-dish and 70% alcohol were added and sent for examination in the lab microscopically and classified according to (4, 11, 12). Number of ectoparasites and degree of infestation was estimated as mentioned before (1).

Collection of blood: Blood samples for hematological test were collected by venipuncture of wing vein kept in EDTA tubes and processed in the lab for the following tests:

Hb using Drabkin solution (by using spectro-photometer) and Digital blood cell counter (8, 9).

PCV microhematocrite method (Capillary tube) RBC

Digital blood counter and hemocytometer using Haymes' solution (9,10).

WBC Digital blood cell counter and hemo-cytometer using Turks solution (9,10).

Differential leucocyte count by staining blood films using leishman stain or Giemsa' stain(9,10).

Results

Table (1) shows different species of ectoparasites isolated from native chicken in Mosul. Total infestation rate was 19.3 %, of which 81% were single and 19 % were mixed infestations. Four species of chewing or biting lice were diagnosed from chicken under study (12.5%), (Fig. 2, 3, 4).

Menacanthus stramineus (chicken yellow body louse) were isolated from skin on breast, thigh and near cloaca. *Cuclotogaster heterographes* found on feathers of the head (head louse) it is dark grey colour. *Gonicotoes gallinae* mainly was seen on down feather (fluff louse) and *Columbicola columbae* (wing louse). These lice are not blood sucking ectoparasites, but have cutting or biting mouth parts and feed on feathers or scales from skin and cause considerable irritation and annoyance to the chicken on which they live. One species of flies *Pseudolynchia canariensis* 1.4% was detected, (Fig. 4).

One species of non-burrowing mite *Dermanyssus gallinae* the red mite of chicken, was isolated (4.3 %), (Fig. 5), it feeds mainly at night with blood sucking habits. One species of soft ticks *Argas persicus* was seen (6.8 %), Fig. (6), which is commonly distributed on tropical and sub-tropical areas, was the most important parasite seen from infested birds. Meanwhile, concerning the severity and number of ectoparasites on each bird three degrees of infestation were noticed (low number 1–50, moderate 51–100, and large number more than 100/ bird) in case of heavy infestation (1).

Infestations with mites 4.3% *Dermanyssus gallinae* (Red mites of poultry), were detected these mites feed on hosts during the night, and hide during the day. The mites suck blood, which result in restless, poor egg production and anemia (3, 8, 13).

Clinical signs of chickens seriously infested with these ectoparasites exhibit irritation, scratching, rubbing, restless, weakness, anorexia, decrease egg production and anemia. Most of these ectoparasites live on the skin or in the feather, some penetrate the skin, others sucking blood.

Table (2) shows that a significant decrease in (PCV %), erythrocyte and/or HB values ($P < 0.05$) in infested group as compared with normal chickens.

It is clear from table (2) that a significant ($P < 0.05$) decrease in PCV, and erythrocyte values, HB values in chickens infested with blood sucking ectoparasites (soft ticks and mites) as compared with control non-infected group of birds. Significant hetrophilia and eosinophilia ($P < 0.01$) as compared with control groups of birds, also seen in table (2).

Table (1): Distribution of various ectoparasites species isolated from infested native chicken in Mosul

No. of Chickens (280)	No. of Positive + Infected bird	% of Infestation	Diagnosis of the ctoparasites
Parasitic findings			
Flies	4	1.4 %	<i>Pseudolynchia canariensis</i>
Lice	35*	12.5 %	1- <i>Menacanthus stramneus</i> . 2- <i>Cuclotogaster heterographes</i> . 3- <i>Gonicotoes gallinae</i> . 4- <i>Columbicola columbae</i> .
Mites	12	4.3 %	<i>Dermanyssus gallinae</i> .
Soft Ticks	19	6.8 %	<i>Argas persicus</i> .
All types of ectoparasites	54	19.3 %	Flies + Lice + Mite + Ticks
Single infection	44**	81 %	
Mixed infection	10	19 %	
Low no. of parasites	36	66.6 %	No.: 1 – 50 Ectoparasites / Bird.
Moderate no. of parasites	13	24 %	No.: 51 – 100 Ectoparasites / Bird.
Heavy No.of parasites	5	9.4 %	No.: more than 100 Ectoparasites / Bird.

* Significant difference from other ectoparasites ($P < 0.05$)

** High significant difference from other types and severe infection ($P < 0.01$).



Fig 1 (Chewing or Biting louse of chicken)
Menacanthus stramineus



Fig 2 (Colmbicola columbae)



Fig 3 (Goniocotes gallinae)



Fig 4 (Anterior end of fly of chicken)
Pseudolynchia canariensis

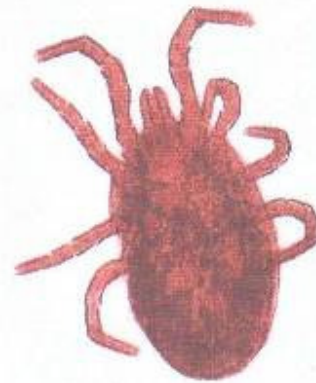


Fig 5 (Red mite of chicken)
Dermanyssus gallinae

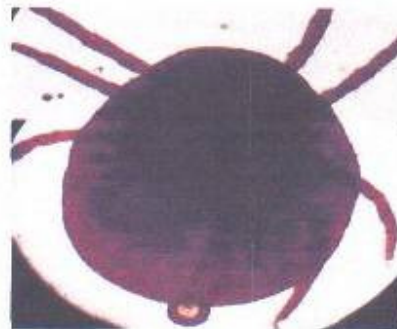


Fig 6 (Soft Tick)
Argas persicus

Table (2): Hematological changes in chickens infested with different ectoparasites in Mosul

Variable	Infested chickens 54	Control group 20
HB	6.9 μ 1.2 *	8.6 – 11.4 gm/ dl
P. C. V.	25 μ 2.3% **	29 – 45 %
Total red cell count	2.51 μ 0.30 **	3- 3.8 \times 106 / cmm.
W. B. C.	> 35 \times 103/ cmm **	19.8 – 29.4 \times 103 / cmm.
Eosinophil	6%**	1.9 %
Heterophil	34%**	27%

* Significant difference from other values at $P < 0.05$.

** Significant difference from other values at $P < 0.01$

Values of HB, P.C.V., Total red cell count are presented as mean μ standard deviation
Values under control group are normal ranges.

Discussion

Many kinds and species of ectoparasites are known to infest chicken (flies, lice, mite, and ticks). The total loss for which they are responsible is numerous, and they present an important practical problem wherever chicken are kept (13, 14). During the present study an attempt was made to find the ectoparasites infesting native chicken in Mosul from different farms, houses and markets (280) birds, and also to determine some haematological changes caused by those ectoparasites.

The majority of the ectoparasites reported in this study were similar to those described by other workers in chicken (3,6,7,13,15). Infestation rate with lice was 14.2 % approximately to that reported in Mosul (6,15) and the body louse of chicken *Menacanthus stramineus* is one of the most common parasites of poultry and this is in agreement with (16). It is mostly located in the region of vent, breast, back, and under the wings. *Cuclotogaster heterographis* chicken head louse is found chiefly on head and neck, *Gonicotoes gallinae*. *Columbicola columbae* all were belong to order Mallophaga chewing lice of birds.

Hoogstraal (17) stated that *A. Persicus* were found in every flock of chicken in several parts of Egypt. The results from Table (1) indicated that 81 % of infected chicken were single (one type of ectoparasite) 19 % were mixed (two type or more). This is similar to that of (6, 11). It appears from our results that there was three degrees of ectoparasitic infestations, (low No. 1–50 / bird, moderate No. 51–100/ bird, and large No. more than 100/ bird)(1), depending on hygienic measures size of houses or cages, and malnutrition as reported by (16).

Hematological findings of the present study (Table 2) revealed decrease values of PCV%, total erythrocytes and / or HB values of the infested chicken as compared with control group. The cause of anemia of infected chicken in

this study is due to blood sucking parasites (blood loss anemia), those results were also recorded by (5, 10, 18). Birds with PCV % of less than 35% are generally considered anemic (9, 10, 18), in which ticks and mites were responsible for these haemorrhagical changes, while lice or flies cause no-anemia in birds (not blood sucking ectoparasites).

Leukocytosis and heterophilia (34%) were seen in diseased birds heavily infested with ectoparasites (more than 35000/ cmm). Eosinophilia 6% was predominant and very characteristic feature seen in Rowmnowsky stained blood smears taken from birds infested with lice, mites, and / or ticks, in addition heterophilia was common among infested chicken in stained blood film (colorless cytoplasm and rod shaped cytoplasm granules). It was evident that Eosinophilia is common in blood examined smears of infested birds specially moderate or heavy degree of infestation (chronic parasitic disease). Eosinophils look pale blue cytoplasm and round red Eosinophilic granules bright and lobed nuclei, this is similar to that reported by (9, 10, 18).

From this table significant increase of Heterophils and Eosinophils of infested chickens as compared with control group (normal birds).

Acknowledgment

This study was supported by the College of Veterinary Medicine, University of Mosul, Mosul, Iraq.

References

1. Ted J, Slowik, Robert S, Lane. Birds and Their Ticks in North Western California. The J. of Para 2001: 87; 4 : 755-761.
2. Winter AR, Funk EM. Poultry Sc and Practice 4th ed. Chicago, Philadelphia, New York: JB Lippincott Company 1996: 350-360.
3. Edgar HB, Leslie EC, Pomeroy BS. Diseases and Parasites of Poultry 5th ed. Philadelphia, Lea & Febiger 1958: 364-377.
4. Margaret LP. Diseases of Cages and Aviary Birds 2nd ed, Philadelphia, Lea Febiger 1969: 350-355.
5. Jordan FTW, Pattison M. Poultry Diseases 4th ed, Bailliere Tindal, London, WB Saunders 1996: 287-289.
6. خالص أحمد حمد ورياض العراقي. مسح وتشخيص لأنواع القمل على الدجاج المحلي في محافظة أربيل المجلة العراقية للعلوم البيطرية ٢٠٠٧ ؛ ٢١ : ١٣-٢١.
7. Gless, EE, Raw ES. Effects of Chicken Body Louse Infestation on Egg Production J Econ. Ent 1959; 52: 358-359.
8. Bains BS. A Manual of Poultry Disease Edition Roches Basil, Switzerland; (Roche) F. Hoffman La Roche Company 1979: 254-260.
9. Strukie, PD. Avian Physiology 3rd ed, Springer Verlag, New York, Berlin 1976: 45-69.
10. Campell TW. Avian Hematology and Cytology 2nd ed, Iowa State Press, Blackwell Publishing Company 2004: 12.
11. Hendrix CM. Diagnostic Veterinary Parasitology 2nd ed, Mosby Inc 1998: 173-181.
12. Richard W, David S. Veterinary Ectoparasites Biology Pathology and Control 2nd ed, Black Well Science Company, Oxford 2001: 166-168.
13. Reid, WM. Incidence and economic importance of different parasites under different ecological and geographical situation in Egypt. Poultry Sc 1956: 35; 926-933.
14. Herbert HR, Charles AR, Juneprrie AR. A Textbook of Entomology 5th ed, John Wiley Sons, New York, Chichester Brisbane Toronto Singapore 1982: 324-329.
15. Abul-hab J. Biting lice of chicken and pigeons in Baghdad area Sc Res Found. Bull Biol Res Cen, Iraq 1958: 36.
16. Bram RA. Surveillance and Collection of Arthropoda of Vet Importance. Agriculture Handbook 1978: 518.
17. Hoogstral H, Makraw NK. The Ticks (Ixodidea) of Iraq Keys Host and Distribution, J. of Iraq; Med Professions 1958: 6; 2-3.
18. Rick LC, Elsevier M. Veterinary Clinical Pathology Secrets 2nd ed, Elesier Mosby Missouri 2004: 282-301.