

Interleukin 17A as an Effective Target for Anti-inflammatory and Antiparasitic Treatment of Toxoplasmic Uveitis

Arnaud Sauer,^{1,2} Alexander W. Pfaff,² Odile Villard,² Catherine Creuzot-Garcher,⁴ Frédéric Dalle,⁵ Christophe Chiquet,⁶ Hervé Pelloux,⁷ Claude Speeg-Schatz,¹ David Gaucher,¹ Gilles Prevost,³ Tristan Bourcier,^{1,a} and Ermanno Candolfi^{2,a}

¹Service d'Ophtalmologie, Centre Hospitalier Universitaire de Strasbourg, ²Institut de Parasitologie et de Pathologie Tropicale, and ³Institut de Bactériologie, EA 4438, Université de Strasbourg France; ⁴Service d'Ophtalmologie, and ⁵Service de Parasitologie, Centre Hospitalier Universitaire de Dijon, ⁶Service d'Ophtalmologie, Centre Hospitalier Universitaire de Grenoble, France; and ⁷Service de Parasitologie-Mycologie, Centre Hospitalier Universitaire de Grenoble et Université Joseph Fourier Grenoble I, France

Background. Toxoplasmosis is the most common cause of posterior uveitis in immunocompetent subjects. The requirement of limiting both parasite multiplication and tissue destruction suggests that the balance between T-helper (Th) 17 and T-regulatory cells is an important factor in toxoplasmosis-induced retinal damage.

Methods. In a prospective clinical study of acute ocular toxoplasmosis, we assessed the cytokine pattern in aqueous humors of 10 affected patients. To determine the immunological mechanisms, we evaluated intraocular inflammation, parasite load, and immunological responses using messenger RNA and protein levels in a mouse model. Anti-interleukin 17A (IL-17A) monoclonal antibodies (mAbs) were administered with the parasite to evaluate the role of IL-17A.

Results. Severe ocular inflammation and cytokine patterns comparable to human cases were observed, including IL-17A production. Neutralizing IL-17A decreased intraocular inflammation and parasite load in mice. Detailed studies revealed up-regulation of T-regulatory and Th1 pathways. When interferon γ (IFN- γ) was neutralized concomitantly, the parasite multiplication rate was partially restored.

Conclusions. Local IL-17A production by resident cells plays a central role in the pathology of ocular toxoplasmosis. The balance between Th17 and Th1 responses (especially IFN- γ) is crucial for the outcome of infection. This data reveals new in vivo therapeutic approaches by repressing inflammatory pathways using intravitreal injection of IL-17A mAbs.

Toxoplasmosis is the most common cause of posterior uveitis in immunocompetent subjects. Despite their apparent clinical significance, the pathophysiological mechanisms underlying ocular lesions and their recurrence have largely been unexplored [1–3]. Due to the scarcity of parasites in the aqueous humor (AqH) of

affected eyes, an immunopathological mechanism is likely to be involved [1]. There is no clear consensus concerning the treatment of ocular toxoplasmosis (OT), which often involves the concomitant use of antibiotics with corticosteroids. However, such an immunosuppressive treatment may itself be responsible for the reactivation of OT, resulting in large necrotic retinal damage when used without adequate antibiotic coverage [4].

Current OT treatment balances the need to limit parasite multiplication and minimize tissue destruction in the eye. A recent study revealed interleukin 17 (IL-17)-producing T cells in brain inflammation sites due to *Toxoplasma* infection, which is controlled by interleukin 27 (IL-27) [5]. IL-17 is the key cytokine of the recently discovered Th17 inflammatory response. In addition to its anti-*Toxoplasma* role [6], IL-17 stimulates the production of interleukin 6 (IL-6) and nitric

Received 23 September 2011; accepted 7 May 2012; electronically published 22 August 2012.

Presented in part: Association for Research in Vision and Ophthalmology Annual Meeting 2010, Fort Lauderdale, Florida.

^aT. B. and E. C. contributed equally to this work.

Correspondence: Arnaud Sauer, MD, PhD, Service d'Ophtalmologie, Hopitaux Universitaires de Strasbourg, Nouvel Hopital Civil, BP 426, 67091 Strasbourg Cedex, France (arnaud.sauer@chru-strasbourg.fr).

The Journal of Infectious Diseases 2012;206:1319–29

© The Author 2012. Published by Oxford University Press on behalf of the Infectious Diseases Society of America. All rights reserved. For Permissions, please e-mail: journals.permissions@oup.com.

DOI: 10.1093/infdis/jis486

oxide, and amplifies local inflammatory responses in synergy with other mediators, such as interleukin 1, tumor necrosis factor (TNF) α , and interferon γ (IFN- γ) [7]. In addition, IL-17 amplifies local inflammatory responses by recruiting neutrophils and monocytes to sites of infection through the production of interleukin 8, Monocyte Chemoattractant Protein-1 (MCP-1), and granulocyte colony-stimulating factor [6, 8, 9]. A similar mechanism was observed in autoimmune uveitis and scleritis [10], along with its regulation by IL-27 [11–13]. Furthermore, we recently showed in a retrospective study that IL-17 overexpression was observed in most OT cases [14]. The detection of IL-17 in AqH in human OT supports the hypothesis of an autoimmune process [3, 15].

When mice of susceptible strains are infected by the natural oral route, this results in ocular infection, although the parasite load is usually too low and develops too slowly to allow us to investigate immunological mechanisms both in congenital [16] and adult-acquired infections [17]. Therefore, we established a model of direct intraocular injection of tachyzoites of the avirulent *Toxoplasma gondii* PRU strain, which mimics natural pathology, though at a measurable level [18].

Our study aimed to assess the cytokine pattern in a prospective study involving patients with acute OT, particularly in terms of the Th17 pathway; our findings were then confirmed in our mouse model. Furthermore, we aimed to determine the benefit of injecting IL-17A monoclonal antibodies (mAbs) to diminish intraocular inflammation without damaging the ocular tissues on account of the cytolytic effects due to increased ocular parasite loads. Thus, we aimed to control simultaneously the 2 deleterious mechanisms involved in OT. Knowledge about the underlying immune mechanisms would enable us to develop more specific treatments targeting these pathogenetic mechanisms.

MATERIALS AND METHODS

Patients

The AqHs of 20 patients were collected, comprising 10 confirmed cases of acute acquired OT and 10 patients who had previously undergone cataract surgery. These patients were part of a prospective multicenter study benefitting from funds from Protocole Hospitalier de Recherche Clinique (PHRC 3964). All patients were immunocompetent. Anterior chamber puncture and serum sampling were conducted before initiating treatment. OT diagnosis was based on positive polymerase chain reaction (PCR) for 7 patients and immunoblotting for 3. The healthy control patients had been previously operated on for cataracts and were seronegative for *Toxoplasma* antibodies. The anterior chamber puncture was performed at the beginning of the surgical procedure. The protocol was approved by the local ethics committee, and all of the patients provided written informed consent.

Animals

Outbred Swiss-Webster mice were obtained from the Centre d'Élevage R. Janvier. Animals were bred under specific pathogen-free conditions at our laboratory. All experiments were conducted in accordance with the Statement for the Use of Animals in Ophthalmic and Vision Research from the Association for Research in Vision and Ophthalmology, under the surveillance of the regional Public Veterinary Health authorities.

Parasites

Cysts of *T. gondii* of the type II (avirulent) PRU strain were obtained from the brains of previously infected Swiss-Webster mice. Tachyzoites of the *T. gondii* PRU strain were harvested from infected human MRC5 fibroblast cultures.

Experimental Schedule

Mice at 4 weeks of age were infected intravitreally in both eyes with 2000 tachyzoites in 5 μ L phosphate-buffered saline (PBS) using 30-gauge needles. The precise amount of injected tachyzoites was confirmed by microscopic counting and quantitative PCR. Age-matched control mice received an intravitreal injection of 5 μ L of PBS. In a second experiment, 200 pg of anti-IL-17A mAbs were administered together with the tachyzoites. The corresponding control mice received 200 pg of rat immunoglobulin G2a (IgG2a) antibody. Finally, in a third experiment, 200 pg of IFN- γ mAbs and 200 pg of IL-17A mAbs (or 200 pg of a corresponding control rat IgG2a mAbs) in 5 μ L PBS were coadministered intravitreally. All antibodies were purchased from Clinisciences.

Intraocular injections were performed after a sedation procedure using isoflurane inhalation. The mice used in this study were killed by anesthetic overdose on days 1, 3, 5, or 7 after intravitreal injection. Clinical staging of intraocular inflammation was conducted as described elsewhere [19], and AqH was collected by means of an anterior chamber puncture (approximately 5 μ L per eye), then pooled and stored in aliquots of 25 μ L at -80°C until analysis. The eyes were finally enucleated, with the retinas being dissected and then stored at -80°C . Thus, each experimental group consisted of 5 animals (10 eyes), and all experiments were performed 3 times.

Quantification of Parasite Load

DNA was extracted from the whole eye using the QIAamp DNA Tissue Mini Kit (Qiagen), eluted with 200 μ L of Qiagen elution buffer, and stored at -20°C . *T. gondii* real-time PCR (RT-PCR) was performed for the *T. gondii* repeated sequence AF487550 [20] on a LightCycler 2.0 (Roche Diagnostics) using the DNA Master Hybridization Probes Kit (Roche Diagnostics), as described elsewhere [16].

Cytokine Measurement in AqH

The Bio-Plex human 27-Plex and mouse 10-Plex Cytokine Panel (Bio-Rad) assays were used to measure cytokine and chemokine

levels in AqH. The cytokine and chemokine assay plate layout consisted of 1 standard in duplicate (1–32 000 pg/mL), 4 blank wells, and 20- μ L duplicates of pooled AqH samples diluted to 50 μ L with BioPlex mouse serum diluent. The BioPlex method was performed as recommended by the manufacturer. Data was analyzed using Bio-Plex Manager TM software V1.1.

Quantitative RT-PCR Analysis

To include other potentially interesting cytokines or transcription factors that were not included in the BioPlex kit, we performed quantitative RT-PCR for T-bet, IL-27, Foxp3, ROR γ t, and transforming growth factor β (TGF- β). Retinas were gently homogenized. RNA was extracted using the RNeasy kit (Qiagen) according to the manufacturer's recommendations.

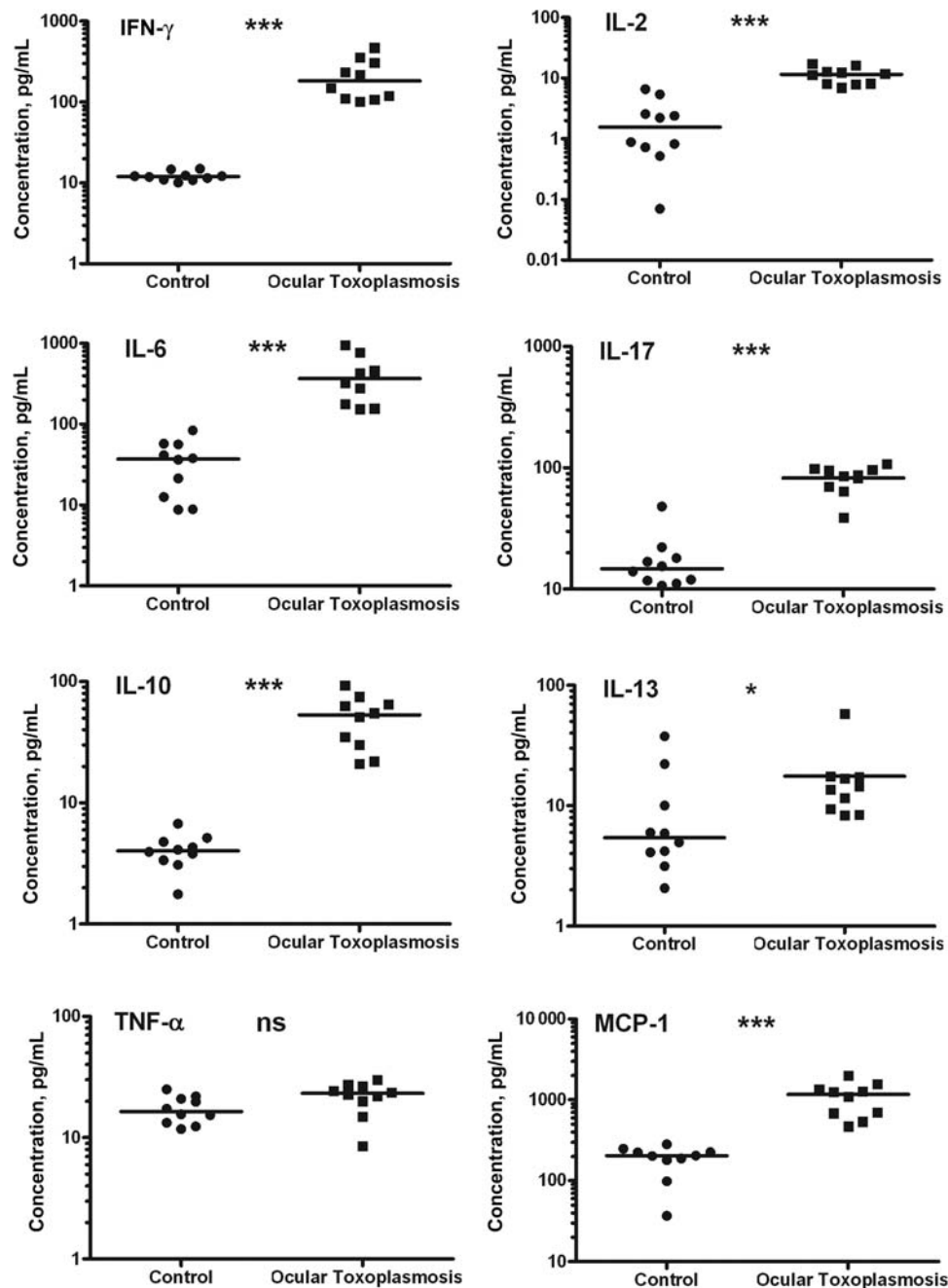


Figure 1. Cytokine and chemokine patterns in the aqueous humor of patients with acute ocular toxoplasmosis (n = 10) compared with control patients with cataracts (n = 10). Immune mediators were administered using a 27-plex BioPlex assay in duplicates of 50 μ L of aqueous humor. Horizontal dashes represent the medians * P < .05, *** P < .001. Abbreviations: IFN- γ , interferon γ ; IL-2, interleukin 2; IL-6, interleukin 6; IL-10, interleukin 10; IL-13, interleukin 13; IL-17, interleukin 17; MCP-1, ; NS, not significant; TNF- α , tumor necrosis factor α ; MCP-1, Monocyte Chemotactic Protein-1.

One microgram of RNA was then reverse-transcribed using the first-strand complementary DNA Synthesis Kit (Amersham Biosciences). Next, the complementary DNA samples were subjected to RT-PCR (LightCycler FastStart DNA MasterPLUS SYBR Green I; Roche Applied Sciences) on a capillary-based LightCycler instrument (Roche). An external standard created using the same primer pairs was employed to quantify gene expression. The messenger RNA (mRNA) expression levels were normalized to the levels of hypoxanthine phosphoribosyltransferase (HPRT) and expressed relative to the mRNA levels of the same gene in a noninfected mouse. The following primers were used in this study: murine hypoxanthine-guanine phosphoribosyltransferase (mHPRT) forward, 5'-GTT GGA TAC AGG CCA GAC TTT GTT G-3'; mHPRT reverse, 5'-GAT TCA ACT TGC GCT CAT CTT AGC C-3'; T-bet forward, 5'-CCT GTT GTG GTC CAA GTT CA-3'; T-bet reverse, 5'-TGC TGC CTT CTG CCT TTC-3';

IL-27 forward, 5'-CCT GTT GCT GCT ACC CTT-3'; IL-27 reverse, 5'-TGT GGA CAT AGC CCT GAA C-3'; Foxp3 forward, 5'-GCT GAT CAT GGC TGG GTT GT-3'; Foxp3 reverse, 5'-GGC CCT TCT CCA GGA CAG A-3'; ROR γ t forward, 5'-AGG CGG CTT GGA CCA CGA T-3'; ROR γ t reverse, 5'-CGG CCC TGG TTC TCA TCA A-3'; TGF- β forward, 5'-TGG CTT CTA GTG CTG ACG C-3'; TGF- β reverse, 5'-TAG TTT GGA CAG GAT CTG GC-3'; IL-17 forward, 5'-TCT CAG GCT CCC TCT TC-3'; and IL-17 reverse, 5'-CTA CCT CAA CCG TTC CAC-3'.

Histopathology and IL-17A Immunofluorescence of Retinal Sections

Eyes were enucleated and immediately fixed in 4% buffered formaldehyde. For histopathology, fixed eyes were embedded in paraffin using an automate (TECK VIP 300). Each piece

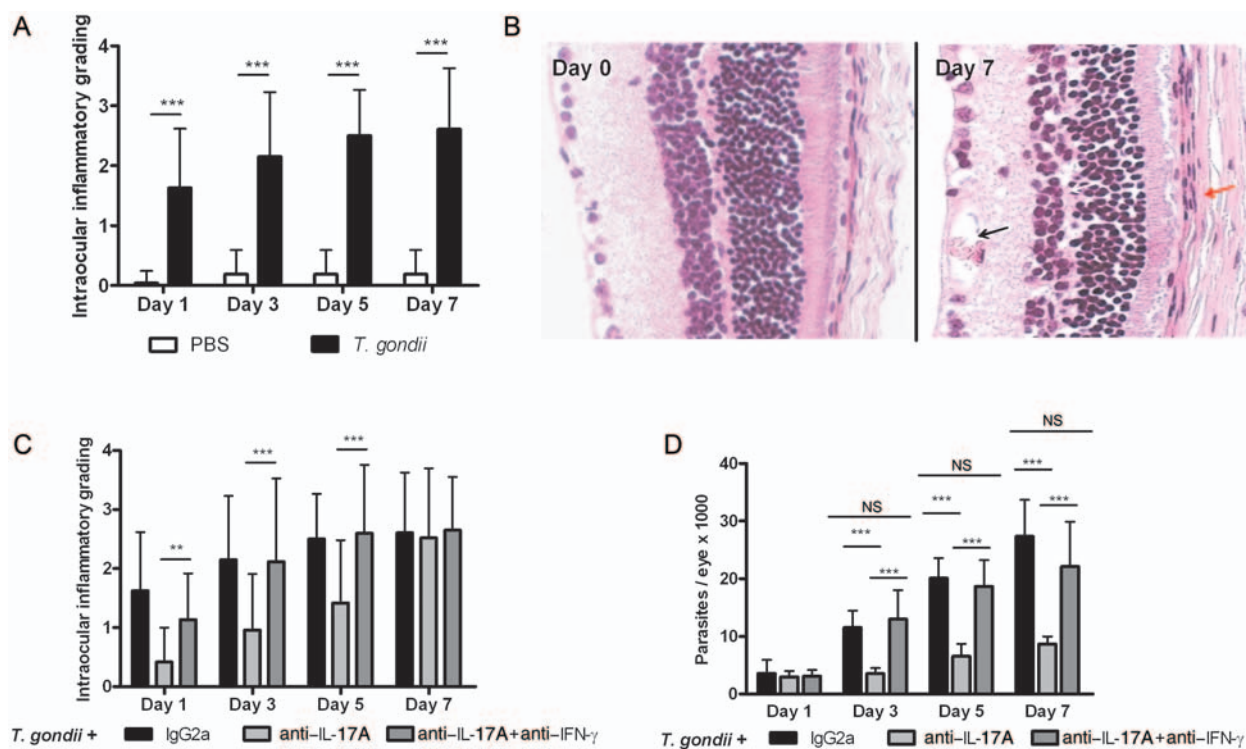


Figure 2. A, Intraocular infection with the avirulent PRU strain of *Toxoplasma gondii* rapidly induces local inflammation. Intraocular inflammation was graded on days 1, 3, 5, and 7 after an intravitreal injection of phosphate-buffered saline (PBS) or 2000 *T. gondii* tachyzoites. Values are expressed as means \pm standard deviations (SDs) of 30 eyes (5 mice per experiment in 3 replicates). B, Histopathology of retinal sections stained with hematoxylin-eosin. Note deterioration of the ganglionic cells layer and the choroids (red arrow) of all the analyzed sections accompanied by an infiltration of inflammatory cells and neovascularization (black arrow) and modified hierarchy of the various nuclear layers. C, Interleukin 17A (IL-17A) neutralization diminished the pathology. Intraocular inflammation was graded on days 1, 3, 5, and 7 after the intravitreal injection of 2000 *T. gondii* tachyzoites and concomitant injection of rat immunoglobulin G2a (IgG2a) or anti-IL-17A antibody. Concomitant neutralization of interferon γ (IFN- γ) reversed the effect of anti-IL-17A treatment. Values are expressed as means \pm SDs of 30 eyes (5 mice per experiment in 3 replicates). $^{***}P < .01$, $^{****}P < .001$. D, Ocular parasite multiplication was reduced after IL-17A neutralization. Parasites were quantified in enucleated eyes by DNA extraction and real-time polymerase chain reaction after intravitreal injection of 2000 *T. gondii* tachyzoites and concomitant injection of rat IgG2a or anti-IL-17A mAb. Neutralization of IFN- γ at the same time as IL-17A resulted in enhanced parasite load on day 7. Values are expressed as means \pm SDs of 3 independent experiments. $^{***}P < .001$. NS, not significant.

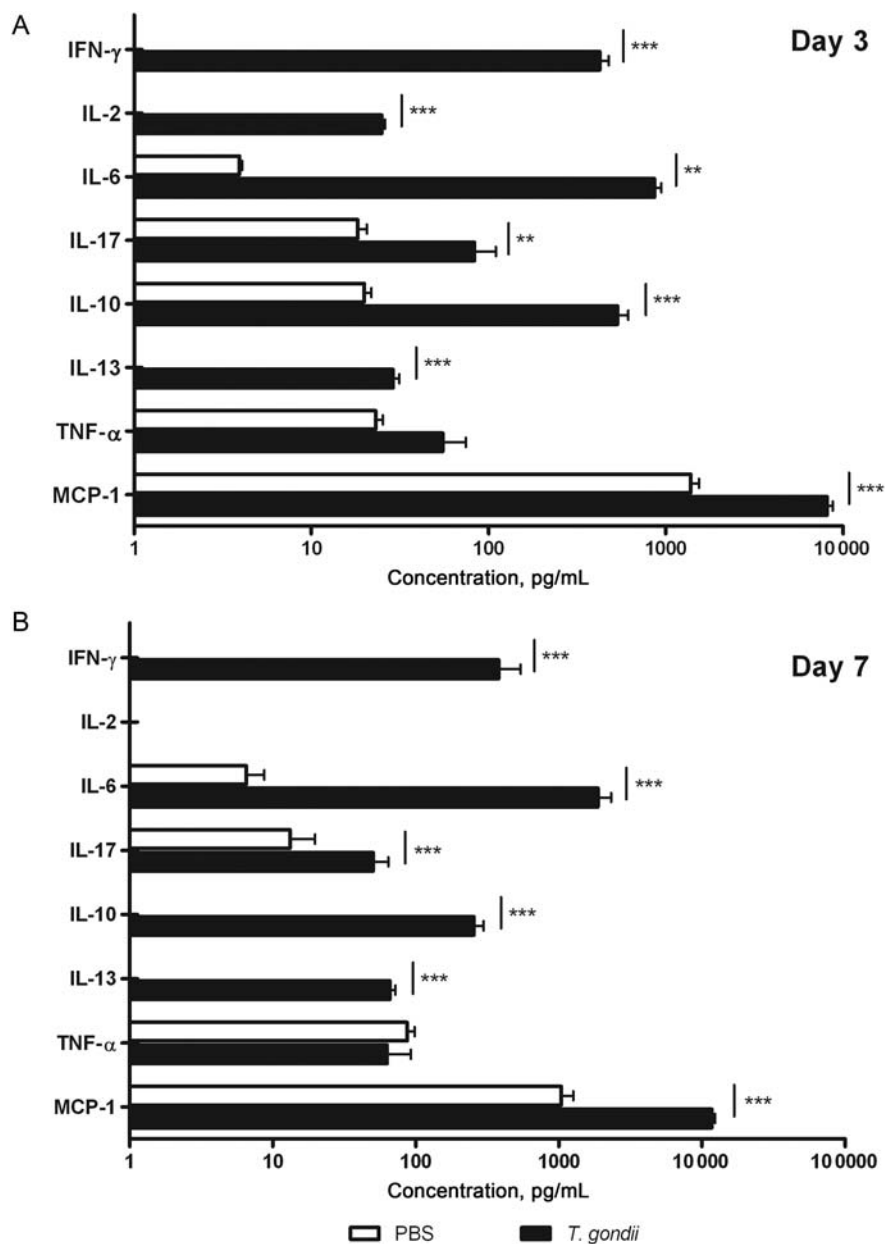


Figure 3. A large panel of cytokines and chemokines was up-regulated after intraocular infection. Cytokine levels in aqueous humor were measured by BioPlex assay on day 3 (A) or 7 (B) after the intravitreal injection of 2000 *Toxoplasma gondii* tachyzoites. Values are expressed as means \pm standard deviations of 3 independent experiments. ** $P < .01$, *** $P < .001$. Abbreviations: IFN- γ , interferon γ ; IL-2, interleukin 2; IL-6, interleukin 6; IL-10, interleukin 10; IL-13, interleukin 13; IL-17, interleukin 17; MCP-1, Monocyte Chemoattractant Protein-1; PBS, phosphate-buffered saline; TNF- α , tumor necrosis factor α .

was serially cut in 10 4- μ m sections hematoxylin-eosin stained with a staining machine (DRS 2000; Sakura).

For immunofluorescence, cryocut sections of whole eyes were prepared as described elsewhere [21]. In short, fixed eyes were placed in increasing concentrations of sucrose and embedded in Tissue-Tek OCT compound (Sakura Finetek). Thereafter, 15- μ m-thick sections were prepared, incubated in methanol, and quenched with glycine. Sections were incubated with rabbit anti-IL-17A antibody (clone H-132, 2 μ g/mL;

Santa Cruz Biotechnology) for 2 hours at room temperature, then with Alexa 488-conjugated anti-rabbit antibody (10 μ g/mL; Invitrogen) for 45 minutes, and finally with Hoechst 33342 stain for 1 minute. All antibodies were diluted in PBS (0.1% bovine serum albumin, 0.05% Tween 20). Between all steps, sections were washed with PBS for 3 \times 5 minutes. After mounting, fluorescence was visualized on an Axio-observer Z1 HSDI epifluorescence microscope (Zeiss) and evaluated with AxioVision v5 software (Zeiss). For colocalization

experiments, slides were incubated simultaneously with anti-IL-17A and goat anti-vimentin (Santa Cruz Biotechnology) antibodies, then with Alexa 488-conjugated anti-goat antibody and Alexa 546-conjugated anti-rabbit antibody (both Invitrogen), using the same protocol described above. Fluorescence was visualized on a Leica SR5 confocal microscope and evaluated using Leica LAS imaging analysis software.

Statistical Analysis

In the human study, values were given as individual cytokine or chemokine levels plus medians. Statistical analysis was performed using the nonparametric Mann-Whitney test. In mouse studies, values were expressed as means \pm standard deviations (SDs) of the 3 independent experiments. The statistical evaluation of the intraocular inflammation grading was performed using Student *t* test. The 2-way analysis of variance test was used to compare the mean titers of immune mediators obtained by RT-PCR and BioPlex analysis in the groups of mice. All statistical analyses and graphs were performed using the GraphPad Prism software, version 5 (GraphPad Software). Differences were considered statistically significant at $P < .05$.

RESULTS

Acute Ocular *Toxoplasma* Infection in Humans Associated With Inflammatory Cytokine Profile

A large panel of immune mediators was up-regulated in the infected eyes, including cytokines of the Th1 (interleukin 2 [IL-2], IFN- γ) and Th2 (interleukin 13 [IL-13], but to a lesser extent) pathways, as well as inflammatory (IL-6, IL-17, MCP-1) and down-regulating cytokines (interleukin 10 [IL-10]). In contrast, TNF- α was not up-regulated. In addition, we confirmed the strong up-regulation of IL-17 in patients with OT (Figure 1). All other cytokines and chemokines were below the detection limit.

Measurable Inflammation Induced by Intraocular *T. gondii* Injection

As shown in Figure 2A, the *T. gondii* injection rapidly induced intraocular inflammation, the differences between the infected and sham-infected mice being highly significant ($P < .001$) throughout the experiment. Our observations showed that the toxoplasmic infection involved mild architectural modifications of the analyzed retinas (Figure 2B). Indeed, we observed a deterioration of the ganglionar cell layer and the choroids of all the analyzed sections accompanied by an infiltration of inflammatory cells and a neovascularization. Moreover, we noticed a deterioration of the hierarchy of the various nuclear layers characterized by a folding of the photoreceptor layer.

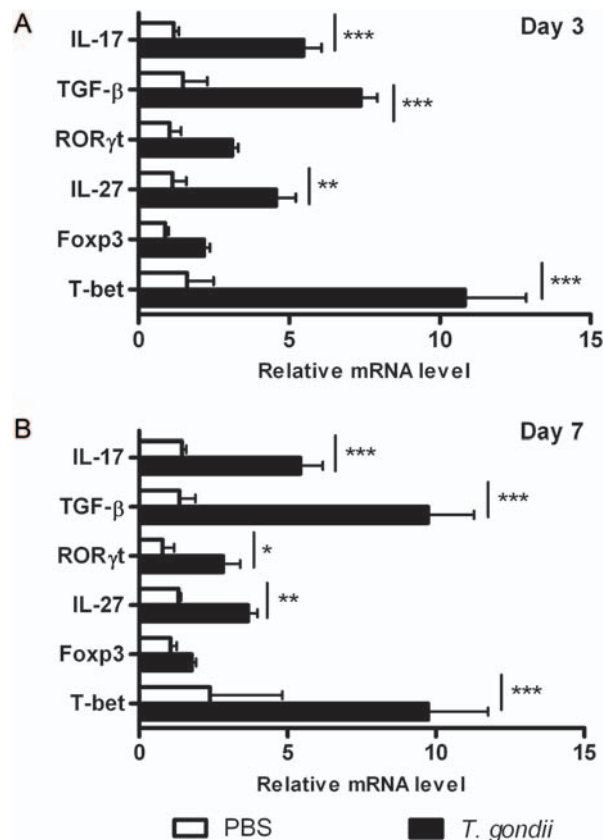


Figure 4. Retinal gene transcript levels of several transcription factors and cytokines increased after infection. Mice were injected intravitreally with phosphate-buffered saline (PBS) or 2000 *Toxoplasma gondii* tachyzoites. Quantitative real-time polymerase chain reaction analysis was performed in pools of the retinas, with 5 mice per group. Values are expressed as means \pm standard deviations of 3 independent experiments. * $P < .05$, ** $P < .01$, *** $P < .001$. Abbreviations: IL-17, interleukin 17; IL-27, interleukin 27; mRNA, messenger RNA; TGF- β , transforming growth factor β .

Local Inflammatory and Anti-inflammatory Reactions Induced by Infection

Several cytokines of the Th1- and Th17-type reactions as well as regulatory cytokines, such as IL-10, were up-regulated on infection. No difference was visible between days 3 and 7, with the exception of IL-2, which was absent at the latter time point (Figure 3). IL-27 and TGF- β levels were significantly increased in the infected eyes. T-bet was markedly enhanced, thus confirming the initiation of a strong Th1 response, in line with our cytokine data. Additionally, the up-regulation of inflammatory cytokines was mirrored by the enhanced ROR γ t transcription (Figure 4).

Effect of IL-17A Neutralization on Intraocular Inflammation Due to *T. gondii* Injection and Pathogen Control

Simultaneous injections of parasites and neutralizing antibodies were performed with the aim of abrogating early IL-17A

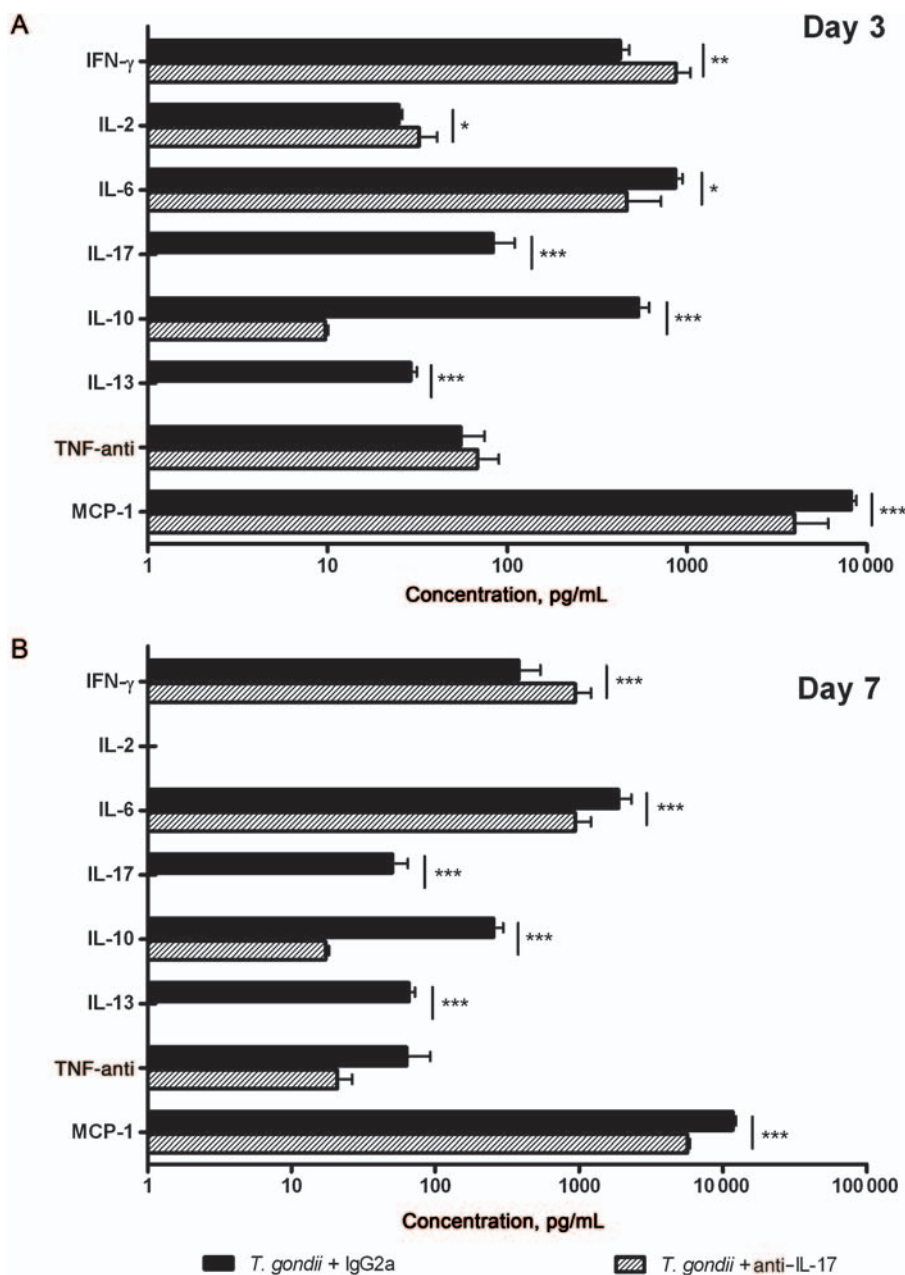


Figure 5. Interleukin 17A (IL-17A) neutralization augmented Th1-type cytokines. Cytokine levels in aqueous humor were measured by BioPlex assay on day 3 (A) or 7 (B) after intravitreal injection of 2000 *Toxoplasma gondii* tachyzoites and concomitant injection of rat IgG2a or anti-IL-17A monoclonal antibody. Values are expressed as means \pm standard deviations of 3 independent experiments. * $P < .05$, ** $P < .01$, *** $P < .001$. Abbreviations: IFN- γ , interferon γ ; IL-2, interleukin 2; IL-6, interleukin 6; IL-10, interleukin 10; IL-13, interleukin 13; IL-17, interleukin 17; MCP-1, Monocyte Chemoattractant Protein-1; TNF- α , tumor necrosis factor α .

and its functional role in the pathological development of the disease. Intraocular inflammation after the intravitreal injection of IL-17A mAb was significantly lower on days 1, 3, and 5 compared with the injection of a rat IgG2a control antibody (Figure 2B). This difference disappeared on day 7. Using the control mAb, the ocular parasite load started to increase exponentially after day 1 until the end of the experiment. After the injection of anti-IL-17A mAbs at the same time as *T. gondii*

tachyzoites, parasite multiplication could not be completely prevented, although it was significantly delayed (Figure 2C).

Effect of IL-17A Neutralization on Cytokine Balance in AqH

AqH levels of the inflammatory mediators, IL-6 and MCP-1, were decreased with anti-IL-17A mAbs as compared with the corresponding IgG2a control. In addition, the Th1 cytokines IL-2 (on day 3) and IFN- γ showed increased levels with

anti-IL-17A mAbs, whereas TNF- α levels did not significantly differ. Surprisingly, IL-10 was down-regulated, and IL-13 was absent (Figure 5A and 5B).

Quantitative RT-PCR Analysis Revealing Shift Toward T-Regulatory Pathways

Although the regulating cytokine TGF- β was slightly less expressed with anti-IL-17A mAbs, the anti-inflammatory IL-27 showed markedly enhanced mRNA levels on IL-17A neutralization. The latter finding was mirrored in the enhanced expression of *Foxp3* mRNA. The highly enhanced *t-bet* expression was in line with the higher IFN- γ levels, thus pointing to an influx of Th1 cells. In contrast, the expression of *ROR γ T* was not affected (Figure 6).

Reversed Effects of Anti-IL-17A Treatment With Concomitant Neutralization of IFN- γ

The neutralization of IFN- γ and IL-17A led to increased inflammation (Figure 2B). Similarly, parasite multiplication almost returned to its original level with IFN- γ and IL-17A neutralization (Figure 2C).

Production of IL-17A in Retinal Cells

Retinas of both noninfected and infected mice stained positive for IL-17A (Figure 7A). The wide distribution of IL-17A-producing cells, mainly located in the ganglion and nuclear layers, suggested resident cells rather than infiltrating leukocytes. Staining was considerably more intense in the retinas of infected mice, being extended to transversal cells. On account of this staining of transversal fibers, we undertook a colocalization study of IL-17A and vimentin, a marker for Müller cells (Figure 7B). A large colocalization of IL-17 and Müller cells was observed, in addition to some IL-17 production in other cell types that did not express vimentin.

DISCUSSION

Understanding the immunopathological mechanisms involved in OT is a prerequisite for developing targeted pharmaceutical interventions. However, because of our limited access to human ocular tissues and the variable ocular affections that occur after oral infection in animal models, few data are available. This is particularly true when investigating early inflammatory responses and cytokine production.

In a recent retrospective study [14], we found a characteristic local cytokine profile in human OT, which notably included IL-17A overexpression. To obtain more precise data, we conducted a prospective study so as to establish ocular cytokine and chemokine levels in clinically well-defined patients in French hospitals. The confirmed presence of IL-17A in infected eyes is of particular interest, because this cytokine is known to induce and mediate proinflammatory responses and

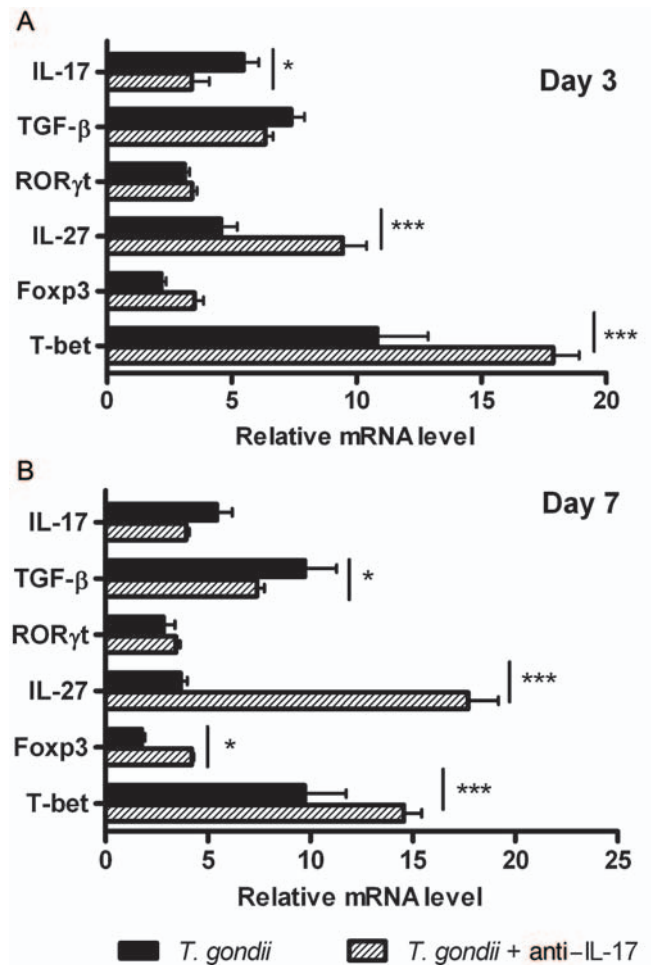


Figure 6. Gene expression analysis revealed increased T-regulatory pathways. Mice were injected intravitreally with 2000 *Toxoplasma gondii* tachyzoites and simultaneously with rat IgG2a or anti-IL-17A antibody. Quantitative real-time polymerase chain reaction analysis was performed in pools of the retinas, with 5 mice per group. Values are expressed as means \pm standard deviations of 3 independent experiments. * P < .05, ** P < .01, *** P < .001. Abbreviations: IL-17, interleukin 17; IL-27, interleukin 27; mRNA, messenger RNA; TGF- β , transforming growth factor β .

autoimmune diseases. The role of IL-17A in infectious diseases is ambiguous, varying between antipathogenic activity and tissue destruction. IL-17 and the corresponding inflammatory response have already been reported during *T. gondii* infections [5, 6, 22]. In contrast, there is a considerable discrepancy in terms of the antiparasitic effect of IL-17. Different studies have revealed contradictory results. The focus on different organs could be one explanation. In addition, numerous studies confirmed the central role of Th17-type cytokines in autoimmune pathology [11, 23], although they may be beneficial in certain infectious diseases [24]. However, the eye presents a particular immunosuppressive environment [25]. Retinal pigment epithelium and probably other cell types

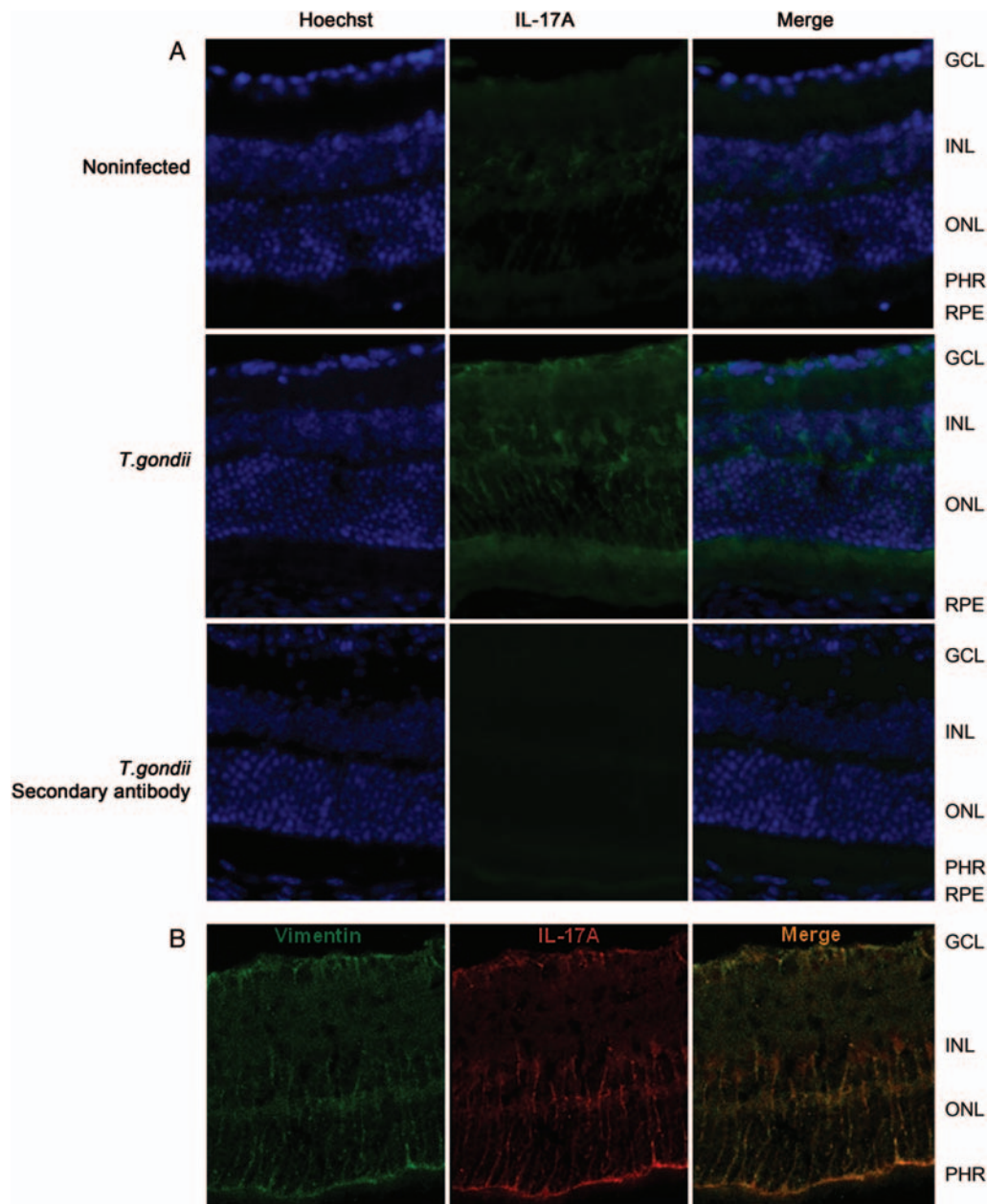


Figure 7. A, Immunofluorescence detection of interleukin 17A (IL-17A) in retinal sections. Cryocut sections of noninfected and *Toxoplasma gondii*-infected retinas on day 7 after injection were incubated with anti-IL-17A antibody, Alexa 488-conjugated secondary antibody, and Hoechst 33342 stain. To assess background staining, only secondary antibody stained sections are shown. Abbreviations: GCL, ganglion cell layer; INL, inner nuclear layer; ONL, outer nuclear layer; PHR, photoreceptors; RPE, retinal pigmented endothelium. B, Colocalization study of vimentin (Müller cells) and IL-17A in *T. gondii*-infected retinas on day 7 after injection, as described in Materials and Methods.

confer tolerance to activated T cells either directly or via the induction of T-regulatory cells [26, 27].

In our model involving the direct intraocular injection of tachyzoites of the avirulent type-II PRU strain of *T. gondii*, which mimics the natural pathology in Europe, we demonstrated the deleterious role of IL-17A in terms of pathology and parasite control. We also observed another increase in

intraocular inflammation on day 7. This increase may have been due to 2 major inflammatory mediator cytokines, IL-6 and MCP-1, which deserve further investigation. T-regulatory pathways were increased by IL-17A neutralization, as shown by the increased *IL-27* and *FoxP3* expression. It would be interesting to know whether existing *FoxP3*⁺ T cells were attracted to the eye or changed their phenotype in situ. Both direct

conversion [27] and peripheral induction of T-regulatory cells by locally primed antigen-presenting cells [28] were reported elsewhere. Keeping in mind the direct antagonism between IL-17 and IL-27 [29], which was also shown in a *T. gondii* infection setting [5], this up-regulation is not surprising.

Our immunofluorescence images suggested the early IL-17A production by resident retinal cells rather than infiltrating T cells. The positive staining in noninfected retinas confirms this interpretation. This is somewhat surprising, because IL-17 production is generally attributed to T cells by activating the transcription factor ROR γ t [30]. However, cells of the innate immune system have been recently recognized as important factors in the rapid onset of inflammatory responses by IL-17 secretion [31]. The observed distribution and early secretion of IL-17A in the eye led us to suspect that resident cells, such as glial cells and/or astrocytes, may be responsible for this early production of IL-17A, as already reported in the brain [32]. Although the retina remains poorly explored, local IL-17 production was observed in a rat model of autoimmune uveitis and then localized to astrocytes based on morphological evidence [33]. Intriguingly, our observed production pattern corresponded with IL-27 production patterns in autoimmune uveitis [11]. It would be interesting to investigate the interplay between inflammatory and anti-inflammatory actions in the same cells.

Whether the up-regulation of IL-27 is directly responsible for the increased Th1 response and IFN- γ production in particular, remains uncertain during OT. IFN- γ is undoubtedly the central player in antitoxoplasmic immunity [34]. Accordingly, when we neutralized IFN- γ at the same time as IL-17A, we found that parasite proliferation nearly reached this level without any neutralizing antibodies. More surprisingly, an early reduction in ocular pathology was equally abrogated. Obviously, IFN- γ may suppress other factors responsible for the disease besides IL-17; in fact, the interleukin 22–interleukin 23 axis was recently described as a pathology factor independent from IL-17 in the intestine during *T. gondii* infection [35, 36]. Further studies are required to fully describe this pathological reaction in the ocular environment and elucidate the interaction between antiparasitic and pathological effects, as well as between Th1- and Th17-type responses in the eye.

In summary, we established a pathogenic role for local IL-17A in OT. Our results relate to the relatively benign Type II strain, predominant in Europe and North America, which induces IL-17 production in mice models. It would be of interest to analyze the inflammatory cytokines in South American patients, harboring more virulent strains [37–39]. The understanding of immunopathological OT events may open new and targeted approaches to immune therapy. The increasing efficacy and safety of intravitreal injections in conjunction with the development of pharmacotherapies has led to a recent surge in the use of this technique for the administration

of various pharmacotherapies in numerous diseases [40]. Because it was suggested that intravitreal drug application was likely to achieve therapeutic levels locally, resulting in prolonged effective concentrations, intravitreal injection may be used in toxoplasmic retinochoroiditis to decrease inflammatory processes. These findings open new in vivo therapeutic approaches based on the repression of the Th17 pathway via IL-17A mAbs.

Notes

Acknowledgments. All authors have seen and approved the content and contributed significantly to the work. No writing assistance other than copy editing (Dr Gabrielle Cremer; Cremerconsulting) was provided in the preparation of the manuscript. We would like to thank Bernard Peltre (Institut de Dermatologie, Strasbourg, France), Luc Marcelin (Service d'Anatomopathologie, Strasbourg, France), and Nicolas Argy and Elise Rochet (Institut de Parasitologie, Strasbourg, France) for performing part of the cryocut and the pathology sections. We are grateful to Daniel Keller, Sylvie Matern, and Rachel Huber for their valuable technical assistance.

Financial support. This work was supported by PHRC 3964 (“Infections oculaires graves”) and by Fondation de France (2007) (A. S.) and Société Française d'Ophtalmologie (2008) (A. S.).

Potential conflicts of interest. All authors: No reported conflicts.

All authors have submitted the ICMJE Form for Disclosure of Potential Conflicts of Interest. Conflicts that the editors consider relevant to the content of the manuscript have been disclosed.

References

- Holland GN. Ocular toxoplasmosis: a global reassessment. Part I: epidemiology and course of disease. *Am J Ophthalmol* **2003**; 136:973–88.
- Holland GN. Ocular toxoplasmosis: a global reassessment. Part II: disease manifestations and management. *Am J Ophthalmol* **2004**; 137:1–17.
- Garweg JG, Candolfi E. Immunopathology in ocular toxoplasmosis: facts and clues. *Mem Inst Oswaldo Cruz* **2009**; 104:211–20.
- de-la-Torre A, Rios-Cadavid AC, Cardozo-Garcia CM, Gomez-Marin JE. Frequency and factors associated with recurrences of ocular toxoplasmosis in a referral centre in Colombia. *Br J Ophthalmol* **2009**; 93:1001–4.
- Stumhofer JS, Laurence A, Wilson EH, et al. Interleukin 27 negatively regulates the development of interleukin 17-producing T helper cells during chronic inflammation of the central nervous system. *Nat Immunol* **2006**; 7:937–45.
- Kelly MN, Kolls JK, Happel K, et al. Interleukin-17/interleukin-17 receptor-mediated signaling is important for generation of an optimal polymorphonuclear response against *Toxoplasma gondii* infection. *Infect Immun* **2005**; 73:617–21.
- Afzali B, Lombardi G, Lechler RI, Lord GM. The role of T helper 17 (Th17) and regulatory T cells (Treg) in human organ transplantation and autoimmune disease. *Clin Exp Immunol* **2007**; 148:32–46.
- Miyamoto M, Emoto M, Emoto Y, et al. Neutrophilia in LFA-1-deficient mice confers resistance to listeriosis: possible contribution of granulocyte-colony-stimulating factor and IL-17. *J Immunol* **2003**; 170:5228–34.
- Ye P, Rodriguez FH, Kanaly S, et al. Requirement of interleukin 17 receptor signaling for lung CXC chemokine and granulocyte colony-stimulating factor expression, neutrophil recruitment, and host defense. *J Exp Med* **2001**; 194:519–27.
- Kuiper JJ, Mutis T, de Jager W, de Groot-Mijnes JD, Rothova A. Intraocular interleukin-17 and proinflammatory cytokines in HLA-A29-associated birdshot chorioretinopathy. *Am J Ophthalmol* **2011**; 152:177–182 e1.

11. Amadi-Obi A, Yu CR, Liu X, et al. TH17 cells contribute to uveitis and scleritis and are expanded by IL-2 and inhibited by IL-27/STAT1. *Nat Med* **2007**; 13:711–8.
12. Ke Y, Sun D, Jiang G, Kaplan HJ, Shao H. IL-22-induced regulatory CD11b+ APCs suppress experimental autoimmune uveitis. *J Immunol* **2011**; 187:2130–9.
13. Lee YS, Amadi-Obi A, Yu CR, Egwuagu CE. Retinal cells suppress intraocular inflammation (uveitis) through production of interleukin-27 and interleukin-10. *Immunology* **2011**; 132:492–502.
14. Lahmar I, Abou-Bacar A, Abdelrahman T, et al. Cytokine profiles in toxoplasmic and viral uveitis. *J Infect Dis* **2009**; 199:1239–49.
15. Gaddi PJ, Yap GS. Cytokine regulation of immunopathology in toxoplasmosis. *Immunol Cell Biol* **2007**; 85:155–9.
16. Lahmar I, Guinard M, Sauer A, et al. Murine neonatal infection provides an efficient model for congenital ocular toxoplasmosis. *Exp Parasitol* **2010**; 124:190–6.
17. Jones LA, Alexander J, Roberts CW. Ocular toxoplasmosis: in the storm of the eye. *Parasite Immunol* **2006**; 28:635–42.
18. Sauer A, Lahmar I, Scholler M, et al. [Development of murine models of ocular toxoplasmosis and preliminary results of ocular inflammatory transcriptome]. *J Fr Ophthalmol* **2009**; 32:742–9.
19. Lu F, Huang S, Kasper LH. Interleukin-10 and pathogenesis of murine ocular toxoplasmosis. *Infect Immun* **2003**; 71:7159–63.
20. Reischl U, Bretagne S, Kruger D, Ernault P, Costa JM. Comparison of two DNA targets for the diagnosis of Toxoplasmosis by real-time PCR using fluorescence resonance energy transfer hybridization probes. *BMC Infect Dis* **2003**; 3:7.
21. Charles E, Joshi S, Ash JD, et al. CD4 T-cell suppression by cells from *Toxoplasma gondii*-infected retinas is mediated by surface protein PD-L1. *Infect Immun* **2010**; 78:3484–92.
22. Guiton R, Vasseur V, Charron S, et al. Interleukin 17 receptor signaling is deleterious during *Toxoplasma gondii* infection in susceptible BL6 mice. *J Infect Dis* **2010**; 202:427–35.
23. Weaver CT, Harrington LE, Mangan PR, Gavrieli M, Murphy KM. Th17: an effector CD4 T cell lineage with regulatory T cell ties. *Immunity* **2006**; 24:677–88.
24. O'Quinn DB, Palmer MT, Lee YK, Weaver CT. Emergence of the Th17 pathway and its role in host defense. *Adv Immunol* **2008**; 99:115–63.
25. Streilein JW. Ocular immune privilege: the eye takes a dim but practical view of immunity and inflammation. *J Leukoc Biol* **2003**; 74:179–85.
26. Horie S, Sugita S, Futagami Y, Yamada Y, Mochizuki M. Human retinal pigment epithelium-induced CD4+CD25+ regulatory T cells suppress activation of intraocular effector T cells. *Clin Immunol* **2010**; 136:83–95.
27. Sugita S, Horie S, Nakamura O, et al. Retinal pigment epithelium-derived CTLA-2alpha induces TGFbeta-producing T regulatory cells. *J Immunol* **2008**; 181:7525–36.
28. Kitaichi N, Namba K, Taylor AW. Inducible immune regulation following autoimmune disease in the immune-privileged eye. *J Leukoc Biol* **2005**; 77:496–502.
29. Batten M, Li J, Yi S, et al. Interleukin 27 limits autoimmune encephalomyelitis by suppressing the development of interleukin 17-producing T cells. *Nat Immunol* **2006**; 7:929–36.
30. Ivanov II, McKenzie BS, Zhou L, et al. The orphan nuclear receptor RORgammat directs the differentiation program of proinflammatory IL-17+ T helper cells. *Cell* **2006**; 126:1121–33.
31. Cua DJ, Tato CM. Innate IL-17-producing cells: the sentinels of the immune system. *Nat Rev Immunol* **2010**; 10:479–89.
32. Kawanokuchi J, Shimizu K, Nitta A, et al. Production and functions of IL-17 in microglia. *J Neuroimmunol* **2008**; 194:54–61.
33. Jia X, Hu M, Wang C, et al. Coordinated gene expression of Th17- and Treg-associated molecules correlated with resolution of the monophasic experimental autoimmune uveitis. *Mol Vis* **2011**; 17:1493–507.
34. Yap GS, Sher A. Cell-mediated immunity to *Toxoplasma gondii*: initiation, regulation and effector function. *Immunobiology* **1999**; 201:240–7.
35. Munoz M, Heimesaat MM, Danker K, et al. Interleukin (IL)-23 mediates *Toxoplasma gondii*-induced immunopathology in the gut via matrixmetalloproteinase-2 and IL-22 but independent of IL-17. *J Exp Med* **2009**; 206:3047–59.
36. Wilson MS, Feng CG, Barber DL, et al. Redundant and pathogenic roles for IL-22 in mycobacterial, protozoan, and helminth infections. *J Immunol* **2010**; 184:4378–90.
37. Fekkar A, Ajzenberg D, Bodaghi B, et al. Direct genotyping of *Toxoplasma gondii* in ocular fluid samples from 20 patients with ocular toxoplasmosis: predominance of type II in France. *J Clin Microbiol* **2011**; 49(4):1513–7.
38. Melo MB, Jensen KD, Saeij JP. *Toxoplasma gondii* effectors are master regulators of the inflammatory response. *Trends Parasitol* **2011**; 27(11):487–95.
39. Sauer A, de la Torre A, Gomez-Marin J, et al. Prevention of retinochoroiditis in congenital toxoplasmosis: Europe versus South America. *Pediatr Infect Dis J* **2011**; 30:601–3.
40. Tolentino M. Systemic and ocular safety of intravitreal anti-VEGF therapies for ocular neovascular disease. *Surv Ophthalmol* **2011**; 56:95–113.