

CASE REPORT

B-Cell Pseudolymphoma Caused by Aluminium Hydroxide Following Hyposensitization Therapy

I. Hernández,^a O. Sanmartín,^b C. Cardá,^c S. Gómez, and A. Alfaro^b

^aServicio de Dermatología, Hospital General Básico de la Defensa de Valencia, Spain

^bServicio de Dermatología, Instituto Valenciano de Oncología, Valencia, Spain ^cServicio de Anatomía Patológica, Hospital Clínico de Valencia, Spain

Abstract. Aluminium hydroxide is used as an adjuvant in vaccines. We describe the case of a patient who presented a persistent adverse local reaction to aluminium hydroxide due to hyposensitization therapy to dust mites. Multiple painful and pruriginous subcutaneous nodules were observed in both arms, along with hypertrichosis at the injection site. Histology revealed a pseudolymphomatous B cell reaction predominantly involving cells that were CD20 positive, did not express BCL-2, and did not display the t(14;18) translocation. The cells also exhibited polyclonal rearrangement of the immunoglobulin heavy chains. X-ray spectral microanalysis revealed deposits of inorganic aluminium in the granular histiocytes among the germinal centers. The patient was diagnosed with cutaneous B-cell pseudolymphoma due to aluminium hydroxide as a result of immunotherapy.

Key words: B-cell pseudolymphoma, aluminium hydroxide, subcutaneous nodules.

PSEUDOLINFOMA B INDUCIDO POR HIDRÓXIDO DE ALUMINIO TRAS TRATAMIENTO HIPOSENSIBILIZANTE

Resumen. El hidróxido de aluminio es una sustancia que se utiliza como adyuvante de las vacunas. Describimos el caso de una paciente que presenta una reacción adversa local y persistente a esta sustancia debido al tratamiento hiposensibilizante frente a los ácaros. Clínicamente se observan múltiples nódulos subcutáneos en ambos brazos, dolorosos, pruriginosos y con hipertrichosis en el sitio de la inyección. El estudio histológico muestra una reacción pseudolinfomatosa de tipo B con predominio de células CD20 positivas, bcl-2 y t(14-18) negativos y una policlonalidad de los genes de cadenas pesadas de las inmunoglobulinas. El microanálisis de espectro de rayos X identificó depósitos inorgánicos de aluminio dentro de los histiocitos granulares entre los centros germinativos. Se establece el diagnóstico de pseudolinfoma B cutáneo por hidróxido de aluminio secundario a una inmunoterapia.

Palabras clave: pseudolinfoma B, hidróxido de aluminio, nódulos subcutáneos.

Introduction

Aluminium hydroxide is a compound used as an adjuvant in various types of vaccines, as it increases their effectiveness and generates a stronger immune response. One of the local adverse effects of this substance is the appearance of subcutaneous nodules at the injection site. Such nodules have a variety of histologic appearances,¹ among them

B-cell pseudolymphoma. We report the case of a patient who developed multiple nodules secondary to hyposensitization therapy with aluminium hydroxide-containing allergen extract.

Case Description

The patient was a 29-year old woman with a history of allergic rhinitis to dust mites who consulted our clinic for multiple painful pruriginous nodules on the upper part of both arms that had appeared a year and half earlier. The patient reported that she had received vaccinations against dust mites for 2 years and that she began to notice the nodules, which increased progressively in number and size, at the injection site approximately 1 year after having

Correspondence:
Onofre San Martín
Servicio de Dermatología
Instituto Valenciano de Oncología
C/ Profesor Beltrán Báguena, 8
46009 Valencia, Spain
osanmartinj@medynet.com

Manuscript accepted for publication May 8, 2007

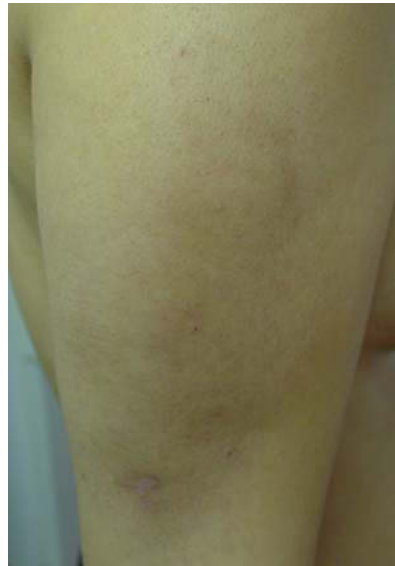

Figure 1. Nodules on the arms with hyperpigmentation and hypertrichosis.

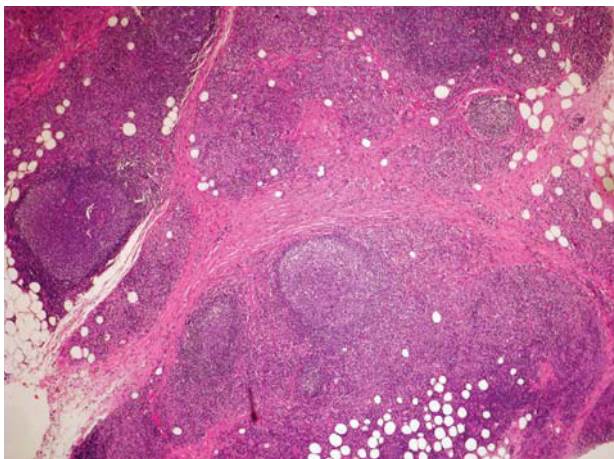


Figure 2. Lymphoid follicles in the subcutaneous tissue separated by areas of sclerosis (hematoxylin-eosin, original magnification $\times 10$).

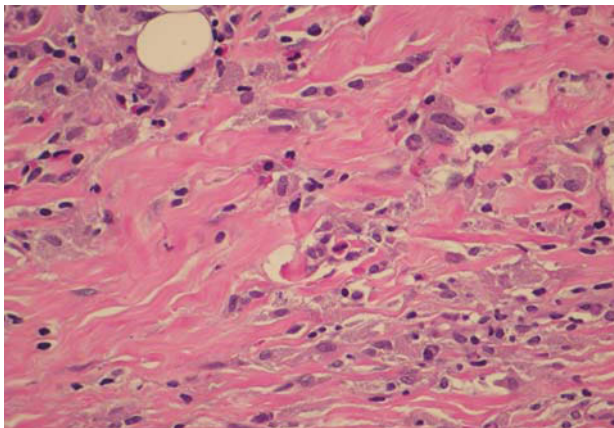


Figure 3. Mixed interfollicular infiltrate composed of lymphocytes, eosinophils, and histiocytes containing a granular cytoplasmic material (hematoxylin-eosin, original magnification $\times 40$)

discontinued therapy. She did not report any accompanying symptoms.

Physical examination revealed 10 nodules on the left arm and 7 on the right arm. They were painful and formed plaques of approximately 14×7 cm on the left arm and 10×4 cm on the right arm. She also presented hyperpigmentation and hypertrichosis on the skin covering the nodules (Figure 1).

Complete blood count; erythrocyte sedimentation rate; kidney and liver function; total proteins; protein analysis; calcium, lactate dehydrogenase, and uric acid levels; and peripheral blood smear were all normal. The only positive finding was a slightly elevated immunoglobulin E level.

Hematoxylin-eosin staining of a biopsy of one of the nodules revealed an inflammatory infiltrate consisting of well-formed lymphoid follicles with germinal centers and a marginal zone composed of reactive lymphocytes with abundant mitotic figures. These follicles were separated by areas of sclerosis and a mixed infiltrate consisting of lymphocytes, eosinophils, and histiocytes (Figure 2). The histiocytes had a large granular cytoplasm due to the presence of inclusions that were birefringent under polarized light (Figure 3). No plasma cells were detected and there was no perivascular or periadnexal infiltrate or foci of necrosis. The epidermis, superficial dermis, and middle dermis were normal.

The immunohistochemical study showed a proliferation of lymphoid cells, composed predominantly of B cells (CD20⁺). Immunoreactivity for BCL-2 oncoprotein was negative and there was no t(14;18) translocation. Germinal center cells were positive for CD10 and BCL-6. Molecular biology studies showed a polyclonal rearrangement of immunoglobulin heavy chains. The patient was diagnosed with B-cell pseudolymphoma.

Energy-dispersive x-ray (EDX) microanalysis of the lysed tissue sample revealed an absorption peak characteristic of aluminium salts (Figures 4 and 5).

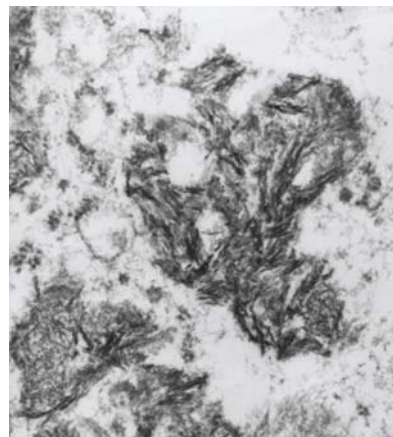


Figure 4. Dense granular material in histiocytes identified by energy-dispersive x-ray microanalysis.

The thin-layer rapid-use epicutaneous test (TRUE test, Allergan, Inc, Irvine, California, USA) yielded negative results, and patch tests for *Dermatophagoides pteronyssinus* and *Dermatophagoides farinae* extracts, and for the vaccine adjuvant containing 0.82 mg/mL of aluminium hydroxide were also negative. Patch tests were also performed with 2% and 33% aluminium hydroxide, aluminium, and aluminium chloride, with only a slight positive reaction (+) to aluminium chloride.

The treatment initiated with topical corticosteroids and oral antihistamines was ineffective, and monthly intralesional injections of triamcinolone acetonide at a concentration of 10 mg/mL were required. This led to a significant reduction in local discomfort and the size of the lesions after a period of 3 months.

Discussion

Aluminium compounds are widely used in personal hygiene products and are found in many deodorants, whitening toothpastes, and some local antiseptics. They are used as adjuvants in some vaccines, such as the hepatitis² and diphtheria-tetanus-pertussis vaccines,³ in specific hyposensitization therapy,⁴ such as that used against mites and wasp stings,⁵ and are also being used in the trial phase of the vaccine against avian influenza.⁶

Severe systemic adverse reactions to aluminium hydroxide, such as macrophagic myofasciitis,⁷ are rare. Adverse local reactions are more frequent, with clinical features ranging from erythema to the formation of subcutaneous nodules. When these appear shortly after the injection, they are self-involuting. However, when they appear months or years after discontinuation of therapy they usually persist for long periods, perhaps years.⁸ Individual differences and the possibility of a faulty technique in applying treatment are factors to be considered. The mechanism through which the aluminium salt deposits in the vaccine compound might induce the persistence of the reaction, be it through toxicity or hypersensitivity, remains to be elucidated.

Prior application of topical corticosteroids, repeated scratching of the area, or simply the inflammation itself could explain the hypertrichosis associated with such processes.⁸ Contradictory results have been reported for patch tests with aluminium in previously sensitized patients.⁹ Our patient had only a slightly positive test result for aluminium chloride.

Cutaneous B-cell pseudolymphomas are benign entities that require careful differential diagnosis with primary cutaneous B-cell lymphomas, such as cutaneous follicle center lymphoma and marginal zone lymphoma.¹⁰ Histopathologic, immunohistochemical, and molecular biology studies are essential.

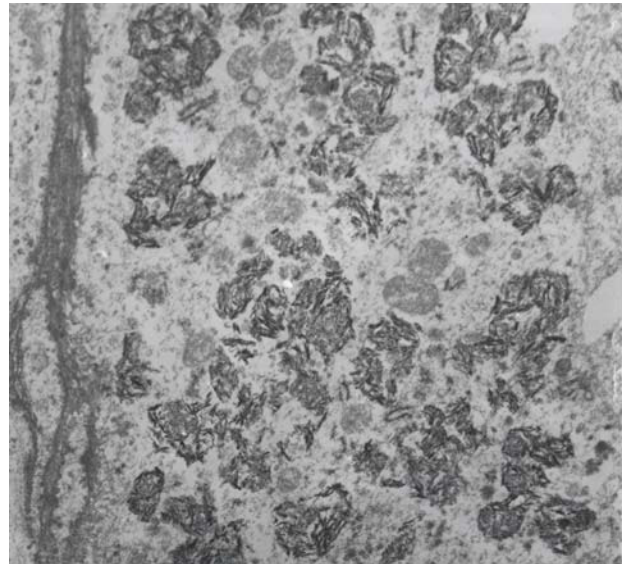


Figure 5. Aluminium salt crystals identified by energy-dispersive x-ray microanalysis.

Reactions to vaccines containing aluminium salts appear most frequently as a lobular panniculitis, followed in frequency by a granulomatous foreign body reaction or a rheumatoid nodule/deep granuloma annulare. A B-cell pseudolymphomatous pattern such as the one we describe may also appear. In all of these, the key to the diagnosis is the presence of eosinophils in the inflammatory infiltrate and of histiocytes with a large granular cytoplasm.¹¹

In the past, the Irwin-Azan stain,¹² which was considered positive if pale pink deposits appeared in the interior of the histiocytes, was used to identify aluminium in tissues. This technique has been supplanted by electron microscopy and EDX,^{13,14} the method we used to show the presence of inorganic aluminium deposits in the cytoplasm of the granular histiocytes among the germinal centers.

It is also possible for a B-cell pseudolymphoma to evolve into a true cutaneous B-cell lymphoma¹⁵ and for lesions to develop at some distance from the vaccination site. For this reason, patients with B-cell pseudolymphomas need to be followed very closely.

The treatment of persistent reactions to aluminium-containing vaccines has produced disappointing results, and topical corticosteroids and antihistamines are usually not very effective. Intralesional corticosteroids lead to temporary remission of the lesions, but they generally reappear with time. Complete excision of the nodules was not considered in this case because of the aesthetic sequelae it would have involved. The use of 5-aminolevulinic acid-mediated photodynamic therapy is recent and results have been encouraging.¹⁶ We ruled out the use of this technique in our patient because the lymphoid follicles were too deep,

and we opted for the administration of intralesional corticosteroids.

In conclusion, we must emphasize that there is a risk of persistent reactions to vaccines. A skin biopsy should be performed in order to determine their histologic patterns, as should immunohistochemical and molecular biology studies. We have described a case of B-cell pseudolymphoma due to aluminium hydroxide following hyposensitization therapy to dust mites.

Conflicts of Interest

The authors declare no conflicts of interest.

REFERENCES

- Culora GA, Ramsay AD, Theaker JM. Aluminium and injection site reactions. *J Clin Pathol.* 1996;49:844-7.
- Maubec E, Pinquier L, Viguier M, Caux F, Amsler E, Aractingi S, et al. Vaccination-induced cutaneous pseudolymphoma. *J Am Acad Dermatol.* 2005;52:623-9.
- Kaaber K, Nielsen AO, Veien NK. Vaccination granulomas and aluminium allergy: course and prognostic factors. *Contact Dermatitis.* 1992;26:304-6.
- Frost L, Johansen P, Pedersen S, Veien N, Ostergaard PA, Nielsen MH. Persistent subcutaneous nodules in children hyposensitized with aluminium-containing allergen extracts. *Allergy.* 1985;40:368-72.
- Vogelbruch M, Nuss B, Korner M, Kapp A, Kiehl P, Bohm W. Aluminium-induced granulomas after inaccurate intradermal hyposensitization injections of aluminium-adsorbed depot preparations. *Allergy.* 2000;55:883-7.
- Lin J, Zhang J, Dong X, Fang H, Chen J, Su N, et al. Safety and immunogenicity of an inactivated adjuvanted whole-virion influenza A (H5N1) vaccine: a phase I randomised controlled trial. *Lancet.* 2006;368:991-7.
- Authier FJ, Sauvat S, Christov C, Chariot P, Raisbeck G, Poron MF, et al. Al(OH)₃-adjuvanted vaccine-induced macrophagic myofasciitis in rats is influenced by the genetic background. *Neuromuscul Disord.* 2006;16:347-52.
- García-Patos V, Pujol RM, Alomar A, Cistero A, Curell R, Fernández-Figueras MT, et al. Persistent subcutaneous nodules in patients hyposensitized with aluminum-containing allergen extracts. *Arch Dermatol.* 1995;131:1421-4.
- Bergfors E, Trollfors B, Inerot A. Unexpectedly high incidence of persistent itching nodules and delayed hypersensitivity to aluminium in children after the use of adsorbed vaccines from a single manufacturer. *Vaccine.* 2003;22:64-9.
- Burg G, Kempf W, Cozzio A, Feit J, Willemze R, E SJ, et al. WHO/EORTC classification of cutaneous lymphomas 2005: histological and molecular aspects. *J Cutan Pathol.* 2005;32:647-74.
- Chong H, Brady K, Metze D, Calonje E. Persistent nodules at injection sites (aluminium granuloma) – clinicopathological study of 14 cases with a diverse range of histological reaction patterns. *Histopathology.* 2006;48:182-8.
- García-Patos V, Alomar A, Leonart R, Cistero A, Matías-Guiu X. [Subcutaneous nodules and sensitivity to aluminum in patients undergoing hyposensitivity immunotherapy]. *Med Cutan Ibero Lat Am.* 1990;18:83-8.
- Morrioni M, Barbatelli G, Carboni V, Sbarbati A, Cinti S. Subcutaneous nodules in a patient hyposensitized with aluminium-containing allergen extracts: a microanalytical study. *Anal Cell Pathol.* 1995;9:235-41.
- Nagore E, Martínez-Escribano JA, Tato A, Sabater V, Dilata JJ. Subcutaneous nodules following treatment with aluminium-containing allergen extracts. *Eur J Dermatol.* 2001;11:138-40.
- Sanguenza OP, Yadav S, White CR Jr., Brazier RM. Evolution of B-cell lymphoma from pseudolymphoma. A multidisciplinary approach using histology, immunohistochemistry, and Southern blot analysis. *Am J Dermatopathol.* 1992;14:408-13.
- Mikasa K, Watanabe D, Kondo C, Tamada Y, Matsumoto Y. Topical 5-aminolevulinic acid-based photodynamic therapy for the treatment of a patient with cutaneous pseudolymphoma. *J Am Acad Dermatol.* 2005;53:911-2.