
Paraganglioma of the Mesenterium: a Case Report

Švajdler M. ml., Bohuš P., Závacký P.¹, Volanská M.¹, Repovský A.²,
Juskaničová E.³

Department of Pathology, Louis Pasteur Faculty Hospital, Košice

¹1st Department of Surgery, Louis Pasteur Faculty Hospital, Košice

²Department of Radiodiagnosics, A. Leňo Hospital, Humenné

³Department of Oncology, A. Leňo Hospital, Humenné
Slovak Republic

Summary

Extra-adrenal paragangliomas constitute 10 % or less of pheochromocytomas/ paragangliomas. Even rarer is the occurrence of paragangliomas outside the usual distribution of paraganglionic tissue. We report a case of extra-adrenal paraganglioma occurring in the small intestine mesentery in a 65-year-old man. To our knowledge, there are only seven case reports of paraganglioma occurring in this non-typical site. Computed tomography showed a solid expansive non-homogeneously enhancing mesenteric mass, measuring 10 x 8 cm with peripheral cystic component. Histologically, the tumour had a typical organoid "zellballen" pattern, showed immunohistochemical positivity for synaptophysin, neuron specific enolase, CD-56, chromogranin, and focally vimentin, and was cytokeratin and EMA negative. S-100 protein stained few sustentacular cells. The patient was free from recurrence or metastasis three months after tumour resection. Although rare, paraganglioma should be included in the preoperative differential diagnosis of solid mesenteric tumours, to prevent any potential life-threatening event preoperatively in the case of a catecholamines-producing tumour.

Key words: extra-adrenal paraganglioma – mesentery – pheochromocytoma

Súhrn

Paraganglióm mezentéria: kazuistika

Extraadrenálne paragangliómy tvoria do 10 % feochromocytómov/paragangliómov. Ešte vzácnejší je výskyt paragangliómov mimo zvyčajnej distribúcie paraganglií. Popisujeme prípad extraadrenálneho paragangliómu mezentéria tenkého čreva u 65 ročného muža. Podľa našich vedomostí, existuje iba sedem popísaných prípadov výskytu paragangliómu v tejto atypickej lokalizácii. Vyšetrenie počítačovou tomografiou zobrazilo solidný expanzívny kontrastom nehomogénne zvýraznený nádor veľkosti 10 x 8 cm. Nádor bol periférne cysticky zmenený. Histologicky mal nádor typickú organoidnú „zellballen“ architektoniku, bol imunohistochemicky synaptofyzín, neurón špecifická enoláza, CD-56, chromogranín a fokálne vimentín pozitívny. Cytokeratín a EMA boli negatívne. S-100 proteín zobrazil sporadické sustentakulárne bunky. Pacient bol 3 mesiace po operácii bez známok recidívy alebo metastáz. Napriek tomu, že je výskyt paragangliómu v mezentériu vzácny, mal by byť zahrnutý do predoperačnej diferenciálnej diagnózy, aby sa predišlo potencionálnej život ohrozujúcej príhode počas operácie tumoru produkujúceho katecholamíny.

Kľúčové slová: extraadrenálny paraganglióm – mezentérium – feochromocytóm

Čes.-slov. Patol., 43, 2007, No. 4, p. 153–156

Extra-adrenal paragangliomas constitute 10 % or less of total pheochromocytomas/paragangliomas (6). Knowledge of the distribution of normal paraganglionic tissue is important to a pathologist because of its value in predicting the sites of origin of paragangliomas. These tumours have been reported virtually at all locations where normal paraganglia are found during fetal and adult life and tend to be most frequent in areas

where paraganglionic tissue is most abundant. However, paraganglia may occur in locations outside the well-established sympathetic and parasympathetic distributions (11). We describe a case of solitary primary paraganglioma of the mesenterium, incidentally found in a 65-year-old man. To our knowledge, this case represents only the eighth reported case of mesenteric paraganglioma.

Case Report

A 65-year-old man with a deficit in cellular immunity and abnormal leukocyte count ($32 \times 10^9/L$, 78% of lymphocytes in differential count) was investigated because of suspicion of chronic

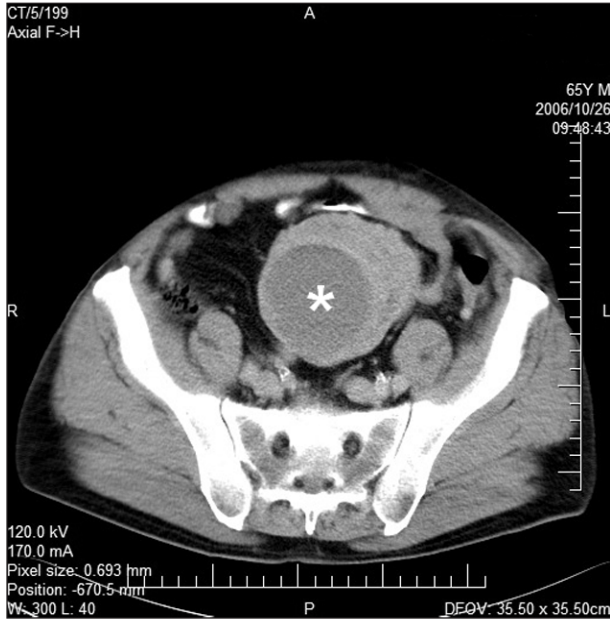

Fig. 1. Computed tomography showing solid expansive non-homogenously enhancing mesenteric mass with peripheral cyst (asterisk).

lymphatic leukaemia (CLL). His medical history included hypertension of several years duration. CLL was confirmed later by the bone marrow examination and the typical immunophenotype on flow cytometry (7). A thoracic and abdominal computed tomography scan, performed for the purpose of staging, did not reveal abnormally enlarged lymph nodes or significant splenomegaly, but showed solid expansive non-homogenously enhancing mesenteric mass, measuring 10 x 8 cm with peripheral cystic component measuring 6 cm (Fig. 1). A short segment of the ileum and its mesentery with the tumour were resected. Postoperatively, whole-body positron emission tomography showed no other primary tumorous lesion. Three months after the operation there are no signs of recurrence of the tumour or metastases.

Material and Methods

The resected specimen consisted of a 22 centimetre-long normal-appearing small bowel with a well demarcated tumorous mass in its mesentery, measuring 12 x 9 x 8 cm. On the cut surface, the tumour consisted of solid pale-brown to umber tissue on its periphery and a central cyst filled with haemorrhagic fluid (Fig. 2). After formalin fixation and routine tissue processing, 5 micron-thick sections were cut

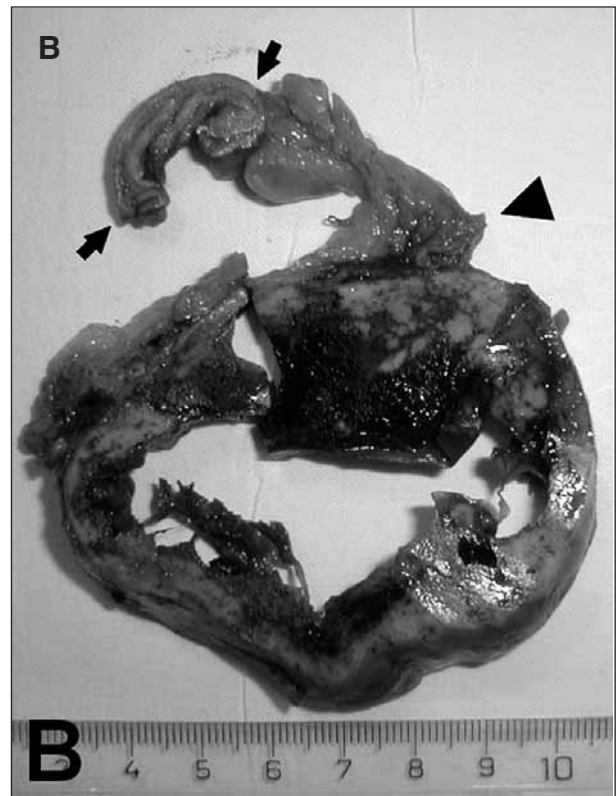
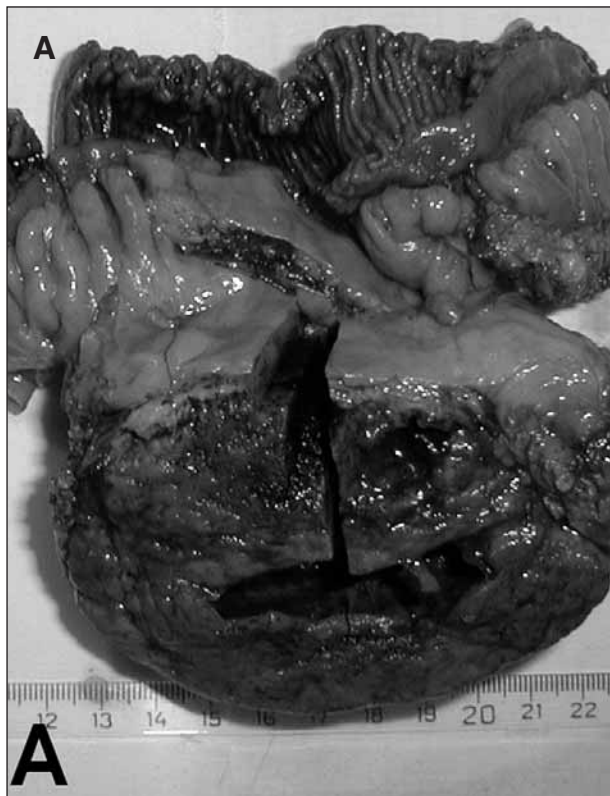


Fig. 2. Native resection specimen showing solid tumour with central cyst (A). Cross section showing relationship to bowel wall (arrows) and root of the mesentery (arrowhead) (B).

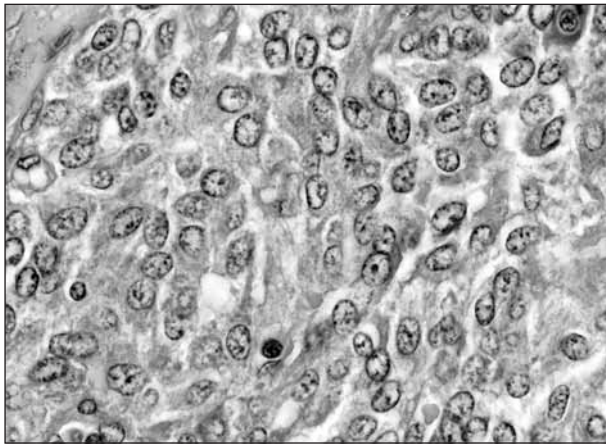


Fig. 3. Paraganglioma composed of epithelioid cells with fine "salt and pepper" neuroendocrine chromatin. HE x 600




Fig. 4. "Zellballen" pattern, highlighted by the PAS staining. PAS x 200

and stained with hematoxylin and eosin, PAS and impregnated with silver for reticulin. Immunohistochemical analysis was done with the following antibodies, using the standard avidin-biotin detection technique (Biogenex) and diaminobenzidine tetrachlorid as chromogene, according to manufacturer data sheets: Cytokeratin cocktail (AE1/AE3, Biogenex), Cytokeratin 8/18 (low molecular weight, 5D3, Biogenex), EMA (Epithelial membrane antigen, E29, Biogenex), S-100 protein (4C4.9, NeoMarkers), Vimentin (V-9, Biogenex), Chromogranin A (SP12, NeoMarkers), CD-56/N-CAM (56C04, NeoMarkers), NSE (Neuron specific enolase, BBS/NC/VI-H14, DAKO) and Synaptophysin (Snp 88, Biogenex).

Results

Histologically, the tumour had a typical organoid "zellballen" pattern, highlighted by the PAS and reticulin staining. Tumour cells were epithelioid and focally spindle-shaped,

with faint eosinophilic cytoplasm and round normochromatic nuclei, with fine "salt and pepper" chromatin (Figs. 3, 4). On average, less than 1 mitosis/10 high power fields were counted and no atypical mitoses were found. Immunohistochemically, the tumour cells stained with antibodies to synaptophysin, neuron specific enolase, CD-56, chromogranin, and focally vimentin, whereas cytokeratin cocktail, cytokeratin 8/18 and EMA were negative. S-100 protein stained only a few sustentacular cells (not shown).

Discussion

Paraganglia are dispersed neuroendocrine organs associated with the sympathetic and parasympathetic autonomous nervous system. Sympathetic paraganglia are distributed along the pre- and paravertebral sympathetic chains and follow the sympathetic innervation of the pelvic and retroperitoneal organs. Parasympathetic paraganglia are distributed along the cervical and thoracic branches of the vagus and glossopharyngeal nerves (4, 11). Paraganglia of the head and neck region and middle mediastinum have a special relationship to the branchial arches such as the carotid body paraganglia and some of these paraganglia function as chemoreceptors. With rare exceptions, the paraganglia of the head and neck are endocrinologically silent. In contrast, sympathoadrenal paraganglia are often functionally active and secrete catecholamines (6).

To our knowledge, there are only seven previously reported paragangliomas occurring in the mesentery. Five cases are found in the English written literature (1-3, 5, 8) and an additional two in Japanese (references 4 and 5 in 5). Similarly to our case, these mesenteric paragangliomas tend to be large tumours, with mean size 9.5 cm (range 3.2 – 20). They occurred in 2 males and 5 females aged 29 to 76 years (average 55) and presented most commonly with abdominal symptoms, nausea, vomiting and/or abdominal mass. In two cases, the presenting symptom was hypertension (2, 3). Although the serum level of catecholamines was not measured in our patient, his hypertension remained stable postoperatively, so it seems unlikely to be caused by functioning paraganglioma.

Although large size and a variegated cut surface showing haemorrhage and necrosis have been correlated with the propensity for malignant behaviour, malignant pheochromocytoma/paraganglioma is currently defined only by the presence of metastasis. Similarly, no imaging feature can reliably distinguish benign from malignant tumours. Intratumoral necrosis, haemorrhage, and heterogeneity in

imaging studies are common in both benign and malignant tumours (10). From the seven reported cases of mesenteric paraganglioma, one behaved in a malignant way, with liver metastasis. Interestingly, it was one of the smallest paragangliomas (4.5 cm), occurring in a 38-year-old woman, demonstrating the unpredictable nature of paragangliomas (reference 5 in 5).

Occurrence of the sporadically reported extra-adrenal paragangliomas outside the distribution of the autonomic nervous system, where normal paraganglia have not been described can probably be explained by the migratory property of the neural crest cells during embryogenesis (3, 5). Paraganglioma occurring in the small intestine mesentery can best be explained by abnormal ventral migration of paraganglionic cells from the root of the superior and inferior mesenteric arteries. These cells can form collection of paraganglionic tissue and give rise to a paraganglioma (3).

Solid tumours of the mesentery are rare and most of them are metastases. Primary solid tumours include smooth muscle tumours, extra-gastrointestinal gastrointestinal stromal tumour (E-GIST), fibromatosis (desmoid tumour), adipose tissue tumours, vascular tumours, so-called malignant fibrous histiocytoma (undifferentiated high grade pleomorphic sarcoma) and peripheral nerve tumours. There are isolated case reports of primary mesenteric carcinoid tumour, follicular dendritic cell tumour and germ cell tumours (9). In our case, the main differential diagnosis was that of a metastasis of carcinoma or carcinoid. A typical "zellballen" pattern together with immunohistochemical positivity for neuroendocrine markers and S-100 protein and negativity with epithelial markers made the distinction very easy.

In conclusion, we report a case of a paraganglioma in the mesentery of the small intestine. In our opinion, paraganglioma should be included in the differential diagnosis of solid tumours at this site, to prevent any potential life-threatening event preoperatively in the case of catecholamine-producing tumour.

Literature

1. **Arean, V.M., Ramirez de Arellano, G.A.:** Intra abdominal non chromaffin paragangliomas. *Ann. Surg.*, 144, 1956, p.133-137.
2. **Carmichael, J.D., Daniel, W.A., Lamon, E.W.:** Mesenteric chemodectoma. Report of a case. *Arch. Surg.*, 101, 1970, p. 630-631.
3. **Jaffer, S., Harpaz, N.:** Mesenteric paraganglioma. A case report and review of the literature. *Arch. Pathol. Lab. Med.*, 126, 2002, p. 632-634.
4. **Komminoth, P., De Krijger, R.R., Tischler, A.S.:** Paraganglia and the adrenal medulla. In: LiVolsi, V.A., Asa, S.L., eds.: *Endocrine Pathology*. Philadelphia: Churchill Livingstone, 2002, p.149.
5. **Kudoh, A., Tokuhisa, Y., Morita, K. et al.:** Mesenteric paraganglioma: report of a case. *Surg. Today*, 35, 2005, p.594-597.
6. **Loyd, R.V., Tischler, A.S., Kimura, N., McNicol, A.M., Young Jr., W.F.:** Adrenal tumours: Introduction. In: DeLellis, R.A., Lloyd, R.V., Heitz, P.U., Eng, Ch., eds.: *WHO Classification of Tumours. Pathology and Genetics of Tumours of Endocrine Organs*. Lyon: IARC Press, 2004, p. 138.
7. **Müller-Hermelink, H.K., Catovsky, D., Montserrat, E., Harris, N.L.:** Chronic lymphocytic leukaemia / small lymphocytic lymphoma. In: Jaffe, E.S., Harris, N.L., Stein, H., Vardiman, J.W., eds.: *WHO Classification of Tumours. Pathology and Genetics of Tumours of Haematopoietic and Lymphoid Tissues*. Lyon: IARC Press, 2001, p. 127-130.
8. **Muzaffar, S., Fatima, S., Saddiqui, M., Kayani, N., Pervez, S., Raja, A.:** Mesenteric paraganglioma. *Can. J. Surg.*, 45, 2002, p.459-460.
9. **Rosai, J.:** Peritoneum, retroperitoneum, and related structures. In: Rosai, J.: *Rosai and Ackerman's Surgical pathology*, 9th ed., Vol. 2. Edinburgh, London, New York, Oxford, Philadelphia, St Louis, Sydney, Toronto: Mosby, 2004, p. 2389-2392.
10. **Thompson, L.D.R., Young Jr., W.F., Kawashima, A., Komminoth, P., Tischler, A.S.:** Malignant adrenal pheochromocytoma. In: DeLellis, R.A., Lloyd, R.V., Heitz, P.U., Eng, Ch., eds.: *WHO Classification of Tumours. Pathology and Genetics of Tumours of Endocrine Organs*. Lyon: IARC Press, 2004, p. 147.
11. **Tischler, A.S.:** Paraganglia. In: Sternberg, S.S., ed.: *Histology for Pathologist*. New York: Raven Press, 1992, p. 364-367.

MUDr. Marián Švajdler ml
Department of Pathology,
Louis Pasteur Faculty Hospital, Košice
Trieda SNP 1
040 01 Košice
Tel.: +420556402917, +420556402914
E-mail: svajdler@yahoo.com