Another Method for Localization of Radiolucent Urinary Stones during ESWL

Ahmed I.A. Ibrahim[1], Soundra Pandyan[2]

Abstract:

Objectives: 1. To study the feasibility and safety of localization of radiolucent urinary stones during ESWL utilising the refluxing intravesically injected contrast medium along indwelling ureteral stents. 2. To identify the optimum volume of contrast medium and the intravesical pressure at which adequate vesicoureteral reflux sufficient for collecting system opacification occurs. 3. To identify criteria by which successful localization can be predicted.

Methods: With antibacterial prophylaxis, hundred mls. of contrast medium diluted with 500 ml normal saline was infused into the bladder through a Y shaped connection attached to a pre-inserted urethral catheter with the other limb connected to a water manometer for the purpose of continuous intravesical pressure recordings. The amount of infused contrast medium and intravesical pressure at which adequate visualization by fluoroscopy occurred was recorded. Successful stone localization was correlated with the infused contrast medium volume, intravesical pressure, infection, stone location, age, weight, stent duration and fluoroscopy time.

Results: Forty six patients were studied. Clear stone localization to facilitate shock targeting was achieved in 37 patients (80%). This occurred with a mean contrast volume of 300 ml at 20 cm water mean intravesical pressure. Apart from urinary tract infection which was associated with a significantly lower success rate, there were no other criteria by which success can be predicted. There were no significant complications and all visualized stones disintegrated well and were completely cleared at 3 months.

Conclusions: The method is safe, easy, repeatable and suitable for targeting radiolucent urinary stones during ESWL in patients with ureteral stents.

Introduction

Localization of radiolucent renal and ureteral stones during ESWL is commonly achieved either by ultrasonography or collecting system opacification by contrast media injected intravenously, percutaneously or through ureteral catheters positioned beforehand. Initially, with early experience on the Dornier HM3 lithotriptor, radiolucent stones were considered a relative contraindication to ESWL because of difficult stone localization[1]. Subsequently with the introduction of in-bath ultrasound as adjunct for treatment of radiolucent stones, with fluoroscopy localization lithotriptors, the imaging shortcomings were overcome[2]. Many recent versions of lithotriptors are supplied with a localization system composed of a real time 3.5 mHz. on line monitoring ultrasound transducer which is quite satisfactory for radiolucent renal stone targeting with a reported success rate of 76%[3]. Although reliable for radiolucent renal stone visualisation, ultrasonographic imaging and interpretation needs an experienced operator.

1. Professor of Urology, Dept. of Surgery, Faculty of Medicine, Ribat National University, Khartoum, Sudan
2. Urology Specialist, Assir Central Hospital, Abha, Saudi Arabia

Correspondence Address: Prof. Ahmed I.A. Ibrahim, P.O. Box 13066, Khartoum, Sudan
Telephone: 00249 912158131 Fax: 00249 183270771 E-mail: aiaibrahim@yahoo.com

It is also known that ultrasonography fails to localize ureteral stones at all levels with an overall reported ultrasonic stone identification rate of only 30% making X-ray fluoroscopy with collecting system opacification mandatory for targeting radiolucent ureteral stones during ESWL[4]. Intravenous injection of contrast media produces only a short lived opacification which may not be sufficient for protracted ESWL. It also requires fluid restriction which contradicts with the adequate hydration recommended for effective stone fragmentation by shock waves. Retrograde opacification requires general or regional anaesthesia for insertion of ureteral catheters which conflicts with minimal invasiveness strategies. Furthermore, follow up of the treatment outcome by fluoroscopy mandates further ureteral catheter insertion or I.V. urography to monitor progression of stone debris. Routine pre-ESWL ureteral stenting had been recommended for bulky and complex renal stones[5,6]. They are also inserted for patients presenting with completely obstructed kidneys secondary to acutely impacted ureteral stones. Localization of radiolucent ureteral stones for targeting during ESWL had been attempted by using a special double pigtail stent with an extracoil as a pointer for the stone in one published report[7]. With ureteral stenting

vesicoureteral reflux had been shown to occ the majority of patients[8] at an average bladder pressure of 20 cm water[9] and also in an experimental porcine model[10]. We rather thought of making use of this stenting side effect to opacify the collecting system by intravesical injection of contrast media resulting in a clear collecting system image which we called "refluxogram" for the purpose of localization of radiolucent renal and ureteral stones during ESWL as an alternative technique for the more invasive retrograde opacification by ordinary ureteral catheters. Our initial experience was quite encouraging and therefore we decided to study further the feasibility and safety of this method in patients with radiolucent stones who already had ureteral stents inserted for other reasons.

Patients and Methods

All patients presenting with radiolucent urinary stones who had an indwelling ureteral stent inserted either for bulky renal stones or ureteral stone impaction were considered for the study. Patients with history of hypersensitivity to contrast media were excluded. Approval of the local ethical committee was obtained. Informed consent was also obtained from all patients. Patients underwent routine investigations namely; urinalysis, urine culture and sensitivity, biochemical workup and imaging by I.V. urography and ultrasonography and computed tomography when necessary. The potential hazards of collecting system opacification through indwelling ureteral stents such as ascending infection and loin and suprapubic discomfort was explained to the patients. Patients with documented bacteriuria were treated by appropriate antibacterials according to urine culture and sensitivity and patients with sterile urine had antibacterial prophylaxis with a single shot 1000 mg. Intravenous ceftazidime. Hundred ml of contrast medium diluted with 500 ml normal saline was infused into the bladder through a Y shaped connection attached to a pre-inserted urethral catheter with the other limb connected to a water manometer for the purpose of continuous intravesical pressure recordings. Patients were protected against loin and suprapubic discomfort by injecting the minimal volume of the contrast medium that is just adequate for localization and at the lowest possible intravesical pressure. X-ray fluoroscopy was performed at intervals until adequate opacification of the collecting system was achieved at which point the amount of infused recorded and further infusion was discontinued. The total fluoroscopy time was also recorded. ESWL was carried out on the Doli Dornier's lithotripter under sedo-analgesia with 50 mg. pethidine and 10 mg. diazepam Post ESWL stone disintegration and clearance after stent removal was verified by ultrasonography, non contrast CT scan and in few cases with retrograde pyelography. All patients had urine culture before leaving hospital and all complications occurring during or after the procedure were recorded. The outcome of stone treatment using this procedure was assessed using the following parameters:

1. Number of ESWL shocks and number of sessions if more than one session was needed.
2. Stone clearance at 3 months following ESWL.
3. Total fluoroscopy time.
4. Complications such as haematuria, septicaemia, loin discomfort, postoperative bacteriuria, dysuria, suprapubic discomfort, hypersensitivity to the contrast medium and any other complications.
5. Mean intravesical pressure and infused contrast volume at which opacification by vesicoureteral reflux occurs.

Results

A total of 46 patients were included in the study, 38 males and 8 females. Mean age was 51+ 16 (range 22 to 90 years) and the mean weight was 81+ 17 Kg (range 53-120). A total of 31 renal stones and 9 ureteral stones were treated and the mean stent duration was 17+ 21 days. Mean fluoroscopy time was 125+ 62 minutes, mean Intravesical pressure was 21+ 9 (range 8-54 cm water and mean contrast volume infused was 295+ 100 ml. (range 150-600 ml.). Mean total duration of ESWL was 54+ 17 min (range 21-100 min). Mean number of sessions was 1.6+ 0.7 (range 1-4) and mean number of shocks was 2963+ 476 (range 1000-4000). Table 1 shows the location of the stones in the urinary tract.

Table 1: Stone location in the urinary tract

Location of the stone	No. (%)
Single renal stone	23 (50)
Multiple renal stones	6 (17.4)
Upper ureteral stone	1 (2.2)
Middle ureteral stone	8 (17.4)
Lower ureteral stone	5 (10.9)
Combined renal and ureteral stones	1 (2.2)

Total	46 (100)

Table 2 shows correlation of stone location with succ Thirty sev [illegible] visualized successfully enough, (Fig. 1 and Fig. 2) to allow shock targeting, 26 renal, 10 ureteral and one combined renal and ureteral stones. All stones that were successfully visualized and targeted were completely cleared at 3 months. Apart from slight suprapubic discomfort which was easily controlled by further sedo-analgesia, non of the patients had serious complications such as contrast hypersensitivity, fever, septicaemia, loin pain, post ESWL dysuria or haematuria.

Table 2: Correlation of stone location with clear localization by refluxogram

Stone Location	Stone visualization Clear	Not clear
Single renal stone	21	2
Multiple renal stones	5	3
Upper ureteral stone	0	1
Middle ureteral stone	5	3
Lower ureteral stone	5	0
Renal and ureteral stones	1	0
Total	37	9

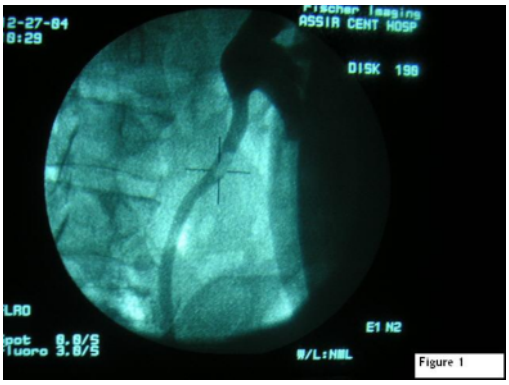

Figure 1: Left upper ureteral stone clearly visualized by refluxogram (stone site is indicated by the cross on the monitor)

Figure 2: Right lower pole renal stone visualized by n the monitor)

Potential Factors influencing clear visualization by refluxogram:

Factors that might influence successful localization were studied namely age, weight, duration of JJ stent, volume of contrast medium injected, intravesical pressure and fluoroscopy time. These were compared in patients who had clear visualization of their stone with those in whom visualization was not clear. None of those potential factors was found to be of significance (Table 3). However, a significantly lower success rate was associated with bacteriuria even if appropriately treated (figure 3).

Table 3: Potential factors that might influence successful localization by refluxogram:

	Quality of localization	Mean	SD	P value
Age (yr)	Clear	51.5	+ 16	0.43
	Not Clear	47	+ 13	
Weight (Kg)	Clear	83	+ 17	0.14
	Not Clear	74	+ 11	
Duration of JJ stent (d)	Clear	18	+ 24	0.82
	Not Clear	16	+ 14	
Volume of contrast injected (ml.)	Clear	296	+ 107	0.90
	Not Clear	291	+ 71	
Intravesical pressure (cm. water)	Clear	21	+ 9	0.83
	Not Clear	20.5	+ 8	
Fluoroscopy time (min)	Clear	126	+ 61	0.83
	Not Clear	121	+ 77	

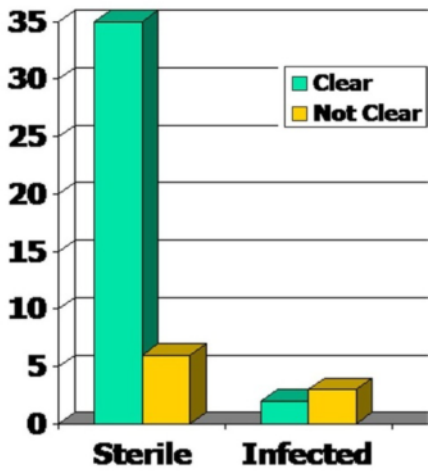

Figure 3: Correlation of urinary infection with clear visualization by refluxogram

Discussion

Successful treatment of urinary calculi can be achieved nowadays by extra-corporeal shock wave lithotripsy in the majority of the cases. Treatment of stones by ESWL requires precise localization of the stone for efficient targeting by shock waves. Localization by fluoroscopy requires contrast medium injection either intravenously or directly into the ureter through pre-inserted catheters. Intrvenous injection produces short- lived opacification and needs to be repeated during ESWL sessions. In severely obstructed kidneys, opacification may be very much delayed, can be very faint or may not occur at all. Direct contrast medium injection is cumbersome and needs endoscopic or percutanous catheter insertion with attendant hazards of aneasthesia and instrumentation. Before ESWL, urinary stone patients, may need JJ ureteral stent insertion as part of the management specially with bulky renal stones and with severe obstruction. Ureteral stents are known to be associated with vesicoureteral reflux in 70% of the cases [8]. This side effect of ureteral stents can be utilized to achieve localization of renal and ureteral stones during ESWL by intravesical instillation of contrast media with certain precautions.

By using this method, we were successful in clear visualization of radiolucent stones during ESWL in 37 out of 46 patients (80%). We were able to target the stones efficiently as evidenced by the complete clearance of the stone fragments during follow up. The total duration of ESWL, fluoroscopy time and total number of shocks were not significantly increased when compared with ESWL for radio-opaque stones. This method was mostly effective in localizing solitary renal stones and lower ureteral stones. Future studies with a larger number of patients may reveal that its efficacy for other stones.

The procedure was not associated with significant complications apart from suprapubic discomfort in some patients. This was easily controlled by sedo-analgesia and by infusing the minimum volume of contrast medium that is adequate for clear opacification of the collecting system. Patients do not feel severe pain because reflux occurs at a mean intravesical pressure of 20 cm. water and with a mean contrast volume of only 300 ml, both of which are well below the maximum detrusor capacity and pressure at micturition. None of the patients had fever or

more than one session of ESWL, localization continued to be successful with repeated sessions.

Since visualization was successful in only 80% of the cases, prediction of success may be important in order not to waste time with patients in whom the procedure will not be successful. We looked into criteria which could predict success but non of them was of help in this regard apart from bacteriuria which was found to be associated with a significantly lower success rate perhaps because of the tendency of encrustation to occur more with infection, which would hinder reflux along the ureteral catheter. For this reason, we would recommend that refluxogram should not be used in the presence of infection.

Conclusions

"Refluxogram" which is the clear image of the collecting system obtained due to reflux of a contrast medium injected intravesically along pre-inserted ureteral stents, can be safely used to localize radiolucent stones in the kidney and the ureter for the purpose of targeting shock waves during ESWL. Its success rate is 80% and can be used repeatedly with multiple ESWL sessions, but it is better avoided in the presence of urinary tract infection.

References

1. Chaussy CG, Schmiedt E. Shock wave treatment for stones in the upper urinary tract. Urol Clin N Am 1983; 10: 743-50
2. Fuchs GJ, Fuchs A. In-bath ultrasound as adjunct for treatment of radiolucent stones with fluoroscopy localization lithotriptors. J Urol part 2 1991; 145: 220A abstract 31
3. Netto NR jr, Claro JFA, Cortado PL. Extracorporeal shock wave lithotripsy of radiolucent urinary calculi using the Siemens lithostar plus. J Urol 1992; 148:1112-13
4. Gschwend J, Miller K, Weber HM et al. Shock wave lithotripsy of ureteral calculi: How efficient is localisation with ultrasound? J Urol 1990 ;143: 247A abstract 234

5. Shabsigh R, Gleeson MJ, Griffith DP. The benefits of stenting on a more-or-less routine basis prior to extracorporeal shock wave lithotripsy. Urol Clin N Amer 1988; 15:493
6. Libby JM, Meacham RB, Griffith DP. The role of silicone ureteral stents in extracorporeal shock wave lithotripsy of large renal calculi. J Urol 1988; 139:15
7. Bhatia V, Biyani CS, Baliga D. Localisation of radiolucent stones in the ureter: extracoil of double pigtail stent as a pointer. Br J Urol 1993; 72: 988-89
8. Mosli HA, Farsi HM, Al-Zimaity MF et al. Vesicoureteral reflux in patients with double pigtail stents. J Urol 1991; 146: 966-69
9. Hubner WA, Plas EG, Stoller ML. The double-J ureteral stent: in vivo and in vitro flow studies. J Urol 1992; 148: 278-80
10. Ramsay JWA, Payne SR, Gosling PT et al. The effects of double J stenting on unobstructed ureters: an experimental and clinical study. Br J Urol 1985; 57: 630-34