Neurol Med Chir (Tokyo) 44, 420～423, 2004

Surgically Treated Aneurysm of the Trunk of the Persistent Primitive Trigeminal Artery

—Case Report—

Takashi TAKASE, Hideki TANABE, Akinori KONDO, Naosuke NONOGUCHI, and Kazuyuki TANE*

*Department of Neurosurgery, Shiroyama Hospital, Brain and Spine Surgery Center, Habikino, Osaka; *Department of Neurosurgery, Tane General Hospital, Osaka*

Abstract

A 62-year-old man presented with a very rare cerebral aneurysm arising from the trunk of the persistent primitive trigeminal artery (PPTA) manifesting as subarachnoid hemorrhage. Angiography showed a saccular aneurysm at the curved mid-section of the trunk of the left PPTA of the adult type. The patient underwent surgery via the left subtemporal approach, and the aneurysm was successfully eliminated by clipping without sequelae. Aneurysm formation at this point was probably due to hemodynamic stress. The perforating arteries from the PPTA may be important in supply of the hindbrain, so PPTA patency should be preserved if possible.

Key words: cerebral aneurysm, persistent primitive trigeminal artery trunk, direct surgical clipping

Introduction

Persistent primitive trigeminal artery (PPTA) is the most common primitive carotid-basilar artery anastomosis with an incidence of approximately 0.2%.[1] Recently, the incidence of intracranial aneurysms in patients with PPTA has been estimated as approximately 3%, quite similar to that in the general population of about 3.7%.[4] Aneurysms of the PPTA or at the junction of the PPTA and the internal carotid or basilar artery are rare, and aneurysms arising from the trunk of the PPTA are very rare. Aneurysms in patients with PPTA commonly arise from the circle of Willis. Only 11 cases of aneurysms on the trunk of the PPTA, mostly saccular, have been reported.[3,5,6,8–11,13,17,18] Seven patients presented with subarachnoid hemorrhage (SAH), including three patients with multiple aneurysms.

We report a case of ruptured PPTA aneurysm at the curved mid-section of its trunk which was surgically eliminated.

Case Report

A 62-year-old man suffered SAH but developed no neurological deficits. Computed tomography showed SAH dominant on the left side of the prepontine cistern (Fig. 1). Left carotid angiography revealed a saccular aneurysm at the curved mid-section of the trunk of the left PPTA. The basilar artery distal to the branching of the anterior inferior cerebellar artery was well opacified through the PPTA (Fig. 2A). Aneurysms of the left internal carotid-anterior choroidal artery and anterior communicating artery were also visualized. Left vertebral angiography showed narrowing of the basilar artery proximal to the junction of the PPTA (Fig. 2B). The right posterior communicating artery was the fetal type, and the A_1 segment of the right anterior cerebral artery was hypoplastic. These findings suggested that the SAH was due to rupture of the PPTA trunk aneurysm.

The patient underwent surgery on the day of admission via a left subtemporal approach. The posterior part of the tentorium was cut and divided to reach the aneurysm. The left superior cerebellar

Received December 15, 2003; Accepted April 6, 2004
Author's present address: T. Takase, M.D., Department of Neurosurgery, Tane General Hospital, Osaka, Japan.

artery was followed proximally to identify the PPTA. This artery gave rise to a perforating branch to the brain stem (Fig. 3A). Further dissection disclosed a saccular aneurysm at the curved mid-section of the PPTA. The aneurysm was successfully clipped and the rupture point was ascertained (Fig. 3B). All other aneurysms were also treated via a left pterional approach, including an aneurysm on the left internal carotid-posterior communicating artery, which was not opacified on the preoperative angiogram. His postoperative course was uneventful and follow-up angiography 5 weeks later disclosed complete elimination of the aneurysms with preserved patency of the PPTA (Fig. 4).

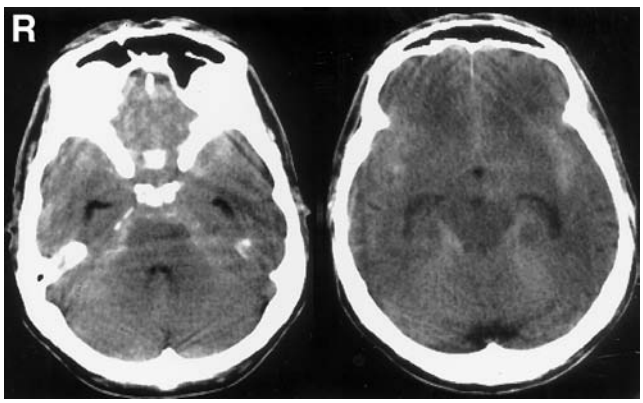

Fig. 1 **Computed tomography scans on admission showing diffuse subarachnoid hemorrhage predominantly on the left side of the prepontine cistern.**

Discussion

Various etiologies for aneurysms arising from the PPTA have been suggested, including dysplasia of the wall of the PPTA, and hemodynamic stress on

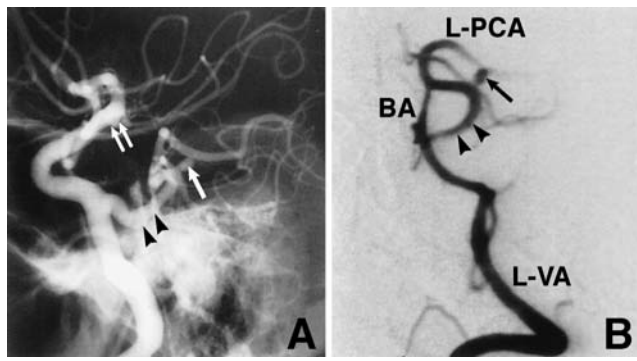

Fig. 2 **A: Left carotid angiogram (lateral view) showing the left persistent primitive trigeminal artery (PPTA; *arrowheads*) with a saccular aneurysm (*arrow*) at the curved mid-section of the trunk. The basilar artery distal to the anterior inferior cerebellar artery was visualized through the PPTA. A left internal carotid-anterior choroidal artery aneurysm was also seen (*double arrow*). B: Left vertebral angiogram (left anterior oblique view) showing stenosis of the basilar artery proximal to the junction of the PPTA (*arrowheads*). BA: basilar artery, L-PCA: left posterior cerebral artery, L-VA: left vertebral artery.**

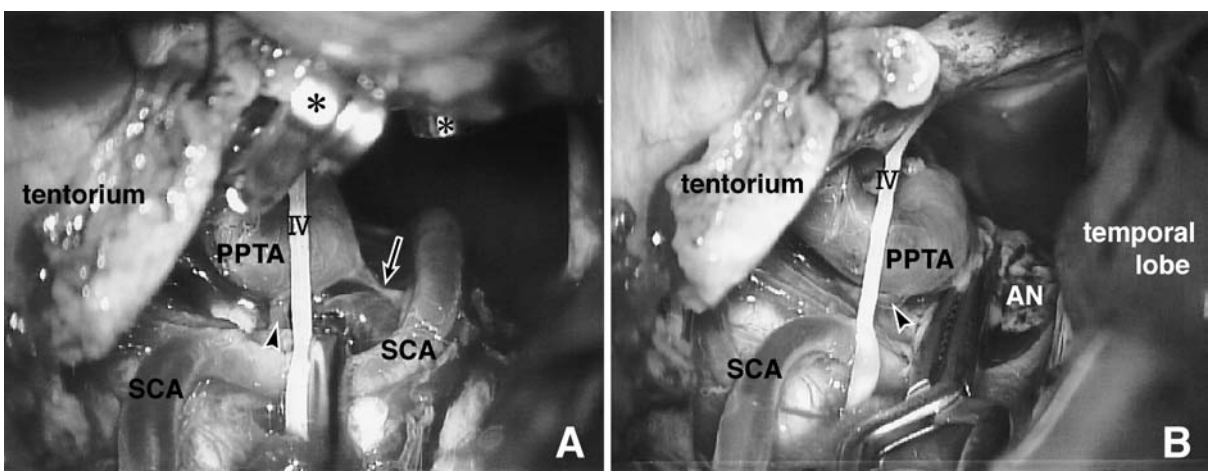

Fig. 3 **Intraoperative microscopic view before (A) and after (B) neck clipping of the aneurysm (AN). *Arrow* indicates the aneurysmal neck. The *arrowhead* indicates a perforating branch to the brain stem. The *asterisks* indicate clips temporarily applied to the persistent primitive trigeminal artery (PPTA) proximal and distal to the aneurysm. IV: left trochlear nerve, SCA: superior cerebellar artery.**

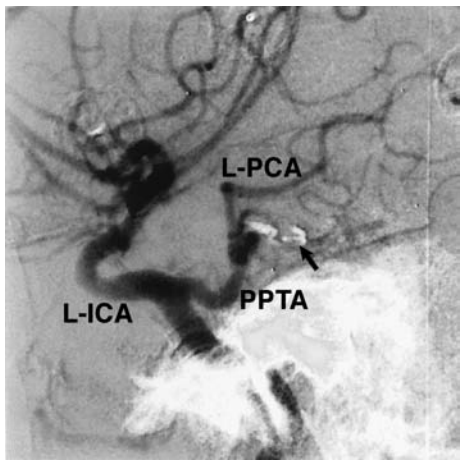

Fig. 4 Left carotid angiogram obtained 5 weeks later revealing complete elimination of the aneurysm with preserved patency of the persistent primitive trigeminal artery (PPTA). The *arrow* indicates the clip. L-ICA: left internal carotid artery, L-PCA: left posterior cerebral artery.

the PPTA.[8-10] Autopsy specimens of PPTA have shown atherosclerotic changes of the arterial wall, more in the proximal than the distal portion to the aneurysm, but histological studies have revealed no evidence of developmental pathological anomalies in the wall of the PPTA.[9] We speculate that the specific hemodynamics of the PPTA, which directly branches and receives significant blood flow from the internal carotid artery, may induce the formation of aneurysms. The site of the aneurysm in our case was the curved trunk of the PPTA, as found in most other reported aneurysms of the PPTA trunk.[3,5,6,8-11,13,17,18] Such characteristic anatomical findings of the aneurysms strongly suggest that high hemodynamic stress initiated aneurysm formation. However, whether small branching arteries from the PPTA at the site of the aneurysm were involved, and any congenital predisposition of the artery walls cannot be excluded because of the multiple aneurysms around the circle of Willis in this case.

Only two aneurysms of the trunk of the PPTA have previously been directly treated, one by direct surgical clipping and one by endovascular treatment.[11,13] Direct surgical clipping of a fusiform-type aneurysm of the PPTA eliminated the aneurysm by angiography but also occluded the PPTA, although the patient tolerated this well.[13] Endovascular treatment had to obliterate the origin of the PPTA together with the aneurysm because of PPTA tortuosity, and the patient's clinical course was unremarkable.[11]

The clinical significance of perforating arteries from the PPTA has not been discussed in reports of the treatment of the PPTA aneurysms. Anatomically, the PPTA can be classified into two variations according to the relationship with the abducens nerve; i.e. the lateral petrosal and medial sphenoid variations.[15,16] The lateral petrosal variation gives rise to perforating branches to the pons.[14,15] Autopsy reports of adult cases of PPTA have described two arterial branches originating from the cisternal portion of the PPTA, an artery supplying the trigeminal nerve root and a perforating artery to the pons, and a branch sending a perforating artery directly into the pons, as well as no finding of perforating arteries.[9,14-16] The pontine branches are very probably functioning vessels in the brain stem and occlusion of the PPTA may cause ischemic lesions in the brain stem.[14]

The two types of PPTA should be considered before sacrifice of the PPTA: the adult-type PPTA (posterior circulation independent of the PPTA), and the fetal type (posterior circulation dependent on the PPTA).[2] Although pontine branches from the trunk of the PPTA were usually found in the brains of 4-, 6-, and 8-month-old fetuses, these arteries are usually occluded before birth.[12] In our case, the PPTA was of the adult type. During surgery, we were not sure whether the perforating artery from the PPTA was clinically significant, so we tried to preserve the patency of the PPTA to prevent ischemic lesions in the brain stem. Although the clinical importance of preserving such arteries remains unsolved, the blood supply of the hindbrain may be maintained via another possible collateral route, such as the posterior communicating artery in the case of adult-type PPTA.[7] In such cases, the perforating arteries from the PPTA may be sacrificed without sequelae.

The present case of a ruptured saccular aneurysm at the curved mid-section of the trunk of the PPTA is very rare, and was successfully treated by direct surgical clipping. Hemodynamic stress delivered directly from the carotid artery may have accelerated the formation of this aneurysm, but congenital disposition could not be eliminated since this patient also had multiple aneurysms around the circle of Willis.

References

1) Agnoli AL: Vascular anomalies and subarachnoid haemorrhage associated with persisting embryonic vessels. *Acta Neurochir* (*Wien*) 60: 183–199, 1982
2) Ahmad I, Tominaga T, Suzuki M, Ogawa A, Yoshimoto T: Primitive trigeminal artery associated with cavernous aneurysm: case report. *Surg Neurol*

41: 75–79, 1994
3) Brockhoff V, Tiwisina T: [Aneurysm of the arteria primitiva trigemina persistens as a rare cause of spontaneous subarachnoid hemorrhage]. *Zentralbl Neurochir* 26: 295–302, 1965 (Ger)
4) Cloft HJ, Razack N, Kallmes DF: Prevalence of cerebral aneurysms in patients with persistent primitive trigeminal artery. *J Neurosurg* 90: 865–867, 1999
5) Djindjian R, Hurth M, Bories J, Brunet P: [The primitive trigeminal artery. (Arteriographic aspects and significance apropos of 12 cases)]. *Presse Med* 73: 2905–2910, 1965 (Fre)
6) Eggers FM, Tomsick TA, Chambers AA, Lukin RR: Aneurysms of persistent trigeminal arteries. Report of two cases. *Neuroradiology* 24: 65–66, 1982
7) Enomoto T, Sato A, Maki Y: Carotid-cavernous sinus fistula caused by rupture of a primitive trigeminal artery aneurysm. Case report. *J Neurosurg* 46: 373–376, 1977
8) Freitas PE, Aquini MG, Chemale I: Persistent primitive trigeminal artery aneurysm. *Surg Neurol* 26: 373–374, 1986
9) Fujii Y, Kawasaki S, Abe H, Yamada M, Yoshida Y: [An autopsy case of a persistent primitive trigeminal artery aneurysm]. *No Shinkei Geka* 16: 181–186, 1988 (Jpn, with Eng abstract)
10) George AE, Lin JP, Morantz RA: Intracranial aneurysm on a persistent primitive trigeminal artery. Case report. *J Neurosurg* 35: 601–604, 1971
11) Hanabusa K, Murao K, Morikawa A, Taki W, Waga S: Endovascular treatment for a ruptured persistent trigeminal artery variant aneurysm on the distal portion — case report. *Neurol Med Chir (Tokyo)* 40: 637–640, 2000
12) Khodadad G: Persistent trigeminal artery in the fetus. *Radiology* 121: 653–656, 1976
13) Morrison G, Hegarty WM, Brausch CC, Castele TJ, White RJ: Direct surgical obliteration of a persistent trigeminal artery aneurysm. Case report. *J Neurosurg* 39: 249–251, 1974
14) Ohshiro S, Inoue T, Hamada Y, Matsuno H: Branches of the persistent primitive trigeminal artery — an autopsy case. *Neurosurgery* 32: 144–148, 1993
15) Salas E, Ziyal IM, Sekhar LN, Wright DC: Persistent trigeminal artery: an anatomic study. *Neurosurgery* 43: 557–562, 1998
16) Suttner N, Mura J, Tedeschi H, Ferreira MA, Wen HT, de Oliveira E, Rhoton AL Jr: Persistent trigeminal artery: a unique anatomic specimen — analysis and therapeutic implications. *Neurosurgery* 47: 428–433, 2000
17) Tomsick TA, Lukin RR, Chambers AA: Persistent trigeminal artery: unusual associated abnormalities. *Neuroradiology* 17: 253–257, 1979
18) Wolpert SM: The trigeminal artery and associated aneurysms. *Neurology* 16: 610–614, 1966

Address reprint requests to: T. Takase, M.D., Department of Neurosurgery, Tane General Hospital, 1-2-31 Sakaigawa, Nishi-ku, Osaka 550-0024, Japan.
e-mail: neu031@poh.osaka-med.ac.jp