JCN Open Access LETTER TO THE EDITOR

pISSN 1738-6586 / eISSN 2005-5013 / J Clin Neurol 2016;12(4):517-518 / http://dx.doi.org/10.3988/jcn.2016.12.4.517

A Nonpregnant Woman with Group B Streptococcal Meningitis and Multifocal Embolic Infarctions

Doo Yong Park
Su Bin Lee
Do Young Yoon
Jee Young Kim

Department of Neurology,
Seonam University College of Medicine,
Myongji Hospital, Goyang, Korea

Dear Editor,

A 60-year-old woman presented with the sudden onset of altered mental status, headache, and fever (37.7°C). A few days previously she had been diagnosed with spinal stenosis and received several intramuscular (i.m.) injections for pain relief around the back and buttock at another pain clinic. A physical examination revealed violaceous skin lesions around the injection site (Fig. 1A). Stuporous mentality and neck stiffness were noted. The extremities withdrew symmetrically to painful stimuli, deep tendon reflexes were symmetrically normoactive, and Babinski's sign was not observed. Laboratory tests showed elevated C-reactive protein (>30.34 mg/dL) and serum creatine kinase (303 IU/L). The findings of a chest X-ray and brain computed tomography (CT) without contrast agent were unremarkable. A lumbar puncture showed an opening pressure of 200 mmH_2O. In her cerebrospinal fluid (CSF), the cell count was 921 cells/mm^3 (comprising 82% polymorphonuclear leukocytes), the glucose level was 16 mg/dL (173 mg/dL in plasma), and the protein level was 245.7 mg/dL. Diffusion-weighted brain magnetic resonance imaging (MRI) revealed diffusion restrictions in the right anteroinferior cerebellum, superior vermis to superior cerebellum, left hippocampus, right inferior frontal gyral cortex, right superior parietal lobular cortex, and bilateral high frontoparietal cortices (Fig. 1B-E). Additionally, diffuse leptomeningeal enhancement was observed along both cerebral cortical sulci. These findings were compatible with meningitis and acute multifocal embolic infarctions. The findings of spine MRI and transthoracic echocardiography were insignificant.

Intravenous (i.v.) dexamethasone and high-dose broad-spectrum antibiotics (ceftriaxone, vancomycin, and ampicillin) were started. *Streptococcus agalactiae* was isolated from cultured CSF, blood, and urine 3 days later. Her mental status improved, but she showed intermittent confusion, gait ataxia, and left-arm weakness. Her fever and back pain did not improve. After 15 days we performed abdomen and pelvis CT with contrast agent and lumbar spine MRI to identify other causes of fever and back pain. The CT revealed severe pyelonephritis bilaterally and multiple abscesses of the right psoas and left gluteus maximus muscles (Fig. 1F, G, and H). The spine MRI showed infectious spondylitis of the lumbar third and fourth vertebral bodies and increased leptomeningeal enhancement (Fig. 1I). We changed the antibiotics to imipenem and ampicillin, debrided necrotic tissues, and introduced a vacuum-drainage catheter into the gluteal abscess. Follow-up brain and spine MRI at 6 weeks showed improvement in meningitis and infectious spondylitis. Her health gradually improved over a long period (>4 months) with the administration of high-dose i.v. antibiotics and surgical management.

Group B Streptococcal (GBS) was known to be a leading pathogen underlying neonatal sepsis, pneumonia, and meningitis in developing countries during the 1970s.[1] Although neonatal GBS diseases have declined, the rate of invasive GBS disease in adults is increasing, especially in elderly persons with underlying chronic diseases including diabetes mellitus

Received February 22, 2016
Revised May 17, 2016
Accepted May 19, 2016

Correspondence
Jee Young Kim, MD, PhD
Department of Neurology,
Seonam University College of Medicine,
Myongji Hospital,
55 Hwasu-ro 14beon-gil, Deogyang-gu,
Goyang 10475, Korea
Tel +81-31-810-6130
Fax +81-31-969-0500
E-mail nrkjy55@gmail.com

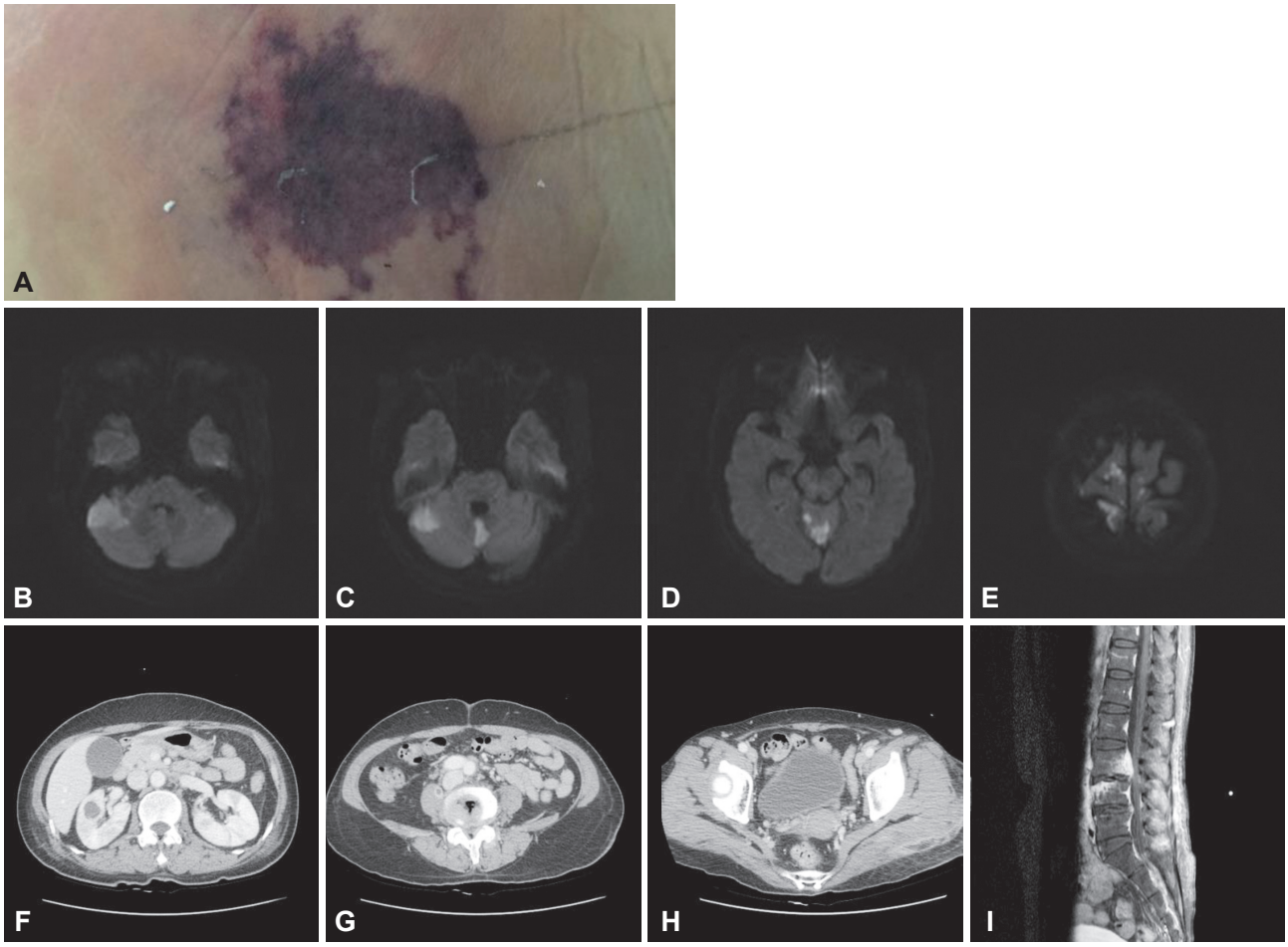

Fig. 1. Skin lesion and radiological images of the 60-year-old patient. A: Violaceous macule around the injection site. B-E: Diffusion-weighted brain MRI showed diffusion restrictions at right anteroinferior cerebellum, superior vermis to superior cerebellum, left hippocampus, right inferior frontal gyral cortex, right superior parietal lobular cortex and bilateral high frontoparietal cortices. F, G, and H: Abdomen-pelvic CT showed pyelonephritis in the both kidneys and perimuscular abcess, posterior to the left gluteus maximus associated with diffuse fasciitis and subcutaneous infection. Also, small abscess was observed in right psoas muscle. I: L-spine MRI revealed infectious spondylitis, 3rd–4th lumbar vertebral bodies with infection of facet joints.

(DM), liver cirrhosis (LC), stroke history, and cancer.[1,2] A previous Korean study found that GBS bacteremia was more common in those aged >50 years with DM, LC, and solid tumors.[3] There are various clinical manifestations of invasive GBS infection in adults, including bacteremia, skin or soft-tissue infection, pneumonia, and bone and joint infections.[2,3] GBS meningitis is an uncommon manifestation of invasive GBS disease in adults, but it has a high mortality rate (27–34%).[2] One case of infective endocarditis and meningitis caused by GBS has been reported in Korea.[4] However, to the best of our knowledge there has been no report of GBS meningitis and multifocal embolic infarctions associated with skin and soft-tissue infection in Korea. The present case was a previously healthy woman who developed necrotizing skin and soft-tissue infection after i.m. injections that was complicated by invasive and disseminated GBS infections including bacteremia, meningitis, spondylitis, and pyelonephritis. The disseminated GBS disease in this case was possibly attributable to the soft-tissue infection at the site of i.m. injections. Such soft-tissue infection could be prevented if medical providers perform a procedure carefully and offer a meticulous follow-up. This case suggests that medical providers should be aware of this complication and take suitable precautions.

REFERENCES

1. Johri AK, Lata H, Yadav P, Dua M, Yang Y, Xu X, et al. Epidemiology of Group B Streptococcus in developing countries. *Vaccine* 2013;31 Suppl 4:D43-D45.
2. Farley MM. Group B streptococcal disease in nonpregnant adults. *Clin Infect Dis* 2001;33:556-561.
3. Lee MS, Bae IG, Kim EO, Kim YS, Woo JH, Kim MN, et al. Characteristics of group B Streptococcal bacteremia in non-pregnant adults and neonates. *Korean J Infect Dis* 2000;32:49-54.
4. Lee JY, Kim HA, Kim HS, Ryu SY. A case of infective endocarditis and meningitis caused by Streptococcus agalactiae. *Korean J Med* 2013;85:435-438.