

Impaction of right dorsal colon in the horse: report of 32 cases

J. MEZEROVÁ, R. KABEŠ, Z. ŽERT, P. JAHN, J. HANÁK

University of Veterinary and Pharmaceutical Sciences, Brno, Czech Republic

ABSTRACT: Acute as well as chronic and recurrent colic episodes were caused by right dorsal colon (RDC) impaction in 7.98% of all colic patients. Significantly higher statistical evidence was figured out in hucul horses, mares and 7-year-old animals. Diagnosis of RDC impaction was established on the basis of rectal palpation (68.75%) or laparotomy (31.25%). Yield of rectal palpation was limited by a difficult accessibility of RDC, small body frame of the animal, severe abdominal pain and by further physiological or pathological changes in abdominal cavity. Simple RDC impaction was diagnosed in 16 (50%) of 32 cases, in 9 horses the impaction associated with the large colon displacement or torsion. In 4 horses also small colon impaction together with RDC impaction and in 3 horses impaction of another GIT part were found. Clinical signs of disease were influenced by these pathological findings. In two cases the diagnosis sand impaction was established during laparotomy. RDC impaction was treated conservatively in some patients (28.13%), however in most patients surgery was needed (65.63%). Conservative therapy was successful in the horses with short duration of disease and in cases, where the RDC impaction was the only pathological finding without associated complications. As indicators for surgery were chronic course of disease, high degree of general health alteration, severe abdominal pain with no reaction to analgesics, cases where the strangulation could not be excluded by rectal palpation or another lesions that cannot be treated conservatively and/or unsuccessful conservative therapy. The surgery was used in 21 cases (65.63%). 17 patients recovered from anaesthesia, 1 horse was destroyed in 14 days due to the repeated impaction. Complications, that were associated with surgery in the group of patients with RDC impaction, occur also during surgical treatment in all type of colic patients. In 2 mares the abortion occurred, in 3 horses the convalescence time have been complicated by diarrhoea, and in 1 horse by acute laminitis. Surgical wound infection was a cause of ventral hernia in 1 horse. 25 horses from all 32 cases hospitalised and treated either conservatively or surgically were passed to home care (78.12%). On the basis of obtained results there is possible to evaluate the prognosis in patients with acute and simple impaction as favourable and in patients in which the disease was complicated by further pathology as obscured. Chronic recurrent impaction was diagnosed repeatedly (3×) in one horse, that did not respond to the conservative treatment and surgery provided the only short time solution. Therefore the prognosis in this case was evaluated as not advanced.

Keywords: horse; colic; right dorsal colon; treatment

INTRODUCTION

Impaction of the ascending colon is often a cause of colic in the horse. Clinical signs, diagnosis, therapy and prognosis depend on the location of impaction in the large colon. Mild abdominal pain, no general health alteration, a successful result of conservative treatment and a good prognosis mostly attend the ventral colon and pelvic flexure impactions. Impaction of the right dorsal colon (RDC impaction) may be accompanied by severe abdominal pain and high degree of general health alteration. In significant number of patients the conservative therapy is unsuccessful and surgical treatment is the only solution. Some cases of RDC impaction do not have signs of acute colic but can suffer by chronic and relapsing disease, however. The specific category of constipation is a sand impaction as RDC is supposed to be a place predisposed for the sand accumulation and the enterolith localisation

(Specht and Colahan, 1988; Sullins, 1990). Moreover the RDC impaction is not only the simple colic disease. It can be complicated by the large colon displacement and torsion in some patients (Hackett, 1983; Sullins, 1990; White and Dabareiner, 1997; Huskamp *et al.*, 1999, etc.).

The frequency of impactions is high and many studies of ascending colon constipation were published. Unfortunately we did not record any study that would summarise higher number of patients with RDC impaction until now.

The aim of the presented clinical study was to evaluate a frequency of RDC impaction occurrence as well as breed, gender and age predilection, consider the diagnostic approach and to identify another disorders that can be found simultaneously. We tried to find out any criteria for the decision of conservative or surgical treatment and to evaluate the results of the treatment and prognosis.

MATERIAL AND METHODS

Cases with RDC impaction were selected from the group of colic patients that were treated at our clinic between 1st October 1994 and 31st December 1999. Diagnosis was established by the clinical examination or during the laparotomy in these patients.

All patients were clinically examined immediately after their arrival to the clinic. The modified examination procedure described by Huskamp and Kopf (1978) was used. Data of the history included an information on previous colic diseases, previous abdominal surgeries, duration of disease, degree of abdominal pain and treatment used before arrival.

The intensity of abdominal pain, heart rate, colour of conjunctiva and mucous membranes, peristalsis, abdominal distension, sweating and the results of rectal examination were evaluated during the initial clinical examination.

The parameters that can be expressed numerically were characterised by range of values, arithmetical average, standard deviation and medians. The routine classification was used for other parameters such as intensity of abdominal pain, peristalsis, abdominal distension, sweating, colour of conjunctiva and mucous membranes (Table 1). On the base of rectal palpation (Kopf and Huskamp, 1978; Huskamp and Kopf, 1995) the preliminary clinical diagnosis was established with following possibilities: 1. simple RDC impaction, 2. RDC impaction complicated by colonic displacement and 3. displacement of colon or 4. constipation of the cecum body. If the rectal palpation did not reveal any pathological finding, the clinical diagnosis was not closed. In 4 horses the rectal palpation was not possible because of small body frame or very severe abdominal pain.

Patients, in which history and results of initial clinical examination did not indicate the necessity for the surgical intervention, intensive conservative treatment with monitoring of general health conditions was introduced. Following signs indicated prompt exploratory surgery: increasing intensity of the abdominal pains none or short response to analgetics or sedatives and serious general health alterations.

Horses with RDC impaction were compared to all colic in-patients for the evaluation of the breed, age and gender predilection.

The effectiveness of diagnostics was evaluated on the basis of rectal palpation results. In cases where surgery was needed, the rectal and laparotomy findings were compared to evaluate the reliability of rectal palpation in diagnostics.

Identification of pathological states, that can be associated with the RDC impaction, was established from laparotomy findings analysis.

All patients were divided into two groups according to the mode of the treatment in order to assess the data of history and results of clinical examination that indicate

conservative or surgical treatment. The horses treated conservatively only were classified as a group I. Patients that were treated surgically was classified as a group II. The group II was further divided into group IIa (horses treated surgically immediately after initial clinical examination) and group IIb (horses treated surgically after unsuccessful initial conservative treatment). The history and results of clinical examination were evaluated to find parameters common for horses of each group. In the group IIb beside of all parameters of the general health alteration at the time of arrival also the changes that had occurred during the conservative therapy were evaluated. A horse that died before the treatment was not inserted into any group.

All complications accompanying the therapy were registered in patients of all groups.

Prognosis of RDC impaction was expressed by percentage of successfully treated horses that left our clinic for a home care.

For the statistical evaluation of breed, gender and age predisposition to the RDC impaction we used χ^2 -test (Anděl, 1985).

RESULTS

Total number of 2 688 horses was treated (out- and in-patients) at our clinic from 1st October 1994 to 31st December 1999. 401 horses (14.92%) were treated because of colic. The RDC impaction was identified by clinical examination or laparotomy in 32 cases (7.78% of all colic patients), which represented 30 horses. One of these horses was hospitalised three times.

The different breeds of horses with RDC impaction and their comparison with all colic patients are shown in Figure 1. Relation between breed and RDC impaction was not proved. Quotient of Hucul horse in the group of all horses was of high statistical significance ($\chi^2 = 25.373$; $P < 0.01$).

The mares predominated in the group of horses with RDC impaction. The same situation was found in the group of all horses with colic disease (Figure 2). Higher occurrence of RDC impaction in mares was of statistical significance, if we took stallions and geldings into one group together ($\chi^2 = 4.69$; $P < 0.05$).

The age range of all horses with colic (401 horses) was from 1 day to 25 years (average 6.29 ± 4.39 , median 5). The age range of patients with RDC impaction was from 6 weeks to 18 years (average 6.22 ± 4.03 , median 5.5) as demonstrated in Figure 3. Statistical evaluation did not prove any dependence of age on prevalence of RDC impaction. Only the group of 7-year-old horses had significantly higher prevalence of RDC impaction than in other colics ($\chi^2 = 5.43$; $P < 0.05$).

Ten horses (group I) from all 32 cases with RDC impaction were treated conservatively. The indication for

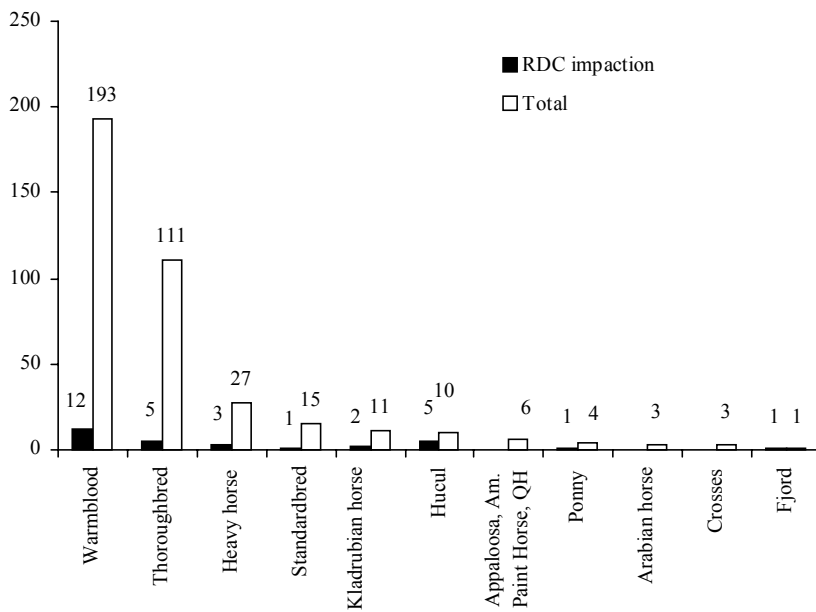


Figure 1. Breed relevancy in all colic patients and those with RDC impaction

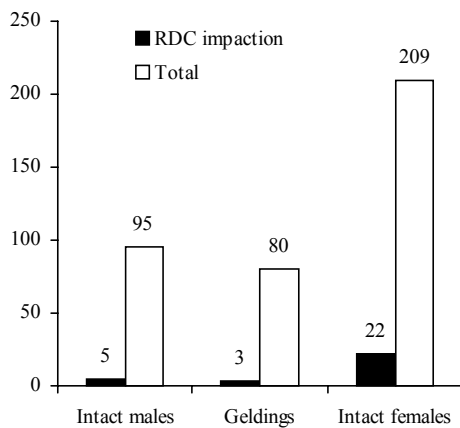


Figure 2. Gender relevancy in all colic patients and patients with RDC impaction

surgery was found in 21 cases (group II) either after initial clinical examination (IIa – 8 horses) or during unsuccessful conservative treatment (IIb – 13 horses).

One horse, in which massive RDC impaction was found, died for intestine rupture before the therapy could start. The duration of disease and results of clinical examination in groups I, IIa and IIb are shown in Table 1.

There was not possible to evaluate statistically these clinical parameters because of small numbers of patients in these groups.

The group I was characterised by the short disease duration and none or small alteration of clinical parameters. The most expressive and most often general health alterations were found in group IIa. The course of disease was generally acute although repeated colic episodes during last 3 months were mentioned in the history of one patient.

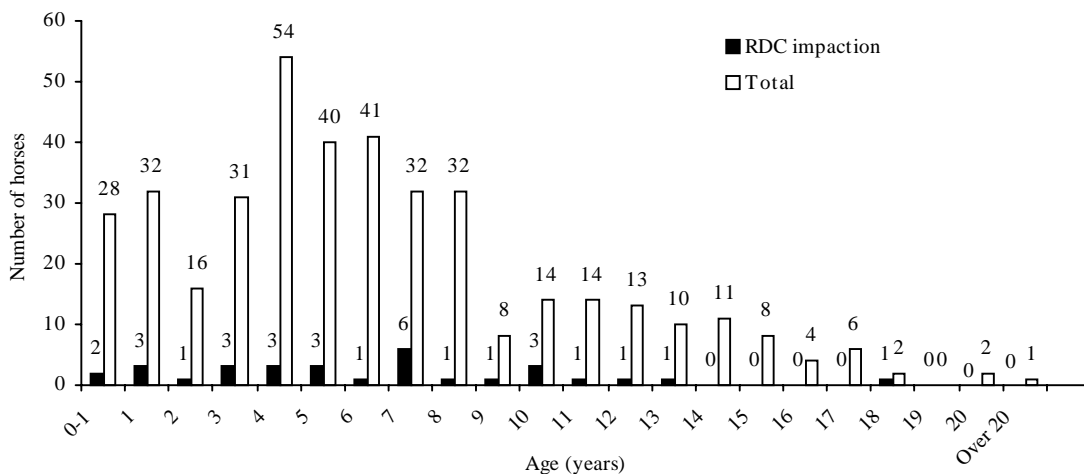


Figure 3. The age range of horses with colic and RDC impaction

Table 1. Duration of disease and results of initial clinical examination in all groups of patients

	Conservative treatment		Surgical treatment	
	group I (n = 10)		group IIa (n = 8)	group IIb (n = 13)
Duration of the disease (hours)	16.55 ± 19.05 median 11		18.06 ± 5.41 median 17	53.92 ± 85.05 median 24
Heart rate	52.40 ± 9.37 median 53		74.63 ± 18.09 median 80	61.50 ± 19.85 median 58
Intensity of the colic				
None	7		0	7
Mild	3		3	3
Intermediate	0		2	1
Severe	0		3	2
Peristalsis				
Functional	3		0	4
Decreased (left side + right side + both sides)	1 + 6		2 + 0 + 0	1 + 1 + 7
Stopped (left side + right side + both sides)	0		2 + 0 + 4	0 + 0 + 0
Abdominal distension				
Not evident	8		3	9
Mild	0		2	2
Evident (right side)	1		0	0
Evident (bilateral)	1		3	2
Conjunctiva				
Anemic	0		0	0
Pink	9		3	9
Red	1		2	2
Violet	0		3	0
Subicteric	0		0	2
Mucous membranes				
Anemic	0		0	0
Pink	9		4	10
Red	1		2	0
Cyanotic	0		2	0
Subicteric	0		0	3
Body surface				
Dry	10		7	10
Mild sweating	0		0	0
Sweating	0		1	3
Sweating, cold periphery	0		0	0

As evident from Table 1 there is a large variability of the disease duration in the group IIb. The patient with chronic 14-days course of disease and the second one with relapse of RDC impaction caused this fact.

The rectal palpation revealed the RDC impaction in all patients of the group I. In five of them the impaction was accompanied by distension of the left colon.

The rectal palpation was possible to perform in six horses from eight horses of the group IIa. The simple RDC

impaction was found out in 2 cases. In 3 horses RDC impaction was found together with the large colon displacement. In one horse the large colon displacement was established as a single clinical diagnosis.

In group IIb eleven horses from 13 were rectally palpated. In 5 cases (3 horses) RDC impaction was found, in one horse small colon impaction was found simultaneously with RDC impaction. In 2 horses strongly dilated and displaced large colon could be palpated only. In

Table 2. The overview of rectal and laparotomic findings in treated horses

Number	Rectal finding	Laparotomic (pathological finding)
3	negative	sand impaction RDC
7	IRDC	–
29	IRDC	–
34	IRDC	–
52	–	IRDC, (impaction of small colon)
67	IRDC	IRDC, torsion of large colon
92	IRDC, distension of large colon and cecum	–
101	IRDC	IRDC, partial torsion of large colon
115	dislokace kolonu	IRDC, ventroflexion of pelvic flexure
128	–	IRDC and small colon impaction
160	IRDC	IRDC
167	IRDC, distension of large colon and cecum	–
199	IRDC, tumor ?	(IRDC, rupture of the intestinal wall)
203	IRDC and small colon impaction	IRDC and small colon impaction
205	large colon displacement	IRDC, partial torsion of large colon
207	IRDC, large colon displacement	IRDC, ILDC
211	IRDC, distension of large colon and cecum	–
236	large colon displacement	IRDC, ventroflexion of pelvic flexure
239	–	IRDC, right displacement of large colon
250	IRDC	IRDC
259	–	IRDC, small colon impaction
261	IRDC, large colon displacement	IRDC, right displacement
277	IRDC, ILDC, distension of large colon and cecum	–
278	IRDC	IRDC
300	IRDC	–
316	negative	IRDC
321	cecum impaction	IRDC, ventroflexion of pelvic flexure
326	IRDC, enterolith ?	IRDC
347	–	–
350	IRDC, mild large colon and cecum distension	–
379	IRDC, large colon displacement	IRDC, partial large colon torsion
393	IRDC	sand impaction of RDK and pelvic flexure, gastric overfilling

IRDC = impaction of RDC, ILDC = impaction of left dorsal colon; pathological diagnoses in brackets

one horse a resistance was palpated only and incorrectly considered as an impaction of cecum. In 2 horses the results of rectal palpation were scored as negative.

The overview of rectal findings in 28 cases is available in Table 2. On the basis of surgical (laparotomic) findings in this table the yield of rectal palpation for RDC impaction diagnosis can be evaluated. In 22 (78.57%) of 28 horses the RDC impaction was rectally identified and in some cases also the other pathological finding. In 6 (21.43%) of all examined horses the diagnosis was not established. In our group of 32 horses the diagnosis – impaction of RDC – was established by rectal palpation in 68.75% patients.

The clinical diagnosis (surgical, pathological) impaction (sand colic) of RDC was determined as the only reason of colic in 16 (50%) horses out of 32 cases. The RDC impaction was associated with the impaction of another part of the large colon in 3 horses, small colon impaction in 4 horses and displacement or torsion of the large colon in 9 horses (Table 2).

Ten horses were treated conservatively only. One of them was euthanized during the therapy because of decision of its owner. The therapy was successful in 9 cases. The RDC impaction was not complicated in these horses.

The surgical treatment was indicated in 21 cases (65.63%) and the surgery went through in all of them. Two horses died because of sudden cardiac failure im-

mediately after surgery and another one after two hours. One mare was euthanized because of myopathy in 4 hours after surgery. Altogether 17 horses (80.95%) recovered from the anaesthesia. One horse was euthanized because of resistance was repeatedly found in the area of RDC during two weeks after surgery. Two pregnant mares aborted during 15 and 25 hours, respectively, after surgery. In one horse acute laminitis of front legs was diagnosed, that caused a mild rotation of hoof bones. In 3 horses the post operation period was complicated by diarrhoea. In one horse the incision infection caused a large ventral hernia.

25 patients from 32 in-patients and 31 cases treated surgically or conservatively were cured (i.e. 78.12% and 80.65%, respectively). Conservative treatment of 10 horses was successful in 9 of them. It means 90% success in cases, which this therapy was indicated for, and 28.13% success of conservative therapy in the group of all patients.

Sixteen horses from 21 cases (76.19%) which the surgical treatment was used in cured. One mare underwent surgery as 8.5 month pregnant and she gave birth to a healthy foal in time.

DISCUSSION

The comparison of our results with results of other authors is difficult as we did not find any similar study in larger number of animals regarding the RDC impaction.

We have proved higher statistical conclusive evidence for occurrence of RDC impaction in Hucul horse. We assume that the specific way of breeding and feeding of these horses cause the higher number of Hucul horses in our group. Hucul is considered to be a hard and unpretending breed of horse, but a lot of laic owners are misapplying this.

Mares had significantly higher share in the group of horses with RDC impaction. Dabareiner and White (1995) also mentioned this fact but no reliable explanation exists. Mares in our group were used for sport riding or working in the same way like geldings and colts. Therefore we can exclude influence of differences in feeding, keeping or exercise, that can be considered in comparison between breeding animals and horses in training.

Age of horses with RDC impaction was not significantly different from all colic patients. We can conclude from acquired data that horses of any age can suffer from this disease, however. We have found statistical significant evidence for higher susceptibility in 7-year-old horses. These our results agree with average age of group of horses with large colon impaction, that was analysed by Dabareiner and White (1995).

In all our patients of the age of 1-year or younger the RDC impaction was associated with the small colon impaction. According to our experience and literature data (Vatistas *et al.*, 1996; Cable *et al.*, 1997), the small colon impactions are on the contrary of the large colon (esp.

RDC) impactions often a reason for the surgery in these age categories.

The horses were included into the RDC impaction group on the base rectal examination or the finding during laparotomy. We can not forget the contingency mentioned by White and Dabareiner (1997), that there is the possibility of the negative rectal finding in some horses with the RDC impaction. Since there are some horses with “opened diagnosis” in our group of patients that were successfully treated conservatively using infusions we can not exclude that the number of horses with the RDC impaction was in fact higher.

RDC impaction in 9 horses treated surgically was accompanied by complete or incomplete large colon torsion, right dorsal displacement of the large colon and ventroflexion of the pelvic flexure. Our findings agree with the results of other authors (Hackett, 1983; Specht and Colahan, 1988; Ragle *et al.*, 1989; Mealey *et al.*, 1995; Huskamp *et al.*, 1999, etc.) who consider the ascending colon displacement as a consequence and complication of RDC impaction.

The connection between RDC and small colon impactions is not clear up so far. It can not be claimed that one condition is the complication of the other. We can not suppose also that the occurrence of both problems together is only circumstantial. Dart *et al.* (1992) and Edwards (1992) described groups of horses with the small colon impaction but they did not refer about accompanying large colon impaction in any patient.

The aetiology of RDC impaction as well as the small colon impaction can be the same and both these disorders can originate in the same time independently. On the other hand every horse younger than 1 year suffering by RDC impaction had the small colon impaction simultaneously in the group of our patients. The small colon impaction is more often the cause of colic in comparison with the large colon impaction in this age category. One can conclude that the small colon obstruction is a primary problem and the accumulation of ingest in RDC occurs secondarily because of intestine motility disorders.

The diagnosis RDC constipation was specified as the sand impaction in 2 of 32 cases during the laparotomy. We did not find the sand impaction of another part of gastrointestinal tract in any horse treated surgically. This agrees with the literature data (Colahan, 1987; Specht and Colahan, 1988; Ragle *et al.*, 1989; Hammock *et al.*, 1998), where the right colon is considered to be a pre-disposed place for the sand accumulation.

In three patients the RDC impaction was a cause of chronic disease, that was not diagnosed for a few weeks. Two mares died before the start of the treatment or immediately after surgery, respectively. Therefore the recurrent character of the impaction in these horses can not be discussed. The last stallion was hospitalised because of RDC impaction that needed the surgery three times. Before the second and third surgery this horse underwent

the intensive conservative treatment. On the base of this finding we can agree with claiming of German authors (Huskamp *et al.*, 1999), that there is no chance to treat horses with the chronic recurrent impaction conservatively and repeated surgery during which the material from colon is evacuated is only transient solution.

There are several surgical methods described for the treatment of chronic caecal impaction (Scheidemann, 1997; Huskamp *et al.*, 1999) but we noted none for the chronic RDC impaction. During the last surgery of stallion we tried to make a bypass between the right dorsal and small colon. Andrews and Robertson (1988) described this method for successful treatment of patient with chronic RDC obstruction. We incised the intestine wall in a place where no macroscopic fibrous changes were seen. The connection in the length of 30 cm between the large and small colon was not functional enough to enable ingest to pass through and the accumulation in RDC resulted, however.

The differences between clinical diagnosis and surgery findings in our patients advert to diagnostic problems described by other authors (Huskamp and Kopf, 1995; White and Dabareiner, 1997; Huskamp *et al.*, 1999, etc.). Strong abdominal pain and small body frame complicate the rectal palpation and diagnostics in many colic diseases. In the case of RDC impaction also a large body frame is a difficulty for rectal palpation. RDC can not be sometimes reached as well as because of gas accumulation in large intestine associated with impaction or because of pregnant uterus.

We can conclude from the evaluation of our group of horses that RDC impaction requires relatively often surgical therapy. Data of history and results of initial clinical examination were used to evaluate the general health alteration and select between immediate surgery or conservative therapy. Changes in clinical parameters such as repeating abdominal pain and failure of conservative therapy were the main indicators for the need of later surgery.

In two patients with a history of recurrent colics the surgery was chosen as a way of treatment immediately. In one of them we have found RDC sand impaction. Intermittent colics responding to analgesics are considered to be a characteristic sign of sand impaction by Sullins (1990). On the contrary Specht and Colahan (1988) did not notice any foregoing episodes of abdominal discomfort in most of their patients with the sand impaction. In the second horse of our group the clinical examination proved massive RDC impaction but could not exclude a pertinent enterolithiasis or tumour.

The history of disease duration in association with evaluation of general health alteration and conservative treatment is the useful indicators for surgery. Huskamp *et al.* (1999) considers horses with prolonged RDC impaction as often candidates for surgery. We can confirm his opinion, evaluating animals with the only simple impaction.

In cases when impacted RDC is the only pathological rectal finding it is possible to presume that elongation of disease duration decreases the chance for successful conservative therapy. Short duration of disease could be taken as an indicator for the conservative treatment. This fact is insignificant in cases where RDC impaction is associated with the large colon displacement or small colon impaction. Even short time course of disease but high intensity of abdominal pain, alteration of general health and only a slight response to analgesics are indicators for the surgical treatment.

The intensity of abdominal pain indicated with certain limitations either surgery or conservative treatment. There was possible to use the conservative therapy in cases when horses showed no signs of abdominal pain and rectal palpation exposed impaction or dislocation of the colon. The same situation was found in the cases of abdominal pain of mild intensity reacting to small doses of analgesics or sedatives. Several authors (Specht and Colahan, 1988; Peloso *et al.*, 1992; Parks, 1996) published the similar results. The surgical revision of abdominal cavity was indicated by the acute pain with no reaction to analgesics as well as mild or intermittent signs of abdominal discomfort connected with negative results of rectal palpation or chronic and recurrent course of disease.

The heart rate and colour of conjunctiva and mucous membranes evaluated the degree of cardiovascular system alteration. In spite of higher average of heart rate in surgically treated horses, this result can not be used in decision for the best way of therapy. Extensive heart rate range in surgical patients was caused not only by physiologic differences between a few weeks old foals and adult horses but also by different character of the disease in groups of horses (simple impaction, impaction associated with displacement). Low heart rate is not necessary an indicator of good prognosis as a mare with physiologic values of heart rate just before sudden death was in the group of our patients.

The most important parameter for a way of therapy decision was the result of rectal palpation. In all conservatively treated horses we have found simple RDC impaction (in one horse associated with left dorsal colon impaction) which was accompanied by distension of left colon and cecum. In comparison with surgically treated patients the impaction was less extensive. In surgically immediately treated horses where rectal palpation showed only the impaction was not possible to exclude enterolithiasis, tumour, intraabdominal adhesions which could explain chronic or recurrent course of disease. Oedema of the large colon wall was found in another horse by repeated rectal palpation and we considered a possible damage of intestinal wall. If the rectal palpation did not indicate the optimal way of therapy we contemplated intensity of abdominal pain, reaction to analgesics and the degree of general health alteration. This conclusion agrees

with opinion of other authors (Specht and Colahan, 1988; Andrews and Robertson, 1988; Dabareiner and White, 1995; Parks, 1996, etc.).

Surgical treatment linked to high frequency of complications that either caused a death of horse during short time after ending of anaesthesia or notably disturbed a period of recovery. These complications were acute diarrhoea, laminitis, abortion or infection of surgical wound. These same complications were registered also by many foreign authors (Moore and White, 1982; Palmer *et al.*, 1985; Specht and Colahan, 1988; Mogg *et al.*, 1992; Hassel *et al.*, 1999, etc.). Such problems are generally associated with an abdominal surgery in the horse. Data of authors mentioned above did not deal with the colon impaction only. Higher occurrence in patients with RDC impaction has to be evaluated by analysis of all complications in surgically and conservatively treated colic horses.

REFERENCES

- Anděl J. (1985): *Matematická statistika*. SNTL, Praha. 346.
- Andrews F.A., Robertson J.T. (1988): Diagnosis and surgical treatment of functional obstruction of the right dorsal colon in a horse. *J. Am. Vet. Med. Assoc.*, 193, 956–958.
- Cable C.H.S., Fubini S.L., Erb H.N., Hakes J.E. (1997): Abdominal surgery in foals: review of 119 cases (1977–1994). *Equine Vet. J.*, 29, 257–261.
- Colahan P.T. (1987): Sand colic. In: Robinson N.E. (ed.): *Current Therapy in Equine Medicine*. WB Saunders Co, Philadelphia. 55–58.
- Dabareiner R.M., White N.A. (1995): Large colon impaction in horses: 147 cases (1985–1991). *J. Am. Vet. Med. Assoc.*, 206, 679–685.
- Dart A.J., Snyder J.R., Pascoe J.R., Farver T.B., Galuppo L.D. (1992): Abnormal conditions of the equine descending (small) colon: 102 cases (1979–1989). *J. Am. Vet. Med. Assoc.*, 200, 971–978.
- Edwards G.B. (1992): A review of 38 cases of small colon obstruction in the horse. *Equine Vet. J. (Suppl 13)*, 42–50.
- Hackett R.P. (1983): Nonstrangulated colonic displacement in horses. *J. Am. Vet. Med. Assoc.*, 182, 235–240.
- Hammock P.D., Freeman D.E., Baker G.J. (1998): Failure of psyllium mucilloid to hasten evacuation of sand from the equine large intestine. *Vet. Surg.*, 27, 547–554.
- Hassel D.M., Langer D.L., Snyder J.R., Drahe C.H.M., Goodell M.L., Wyle A. (1999): Evaluation of enterolithiasis in equids: 900 cases (1973–1996). *J. Am. Vet. Med. Assoc.*, 214, 233–237.
- Huskamp B., Kopf N. (1978): Systematische Diagnostik am Kolikpferd. *Prakt. Tierarz.*, 59, 408–412.
- Huskamp B., Kopf N. (1995): Die rektale Untersuchung beim Kolikpferd. *Wak Verlag- und Kunstberatung, München*. 97 pp.
- Huskamp B., Kopf N., Scheidemann W. (1999): Magen – Darm – Trakt. In: Dietz O., Huskamp B. (eds.): *Handbuch Pferde Praxis*. Ferdinand Enke Verlag. 411–502.
- Kopf N., Huskamp B. (1978): Die rektale Untersuchung beim Kolikpferd. *Prakt. Tierarz.*, 4, 259–268.
- Mealey R.H., Chaffin M.K., Peloso J.G., Crabill M.R. (1995): Colonic phytobezoar and volvulus in a colt. *Vet. Med.*, 982–984.
- Mogg T.D., Groenendyk S., Sutton R.H. (1992): Volvulus of the colon in a horse associated with a mesocolic-umbilical band. *Aust. Vet. J.*, 69, 11–12.
- Moore J.N., White N.A. (1982): Acute abdominal disease. *Vet Clin North Am (Large Anim. Pract.)*, 4, 61–78.
- Palmer J.E., Benson C.E., Whitlock R.H. (1985): Salmonella shed by horses with colic. *J. Am. Vet. Med. Assoc.*, 187, 256–257.
- Parks A.H. (1996): Displacement of the large colon: Conservative versus surgical management. *Comp. Cont. Educ. Pract.*, 18, 84–87.
- Peloso J.G., Coatney R.W., Caron J.P., Steficek B.A. (1992): Obstructive enterolith in an 11-month-old miniature horse. *J. Am. Vet. Med. Assoc.*, 201, 1745–1746.
- Ragle C.A., Meagher D.M., Lacroix C.A., Honnas C.M. (1989): Surgical treatment of sand colic. Results in 40 horses. *Vet Surg.*, 18, 48–51.
- Scheidemann W. (1997): Langzeitergebnisse der Erweiterungsplastik vom *Ostium caecocolicum* bei der chronisch rezidivierenden Blinddarmobstipation. In: XII. Tagung über Pferdekrankheiten, Essen.
- Specht T.E., Colahan P.T. (1988): Surgical treatment of sand colic in equids: 48 cases (1978–1985). *J. Am. Vet. Med. Assoc.*, 193, 1560–1564.
- Sullins K.E. (1990): Diseases of the large colon. In: White N.A.: *The equine acute abdomen*. Lea & Febiger, Philadelphia. 375–391.
- Vatistas N.J., Snyder J.R., Wilson W.D., Drake C.H., Hildebrand S. (1996): Surgical treatment for colic in the foal (67 cases): 1980–1992. *Equine Vet. J.*, 28, 139–145.
- White N.A., Dabareiner R.M. (1997): Treatment of impaction colics. *Vet. Clin. North Am. Equine Pract.*, 13, 243–259.

Received: 00–12–20

Accepted after corrections: 01–12–11

Corresponding Author:

MVDr. Jana Mezerová, PhD., University of Veterinary and Pharmaceutical Sciences, Palackého 1–3, 612 42 Brno, Czech Republic

Tel. +420 5 41 56 23 45, fax +420 5 41 56 23 95, e-mail: mezerovaj@vfu.cz