



ELSEVIER

CLINICAL RESEARCH STUDY

Diagnostic Pathways in Acute Pulmonary Embolism: Recommendations of The PIOPED II Investigators

Paul D. Stein, MD,^{a,b} Pamela K. Woodard, MD,^c John G. Weg, MD,^d Thomas W. Wakefield, MD,^e Victor F. Tapson, MD,^f H. Dirk Sostman, MD,^{g,h} Thomas A. Sos, MD,ⁱ Deborah A. Quinn, MD,^{j,k} Kenneth V. Leeper, Jr, MD,^l Russell D. Hull, MBBS, MSc,^m Charles A. Hales, MD,^{j,k} Alexander Gottschalk, MD,ⁿ Lawrence R. Goodman, MD,^o Sarah E. Fowler, PhD,^p John D. Buckley, MD, MPH^q

^aDepartment of Research, St. Joseph Mercy Oakland Hospital, Pontiac, Mich; ^bDepartment of Medicine, Wayne State University, Detroit, Mich; ^cDepartment of Radiology, Washington University, St. Louis, Mo; Departments of ^dMedicine and ^eSurgery, University of Michigan, Ann Arbor; ^fDepartment of Medicine, Duke University, Durham, NC; ^gOffice of the Dean, Weill Cornell Medical College, New York, NY; ^hOffice of the Executive Vice President, Methodist Hospital, Houston, Tex; ⁱDepartment of Radiology, Weill Cornell Medical College, New York, NY; ^jDepartment of Medicine, Massachusetts General Hospital, Boston; ^kHarvard Medical School, Boston, Mass; ^lDepartment of Medicine, Emory University, Atlanta, Ga; ^mDepartment of Medicine, University of Calgary, Calgary, Alberta, Canada; ⁿDepartment of Radiology, Michigan State University, East Lansing; ^oDepartment of Radiology, Medical College of Wisconsin, Milwaukee; ^pThe Biostatistics Center, Department of Epidemiology and Biostatistics, George Washington University, Rockville, Md; ^qDepartment of Medicine, Henry Ford Hospital, Detroit, Mich.

ABSTRACT

PURPOSE: To formulate comprehensive recommendations for the diagnostic approach to patients with suspected pulmonary embolism, based on randomized trials.

METHODS: Diagnostic management recommendations were formulated based on results of the Prospective Investigation of Pulmonary Embolism Diagnosis II (PIOPED II) and outcome studies.

RESULTS: The PIOPED II investigators recommend stratification of all patients with suspected pulmonary embolism according to an objective clinical probability assessment. D-dimer should be measured by the quantitative rapid enzyme-linked immunosorbent assay (ELISA), and the combination of a negative D-dimer with a low or moderate clinical probability can safely exclude pulmonary embolism in many patients. If pulmonary embolism is not excluded, contrast-enhanced computed tomographic pulmonary angiography (CT angiography) in combination with venous phase imaging (CT venography), is recommended by most PIOPED II investigators, although CT angiography plus clinical assessment is an option. In pregnant women, ventilation/perfusion scans are recommended by many as the first imaging test following D-dimer and perhaps venous ultrasound. In patients with discordant findings of clinical assessment and CT angiograms or CT angiogram/CT venogram, further evaluation may be necessary.

CONCLUSION: The sequence for diagnostic test in patients with suspected pulmonary embolism depends on the clinical circumstances. © 2006 Elsevier Inc. All rights reserved.

KEYWORDS: Pulmonary embolism; Venous thromboembolism; Computed tomographic angiography; D-dimer; Pulmonary scintigraphy; Clinical assessment

Supported by Grants HL63899, HL63928, HL63931, HL063932, HL63940, HL63941, HL63942, HL63981, HL63982, and HL67453 from the U.S. Department of Health and Human Services, Public Health Services, National Heart, Lung, and Blood Institute, Bethesda, MD.

Diagnostic Pathways in Acute Pulmonary Embolism: Recommendations of the PIOPED II Investigators by Stein et al is being jointly published by *The American Journal of Medicine* and *Radiology*. A similar article will appear as an editorial in the January 2007 issue of *Radiology*.

The choice of diagnostic tests depends on the clinical probability of pulmonary embolism, condition of the patient, availability of diagnostic tests, risks of iodinated contrast material, radiation exposure, and cost. Recommendations can now be

Requests for reprints should be addressed to Paul Stein, MD, St. Joseph Mercy Oakland Hospital, 44405 Woodward Ave., Pontiac, MI 48341-5023. E-mail address: steinp@trinity-health.org.

formulated based on the results of the Prospective Investigation of Pulmonary Embolism Diagnosis II (PIOPED II)¹ and other studies,²⁻⁴ albeit with continued reliance on the physician's judgment. The following recommendations include both evidence-based recommendations and opinions based on information available at this time. Both are subject to revision as further data become available. Information related to radiation exposure,⁵⁻¹² charges for tests, and positive predictive values of clinical probability assessments^{2,13-19} are shown in Tables 1-3.

CLINICAL ASSESSMENT

Physicians with experience in pulmonary embolism showed similar results with empirical assessment^{14,17,18} and by objective assessment (Table 3).^{2,13-17,19} Objective assessment may be more robust when applied by nonexperts.

Recommendations for clinical assessment:

- Clinical assessment should be made before imaging.
- Clinical assessment should be made by an objective method.

PATIENTS WITH LOW PROBABILITY CLINICAL ASSESSMENT

The quantitative rapid enzyme-linked immunosorbent assay (ELISA), with a sensitivity of 95%, showed the most clinically useful values among the various D-dimer assays.²⁰ When used in combination with a low probability objective clinical assessment, which ranges from 4% to 15%^{2,14-17,19} (Table 3, Figure 1), the post-test probability of pulmonary embolism ranges from 0.7% to 2% with a normal D-dimer rapid ELISA.^{20,21} No further testing is required if D-dimer is normal in a patient with a low probability clinical assess-

ment. Additional testing with venous ultrasound or gadolinium enhanced magnetic resonance venography²² is optional.

An abnormal D-dimer indicates the need for further testing if pulmonary embolism is suspected. The majority of PIOPED II investigators preferred the combination of contrast-enhanced multidetector computed tomographic pulmonary angiography (CT angiography) and venous phase imaging of the proximal leg veins (CT venography). A CT angiogram had a sensitivity of only 83% in PIOPED II and would be inadequate in the absence of clinical assessment or CT venography.¹

Radiation exposure can be reduced by omitting the iliac veins and inferior vena cava in the CT venogram. Among patients who showed thrombi on CT venography, the iliac veins or the inferior vena cava showed thrombi in the absence of femoral or popliteal vein thrombi in only 3 of 105 (3%).¹

In PIOPED II among patients with a low probability clinical assessment, if CT angiography was negative, pulmonary embolism

was present in 4%. If CT angiography/CT venography was negative, pulmonary embolism was present in 3% (Figure 2).¹ In outcome studies of untreated patients with normal CT angiography and clinical assessment that ranged from low probability to "likely," 1.3% had venous thromboembolism and 1.5% would have had pulmonary embolism or deep venous thrombosis on 3-month follow-up.^{3,4}

If CT angiography was positive in a patient with a low probability clinical assessment, pulmonary embolism was present in 58%. With a positive CT angiogram/CT venogram, pulmonary embolism was present in 57%.¹ However, if the CT angiography showed pulmonary embolism in a main or lobar pulmonary artery, pulmonary embolism was present in 97%.¹ If the largest vessel showing pulmonary embolism was in a segmental branch, pulmonary embolism was present in 68%. If in a subsegmental branch, pulmonary embolism was present in 25% of patients, but data are sparse in the subsegmental group.¹

Recommendations for patients with low probability clinical assessment (Figure 2):

- Perform a D-dimer rapid ELISA.
- No further testing is required if D-dimer is normal.
- If D-dimer is positive, CT angiography/CT venography is recommended by most PIOPED II investigators.

CLINICAL SIGNIFICANCE

- Patients with suspected pulmonary embolism should have an objective clinical assessment.
- Obtain a D-dimer rapid ELISA if clinical assessment is low or intermediate probability.
- CT angiography/CT venography is recommended by most PIOPED II investigators as the first imaging tests.
- With discordant findings of clinical assessment and CT angiograms or CT angiograms/CT venograms, further evaluation may be necessary.
- In pregnant women and women of reproductive age, pulmonary scintigraphy may be the imaging test of choice.

Table 1 Charges (Including Physicians' Fees) at a Community Hospital

Procedure	Charges (Dollars)
Pulmonary angiography	6106
Contrast-enhanced spiral CT	1739
Ventilation/perfusion lung scan	917
Ultrasound, both legs	631
D-dimer (Rapid ELISA)	24

CT = computed tomography; ELISA = enzyme-linked immunosorbent assay.

Table 2 Radiation Exposure

Examination	Effective Whole Body Dose (mSv)	Refs
Chest PA and lat	0.07	11
Perfusion scan	0.8	7
Ventilation/perfusion scan	1.2-2.0	7,10
CT angiography	1.6-8.3	6-10
CT venography	5.7	10
Pulmonary digital subtraction angiogram	3.2-30.1	6-10
Background radiation/year	2.5	5
Max allowable/year radiation workers	50	12
Avg allowable/year radiation workers	20	12

PA = posterior-anterior; Lat = lateral; CT = contrast-enhanced multidetector computed tomographic angiography; Max = maximum; Avg = average.

- CT venography of only the femoral and popliteal veins is recommended to reduce radiation.
- If CT angiography or CT angiography/CT venography is negative, treatment is unnecessary.
- With main or lobar pulmonary emboli on CT angiography, treatment is indicated.
- With segmental or subsegmental pulmonary emboli the certainty of the CT diagnosis should be re-assessed.
- CT angiography or CT angiography/CT venography should be repeated if image quality is poor.
- In patients with segmental or subsegmental pulmonary emboli, pulmonary scintigraphy, a single venous ultrasound in those evaluated by CT angiography only, serial venous ultrasound examinations,^{13,23} or pulmonary digital subtraction angiography are optional.

PATIENTS WITH A MODERATE PROBABILITY CLINICAL ASSESSMENT

Patients with objectively measured moderate clinical probabilities of pulmonary embolism were shown to have pul-

Table 3 Probability of Pulmonary Embolism According to Clinical Assessment*

	Clinical Low Pulmonary Embolism (%)	Clinical Moderate Pulmonary Embolism (%)	Clinical High Pulmonary Embolism (%)	Refs
Empirical Wells (extended)	10	31	61	14,17,18
Wells (simplified)	4	30	68	2,13,14
Geneva score	15	29	59	14-16
Geneva revised	11	38	79	16,17
	8	29	74	19

*Pooled data.

D-Dimer Rapid ELISA Pathway

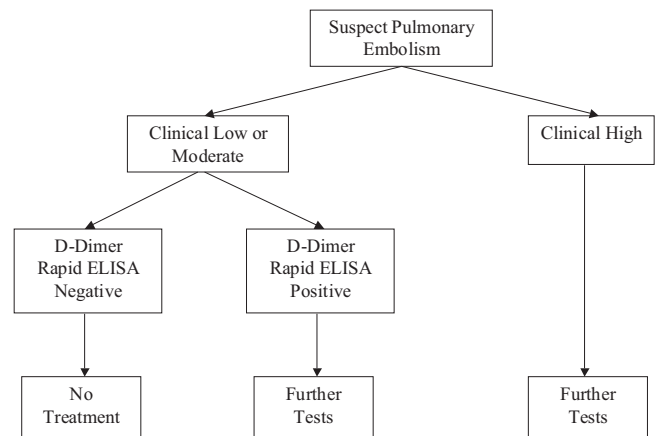


Figure 1 Pathway for D-dimer by quantitative rapid ELISA in combination with clinical assessment. If clinical assessment is low or moderate probability, and D-dimer rapid ELISA is negative, pulmonary embolism would be excluded. If clinical assessment is high probability, further testing is necessary irrespective of the results of D-dimer testing. ELISA = enzyme-linked immunosorbent assay.

monary embolism in 29% to 38%.^{2,14-18,21} The posttest probability of pulmonary embolism with a 30% clinical probability of pulmonary embolism is 5% with a normal rapid ELISA.^{20,21}

With a moderate clinical probability assessment, if the CT angiogram was negative, pulmonary embolism was present in 11%. If CT angiogram/CT venogram was negative, pulmonary embolism was present in 8%.¹ Outcome studies showed pulmonary embolism 3 months after a negative CT angiogram in $\leq 1.5\%$ of patients.^{3,4}

If CT angiography was positive in a patient with a moderate probability clinical assessment, pulmonary embolism was present in 92%, and with a positive CT angiogram/CT venogram combination, pulmonary embolism was present in 90%.¹ The predictive values with lobar, segmental, and subsegmental pulmonary emboli and recommendations for further imaging are as described in the section on low probability clinical assessment.

Recommendations for patients with a moderate probability clinical assessment (Figure 3):

- We recommend a D-dimer rapid ELISA.
- If D-dimer rapid ELISA is negative, no further testing is necessary, but a venous ultrasound or magnetic resonance venography is optional.
- If D-dimer is positive, CT angiography/CT venography is recommended by most PIOPED II investigators.
- Treatment with anticoagulants while awaiting the outcome of diagnostic tests may be appropriate, particularly if the tests cannot be obtained immediately.²⁴

Patients with Low Probability Clinical Assessment

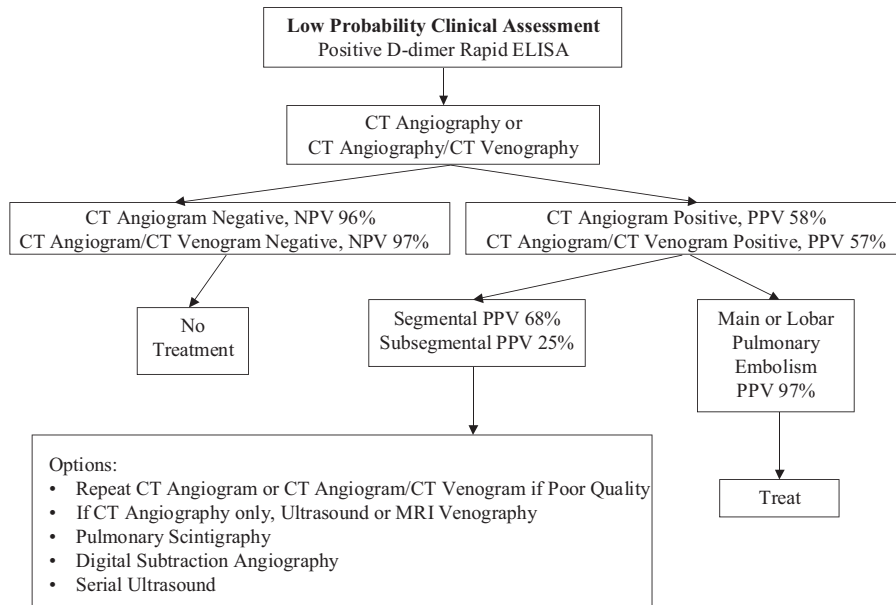


Figure 2 Pathway for diagnosis with CT angiography or CT angiography/CT venography following testing with D-dimer in combination with low probability clinical assessment. CT angiography = contrast-enhanced multidetector computed tomographic pulmonary angiography; CT venography = contrast-enhanced multidetector computed tomographic venous phase imaging of the veins of the lower extremities; NPV = negative predictive value; PPV = positive predictive value.

- If CT angiography or CT angiography/CT venography are negative, no treatment is necessary, but a venous ultrasound is recommended for those with a negative CT angiogram alone.
- If CT angiography or CT angiography/CT venography are positive, treatment is recommended.
- With segmental or subsegmental pulmonary emboli, the certainty of the CT diagnosis should be re-assessed and

Patients with Moderate Probability Clinical Assessment

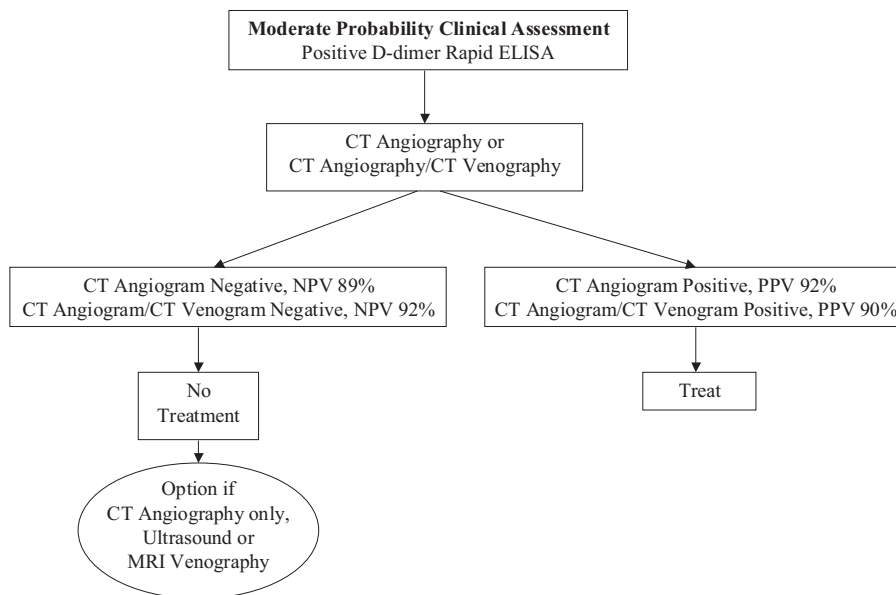


Figure 3 Pathway for diagnosis with CT angiography or CT angiography/CT venography following testing with D-dimer in combination with moderate probability clinical assessment. CT angiography = contrast-enhanced multidetector computed tomographic pulmonary angiography; CT venography = contrast-enhanced multidetector computed tomographic venous phase imaging of the veins of the lower extremities; NPV = negative predictive value; PPV = positive predictive value.

Patients with High Probability Clinical Assessment

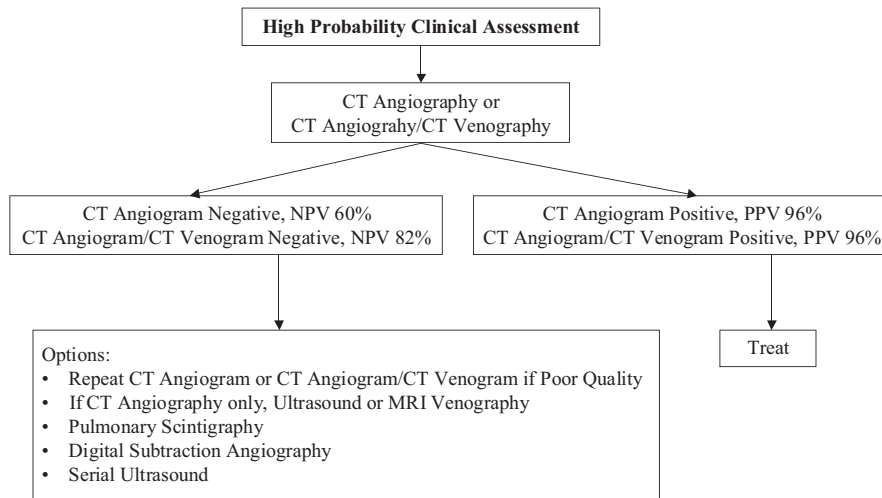


Figure 4 Pathway for diagnosis with CT angiography or CT angiography/CT venography in patients with a high probability clinical assessment. CT angiography = contrast-enhanced multidetector computed tomographic pulmonary angiography; CT venography = contrast-enhanced multidetector computed tomographic venous phase imaging of the veins of the lower extremities; NPV = negative predictive value; PPV = positive predictive value.

options followed according to recommendations for patients with a low probability clinical assessment.

PATIENTS WITH A HIGH PROBABILITY CLINICAL ASSESSMENT

A D-dimer is not helpful because a negative D-dimer does not exclude pulmonary embolism in >15% of patients with a high probability clinical assessment.^{20,21}

If either CT angiography alone or CT angiography/CT venography combination were positive in a patient with a high probability clinical assessment, pulmonary embolism was present in 96% in PLOPED II.¹ If CT angiography was negative in a patient with a high probability assessment, pulmonary embolism was present in 40%, and if CT angiography/CT venography was negative, pulmonary embolism was present in 18%.¹ If considering ventilation/perfusion lung scans for further testing, or a perfusion lung scan alone if the chest radiograph is normal or nearly normal,²⁵ the proportion of patients with a nondiagnostic pulmonary scintiscan is lower with a normal chest radiograph than with an abnormal chest radiograph^{26,27} and has been reported to be only 9%.²⁷

Recommendations for patients with a high probability clinical assessment (Figure 4):

- D-dimer testing need not be done because a negative D-dimer in a patient with a high probability clinical assessment may not exclude pulmonary embolism.
- Treat with anticoagulants while awaiting the outcome of diagnostic tests.²⁴
- Most PLOPED II investigators recommend CT angiography/CT venography.
- If CT angiography is negative and CT angiography/CT venography was not done or was technically inadequate,

a venous ultrasound or magnetic resonance venography is recommended.

- If CT angiography or CT angiography/CT venography are negative, other options include serial venous ultrasound examinations, pulmonary digital subtraction angiography, and pulmonary scintigraphy.
- If CT angiography or CT angiography/CT venography are positive, treatment is recommended.

OPTIONAL PATHWAYS, ALL PATIENTS

Venous ultrasound detects deep venous thrombosis in 13% to 15% of patients with suspected pulmonary embolism^{28,29} and in 29% with proven pulmonary embolism,²⁹ thereby allowing treatment with no further obligatory testing.

Recommendation for optional pathways:

- A venous ultrasound before imaging with CT angiography or CT angiography/CT venography is optional and may guide treatment if positive.

PATIENTS WITH ALLERGY TO IODINATED CONTRAST MATERIAL

If clinical assessment and D-dimer fail to exclude pulmonary embolism, a venous ultrasound may be positive and guide therapy. Patients with mild to moderate iodine allergies may be pretreated with steroids and then imaged with CT. With severe iodine allergy, pulmonary scintigraphy may be a useful alternative. A low probability ventilation/perfusion scan combined with a low probability clinical assessment showed pulmonary embolism in only 4%.¹⁸ A high probability ventilation/perfusion scan in a patient with a high probability clinical assessment showed pulmonary embolism in 96%.¹⁸ With other combinations, pulmonary

embolism was present in 16% to 88%, and further evaluation is needed. Further evaluation may include serial venous ultrasound^{13,23} or gadolinium-enhanced CT angiography (0.3-0.4 mmol/kg).³⁰ Preliminary investigations suggest that gadolinium-enhanced magnetic resonance imaging may be useful.³¹⁻³⁴

Recommendations for patients with allergy to iodinated contrast material:

- D-dimer with clinical assessment is recommended to exclude pulmonary embolism.
- Patients with mild iodine allergies may be treated with steroids before the CT imaging.
- Venous ultrasound and pulmonary scintigraphy are recommended as alternative diagnostic tests in patients with severe iodine allergy.
- Serial venous ultrasound and gadolinium-enhanced CT angiography are options.

PATIENTS WITH IMPAIRED RENAL FUNCTION

In PIOPED II, only 1 of 824 patients who had CT angiography (0.1%) developed renal failure.¹ Nonionic contrast material was used.¹ Patients with abnormal serum creatinine levels were excluded. If the creatinine clearance is only somewhat elevated, whether to proceed with CT imaging depends on clinical judgment. Nonionic contrast material appears to be less nephrotoxic³⁵ and generally better tolerated³⁶ than ionic contrast material, although some reported no difference in nephrotoxicity.³⁷ Prophylactic hydration with sodium bicarbonate before contrast exposure reduces the risks of renal dysfunction in patients with renal insufficiency and has been reported to be more effective than hydration with sodium chloride.³⁸ An isotonic solution of sodium bicarbonate 3 mL/kg per hour for 1 hour before and 1 mL/kg per hour for 6 hours after the administration of contrast material has been recommended.^{38,39}

Nonsteroidal anti-inflammatory drugs and dipyridamole were discontinued in PIOPED II. They should be discontinued as early as possible before the administration of contrast material.⁴⁰ Metformin (Glucophage) also should be discontinued before the injection of contrast material, because if contrast-induced renal failure occurs, metformin accumulation in body tissues could cause lactic acidosis.⁴¹ Metformin, however, does not cause renal failure.⁴¹ In emergency or urgent situations, if renal function is normal, the study may proceed with little risk.⁴¹ If renal function is abnormal or unknown, metformin should be discontinued, and hydration, as well as other precautions listed above should be taken.⁴¹ Therapy with metformin can be resumed when renal function has been shown to be normal.^{40,41} Results with angiotensin-converting enzyme inhibitors have been equivocal.⁴⁰

Recommendations for patients with impaired renal function:

- D-dimer with clinical assessment is recommended to exclude pulmonary embolism.

- Venous ultrasound is recommended and, if positive, treatment is indicated.
- Pulmonary scintigraphy is recommended if venous ultrasound is negative.
- Serial venous ultrasound is an option.

WOMEN OF REPRODUCTIVE AGE

Female breast radiation is a concern, but the risk of death from undiagnosed pulmonary embolism far exceeds the risk of radiation-induced malignancy. The absorbed dose to the breast with CT angiography has been calculated as 10-50 mGy.⁴²⁻⁴⁴ The absorbed dose to the breast with a perfusion lung scan has been estimated to be 0.28 mGy.⁴² The absorbed dose to the breast with standard 2-view mammography is 3 mGy.⁴³

Pulmonary scintigraphy would minimize breast radiation. In PIOPED, a ventilation/perfusion scan in patients with a normal chest radiograph was diagnostic (high probability or normal/nearly normal) in 52% of patients with suspected pulmonary embolism.²⁶ More recently, a ventilation/perfusion scan was shown to be diagnostic in 91% of patients with suspected pulmonary embolism and a normal chest radiograph.²⁷

Recommendations for women of reproductive age:

- If D-dimer rapid ELISA is positive, venous ultrasound as the next diagnostic test is optional.
- Pulmonary scintigraphy is recommended by some PIOPED investigators as the next imaging test.
- A CT angiogram with venous ultrasound is an acceptable alternative.
- If a CT venogram is deemed necessary, it is advisable to start at the acetabulum to reduce gonadal irradiation.

PREGNANT PATIENTS

In pregnant women, D-dimer testing may be useful even though it may be positive due to the pregnancy.⁴⁵ Venous ultrasound detects deep venous thrombosis in 13% to 15% of patients with suspected pulmonary embolism^{28,29} and in 29% with proven pulmonary embolism,²⁹ eliminating the need for radiographic imaging. If radiographic imaging is necessary, some have recommended⁴⁶ or used⁴⁷ CT angiography rather than ventilation/perfusion lung scans. Magnetic resonance imaging requires further validation.³¹⁻³⁴ However, adequate and well-controlled studies of gadopentetate dimeglumine have not been conducted in pregnant women.⁴⁸ It is not known to what extent it is excreted in human milk.⁴⁸

Some indicate that the radiation dose to the fetus from 16-slice CT angiography, 0.24-0.47 mGy at 0 months and 0.61-0.66 mGy at 3 months, is of the same magnitude as a ventilation/perfusion scan, 0.25-0.36 mGy at 0 months and 0.31-0.32 mGy at 3 months, or a perfusion scan alone, 0.21 mGy at 0 months and 0.30 mGy at 3 months.⁴⁹ Others indicate that the absorbed dose to the fetus is less with CT angiography than a perfusion scan (0.01 mGy vs. 0.12 mGy).⁴²

Recommendations for pregnant patients:

- D-dimer with clinical assessment should be obtained.
- If D-dimer is positive, venous ultrasound is recommended before imaging tests with ionizing radiation.
- Some PIOPED II investigators recommend pulmonary scintigraphy, and some recommend a CT angiogram.

PATIENTS IN EXTREMIS

The sensitivity of transthoracic echocardiography for right ventricular enlargement or dysfunction in patients with massive pulmonary embolism or unstable patients, combining data from 3 case series, was 33 of 33 (100%).⁵⁰⁻⁵² If any 2 of the following 3 assessments were positive (clinical probability high, echocardiogram and ultrasound), the sensitivity for massive pulmonary embolism was 33 of 34 (97%) and the negative predictive value was 98%.⁵³

Recommendations for patients in extremis:

- Bedside echocardiography and bedside leg ultrasonography in combination are recommended as rapidly obtainable bedside tests.
- Right ventricular enlargement or poor right ventricular function, in a proper clinical setting, can be interpreted as resulting from pulmonary embolism.
- A positive venous ultrasound in the appropriate clinical setting also indicates pulmonary embolism.
- A portable perfusion scan is recommended by some.
- Immediate transfer to an interventional catheterization laboratory is recommended by some.
- A combination of a negative bedside echocardiogram and venous ultrasound indicate the need for CT angiography if it is feasible.
- When the patient stabilizes, appropriate imaging studies should be performed.

In conclusion, the PIOPED II investigators recommend stratification of all patients with suspected pulmonary embolism according to an objective probability assessment. A negative D-dimer rapid ELISA with a low or moderate probability clinical assessment can safely exclude pulmonary embolism. If pulmonary embolism is not excluded, CT angiography/CT venography is recommended by most PIOPED II investigators, although CT angiography alone is an option. In patients with discordant findings on clinical assessment and CT imaging, further evaluation depends on clinical judgment. In pregnant women, ventilation/perfusion scans are recommended by many PIOPED II investigators as the first imaging test.

References

1. Stein PD, Fowler SE, Goodman LR, et al; PIOPED II Investigators. Multidetector computed tomography for acute pulmonary embolism. *N Engl J Med.* 2006;354:2317-2327.
2. Wells PS, Anderson DR, Rodger M, et al. Excluding pulmonary embolism at the bedside without diagnostic imaging: management of patients with suspected pulmonary embolism presenting to the emergency department by using a simple clinical model and D-dimer. *Ann Intern Med.* 2001;135:98-107.
3. Perrier A, Roy PM, Sanchez O, et al. Multidetector-row computed tomography in suspected pulmonary embolism. *N Engl J Med.* 2005; 352:1760-1768.
4. Christopher Study Investigators. Effectiveness of managing suspected pulmonary embolism using an algorithm combining clinical probability, D-dimer testing, and computed tomography. *JAMA.* 2006;295: 172-179.
5. Robinson A. In: Grainger RG, Allison D, eds. *Grainger & Allison's Diagnostic Radiology*, 3rd ed. New York, NY: Churchill Livingstone: 169-183; 1997.
6. Kuiper JW, Geleijns J, Matheijssen NAA, et al. Radiation exposure of multi-row detector spiral computed tomography of the pulmonary arteries: comparison with digital subtraction pulmonary angiography. *Eur Radiol.* 2003;13:1496-1500.
7. O'Neill J, Murchison JT, Wright L, Williams J. Effect of the introduction of helical CT on radiation dose in the investigation of pulmonary embolism. *Br J Radiol.* 2005;78:46-50.
8. Mayo JR, Aldrich J, Muller NL. Radiation exposure at chest CT: a statement of the Fleischner society. *Radiology.* 2003;228:15-21
9. Resten A, Mausoleo F, Valero M, Musset D. Comparison of doses for pulmonary embolism detection with helical CT and pulmonary angiography. *Eur Radiol.* 2003;13:1515-1521.
10. Wittram C, Liu B, Callahan RJ, et al. An estimate of the radiation dose received per patient for the investigation of pulmonary venous thromboembolism based on the PIOPED II data. Presented at the annual meeting of the Radiological Society of North America (Abstract 4408707). Chicago, IL: November 2005.
11. Huda W, Sourkes AM. Radiation doses from chest x-rays in Manitoba (1979 and 1987). *Radiat Prot Dosimetry.* 1989;28:303-308.
12. 1990 Recommendations of the International Commission on Radiological Protection. *Ann ICRP.* 1991;21:1-201.
13. Wells PS, Ginsberg JS, Anderson DR, et al. Use of a clinical model for safe management of patients with suspected pulmonary embolism. *Ann Intern Med.* 1998;129:997-1005.
14. Sanson BJ, Lijmer JG, Mac Gillavry MR, et al. Comparison of a clinical probability estimate and two clinical models in patients with suspected pulmonary embolism. ANTELOPE-Study Group. *Thromb Haemost.* 2000;83:199-203.
15. Wells PS, Anderson DR, Rodger M, et al. Derivation of a simple clinical model to categorize patients' probability of pulmonary embolism: increasing the models utility with the SimpliRED D-Dimer. *Thromb Haemost.* 2000;83:416-420.
16. Chagnon I, Bounameaux H, Aujesky D, et al. Comparison of two clinical prediction rules and implicit assessment among patients with suspected pulmonary embolism. *Am J Med.* 2002;113:269-275.
17. Wicki J, Perneger TV, Junod AF, et al. Assessing clinical probability of pulmonary embolism in the emergency ward. A simple score. *Arch Intern Med.* 2001;161:92-97.
18. Value of the ventilation/perfusion scan in acute pulmonary embolism: results of the Prospective Investigation of Pulmonary Embolism Diagnosis (PIOPED). The PIOPED Investigators. *JAMA.* 1990;263: 2753-2759.
19. Le Gal G, Righini M, Roy PM, et al. Prediction of pulmonary embolism in the emergency department: the revised Geneva score. *Ann Intern Med.* 2006;144:165-171.
20. Stein PD, Hull RD, Patel KC, et al. D-dimer for the exclusion of deep venous thrombosis and acute pulmonary embolism: a systematic review. *Ann Intern Med.* 2004;140:589-602.
21. Sox HC. Commentary. *Ann Intern Med.* 2004;140:602.
22. Sostman HD. MRA for diagnosis of venous thromboembolism. *Q J Nucl Med.* 2001;45:311-323.
23. Stein PD, Hull RD, Pineo G. Strategy that includes serial noninvasive leg tests for diagnosis of thromboembolic disease in patients with suspected acute pulmonary embolism based on data from PIOPED. Prospective Investigation of Pulmonary Embolism Diagnosis. *Arch Intern Med.* 1995;155:2101-2104.

24. Buller HR, Agnelli G, Hull RD, et al. Antithrombotic therapy for venous thromboembolic disease: the Seventh ACCP Conference on Antithrombotic and Thrombolytic Therapy. *Chest*. 2004;126(Suppl):401S-428S.
25. Stein PD, Terrin ML, Gottschalk A, et al. Value of ventilation/perfusion scans compared to perfusion scans alone in acute pulmonary embolism. *Am J Cardiol*. 1992;69:1239-1241.
26. Stein PD, Alavi A, Gottschalk A, et al. Usefulness of non-invasive diagnostic tools for diagnosis of acute pulmonary embolism in patients with a normal chest radiograph. *Am J Cardiol*. 1991;67:1117-1120.
27. Forbes KP, Reid JH, Murchison JT. Do preliminary chest X-ray findings define the optimum role of pulmonary scintigraphy in suspected pulmonary embolism? *Clin Radiol*. 2001;56:397-400.
28. Perrier A, Roy PM, Aujesky D, et al. Diagnosing pulmonary embolism in outpatients with clinical assessment, D-dimer measurement, venous ultrasound, and helical computed tomography: a multicenter management study. *Am J Med*. 2004;116:291-299.
29. Turkstra F, Kuijer PM, van Beek EJ, et al. Diagnostic utility of ultrasonography of leg veins in patients suspected of having pulmonary embolism. *Ann Intern Med*. 1997;126:775-781.
30. Remy-Jardin M, Bahepar J, Lafitte JJ, et al. Multi-detector row CT angiography of pulmonary circulation with gadolinium-based contrast agents: prospective evaluation in 60 patients. *Radiology*. 2006;238:1022-1035.
31. Stein PD, Woodard PK, Hull RD, et al. Gadolinium enhanced magnetic resonance angiography for detection of acute pulmonary embolism: and in depth review. *Chest*. 2003;124:2324-2328.
32. Meaney JF, Weg JG, Chenevert TL, et al. Diagnosis of pulmonary embolism with magnetic resonance angiography. *N Engl J Med*. 1997;336:1422-1427.
33. Oudkerk M, van Beek EJ, Wielopolski P, et al. Comparison of contrast-enhanced magnetic resonance angiography and conventional pulmonary angiography for the diagnosis of pulmonary embolism: a prospective study. *Lancet*. 2002;359:1643-1647.
34. Gupta A, Frazer CK, Ferguson JM, et al. Acute pulmonary embolism: diagnosis with MR angiography. *Radiology*. 1999;210:353-359.
35. Harris KG, Smith TP, Cragg AH, Lemke JH. Nephrotoxicity from contrast material in renal insufficiency: ionic versus nonionic agents. *Radiology*. 1991;179:849-852.
36. Barrett BJ, Carlisle EJ. Metaanalysis of the relative nephrotoxicity of high- and low-osmolality iodinated contrast media. *Radiology*. 1993;188:171-178.
37. Schwab SJ, Hlatky MA, Pieper KS, et al. Contrast nephrotoxicity: a randomized controlled trial of a nonionic and an ionic radiographic contrast agent. *N Engl J Med*. 1989;320:149-153.
38. Merten GJ, Burgess WP, Gray LV, et al. Prevention of contrast-induced nephropathy with sodium bicarbonate: a randomized controlled trial. *JAMA*. 2004;291:2328-2334.
39. Chertow GM. Prevention of radiocontrast nephropathy: back to basics. *JAMA*. 2004;291:2376-2377.
40. Waybill MM, Waybill PN. Contrast media-induced nephrotoxicity: identification of patients at risk and algorithms for prevention. *J Vasc Interv Radiol*. 2001;12:3-9.
41. Heupler FA, Jr. Guidelines for performing angiography in patients taking metformin. Members of the Laboratory Performance Standards Committee of the Society for Cardiac Angiography and Interventions. *Cathet Cardiovasc Diagn*. 1998;43:121-123.
42. Cook JV, Kyriou J. Radiation from CT and perfusion scanning in pregnancy. *BMJ*. 2005;331:350.
43. Parker MS, Hui FK, Camacho MA. Female breast radiation exposure during CT pulmonary angiography. *AJR Am J Roentgenol*. 2005;185:1228-1233.
44. International Commission on Radiological Protection. ICRP Publication 87: Managing patient dose in computed tomography. *Ann ICRP*. 2000;30:7-45.
45. Eichinger S. D-dimer testing in pregnancy. *Pathophysiol Haemost Thromb*. 2003/2004;33:327-329.
46. Matthews S. Imaging pulmonary embolism in pregnancy: what is the most appropriate imaging protocol? *Br J Radiol*. 2006;79:441-444.
47. Schuster ME, Fishman JE, Copeland JF, et al. Pulmonary embolism in pregnant patients: a survey of practices and policies for CT pulmonary angiography. *AJR Am J Roentgenol*. 2003;181:1495-1498.
48. Package Insert: Magnevist. Wayne, NJ: Berlex Laboratories. Revised May 2000.
49. Hurwitz LM, Yoshizumi T, Reiman RE, et al. Radiation dose to the fetus from body MDCT during early gestation. *AJR Am J Roentgenol*. 2006;186:871-876.
50. Cheriex EC, Sreeram N, Eussen YF, et al. Cross-sectional Doppler echocardiography as the initial technique for the diagnosis of acute pulmonary embolism. *Br Heart J*. 1994;72:52-57.
51. Mansencal N, Redheuil A, Joseph T, et al. Use of transthoracic echocardiography combined with venous ultrasonography in patients with pulmonary embolism. *Int J Cardiol*. 2004;96:59-63.
52. Rudoni RR, Jackson RE, Godfrey GW, et al. Use of two-dimensional echocardiography for the diagnosis of pulmonary embolus. *J Emerg Med*. 1998;16:5-8.
53. Grifoni S, Olivotto I, Cecchini P, et al. Utility of an integrated clinical, echocardiographic, and venous ultrasonographic approach for triage of patients with suspected pulmonary embolism. *Am J Cardiol*. 1998;82:1230-1235.