

## The Functional Role of Transperineal Ultrasound in the Evaluation of Females with Urinary Incontinence Compared to Urodynamic Studies

MANAL H. WAHBA, M.D.\*; RANIA F. ABDELSAYED, M.D.\*\* and AHMED A.S. MAHMOUD, M.D.\*\*\*

*The Department of Radiology, Cairo University\*, \*\* and Theodor Bilharz Institute\*\*\**

### Abstract

**Objective:** To prospectively evaluate the role of transperineal ultrasound in the diagnosis of female with urinary incontinence compared to urodynamic studies as the golden standard.

**Patients and Methods:** This study had institutional review board approval, and informed consent was obtained from all participants. This pilot study included twenty female patients, their age ranges from 24-50 year old (mean age 34.5 years).

All patients underwent clinical examination, urodynamic studies and transperineal ultrasound examination. According to the clinical findings 15 patients were diagnosed as mixed urinary incontinence (Involuntary leakage associated with urgency) and 5 patients as stress urinary incontinence (involuntary leakage on effort, exertion, sneezing or coughing).

The transperineal ultrasound was conducted using an (GE. ultrasound machine). A 6.5 MHz end fire vaginal endoprobe was applied to the perineum in the axial and sagittal planes. The patients were examined at rest and during different grades of straining. The ultrasound criteria evaluated by the US include: 1- Bladder neck position 2- Posterior urethro-vesical angle 3- Anterior urethral (rotational) angle 4- Urethral luminal diameter and wall thickness 5- Bladder wall thickness.

**Results:** Out of 20 patients with urinary incontinence; 12 patients (60%) had positive sonographic findings. However 8 patients (40%) were negative on perineal ultrasound. The positive sonographic findings were as follow; urethral hypermobility and intrinsic sphincteric deficiency (ISD) were detected in 7 (35%) patients, 3 (15%) patients had only urethral hypermobility, while ISD was diagnosed in 2 (10%) patients.

The ultrasound was 100% in agreement with urodynamics diagnosis in patients with intrinsic sphincter deficiency. 71.5% in patients with both urethral hypermobility and intrinsic sphincter deficiency, while 66.7% in patients with urethral hypermobility only.

**Conclusion:** Transperineal ultrasound is a simple, easily conducted examination that can be used as screening imaging modality in patients with urinary incontinence to diagnose patients who are in need for further assessment.

**Key Words:** *Transperineal ultrasound – Stress incontinence – Urodynamic urethral hypermobility – Intrinsic sphincteric deficiency – Urethrovessical.*

### Introduction

**URINARY** incontinence is a bothersome condition for many women, with an overall prevalence of approximately 40% [1]. Any leakage at least once in the past year, ranges from 2.5 to 51%, Weekly urine leakage was reported in 10% of women in an ethnically diverse urban population [2].

The precise anatomical and physiological mechanisms involved in urinary incontinence are poorly understood. Urinary continence occurs because maximum urethral pressure remains greater than intravesical pressure during bladder filling, and increases in intra-abdominal pressure are transmitted equally to the bladder and proximal urethra. The vesical neck and proximal urethra are normally intra-abdominal structures that lie above a well-supported pelvic diaphragm and they are positioned in such a way to promote the equal distribution of forces to the bladder and urethra during increases in intraabdominal pressure [3]. Poor anatomical support of the bladder neck, bladder base and proximal urethra, resulting in descent and hypermobility outside the intra-abdominal transmission zone, is considered the pathological basis of stress urinary incontinence [4].

Although it is not a life-threatening disease, it might have a significant influence on the physical, psychological, and social well-being of the affected patients [5]. Stress, urge, and mixed urinary incontinence are the most common subtypes of urinary incontinence [1].

Transperineal ultrasound especially has provided a good visualization of the urinary bladder,

**Correspondence to:** Dr. Manal H. Wahba, The Department of Radiology, Cairo University

bladder base, urethrovesical (UV) junction, urethra and the symphysis pubis [6]. It has been used as an alternative to conventional radiological techniques to assess the dynamic changes of the urethrovesical junction and proximal urethra for two decades [7]. It has been shown to detect the overall reduction of urethral muscular wall thickness in urinary incontinence [8].

Videourodynamics consists of the simultaneous registration of pressure in the bladder and rectum, and external sphincter behavior, visualizing the bladder cycle in fluoroscopy. Videourodynamics is considered by most to be the gold standard for evaluating urinary incontinence [5]. Observations of thousands of videourodynamic examinations demonstrated that 76% of those classified as having intrinsic sphincter deficiency were recorded as having consistently low leak point pressures (less than 60cm H<sub>2</sub>O). It has over the last few years evolved as an easily performed and reliable test to determine the ability of the urethra to resist the expulsive force of the bladder generated by increased intra-abdominal pressure. The term valsalva (or abdominal) leak point pressure (VLPP) represents a measure of the intravesical pressure that is required to overcome urethral resistance during a stress manoeuvre such as coughing or straining [9].

It represents the lowest bladder pressure at which urethral leakage occurs during a prompted stress maneuver. As a dynamic test, it is a reflection of the stress competence of the urethra, which ultimately mirrors its ability to resist abdominal pressure as an expulsive force. Detrusor leak point pressure (DLPP) by contrast is the pressure at which detrusor stretch or contraction generates sufficient force to induce involuntary urinary leakage [9,10].

The aim of this study is to prospectively evaluate the role of transperineal ultrasound in the diagnosis of female with urinary incontinence compared to urodynamic studies as the golden standard.

### **Patients and Methods**

This pilot study included twenty female patients, their age ranges from 24-50 years old (mean age 34.5 years). All patients underwent clinical examinations, urodynamic studies and transperineal ultrasound examination. According to the clinical findings 15 patients were diagnosed as mixed urinary incontinence (i.e the complaint of involun-

tary leakage associated with urgency also with exertion, effort, sneezing or coughing) and 5 patients as stress urinary incontinence.

The transperineal ultrasound was conducted (using LOGIQ 7 PRO, GE ) General electric medical system ultrasound machine. A 6.5 MHz end fire vaginal endoprobe applied to the perineum in the axial and sagittal planes. Transperineal US was performed by positioning the transducer tenderly onto the perineum in midsagittal line to visualize pubic symphysis, urethra and bladder, vagina and anal canal. The patients were examined at rest and during different grades of straining. The ultrasound criteria evaluated by the US include:

- 1- Bladder neck position.
- 2- Posterior urethro-vesical angle. (PUVA).
- 3- Anterior urethral (rotational) angle. (AUA).
- 4- Urethral luminal diameter and wall thickness.
- 5- Bladder wall thickness.

The urodynamic study is a dynamic test, which documents the abdominal pressure required to induce incontinence and performed by inserting urethral & rectal catheters. A transurethral double-lumen catheter is connected to fluid source & the other was used for measuring the intravesical pressure. It should be as small as possible but not so small as too dampen pressure transmission or limit the desired filling rate. The abdominal leak point pressure (ALPP) was measured that represents the lowest bladder pressure at which urethral leakage occurs during a prompted stress maneuver.

All cases were performed at Kasr Al-Aini Hospital, Faculty of Medicine, Cairo University during 2011 – 2012.

### **Results**

From the 20 patients with urinary incontinence; 12 patients (60%) had positive sonographic findings. However 8 patients (40%) were negative on perineal ultrasound. The positive sonographic findings were as follow; urethral hypermobility and intrinsic sphincteric deficiency (ISD) were detected in 7 (35%) patients, 3 (15%) patients had only urethral hypermobility, while ISD was diagnosed in 2 (10%) patients.

The patients were classified according to the ultrasonographic findings into three groups, and are presented as in Table (1) as the following:

Table (1): The details of the ultrasonographic findings in each group were summarized.

	No of cases	BN decent	Increase of PUVA	Rotational angle	Urethral thickness & diameter	Funeling
Group A	3 (15%)	–	3 (15%)	3 (15%)		1 (5%)
Group B	2 (10%)	–	–	–	2 (10%)	–
Group C	7 (35%)	1 (5%)	7 (35%)	7 (35%)	7 (35%)	1 (5%)

Group A:

*Urethral hypermobility which was characterized by:*

1- Widening of the PUVA 105 degree (Fig. 1).

2- Increased AUA (rotational angle) 110 degree (Fig. 2).

3- Significant downward displacement of the bladder base and proximal urethra.

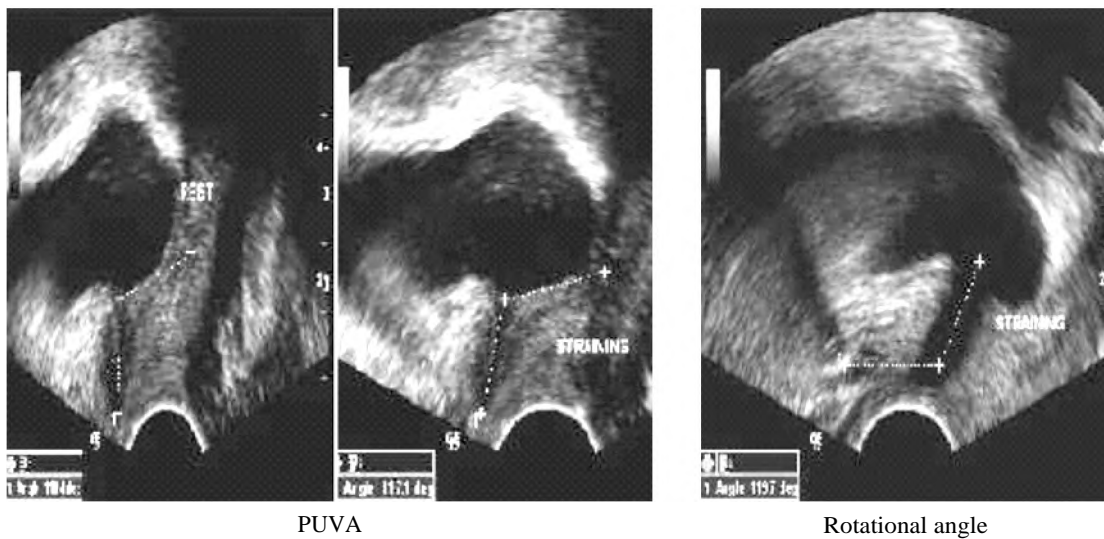


Fig. (1): Transperineal ultrasound of a female patient complaining of mixed urinary incontinence shows widening of the posterior urethral angle. (PUVA is an angle formed between a line drawn tangent the proximal half of the urethra and a line tangent the infero-posterior aspect of the bladder base). And also shows increased in the rotational angle (which refers to the slope of the proximal half of the urethral axis with respect to the x axis of the pubic bone).

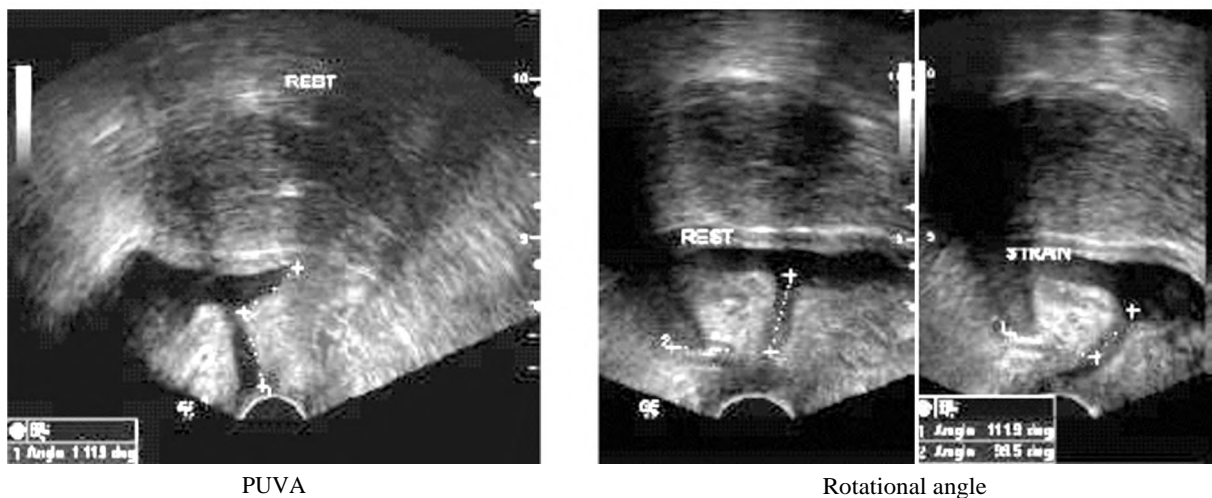


Fig. (2): TPUS with urethral hypermobility revealing increased PUVA (112 degrees), widening of the rotational angle (120 degrees), no bladder base descent, normal urethral wall thickness and vascularity with ALPP <60cm H<sub>2</sub>O that is seen in the urodynamic study.

Group B:

*Intrinsic sphincteric deficiency (ISD) which was characterized by:*

- 1- Reduction of the urethral wall thickness (normal mean values  $4.3\text{mm} \pm 5\text{mm}$ ) and its hypovascularity with increased urethral lumen diameter (5mm) (Fig. 3).
- 2- Opening of the bladder neck (BN) with coughing and straining (funneling).

Group C:

Characterized by the presence of causes of urethral hypermobility and ISD (Figs. 4,5).

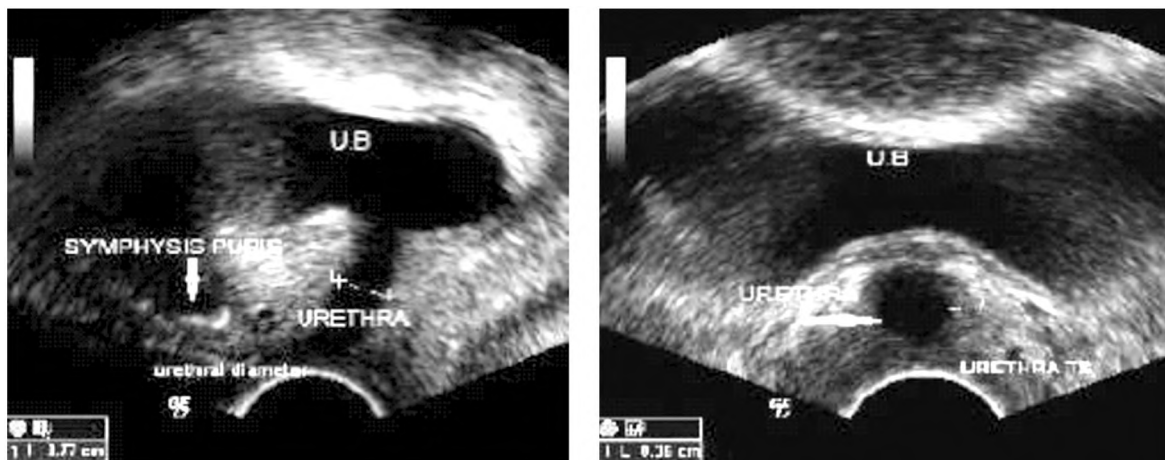
Based on urodynamic study of those 20 patients, 6 (30%) were negative and 14 (70%) were positive on urodynamics. Of the 14 positive urodynamics patients, 2 patients had no positive findings on transperineal ultrasound and the other 12 (60%)

patients had the following findings as shown in Table (2).

The ultrasound was in agreement with urodynamics diagnosis in nine cases (75%) patients.

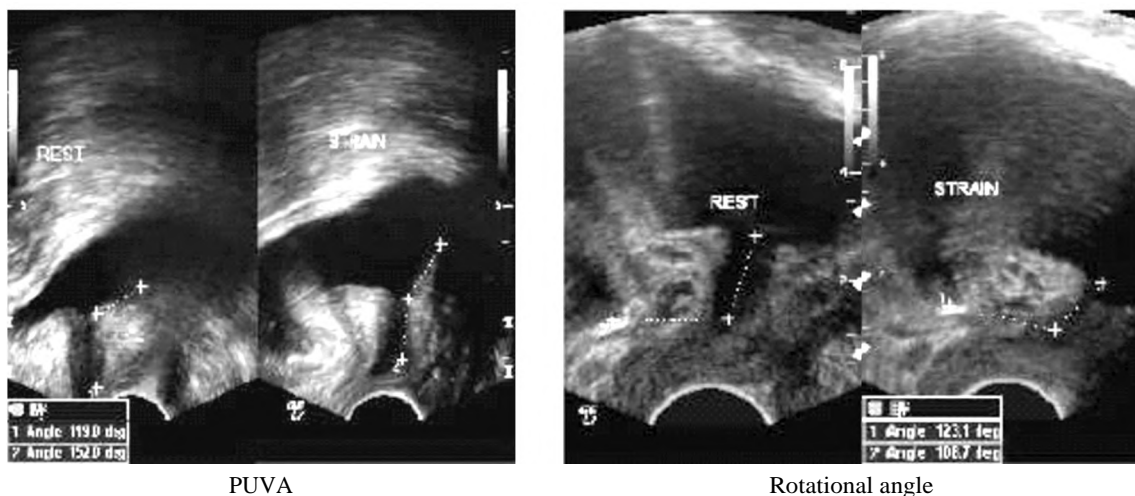
In three cases (25%) patients there was disagreement between urodynamics and ultrasound. From these three patients (two cases) 16% patients were diagnosed by ultrasound as having both urethral hypermobility and ISD, and one case (8%) of urethral hypermobility only, with no agreement to ALPP ( $>60\text{cm H}_2\text{O}$ ) that is seen on urodynamic study.

Hence the ultrasound was 100% in agreement with urodynamics diagnosis in patients with intrinsic sphincter deficiency. 71.5% in patients with both urethral hypermobility and intrinsic sphincter deficiency (Fig. 5), while 66.7% in patients with urethral hypermobility only.



Urethral luminal diameter and wall thickness

Fig. (3): TPUS (sagittal and axial) demonstrates decreased urethral wall thickness (34mm) and increased in urethral diameter (77mm) with normal PUVA and rotational angle in 45Y incontinent women with ISD (group B) seen by U/S and an agreement to ALPP  $<60\text{cm H}_2\text{O}$  that is seen on urodynamic study.



PUVA

Rotational angle

Fig. (4): Urethral hypermobility and ISD (group C) seen by U/S in (both resting and straining) with an agreement to ALPP  $<60\text{cm H}_2\text{O}$  on urodynamic study.

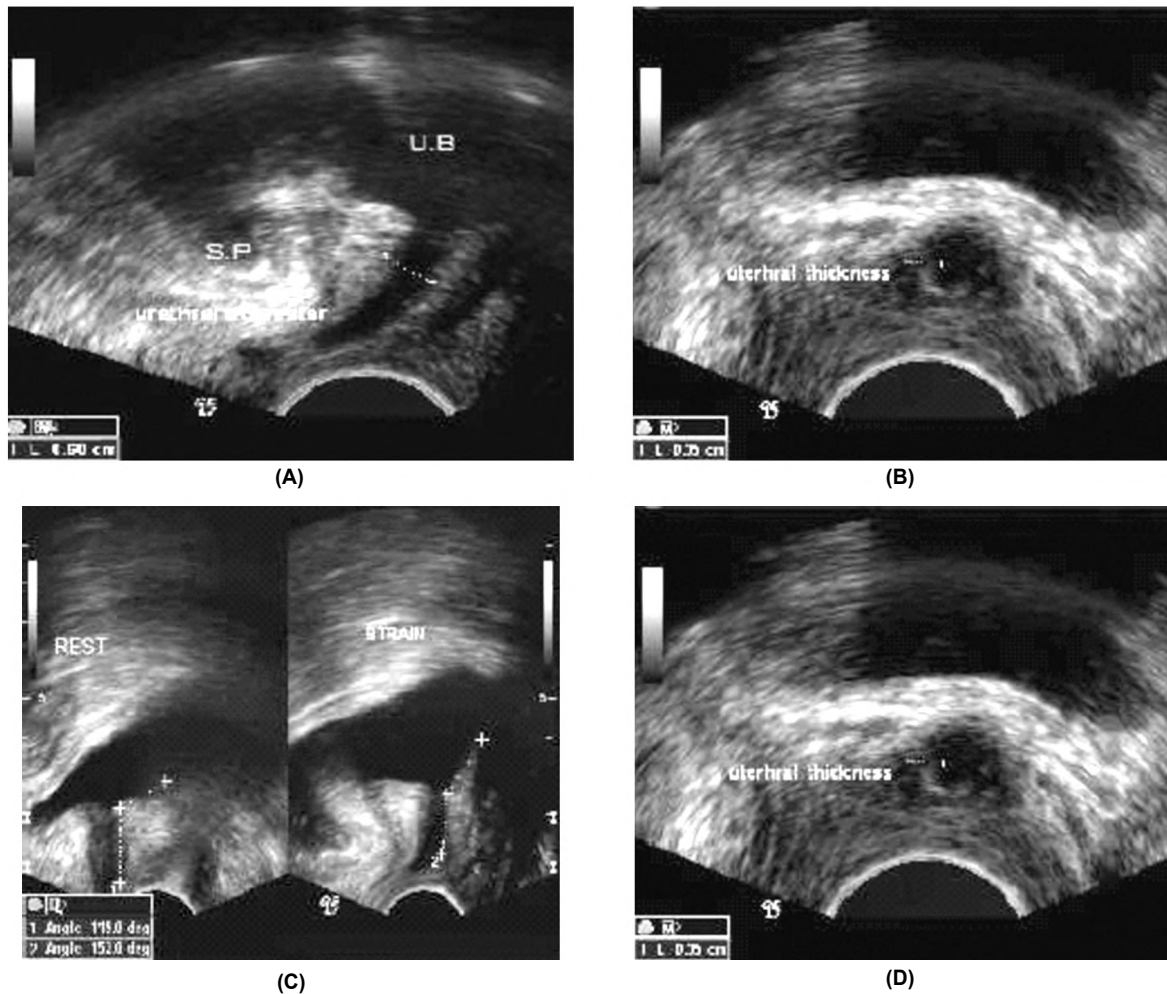


Fig. (5): TPUS showing increase in urethral diameter (60mm) A- And decreased urethral wall thickness (35mm) in B- As well as widening of the PUVA (152 degrees) C- And increased rotational movement (118 degrees) in D- US findings consistent with that of urethral hypermobility and ISD with an agreement to ALPP <60cm H<sub>2</sub>O that is seen on urodynamic study.

Table (2): Number of patients with positive urodynamic study in the three groups classified according to the ultrasonographic findings.

Patients group	Urodynamic examination			
	ALPP <60mm H <sub>2</sub> O	Detrouser instability	Low bladder capacity	No finding
Group A	2 (10%)	2 (10%)	–	1 (5%)
Group B	2 (10%)	2 (10%)		
Group C	5 (25%)	3 (15%)	2 (10%)	2 (10%)

**Discussion**

Urinary incontinence is a bothersome condition for many women, with an overall prevalence of approximately 40%. Stress, urge, and mixed urinary incontinence are the most common subtypes of urinary incontinence [1].

On clinical examination, bladder neck mobility assessment in the study of patients with urinary incontinence is mandatory. The Q-tip test does not produce reliable results [10]. Significant anatomical

changes on cystourethrography in SUI patients were recognized as long as 50 years ago. These changes included loss of the normal PUV angle (90-100°), so that the base of the bladder and the urethra are in line; funneling of the UV junction; and increased downward movement of the bladder base and rotation of the urethra on straining [6].

A video urodynamic study is still an expensive method to use routinely. Magnetic resonance imaging is another viable alternative but has not widely used in the investigation of urinary incontinence.

For all these reasons, ultrasonography is the principal modality for studies of the anatomy and functionality of the lower urinary tract in patients with a history of urinary leakage [11] Together with history, clinical examination and urodynamics, it has been shown to improve the accuracy of the diagnosis of the functional and morphological disorder [6].

Ultrasonography in the evaluation of urinary incontinence is an easy, inexpensive technique, and it is considered comfortable for most patients. Nowadays, it is becoming more widespread as a complementary examination in diagnostic investigations. In contrast to other radiologic techniques, it is a noninvasive procedure without exposure to X-ray hazards and with similar or even superior outcomes [11]. Perineal ultrasound especially has given good visualization of the bladder, bladder base, urethrovesical (UV) junction and the symphysis pubis [5]. In contrast to urodynamic evaluation, this technique enables the lesion causing the incontinence to be seen in real time (Fig. 4).

It is possible to see the posterior caudal movement of the urethrovesical junction and therefore to visualize urethral hypermobility [12].

This study shows the main morphological changes in UI with group A (urethral hypermobility) was increased posterior vesicle angle, increased rotational angle and funneling of the bladder neck. This was compatible with Chen et al., 2006 [7] who reported that, serial reports have indicated that the morphological features of UI are change in urethral angles, funneling of the bladder neck, and location of the urethrovesical junction being at the most dependent point of the lower urinary tract also César et al., 2011 [12] found that is possible to see the posterior caudal movement of the urethrovesical junction and therefore to visualize urethral hypermobility.

Intrinsic sphincter deficiency results from inadequate coaptation and compression due to loss of muscle strength and volume. In intrinsic sphincter deficiency, there is malfunction of the sphincter itself, which leads to an open vesical neck at rest and a low Valsalva leak point pressure [13].

Urethral hypermobility results from weakening of urethra supporting structures leading to downward displacement and rotation of the urethra. Both conditions lead to stress urinary incontinence, which results in leakage of urine with increase in intraabdominal pressure when the urethra opens concomitantly, such as during a cough, strain, laugh, or exercise. Most patients have elements of both disorders in varying degrees [14].

In our results we found the presence of high association of urinary incontinence with urethral hypermobility associated with intrinsic sphincter deficiency in group C (hypermobility and ISD) which they represented most of the positive ultrasonographic cases in our study. This finding also reported in the study of Arriola et al., [15] as they

found a high association of stress urinary incontinence with urethral hypermobility associated with intrinsic sphincter deficiency.

We also found that most of our cases who were positive by perineal Ultrasound with a significant urethral hypermobility, this was supported by Lavanga et al., 2000 [16] and Antovska [17] who reported a significant degree of urethral axis rotation in most of the patients group with incontinence compared to healthy individuals.

Oliveira et al., [11] reported that, urethral diameter values greater than 6mm highly suggest the presence of ISD, with accuracy evaluated around 84%. This was compatible with this study with accuracy about 82% related to urodynamic study.

We found there was no correlation between hypermobility of the bladder neck with findings of leak point pressure that was seen in group A. However, the urethral diameter showed a positive correlation with leak point pressure values of less than 60cm H<sub>2</sub>O seen in group B (ISD) and the same results had been described by Dietz and Clarke, 2001 [18] and also this finding was compatible with Oliveira et al., 2006 whose reported that, the hypermobility of the bladder neck did not correlate with findings of leak point pressure, however, the urethral diameter showed a positive correlation with leak point pressure values of less than 60cm H<sub>2</sub>O.

In conclusion, together with history, clinical examination and urodynamics, perineal ultrasound has been shown to improve the accuracy of the diagnosis of the functional and morphological disorder. In our study we found that the main morphological changes seen in UI were increase in the posterior vesicle angle and rotational angle, bladder neck descent, funneling of the bladder neck in group A and a reduction of the urethral wall thickness and increased in its luminal diameter. The highest association between a reduction of the urethral wall thickness and increased its luminal diameter seen by perineal ultrasound with decreased in ALPP <60mm H<sub>2</sub>O on urodynamic study was seen in patients group B (ISD).

We are aware of the limitation of this study in the form of relatively small number of patients and further future study with large number of patients is recommended.

#### *Conclusion:*

Together with history, clinical examination and urodynamics, transperineal ultrasound has been shown to improve the accuracy of the diagnosis

of the functional and morphological disorder. It is an easy, inexpensive technique, and it is considered comfortable for most patients. In our study we were found that the PU is easy, inexpensive technique, and it is considered comfortable for most patients.

Now it becomes more widespread as a complementary examination in diagnostic investigations in UI. The main morphological changes seen was widening of the posterior vesical angle, increased anterior urethrovesical angle, displacement of the bladder neck, funneling of the bladder neck, decreased urethral wall thickness and vascularity and increased urethral luminal diameter. And from our study for those 20 patients, there were 75% patients with MUI and 25% patients with SUI diagnosed clinically. We found the accuracy of PU in the diagnosis of UI was 82%. The highest agreements (100%) between decrease in the urethral wall thickness with it is hypovascularity and increased in the urethral diameter with the decreased in the ALPP (<60mm H<sub>2</sub>O) was seen in group A (ISD) while the lowest agreements (66.7%) was seen in group B (hypermobility only group).

### References

- 1- MCNANLEY A.R., DUECY E.E., GUNHILDE M., et al.: Symptom-based, clinical, and urodynamic diagnoses of urinary incontinence: Female Pelvic Med. Reconstr Surg., (16): 97-101, 2010.
- 2- BUCKLEY B.S. and LAPITAN M.C.: Prevalence of urinary incontinence in men, women, and children current evidence: Findings of the fourth international consultation on incontinence. AU, epidemiology committee of the fourth international consultation on incontinence, Paris SO Urology, 76 (2): 265, 2010.
- 3- DELANCEY J.O., CARDOZO L. and STASKIN D.: Textbook of female urology and urogynecology. 1<sup>st</sup> ed. london: Isis Medical Media., 112-124, 200 1.
- 4- SENDAG F., VIDINLI H., KAZANDI M., et al.: Role of perineal sonography in the evaluation of patients with stress urinary incontinence. Australian and new zealand Journal of Radiology of Obstetric and Gynecology, 43: 54-57, 2003.
- 5- NOVARA G. and ARTIBANI W.: Imaging for urinary incontinence-a contemporary perspective: Current Opinion Urology, (16): 219-223, 2006.
- 6- VIRTANEN H.S. and KIILHOLMA: Urogynecologic ultrasound is a useful aid in the assessment of female stress urinary incontinence-a prospective study with TVT Procedure: Int. Urogynecol. J., 13: 218-222, 2002.
- 7- CHEN H.Y., HUANG Y.L., HUNG Y.C., et al.: Evaluation of stress urinary incontinence by computer-aided vector-based perineal ultrasound: Acta. Obstetricia et Gynecologica., 85: 1259-1264, 2006.
- 8- PILONI V.L. and SPASSAFUMO L.: Sonography of the female pelvic floor: Pelviperineology, 26: 59-65, 2007.
- 9- ARTIBANI W. and CERRUTO M.A.: The role of imaging in urinary incontinence. BJU Int., 95: 699-703, 2005.
- 10- MANIAM P. and GOLDMAN H.B.: Removal of transurethral catheter during urodynamics may unmask stress urinary incontinence. J. Urol., 167: 171, 2002.
- 11 - OLIVEIRA F.R., RAMOS J.G. and COSTA S.M.: Translabial ultrasonography in the assessment of urethral diameter and intrinsic urethral sphincter deficiency. American Institute of Ultrasound in Medicine, 25: 1153-1158, 2006.
- 12- CÉSAR R.R.L., CÉSAR F.R.L., ROSALES E.A., et al.: Ultrasonography in female non-neurological urinary incontinence evaluation. Rev. Mex. Urol., 71 (6): 319-324, 2011.
- 13- MACURA K.J., GENADRY R.R. and BLUEMKE D.A.: MR imaging of the female urethra and supporting ligaments in assessment of urinary incontinence: Spectrum of Abnormalities. Continuing medical education. Radiographics., 26: 1135-1149, 2006.
- 14- SANTIAGU S.K., ARIANAYAGAM M., WANG A., et al.: Urinary incontinence pathophysiology and management outline. Australian Family Physician, 3 7: 106-110, 2008.
- 15-ARRIOLA A.P., DALENZ V. S. and SCHANZ P.J.: Study of female urinary incontinence with single channel urodynamics. Comparison of the symptoms on admission. Neurological and Urodinamic Urology, 62 (2): 115-121, 2009.
- 16- LAVANGA M., CHIONO L., SCHENONE M., et al.: Translabial ultrasonography in the diagnosis of stress urinary incontinence in women. Arch. Ital. Urol. Andrology, 72: 228-234, 2000.
- 17- ANTOVSKA V.S.: Ultrasound characteristics of patients with urinary stress incontinence with or without genital Prolapse. Korean. J. Urol. October., 53 (10): 691-698, 2012.
- 18- DIETZ H.P. and CLARKE B.: The urethral pressure profile and ultrasound imaging of the lower urinary tract. Int. Urogynecol J. Pelvic. Floor. Dysfunction, 12: 38-41, 2001.