

Syddansk Universitet

Utility of Lung Ultrasound in Near-Drowning Victims

Laursen, Christian Borbjerg; Rømhild Davidsen, Jesper; Madsen, Poul Henning

Published in:
B M J Case Reports

DOI:
[10.1136/bcr.01.2012.5687](https://doi.org/10.1136/bcr.01.2012.5687)

Publication date:
2013

Document version
Publisher's PDF, also known as Version of record

Citation for published version (APA):
Laursen, C. B., Rømhild Davidsen, J., & Madsen, P. H. (2013). Utility of Lung Ultrasound in Near-Drowning Victims. B M J Case Reports, [bcr0120125687]. DOI: 10.1136/bcr.01.2012.5687

General rights

Copyright and moral rights for the publications made accessible in the public portal are retained by the authors and/or other copyright owners and it is a condition of accessing publications that users recognise and abide by the legal requirements associated with these rights.

- Users may download and print one copy of any publication from the public portal for the purpose of private study or research.
- You may not further distribute the material or use it for any profit-making activity or commercial gain
- You may freely distribute the URL identifying the publication in the public portal ?

Take down policy

If you believe that this document breaches copyright please contact us providing details, and we will remove access to the work immediately and investigate your claim.

Novel diagnostic procedure

Utility of lung ultrasound in near-drowning victims

Christian B Laursen, Jesper Rømhild Davidsen, Poul Henning Madsen

Department of Respiratory Medicine, Odense University Hospital, Odense, Denmark

Correspondence to Dr Christian B Laursen, christian.b.laursen@ouh.regionyddanmark.dk**Summary**

Drowning and near-drowning are common causes of accidental death worldwide and respiratory complications such as non-cardiogenic pulmonary oedema, acute respiratory distress syndrome and pneumonia are often seen. In other settings lung ultrasound can accurately diagnose these conditions; hence lung ultrasound may have a potential role in the evaluation of drowning or near-drowning victims. In this case report the authors describe a 71-year-old man who was brought to hospital with acute respiratory failure after a near-drowning accident. Lung ultrasound showed multiple B-lines on the anterior and lateral surfaces of both lungs, consistent with pulmonary oedema. Focus assessed transthoracic echocardiography showed no pericardial effusion and a normal global left ventricular function. Based on these findings the patient was diagnosed as having non-cardiogenic pulmonary oedema. Subsequent chest x-ray showed bilateral infiltrates consistent with pulmonary oedema. The case report emphasises the clinical value of lung ultrasound in the evaluation of a near-drowning victim.

BACKGROUND

Drowning and near-drowning are common causes of accidental death worldwide and remain leading causes of accidental death among young children in industrialised countries. Respiratory complications such as non-cardiogenic pulmonary oedema, acute respiratory distress syndrome (ARDS) and pneumonia are often seen.¹ In order to diagnose these conditions chest x-ray (CXR) is recommended at baseline. However, as the CXR may underestimate the severity of lung injury further diagnostic tools are warranted.^{1 2}

Lung ultrasound (LUS) can accurately diagnose, quantify and monitor non-cardiogenic pulmonary oedema, ARDS and pneumonia. Hence many investigators have found LUS to be superior to conventional chest x-ray in these settings.³⁻⁵ Thus, LUS may have a potential impact on the evaluation of drowning or near-drowning victims.

CASE PRESENTATION

A 71-year-old man with atrial fibrillation, hypercholesterolaemia, arterial hypertension, ischaemic heart disease and type 2 diabetes mellitus was brought to hospital after accidental near-drowning in seawater. On arrival on scene of the accident, the emergency medical services recorded a transcutaneous oxygen saturation of 55%. Supplemental oxygen was administered, and the patient was evacuated to the level 1 trauma centre at this hospital.

INVESTIGATIONS

On admission, the patient was found alert and only mildly distressed. No signs or history of trauma was noticed. He was systematically evaluated with the ABCDE approach. (A) Upper airways were patent without support. (B) No cyanosis on high-concentration oxygen. Both sides of the chest were rising on inspiration, and bilateral crackles were

present on lung auscultation. Transcutaneous oxygen saturation was 83% on 8 litres of oxygen/min, increasing to 93% on 15 litres of oxygen/min using a non-rebreathing system. Respiratory frequency was 22/min. (C) The skin was cold, but dry. Blood pressure was 134/68 mm Hg and pulse 82/min. No neck-vein distension was present and the trachea was in the mid-line. (D) Glasgow coma scale score was 15. Blood-glucose 8.3 mmol/litre. Spontaneous movement of all extremities was noticed. (E) Rectal temperature was 35.0°C.

With the patient in the supine position LUS was performed and multiple B-lines on the anterior and lateral surfaces of both lungs were found (figure 1). Lung sliding was present, and the pleural line was normal with no fragmentations. No pleural effusion or consolidations were seen. Focus assessed transthoracic echocardiography (FATE) showed no pericardial effusion and a normal global left ventricular function.

Arterial blood gas analysis on arrival: pH=7.34, pCO₂=5.42 kPa, pO₂=6.76 kPa, standard bicarbonate=21.2 mmol/l and lactate=3.8 mmol/l. Venous blood analyses were notable for leucocytosis. Electrolytes and tests for renal and liver function were normal. ECG showed atrial fibrillation with an average ventricular action of 75 beats/min, but no signs of acute myocardial infarction.

CXR taken 2 h after LUS showed bilateral infiltrates consistent with pulmonary oedema (figure 1).

DIFFERENTIAL DIAGNOSIS

The findings on LUS and CXR were diagnostic of pulmonary oedema, with no signs of ARDS or pneumonia. A diagnosis of cardiogenic pulmonary oedema secondary to myocardial ischemia was not consistent with neither the clinical presentation and history, the ECG nor the FATE examination, leaving the final diagnosis of non-cardiogenic pulmonary oedema.

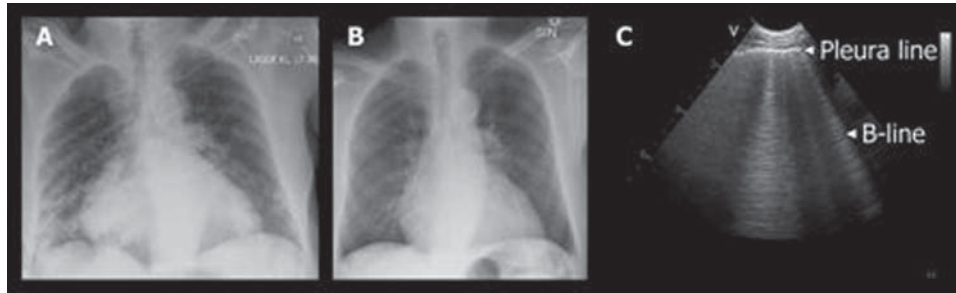


Figure 1 (A) Chest x-ray taken 2 h after arrival at the hospital, showing bilateral infiltrates consistent with pulmonary oedema and a widened heart shadow. (B) Chest x-ray taken 3 days after arrival. The bilateral infiltrates have disappeared, the heart shadow is unaltered. (C) Lung ultrasound image from a patient with pulmonary oedema illustrating the same findings as were seen when lung ultrasound was performed on the near-drowning victim. The horizontal pleural line appears normal and multiple vertical B-lines are present. The multiple B-lines were present on the anterior and lateral surfaces of both lungs consistent with pulmonary oedema.

TREATMENT

The patient was closely monitored and treated with high-flow oxygen via a non-rebreathing mask.

OUTCOME AND FOLLOW-UP

On the third day, the patient was reaching his usual state of health, which in combination with a normalised CXR (figure 1) allowed discharge from the hospital.

DISCUSSION

To our knowledge, this case report is the first to describe the use of LUS in the evaluation of a patient admitted to hospital after a near-drowning accident. Point-of-care LUS is already widely used in trauma, intensive care and emergency medicine, and it would be easy to apply the same principles in the evaluation of acute respiratory failure in a drowning or near-drowning victim.

In other types of pulmonary oedema LUS has been shown capable to monitor changes in the degree of interstitial oedema.³ Thus, theoretically repeated LUS examinations could also be used as an easy bedside tool to monitor the response of initiated treatment.

This case report emphasises the clinical value of LUS in the evaluation of a near-drowning victim. As the evidence in this field is sparse, further studies should be conducted in order to evaluate whether LUS can be legitimated as a diagnostic tool in the evaluation of drowning and near-drowning patients.

Learning points

- ▶ LUS is able to diagnose non-cardiogenic pulmonary oedema in near-drowning victims.
- ▶ The principles of LUS used in other respiratory emergencies seem to be applicable in the evaluation of drowning and near-drowning victims.
- ▶ LUS should be considered as a bedside monitoring tool in drowning and near-drowning victims with respiratory failure.

Acknowledgements Chest x-ray images kindly provided by the Department of Radiology at Odense University Hospital.

Competing interests None.

Patient consent Obtained.

REFERENCES

1. **Salomez F**, Vincent JL. Drowning: a review of epidemiology, pathophysiology, treatment and prevention. *Resuscitation* 2004;**63**:261–8.
2. **Gregorakos L**, Markou N, Psalida V, *et al*. Near-drowning: clinical course of lung injury in adults. *Lung* 2009;**87**:93–7.
3. **Noble VE**, Murray AF, Capp R, *et al*. Ultrasound assessment for extravascular lung water in patients undergoing hemodialysis. Time course for resolution. *Chest* 2009;**135**:1433–9.
4. **Lichtenstein D**, Goldstein I, Mourgeon E, *et al*. Comparative diagnostic performances of auscultation, chest radiography, and lung ultrasonography in acute respiratory distress syndrome. *Anesthesiology* 2004;**100**:9–15.
5. **Reissig A**, Kroegel C. Sonographic diagnosis and follow-up of pneumonia: a prospective study. *Respiration* 2007;**74**:537–47.

This pdf has been created automatically from the final edited text and images.

Copyright 2012 BMJ Publishing Group. All rights reserved. For permission to reuse any of this content visit <http://group.bmj.com/group/rights-licensing/permissions>.
BMJ Case Report Fellows may re-use this article for personal use and teaching without any further permission.

Please cite this article as follows (you will need to access the article online to obtain the date of publication).

Laursen CB, Davidsen JR, Madsen PH. Utility of lung ultrasound in near-drowning victims. *BMJ Case Reports* 2012;10.1136/bcr.01.2012.5687, Published XXX

Become a Fellow of BMJ Case Reports today and you can:

- ▶ Submit as many cases as you like
- ▶ Enjoy fast sympathetic peer review and rapid publication of accepted articles
- ▶ Access all the published articles
- ▶ Re-use any of the published material for personal use and teaching without further permission

For information on Institutional Fellowships contact consortiasales@bmjgroup.com

Visit casereports.bmj.com for more articles like this and to become a Fellow

Keep up to date with all published cases by signing up for an alert (all we need is your email address) <http://casereports.bmj.com/cgi/alerts/etoc>