

Received: 2014.11.17  
Accepted: 2014.11.24  
Published: 2015.03.06

ISSN 1941-5923  
© Am J Case Rep, 2015; 16: 136-139  
DOI: 10.12659/AJCR.893065

## Sinus Node Dysfunction Requiring Permanent Pacemaker Implantation in a Young Adult with Klinefelter Syndrome

Authors' Contribution:  
Study Design A  
Data Collection B  
Statistical Analysis C  
Data Interpretation D  
Manuscript Preparation E  
Literature Search F  
Funds Collection G

ADEF 1 **Ahmet Karagöz**  
ADEF 2 **Oğuz Dikbaş**  
BE 3 **Erhan Teker**  
BD 1 **Aslı Vural**  
EF 4 **Zeki Yüksel Günaydın**  
EF 4 **Osman Bektaş**

1 Department of Cardiology, Giresun University, Giresun, Turkey  
2 Department of Endocrinology, Giresun University, Giresun, Turkey  
3 Cardiology Clinic, Prof. Dr. A. İlhan Özdemir State Hospital, Giresun, Turkey  
4 Department of Cardiology, Ordu University, Ordu, Turkey

**Corresponding Author:** Ahmet Karagöz, e-mail: [drahmetkgz@hotmail.com](mailto:drahmetkgz@hotmail.com)  
**Conflict of interest:** None declared

**Patient:** Male, 22  
**Final Diagnosis:** Sinus node dysfunction  
**Symptoms:** Bradycardia • lassitude  
**Medication:** —  
**Clinical Procedure:** Pacemaker implantation  
**Specialty:** Cardiology





**Objective:** Unusual clinical course  
**Background:** Klinefelter syndrome is the most common genetic cause of male infertility and affects approximately 1 in 500 live births. Although accompanying cardiac disorder is not a specific feature of Klinefelter syndrome, rarely associated anomalies such as mitral valve prolapse, atrial septal defect, ventricular septal defect, tetralogy of Fallot, patent ductus arteriosus, and hypertrophic obstructive cardiomyopathy have been reported. A clear association between Klinefelter syndrome and arrhythmic disorders has not yet been demonstrated.

**Case Report:** We report a case of a sinus node dysfunction that required permanent pacemaker implantation in a young adult with Klinefelter syndrome. The patient was consulted to cardiology clinic due to bradycardia. On physical examination, no cardiac abnormality was detected except for bradycardia. Holter results showed sinus arrhythmia with a minimum heart rate of 33 bpm and maximum of 154 bpm. There were 3612 ventricular premature beats, 30 ventricular pairs, 804 supraventricular premature beats, 7 supraventricular pairs, and 4 supraventricular runs, the longest of which was 5 beats. The patient had defined dizziness and nausea during Holter monitoring. Electrophysiological study (EPS) was planned because existing findings indicated risk of cardiac syncope. Findings of EPS were interpreted as sinus node dysfunction. A permanent pacemaker implantation was performed and the patient has been free of symptoms since.

**Conclusions:** This concomitance should be kept in mind when examining patients with Klinefelter syndrome with bradycardia and/or syncope. It is easily mistaken for epilepsy, which is a commonly encountered abnormality in Klinefelter syndrome.

**MeSH Keywords:** Klinefelter Syndrome • Pacemaker, Artificial • Sick Sinus Syndrome

**Full-text PDF:** <http://www.amjcaserep.com/abstract/index/idArt/893065>

 1148  —  4  12



## Background

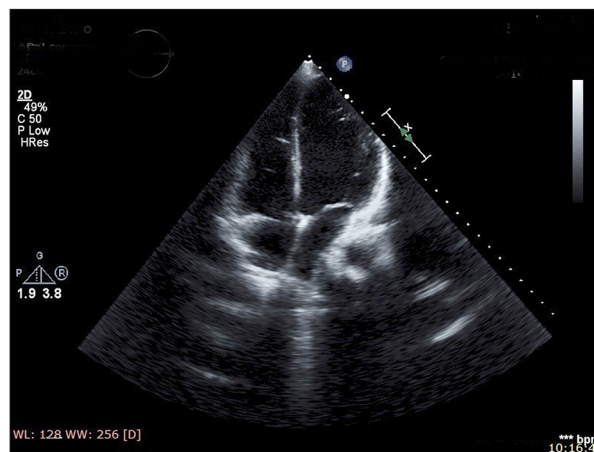
Klinefelter syndrome (KS) is the most frequently seen numerical sex chromosomal abnormality in men and is characterized by the presence of an additional X chromosome (XXY). Although KS classically has 47, XXY chromosomal abnormality, many variants have been described. This sex chromosome aneuploidy affects approximately 1 in 500 live births [1]. Nevertheless, most of the affected patients are overlooked due to phenotypic variation and lack of a widespread and dedicated screening program. It is estimated that only 25% of men with KS are diagnosed during their lifetime, with fewer than 10% being diagnosed before puberty [2]. Therapeutic modalities consist of developmental therapy, hormonal therapy, and fertility preservation. KS is the most common genetically determined cause of male infertility, and is associated with higher risk of various diseases (e.g., cardiovascular disorders) and malignant tumors (e.g., breast cancer and germinal tumors). Cardiac anomalies frequently accompany autosomal trisomies, but are relatively rare in sex chromosome trisomies. KS has been associated with cardiac anomalies such as mitral valve prolapse, atrial septal defect (ASD), ventricular septal defect, tetralogy of Fallot, patent ductus arteriosus, and hypertrophic obstructive cardiomyopathy. We report a case of a 20-year-old patient with KS presenting with symptomatic sinus bradycardia that required permanent pacemaker implantation.

## Case Report

A 22-year-old man was admitted to our endocrinology department with the complaint of lassitude and palpitation. He stated that palpitation had been present for a long time.

He had been a smoker for 4 years and had epilepsy since age 7 years. When he was 19 years old, epilepsy was diagnosed according to EEG test report. The initial diagnosis of KS was made during health check before military service. Typical eunuchoidal stature, laboratory results compatible with hypergonadotropic hypogonadism, and 47, XXY cytogenetic analysis revealed KS.

On physical examination, blood pressure and pulse rate were 100/50 mmHg and 42/minute, respectively. No pathology was found in systemic physical examination. He was eunuchoidal in appearance, with his arm span 185 cm and height 178 cm. Underdeveloped testicles and penis were observed on physical examination. His blood glucose, lipid, electrolytes (sodium, potassium, calcium, and magnesium), renal, and hepatic function test results were in normal laboratory reference ranges. Complete blood count was normal. Hormonal evaluation showed: cortisol 11.22 (6.2–19.4 µg/dl), prolactin 264 (86–324 µIU/ml), TSH 1.7 (0.27–4.2 µU/ml), FSH 40.62 (1.5–12.5



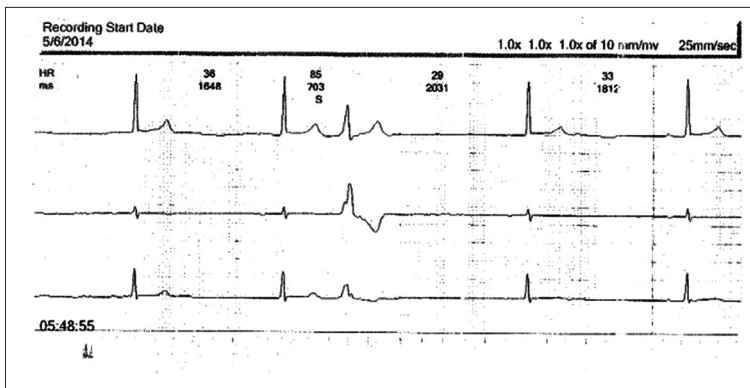
**Figure 1.** Detailed echocardiographic evaluation revealed normal findings.

mIU/ml), LH 28.86 (1.7–8.6 mIU/ml), and testosterone 4.8 (2.5–8.4 ng/ml). His bone mineral density was L1–4 T score  $-2$  SD (0.876 g/cm<sup>2</sup>) and femur neck T score  $-0.3$  SD (0.884 g/cm<sup>2</sup>). We prescribed testosterone and calcium.

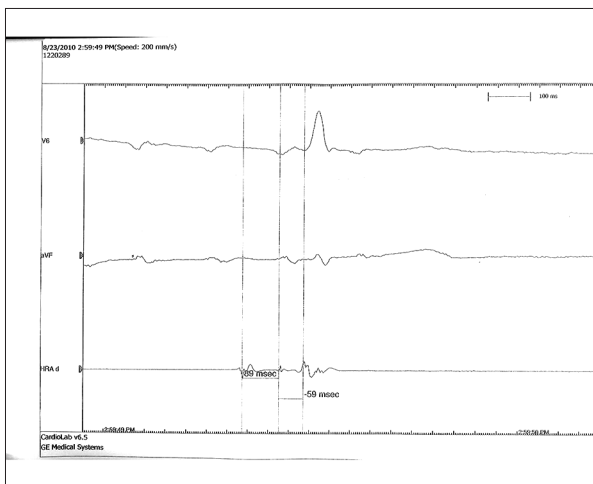
The patient was consulted to cardiology clinic due to bradycardia. He had no history of cardiovascular disease. Electrocardiography revealed sinus bradycardia with a heart rate of 42 bpm. He complained of palpitation and syncope attacks. On physical examination, no cardiac abnormality was detected except for bradycardia. Chest X-ray revealed a typical appearance with normal cardiothoracic ratio. Detailed echocardiography revealed normal findings (Figure 1).

To clarify the etiology of bradycardia and syncope, 24-h Holter monitoring was performed. Holter report showed sinus arrhythmia with a minimum heart rate of 33 bpm and maximum 154 of bpm (Figure 2). There were 3612 ventricular premature beats, 30 ventricular pairs, 804 supraventricular premature beats, 7 supraventricular pairs, and 4 supraventricular runs, the longest of which was 5 beats. The patient also had dizziness and nausea during Holter monitoring. An electrophysiological study (EPS) was planned because existing findings showed risk of cardiac syncope.

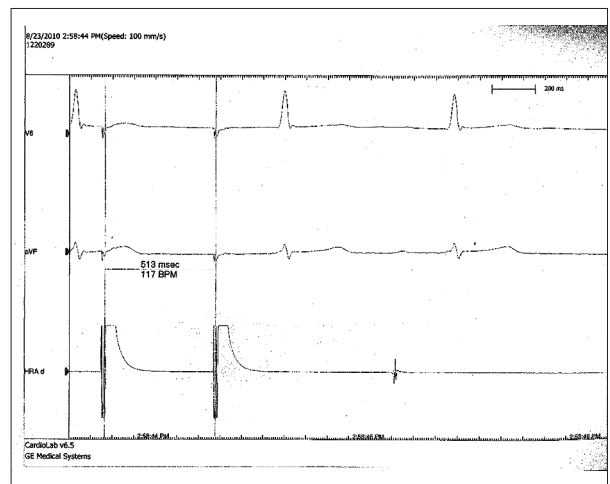
The patient had a history of epilepsy, but he had been free of seizures for a long time and the characteristics of syncope attack depicted by him were not compatible with a seizure. The patient underwent EPS. BCL (basal cycle length), AH, and HV intervals were 1010 msec, 89 msec, and HV 59 msec, respectively (Figure 3). Sinus node recovery time (SNRT) and corrected sinus node recovery time (cSNRT) were 1400–1600 msec and 390–590 msec, respectively. Atrioventricular Wenckebach interval was 520 msec (Figure 4). After administration of atropine, BCL, SNRT, and AVW intervals were 800 msec, 880 msec, and 380 msec, respectively.



**Figure 2.** Demonstration of sinus arrhythmia with a minimum heart rate of 33 bpm in Holter report.



**Figure 3.** Electrophysiological study indicated sinus node dysfunction.



**Figure 4.** Demonstration of sinus node dysfunction in electrophysiological study.

Findings of EPS were interpreted as sinus node dysfunction. Two days after EPS, the patient had a new syncope attack. Permanent pacemaker implantation was performed and the patient has been free of symptoms since.

## Discussion

KS is the most common sex chromosome anomaly and is associated with motor, cognitive, and behavioral dysfunction, tumors, vascular disease, and endocrine/metabolic and autoimmune disease [3]. Although an accompanying cardiac disorder is not a specific feature of Klinefelter syndrome, rarely associated anomalies such as mitral valve prolapse, atrial septal defect (ASD), ventricular septal defect, tetralogy of Fallot, patent ductus arteriosus, and hypertrophic obstructive cardiomyopathy have been reported [4–7]. Cardiovascular abnormalities in KS seem to be related to primary chromosomal abnormalities rather than hypogonadism or other hormonal conditions. Klinefelter syndrome is associated with a significantly reduced life expectancy. Cardiovascular pathologies are the most common parameters determining life expectancy, but little is known

about the nature of the underlying cardiovascular abnormalities. Recently, Pasqually et al. reported on cardiovascular abnormalities in Klinefelter syndrome [8], demonstrating increased frequency of left ventricular diastolic dysfunction, impaired cardiopulmonary performance, chronotropic incompetence, and increased intima-media thickness in patients with KS [8]. These findings highlight the increased mortality in patients with KS. These findings were irreversible, even with testosterone replacement therapy. Agarwal et al. reported multiple cardiac defects, including partial anomalous pulmonary venous connection, atrial septal defect, and pulmonary arterial hypertension, in an elderly man with KS [9]. Although rarely hypertrophic cardiomyopathy and coronary arteriovenous fistula were also reported [4,10]. The association between KS and mitral valve prolapse is relatively well established when compared to other accompanying cardiac disorders [11]. Consequently, although a concomitant cardiac disorder is not a diagnostic criteria or an indispensable characteristic of KS, the abnormalities discussed above may accompany this chromosomal entity.

There are a few case reports pertaining to arrhythmia in KS. Hainstock et al. reported a case with a postural orthostatic

tachycardia syndrome (POTS) in a patient with KS [12]. The only case requiring permanent pacemaker implantation was presented by Yoshida et al. [10], who reported an elderly man with KS associated with hypertrophic cardiomyopathy, sick sinus syndrome, and coronary arteriovenous fistula. The patient was 69 years old and hence old enough to develop degenerative conduction disturbance independent of the chromosomal abnormality. Therefore, it may have been either a component of KS or a coincidental finding. The other report in the literature on conduction disturbance revealed a high prevalence of chronotropic incompetence in patients with KS

[8]. To the best of our knowledge, our report is the first to be published on the development of permanent pacemaker-required arrhythmia in the absence of organic heart disease in a young adult with KS.

## Conclusions

This concomitance should be kept in mind while examining patients with Klinefelter syndrome with bradycardia and/or syncope. It is easily mistaken for epilepsy, which is common in KS.

## References:

1. Nielsen J, Wohler M. Sex chromosome abnormalities found among 34,910 newborn children: results from a 13-year incidence study in Arhus, Denmark. *Birth Defects Orig Artic Ser*, 1990; 26(4): 209–23
2. Bojesen A, Juul S, Gravholt CH: Prenatal and postnatal prevalence of Klinefelter syndrome: a national registry study. *J Clin Endocrinol Metab*, 2003; 88(2): 622–26
3. Sokol RZ: It's not all about the testes: medical issues in Klinefelter patients. *Fertil Steril*, 2012; 98(2): 261–65
4. Ahmed S, Hafeez S, Ali N, Ahmed T: Hypertrophic cardiomyopathy in a patient of Klinefelter syndrome – a rare association. *J Coll Physicians Surg Pak*, 2009; 19(8): 520–22
5. Edlow JB, Shapiro LR, Hsu LY, Hirschhorn K: Neonatal Klinefelter's syndrome. *Am J Dis Child*, 1969; 118(5): 788–91
6. Gautier M, Nouaille J: [2 cases of Klinefelter's Syndrome associated with a Tetralogy of Fallot. (routine study of Barr's corpuscle in 210 infants with congenital cardiopathies)]. *Arch Fr Pediatr*, 1964; 21: 761–63 [in French]
7. Murray D, Bucher R, Miller AB et al: Klinefelter syndrome associated with atrial septal defect and prolapse of the mitral valve. *J Fla Med Assoc*, 1976; 63(6): 421–22
8. Pasquali D, Arcopinto M, Renzullo A et al: Cardiovascular abnormalities in Klinefelter syndrome. *Int J Cardiol*, 2013; 168(2): 754–59
9. Agarwal S, Dekam MJ: Multiple cardiac anomalies in an elderly man with Klinefelter's syndrome. *Singapore Med J*, 2011; 52(1): e15–17
10. Yoshida K, Ryu T, Ogata T et al: An elderly man with Klinefelter syndrome associated with hypertrophic cardiomyopathy, sick sinus syndrome, and coronary arteriovenous fistula. *Jpn Circ J*, 1998; 62(3): 222–24
11. Fricke GR, Mattern HJ, Schweikert HU, Schwanz G: Klinefelter's syndrome and mitral valve prolapse. an echocardiographic study in twenty-two patients. *Biomed Pharmacother*, 1984; 38(2): 88–97
12. Hainstock MR, Gruchala NE, Fike N et al: Postural orthostatic tachycardia in a teenager with Klinefelter syndrome. *Congenit Heart Dis*, 2008; 3(6): 440–42