

## Mastocytosis: Pathology, genetics, and current options for therapy

PETER VALENT<sup>1</sup>, CEM AKIN<sup>2</sup>, WOLFGANG R. SPERR<sup>1</sup>, MATTHIAS MAYERHOFER<sup>1</sup>,  
MANUELA FÖDINGER<sup>3</sup>, ROBERT FRITSCHÉ-POLANZ<sup>3</sup>, KARL SOTLAR<sup>4</sup>,  
LUIS ESCRIBANO<sup>5</sup>, MICHEL AROCK<sup>6</sup>, HANS-PETER HORNY<sup>7</sup>, & DEAN D. METCALFE<sup>8</sup>

<sup>1</sup>Department of Internal Medicine I, Division of Hematology & Hemostaseology, Medical University of Vienna, Austria;

<sup>2</sup>Division of Allergy, University of Michigan, Ann Arbor, MI, USA; <sup>3</sup>Clinical Institute of Medical and Chemical Laboratory Diagnostics, Medical University of Vienna, Austria; <sup>4</sup>Institute of Pathology, University of Tübingen, Germany; <sup>5</sup>Mast Cell Unit, Hospital Ramón y Cajal, Madrid, Spain; <sup>6</sup>CNRS Unit UMR8147 'Cytokines, hematopoiesis, and immune response', Faculté de Pharmacie, Paris, France; <sup>7</sup>Institute of Pathology, University of Lübeck, Germany; and <sup>8</sup>Laboratory of Allergic Diseases, NIAID/NIH, Bethesda, MD, USA

### Abstract

Mast cell disorders are defined by an abnormal accumulation of tissue mast cells (MCs) in one or more organ systems. Symptoms in mastocytosis result from MC-derived mediators and, less frequently, from destructive infiltration of MCs. Cutaneous mastocytosis (CM) is a benign disease of the skin and may regress spontaneously. Systemic mastocytosis (SM) is a persistent disease in which a somatic *c-kit* mutation at codon 816 is usually detectable in MCs and their progenitors. The clinical course in these patients is variable ranging from asymptomatic for years to highly aggressive and rapidly devastating. The WHO discriminates five categories of SM: indolent SM (ISM), aggressive SM (ASM), SM with associated clonal hematological non-MC-lineage disease (AHNMD), and mast cell leukemia (MCL). The *c-kit* mutation D816V is quite common and may be found in all SM-categories. In SM-AHNMD, additional genetic abnormalities have been reported, whereas no additional defects are yet known for ASM or MCL. Patients with ISM and CM are treated with "mediator-targeting" drugs, whereas patients with ASM or MCL are candidates for cytoreductive therapy. The use of "Kit-targeting" tyrosine kinase inhibitors such as STI571 (Imatinib, Gleevec), has also been suggested. However, the D816V mutation of *c-kit* is associated with relative resistance against STI571. Therefore, these patients require alternative targeted drugs or new drug-combinations. In patients with SM-AHNMD, separate treatment plans for the SM-component and the AHNMD should be established. Examples include the use of STI571 in patients with SM plus hypereosinophilic syndrome (SM-HES) and the FIPL1/PDGFR $\alpha$  fusion gene target, or chemotherapy for eradication of AML in patients with SM-AML.

**Keywords:** mast cells, mastocytosis, classification, criteria

### Biology of mast cells – basic concepts

Mast cells are hematopoietic cells with unique functional properties and a distinct composition of mediators and antigens [1,2]. In contrast to basophils and other leukocytes, MCs are long-lived cells with an estimated life span of several months. When mature, MCs reside in vascularized tissues in diverse organs, often in vicinity to smaller or larger blood vessels or nerve fibers [1,2]. In routinely processed tissue sections, MCs can usually be identified by their content of metachromatic granules [1,2]. Within these granules, MCs store vasoactive and immunoregulatory mediators including histamine,

heparin, and cytokines [1–3]. Several mediators including histamine are released from MCs in response to aggregation of the high affinity IgE receptor, activation through complement receptors, or activation by cytokines [1–3]. Other mediators, such as tryptase, are both constitutively secreted from MCs and released after MC activation. Baseline tryptase levels can be measured in the serum as an MC-related marker believed to correlate with the total MC burden in normal subjects as well as in patients with MC proliferative disorders [4–6].

Mast cells reportedly are derived from hematopoietic progenitor cells which reside in the bone marrow, but can also be detected in the peripheral

blood [7–11]. It is assumed that precommitted and MC-committed progenitors are circulating cells that have the capacity of transmigration, and undergo differentiation and maturation in vascularized tissues [12]. Several cytokines and the local microenvironment are considered to contribute to growth and differentiation of MCs in the tissues. The most important cytokine is mast cell growth factor, also termed stem cell factor (SCF), or KIT-ligand. This stroma cell-derived cytokine induces the development of MCs from their uncommitted and MC-committed progenitors [8–15]. Mast cell progenitors in turn, express a specific receptor for SCF [10,12,16]. This tyrosine kinase-receptor (KIT) is encoded by the *c-kit* proto-oncogene [12,16]. KIT and SCF are considered essential for the development and differentiation of MCs. Supporting this concept, defects in *c-kit*- or the *scf* gene in mice lead to MC-deficiency [17,18]. By contrast, “gain-of-function mutations” in the *c-kit* proto-oncogene are associated with enhanced survival (and under certain circumstances with autonomous growth) of MCs and their progenitors [19,20]. Such mutations, particularly *c-kit* D816V, are frequently detected in patients with systemic mastocytosis (SM) [21–26].

### Pathogenesis of mastocytosis – current status

The common pathogenetic hallmark of mastocytosis, shared by all disease variants, is the focal accumulation (clustering) of MCs in various organs [27–30]. Depending on the disease-variant, MCs and their progenitors may also show increased proliferative capacity compared to normal MCs [27–30]. However, to date, little is known concerning pathogenetic factors that contribute to the development of disease variants and disease progression. Likewise, so far, no clear pathogenetic concept has been presented for cutaneous mastocytosis, a disorder apparently confined to the skin that often presents as a self-limiting disease process, particularly in children. It remains unclear whether (all) these patients suffer from a monoclonal MC accumulation in the skin. In fact, only a few of these patients reportedly exhibit mutations in *c-kit*. It has been hypothesized that if such a *c-kit* mutation is present at codon 816, the disease process may often be programmed to become systemic and to persist [23,24,31].

In systemic mastocytosis (SM), monoclonality of the disease is well established in most instances, and several pathogenetic concepts have been developed [32–34]. The most important concept relates to the *c-kit* point mutation D816V, that is detectable in the majority (> 80%) of all patients with SM [20–

26,35]. The D816V *c-kit* mutation is considered to represent an important “hit” contributing to disease development and possibly to differentiation/maturation and abnormal clustering of neoplastic cells (MC, progenitors) in the tissues [19,20]. By contrast, this mutation alone may be unable to act as a proliferation-enhancing oncogene in all cases [36]. However, *c-kit* D816V may play an important and possibly causative role in indolent SM, where the pathologic hallmark is MC differentiation (from immature myeloid progenitor cells) and MC clustering without signs of a substantial proliferation. The same does not appear to hold true for advanced MC neoplasms, i.e. aggressive SM (ASM) or mast cell leukemia (MCL), in which *c-kit* D816V can also be detected, but where MC progenitors, in addition to clustering, may show increased proliferative capacity [27–30,32,33]. In these patients, additional (genetic) defects, that remain to be identified, are likely to contribute to (and possibly cooperate with *c-kit* D816V in) the uncontrolled growth of MCs and their progenitors, and the resulting (adverse) clinical course.

It has also been suggested that, apart from D816V, other *c-kit* mutations may play a role in the development of MC disorders [37–39]. Notably, in patients with SM, several *c-kit* mutations have been identified (Table I). In addition, various chromosomal defects, other gene defects, and genetic polymorphisms have been discussed as contributing to the pathogenesis of SM [40–44]. Many of these defects are detected in patients who have an additional myeloid neoplasm apart from SM, i.e. an associated hematopoietic clonal non-MC lineage disease (AHNMD). Most of these defects have recently been linked to distinct myeloid neoplasms and have been defined as disease criteria by the WHO. Other defects, such as the FIPL1/PDGFR $\alpha$  fusion gene, have recently been associated with specific myeloid neoplasms but are not (yet) mentioned in the WHO classification. Nevertheless, these gene defects may also be reliable discriminative markers sufficient to define a certain subtype of AHNMD in patients with SM. Thus, the presence of eosinophilia and FIPL1/PDGFR $\alpha$  in a patient with SM aids in the diagnosis of SM with hypereosinophilic syndrome (SM-HES), a special subvariant of SM-AHNMD. Table I provides a summary of chromosomal and gene-defects that have been identified in patients with SM.

A second important pathogenetic aspect in SM is the abnormal expression of cell surface adhesion antigens on neoplastic MCs [45–47]. Several antigens specifically detectable on neoplastic MCs in SM, such as CD2 (LFA-2), represent cell-cell adhesion molecules. Since MCs also express CD58



diagnosis is usually established by a bone marrow examination [52,53]. Apart from the bone marrow, other organs such as the liver or the gastrointestinal tract, may also be affected in SM [54–58]. In contrast to SM, CM shows spontaneous regression in a significant number of cases [59].

Systemic mastocytosis is a persistent disease in which the *c-kit* mutation D816V is often detected [20–26]. In some SM-patients, this mutation is not only found in MCs, but also in non-MC-lineage hematopoietic cells [25,26,60–64]. Based on such data, SM is now accepted to be a myeloproliferative disorder [32–34]. This concept is consistent with the observation that MCs derive from myelopoietic progenitors [7–11] and with the relatively high incidence of associated hematologic (clonal) non MC-lineage diseases (AHNMD) including secondary acute myeloid leukemias (AMLs) that occur in these patients [65–68] (Fig. 1).

During the last few years, substantial progress has been made in the morphological, phenotypic, and genetic characterization of neoplastic MCs [32–35]. Based on these advances, an updated consensus classification for mastocytosis has been worked out [69,70]. This WHO classification is based on specific criteria that help in the differentiation between SM and CM, between SM and myelomastocytic disorders, and between SM and a reactive increase in MCs [69,70]. Respective criteria have been termed SM-criteria and are divided into major SM-criteria and minor SM-criteria (Table II). If at least 1 major and 1 minor criterion or at least 3 minor criteria are fulfilled, the final diagnosis is SM (Table II).

Table II. Criteria defining systemic mastocytosis: SM criteria

Major:*	Multifocal dense infiltrates of MCs in bone marrow or other extracutaneous organ(s) (> 15 MCs in aggregate) found in bone marrow sections (tryptase-stained)
Minor:*	MCs in bone marrow or other extracutaneous organ(s) show an abnormal morphology, i.e. type I MCs (> 25%) in bone marrow smears or in histologies <i>c-kit</i> mutation at codon 816** in extracutaneous organ(s) (in most cases, bone marrow cells are examined by RFLP) MCs in bone marrow express CD2 and/or CD25 (determined by flow cytometry***) Serum total tryptase > 20 ng/ml (does not count in patients who have AHNMD-type disease)

\* If at least one major and one minor or at least three minor criteria are fulfilled, the diagnosis SM can be established (69,70).

\*\* Activating mutations at codon 816, in most cases *c-kit* D816V.

\*\*\* The test result can be confirmed by immunohistochemistry. SM, systemic mastocytosis, MCs, mast cells.

### Histology and immunohistochemistry (major criterion)

The most important step in the diagnostic work up of adult patients is a thorough examination of the bone marrow biopsy (and aspirate) [27–30,52,53,71]. The major SM-criterion is the presence of compact dense multifocal MC infiltrates within a bone marrow biopsy section. The most suitable marker for MC detection in such biopsies is tryptase [71–74]. Thus, antibodies against tryptase detect even small-sized compact or diffuse MC infiltrates [71–74]. Compact MC infiltrates are diagnostic and are sometimes also detected in extramedullary visceral organs [53–58].

Apart from compact sharply demarcated MC infiltrates, other types of MC infiltrates have been described with correlation between MC patterns and the subtype of SM [52,53]. In more advanced MC disorders (ASM, MCL), MC infiltrates often are diffuse or mixed, the latter also being termed compact infiltrates with diffuse component [52,53]. In patients with ASM or MCL, the remaining bone marrow architecture is often altered by the MC infiltrate, whereas this is not the case in typical ISM. Here, MC infiltration does not lead to an alteration in the architecture of the remaining (surrounding) normal bone marrow even if some MCs are diffusely spread in these areas [52,53].

### Minor diagnostic criteria for SM

Minor SM criteria relate to the morphology of MCs (spindle shaped, atypical MCs type I), their phenotype (CD2, CD25), elevated serum tryptase, and demonstration of codon 816 mutations of *c-kit* [69,70]. The application of such criteria is often crucial in the diagnostic work up, since MCs may also increase and even form focal infiltrates in reactive MC hyperplasia or in myelomastocytic disorders. For example, advanced myeloid neoplasms may exhibit an increase in diffusely spread MCs in the bone marrow without cytological or biochemical evidence of SM [75–78]. If the percentage of MCs in these patients exceeds 10% of all nucleated cells in the bone marrow or the differential blood count, the final diagnosis is myelomastocytic leukemia [76,78]. Major and minor SM criteria are listed in Table II. Table III shows differential diagnoses to be considered in suspected SM.

### Morphology of Mast Cells in Bone Marrow Smears

The bone marrow smear in suspected SM may show an increase in the number of MCs, abnormal morphology of MCs, or additional cytomorphological abnormalities such as myelodysplasia, eosinophilia, or



Table III. Systemic mastocytosis—differential diagnosis

a.	Systemic disorders mimicking mast cell mediator-effects Vascular diseases (with hypotension and shock) Endocrinologic disorders (diabetes, adrenal tumors, VIPoma, ...) Neurologic and psychiatric disorders (encephalopathy, neuritis, ...) Gastrointestinal disorders (Crohn's disease, ulcerative colitis, ...) Infectious diseases (parasitic infections, hepatitis, others)
b.	Benign disorders associated with mast cell activation Allergies, atopic disorders Benign cutaneous flushing Idiopathic anaphylaxis Chronic urticaria Drug effects on mast cells
c.	Local mast cell hyperplasia Immunocytoma with reactive focal increase in mast cells Cutaneous tumors (melanomas, basal cell carcinoma) Chronic inflammation (autoimmune disorders, intestinal ulcer, ...) Treatment with recombinant stem cell factor (SCF) Thromboembolic disorders
d.	Myelomastocytic overlap syndromes Myelomastocytic leukemia (myeloid neoplasm with increase in MCs but criteria to diagnose SM not fulfilled) Tryptase-positive acute myeloid leukemia (AML) KIT + AML with blast cells expressing CD2 (FAB AML-M4eo, some M3) AML with aberrant expression of <i>c-kit</i> point mutations at codon 816 Chronic myeloid leukemia with accumulation of tryptase + cells Idiopathic myelofibrosis with focal accumulation of mast cells Acute or chronic basophilic leukemia

SM criteria are sufficient to discriminate SM from these differential diagnoses.

an increase in blasts, which raises the suspicion of an associated hematopoietic non-MC lineage disease [69,70,79]. In normal bone marrow, the percentage of MCs is very low (< 0.1%). In patients with SM, the percentage is usually higher [79]. A mast cell percentage of > 10% in bone marrow smears is associated with a poor prognosis and often is indicative of aggressive disease [79]. If the percentage of MCs exceeds 20%, the diagnosis of MC leukemia should be considered, provided that SM criteria are met [79]. Based on consensus criteria, four distinct stages of MC maturation have been defined: the non-granulated (tryptase+) blast, the metachromatically granulated blast (metachromatic blast), the promastocyte (atypical MC type II = MC with bi- or multilobed nuclei), and the mature MC (typical mononuclear MC) (Table IV) [69,70,79]. Immature MCs are frequently recorded in bone marrow smears in patients with aggressive SM (ASM) or mast cell leukemia (MCL) [79]. In indolent SM (ISM), bone marrow MCs are more mature, albeit they do show characteristic

Table IV. Subsets of mast cells defined by morphological criteria

Cell type	Morphological properties
Metachromatic blast*	Blast-like, few metachromatic granules at this stage of maturation, the lineage (mast cell vs. basophil) can not be defined by morphologic criteria alone
Promastocyte* = atypical mast cell type II*	Mostly immature mast cells with bi- or multilobed nuclei, often hypogranulated
Atypical mast cell type I	Mast cells in which 2 of the 3 following morpho-logical aspects are found: a. cytoplasmic extensions (spindle shape) b. hypogranulated cytoplasm c. oval decentralized nucleus
Mature mast cell* = typical tissue mast cell*	Round cell with round central nucleus and well granulated cytoplasm

\* These cell types can also be identified in SCF-dependent progenitor cell cultures.

morphological abnormalities including cytoplasmic extensions, oval nuclei, and a hypogranulated cytoplasm [79]. Such MCs are termed “atypical MCs type I” and are detected in the majority of all patients with ISM [79].

#### *Abnormal Immunophenotype of Mast Cells in Mastocytosis*

Mast cells exhibit a characteristic cell surface antigen phenotype in normal tissues as well as in mastocytosis [32,45–50]. In patients with SM, a number of CD antigens are usually over-expressed on bone marrow MCs compared to normal MCs [45–47]. Most significantly, MCs in patients with SM usually co-express CD2 and CD25, two surface antigens that are not found on normal MCs [45–47]. Therefore, abnormal expression of at least one of these two antigens on MCs is employed as a minor criterion of SM [69,70]. Expression of CD2 and CD25 in bone marrow MCs can be investigated by flow cytometry [45–47] or by immunohistochemistry [80,81]. In both instances, CD25 is the more sensitive parameter. Likewise, in multicolor flow cytometry staining techniques, it is appropriate to use the more sensitive PE-label for CD2 and the somewhat less sensitive FITC-label for CD25. Immunohistochemical staining data may be used to confirm the test result.

#### *Serum Tryptase Measurement*

Tryptase is a well-established and important disease-related marker which should be determined in patients with suspected mastocytosis [4–6]. In healthy individuals, the total serum tryptase levels range between < 1 and 15 ng/ml [4–6]. In patients with CM without

systemic involvement, serum tryptase levels are normal to slightly elevated [4–6]. The same is true for most cases with “isolated” bone marrow mastocytosis without multiorgan involvement [6]. Higher tryptase values increase the likelihood of multiorgan involvement. Thus, in most patients with SM, total serum tryptase levels exceed 20 ng/ml [4–6]. Moreover, tryptase levels in SM are believed to correlate with the burden of neoplastic MCs [5,6]. Notably, however, elevated total tryptase levels have not only been detected in SM, but also in other myeloid neoplasms, especially acute and chronic myeloid leukemias and myelodysplastic syndromes (MDS) without mastocytosis [82–85]. Moreover, total serum tryptase levels may transiently increase during a severe allergic reaction [85,86]. Thus, MC tryptase alone cannot be regarded as a disease-specific and diagnostic marker of SM. Based on these limitations, a persistently elevated serum total tryptase level of > 20 ng/ml is employed as a minor criterion of SM, provided that an AHNMD has been excluded. To restate: in the presence of an AHNMD, the serum tryptase does not count as a criterion of SM [69]. All in all, an important first step in the evaluation of patients with suspected mastocytosis is the determination of the serum tryptase level (as a screen test) with recognition of potential limitations of the test [4–6,87]. In adult patients with a persistently elevated tryptase, the likelihood of SM is significant, and a bone marrow examination warranted.

#### *Recommended Molecular and Cytogenetic Tests*

The examination of the bone marrow in suspected SM should include an analysis of *c-kit* for codon-816 mutations. The most sensitive (and therefore recommended) routine test may be restriction fragment length polymorphism analysis (RFLP) [35]. In patients with suspected SM, the mutation should always be sought using bone marrow cells. If the test is negative in a bone marrow sample, sequence analysis to screen for other *c-kit* mutations, may be required. However, any sequence analysis may yield false-negative results because of the level of sensitivity [35]. By contrast, a false-negative RFLP result is unusual unless MC infiltrates in the bone marrow are very small (as in bone marrow mastocytosis) or when MCs are outnumbered by leukemic (D816V-negative) cells. In such patients, the mutation may only be detected when enriched (sorted or microdissected) bone marrow MCs are analyzed.

In patients with (suspected) AHNMD, bone marrow cells should not only be examined for the presence of *c-kit* mutations, but should also be subjected to appropriate molecular analyses seeking specific fusion genes or specific chromosomal defects related to

hematopoietic neoplasm (Fig. 2) [34]. Likewise, in patients with co-existing eosinophilia, bone marrow and/or blood cells should be examined for the presence of the FIPL1/PDGFRA fusion gene [33]. In SM-AML, the t(8;21) is often detected (Table I). Apart from molecular markers and chromosomes, it may sometimes be appropriate to measure the numbers of colony-forming progenitor cells in patients with suspected SM-AHNMD [34,88].

#### **Categories and subvariants of mastocytosis and current therapy options**

The delineation of subcategories of CM is based on macroscopic inspection and biopsy of lesional skin [51,89–91]. Based on these aspects, three major variants have been defined: maculopapular CM (urticaria pigmentosa), diffuse CM, and solitary mastocytoma of skin [51,69,70,89–91].

In patients with SM, a number of staging investigations are required to define the exact subtype of disease. Aggressive SM is characterized by progressive infiltration of diverse organs by MCs, with resulting impairment of organ-function—respective findings are called C-Findings [69,70,92]. Mast cell infiltration with associated organomegaly should not be regarded as organopathy (C-Finding) unless accompanied by signs of impaired organ function [69,92]. Thus, organomegaly is also found in patients with an indolent or an uncertain (smouldering) course [60–64], and then is regarded as a B-Finding [69]. B- and C-Findings are listed in Table V. In patients with suspected AHNMD [65–68], WHO criteria (for SM and for AHNMD) are employed to define the subvariant (Table I) [69]. Sometimes it may be difficult to discriminate between SM-AML, MCL, and a myelomastocytic leukemia [75,76,78]. MCL is a rare subentity of SM where SM criteria are fulfilled and there is a diffuse leukemic infiltration of hematopoietic tissues by immature neoplastic MCs [27–30,69,70,92–94]. In contrast to ISM, patients with MCL lack UP-like skin lesions [27–30,69,70,92–94]. Table VI provides a summary of variants of mastocytosis recognized by the WHO, and in Fig. 2 a practical guide for the delineation of MC proliferative disorders is presented.

An important aspect of mastocytosis is the frequent occurrence of mediator-related symptoms. These symptoms may be mild, but may also be severe or even life-threatening [95–97]. It is important to be aware that such severe symptoms can occur in any subvariant of mastocytosis (CM or SM), and that the symptoms are not by themselves diagnostic of an aggressive disease (not regarded as C-Findings).

The following sections provide a brief overview of distinct variants of mastocytosis recognized by the

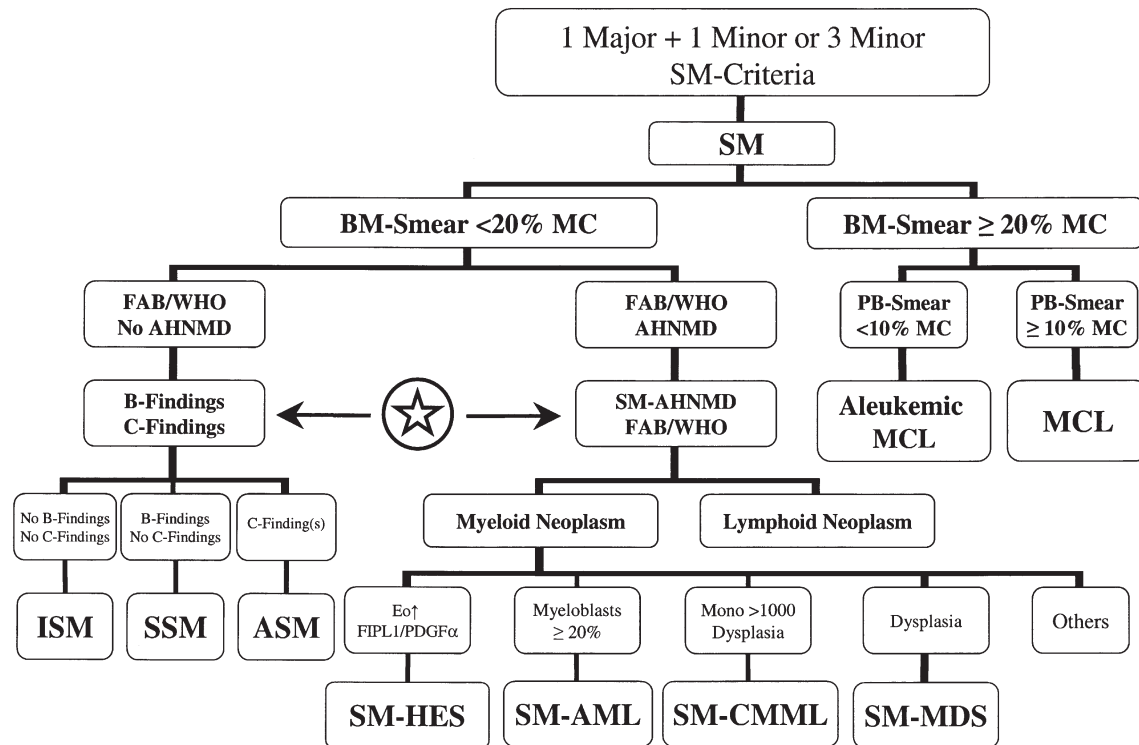


FIGURE 2 Algorithm for a step-wise approach to diagnose variants of SM. When SM criteria are fulfilled (at least 1 major + 1 minor or 3 minor), the diagnosis systemic mastocytosis (SM) can be established. In patients with organopathy and absence of skin lesions, the bone marrow smear ( $> 20\%$  mast cells) and peripheral blood smear (circulating mast cells) can lead to the diagnosis of mast cell leukemia (MCL), which is an extremely rare condition. In most patients no organopathy, no B-Findings, no C-Findings, no circulating mast cells, and no AHNMD are found. These patients usually have skin lesions, and are diagnosed as indolent systemic mastocytosis (ISM). An AHNMD defines SM-AHNMD. In these patients, the nature of the SM component as well as the subtype of the AHNMD (according to WHO criteria) should be defined. C-Finding are indicative of aggressive systemic mastocytosis (ASM). Here it is of importance to be aware that one C-Finding alone is sufficient for the diagnosis ASM. If no C-Findings or signs of an AHNMD are found, but B-Findings are present, the patient is diagnosed to have smouldering systemic mastocytosis (SSM).

WHO, with special reference to diagnostic criteria and available treatment options.

#### Cutaneous Mastocytosis (CM)

CM preferentially develops in early childhood, whereas development of CM in adulthood is unusual [51,90]. By definition, MC infiltration in patients with CM is confined to the skin [51,69]. In most cases, a characteristic maculopapular rash is observed [51,89,90]. In a smaller group, skin lesions are diffuse or nodular [51]. A positive Darier's sign is a typical finding. Blistering of the skin may also be observed, particularly in patients with diffuse cutaneous involvement. The diagnosis CM is based on typical skin lesions, demonstration of characteristic infiltrates of MCs on biopsy, and lack of SM criteria [51,69]. The serum tryptase levels in CM are usually  $< 20$  ng/ml [4–6,69].

Three major forms of CM are recognized by the WHO: (i) urticaria pigmentosa (UP) also termed maculopapular cutaneous mastocytosis (MPCM);

(ii) diffuse cutaneous mastocytosis (DCM); and (iii) mastocytoma of the skin [51,69,70]. UP is the most frequent form of CM and is characterized by a typical maculopapular rash [89,90]. Apart from classical UP, a number of rare subvariants have been described including a plaque form, a nodular form, and a telangiectatic subvariant (telangiectasia macularis eruptiva perstans [TMEP]) [51,90,98,99]. The prognosis of UP is good. In many children, skin lesions regress during puberty. Progression of paediatric CM to SM is unusual. In adults, however, the disease persists and often progresses to SM. In some patients with CM, skin lesions are extensive and accompanied by mediator-related symptoms requiring therapy. A reasonable approach in adults is to offer mediator-targeting drugs and to consider PUVA [51,90,100]. In severe cases, glucocorticoids may be recommended. Diffuse cutaneous mastocytosis (DCM) is less frequently diagnosed than UP [51,90,91,101]. Most patients are children. In contrast to UP, a more diffuse erythrodermic rash is seen [102]. The prognosis in DCM is reasonable,

Table V. B- and C- Findings

---

B-Findings = Indication of high burden of MCs, and expansion of the genetic defect into various myeloid lineages

- (1) Infiltration grade (MCs) in bone marrow > 30% in histology *and*: serum total tryptase levels > 200 ng/ml
- (2) Hypercellular marrow with loss of fat cells, discrete signs of dysmyelopoiesis without substantial cytopenias or WHO criteria for an MDS or MPD
- (3) Organomegaly: palpable hepatomegaly, splenomegaly, or lymphadenopathy (on CT or US: > 2 cm) without impaired organ function

C-Findings = Indication of impaired organ function due to MC infiltration (has to be confirmed by biopsy in most cases)

- (1) Cytopenia(s): ANC < 1,000/ $\mu$ l or Hb < 10 g/dl or Plt < 100,000/ $\mu$ l
- (2) Hepatomegaly with ascites and impaired liver function
- (3) Palpable splenomegaly with hypersplenism
- (4) Malabsorption with hypalbuminemia and weight loss
- (5) Skeletal lesions: large-sized osteolyses or/and severe osteoporosis causing pathologic fractures
- (6) Life-threatening organopathy in other organ systems that is definitively caused by an infiltration of the tissue by neoplastic MCs

---

MCs, mast cells.

Table VI. WHO — Classification of mastocytosis\*

Variant – Term	Abbreviation	Subvariants
Cutaneous mastocytosis	CM	<ul style="list-style-type: none"> <li>– Urticaria Pigmentosa (UP) = Maculopapular CM (MPCM)</li> <li>– Diffuse CM (DCM)</li> <li>– Mastocytoma of Skin</li> </ul>
Indolent systemic mastocytosis	ISM	<ul style="list-style-type: none"> <li>– Smouldering SM</li> <li>– Isolated bone marrow mastocytosis</li> </ul>
Systemic mastocytosis with an associated clonal hematologic non mast cell lineage disease	SM-AHNMD	<ul style="list-style-type: none"> <li>– SM-AML</li> <li>– SM-MDS</li> <li>– SM-MPD</li> <li>– SM-HES</li> <li>– SM-CMML</li> <li>– SM-NHL</li> </ul>
Aggressive systemic mastocytosis	ASM	<ul style="list-style-type: none"> <li>– Lymphadenopathic SM with eosinophilia</li> </ul>
Mast cell leukemia	MCL	<ul style="list-style-type: none"> <li>– Aleukemic MCL</li> </ul>
Mast cell sarcoma		
Extracutaneous mastocytoma		

\* For details of the WHO classification of mastocytosis, see refs 69 and 70.

but the disease may persist into adulthood. Solitary mastocytoma of the skin is also unusual [51,90,103]. Most patients are young infants. Histologically, the lesions consist of densely packed MCs without cellular atypia. In most cases the mastocytoma resolves spontaneously. If this does not occur, excision should be considered [103].

*Indolent Systemic Mastocytosis (ISM)*

ISM is the most frequently diagnosed variant of SM. ISM is associated with SM criteria, presence of UP-like skin lesions, and an indolent clinical course without significant organomegaly or organopathy. The prognosis appears to be good [69,70,95]. Mediator-related symptoms are frequently reported, and may represent the predominant medical problem [95,96]. The bone marrow is almost invariably affected, with multifocal dense infiltrates of MCs [52,53]. In typical ISM, the infiltration grade is rather low, and the infiltrates are sharply demarcated

from normal marrow [52,53]. Typically, MCs in bone marrow smears are atypical MCs type I (Table IV) [79]. Apart from the marrow, MC infiltrates may also be detected in other organs including the liver, spleen, and the gastrointestinal tract [53–58]. In most patients, MCs express CD2 and CD25, and contain the *c-kit* mutation D816V [20–23,45,69]. The serum total tryptase concentration is > 20 ng/ml in almost all cases [4–6,85,86]. Patients with ISM are treated with “mediator-targeting” drugs including anti-histamines, but not with cytoreductive agents (Table VII) [29,30,34,95,97,104]. Skin lesions in ISM may also require treatment. In most cases, transient responses are seen after PUVA [105].

Isolated bone marrow mastocytosis is a rare subentity of ISM characterized by the absence of skin lesions and lack of multiorgan involvement [27,28,69]. It is important to differentiate bone marrow mastocytosis from ASM or MCL, where skin lesions are also absent. In contrast to ASM and MCL, the serum tryptase level in isolated bone



Table VII. Cyto-reductive treatment options for patients with systemic mastocytosis (SM)

Disease variant	Treatment options
Typical indolent systemic mastocytosis (ISM)	No cyto-reductive treatment required. (exception: consider IFN- $\alpha$ 2b for severe osteoporosis even if no histology documenting ASM is available, these cases are considered as ‘probably ASM’).
Smouldering systemic mastocytosis (SSM)	Watch and wait in most cases. However, in select cases (rapidly progressive B-findings) IFN- $\alpha$ 2b +/- glucocorticoids can be considered.
SM-AHNMD	Treat AHNMD as if no SM is present and also treat SM as if no AHNMD is found. If splenomegaly and hypersplenism prohibit therapy — consider splenectomy.
<i>Examples:</i>	
SM-HES + FIPL1/PDGFR	STI571 (Imatinib)
SM-AML	Chemotherapy or palliative drugs
SM-MDS	Palliative in most cases
Aggressive systemic mastocytosis (ASM) with slow progression	IFN- $\alpha$ 2b +/- glucocorticoids If splenomegaly and hypersplenism prohibit therapy — consider splenectomy. In patients without detectable <i>c-kit</i> mutation D816V, STI571 (Imatinib) can be considered.
ASM — rapid progression** and patients who do not respond to IFN- $\alpha$ 2b	Polychemotherapy (+/- IFN- $\alpha$ 2b); consider bone marrow transplantation in select cases. If splenomegaly and hypersplenism prohibit therapy — consider splenectomy. For select cases, cladribine (2CdA) or other cyto-reductive drugs can be considered. Consider hydroxyurea as palliative drug.
Mast cell leukemia (MCL)	Polychemotherapy (+/- 2CdA; +/- IFN- $\alpha$ 2b). Consider bone marrow transplantation. If splenomegaly and hypersplenism prohibit therapy — consider splenectomy. Consider hydroxyurea as palliative drug.

IFN, interferon; SM-AHNMD, systemic mastocytosis with an associated hematologic clonal non mast cell lineage disease.

marrow mastocytosis is usually < 30 ng/ml [6]. In most patients, no therapy is required.

Smouldering systemic mastocytosis (SSM) is another subentity of ISM [60–64,69]. In contrast to typical ISM, B-Findings ( $\geq 2$ ) are noted (Table V). These B-Findings reflect a high burden of MCs and extension of the clonal disease to several myeloid lineages [64,69]. Clinically, the smouldering state has an uncertain prognosis and a variable clinical course. In some instances, the clinical course is long-lasting and silent. In other patients, an AHNMD or ASM develops with time. Typically, patients with SSM have a bone marrow infiltration grade > 30% (dense infiltrates), serum tryptase levels > 200 ng/ml, discrete signs of myelodysplasia or myeloproliferation in bone marrow, and palpable organomegaly (hepato-, spleno-, or lymphadenopathy) [64,69]. These B-Findings are due to organ infiltration by MCs or other myeloid cells. However, impairment of organ function (C-Findings) is not observed. The bone marrow in SSM typically contains mixed infiltrates (dense focal with an additional diffuse component) of MCs [52,53]. These MCs may be quite immature. The *c-kit* mutation D816V is detectable in a majority of the cases [60–64]. In most instances, the mutation is also detected in other myeloid lineages and thus in unfractionated blood leukocytes [60–64]. The treatment of SSM is identical to that in patients with ISM. However, SSM-patients should be observed closely for signs of progression or occurrence of an AHNMD.

#### *SM with Associated clonal Hematologic Non-Mast cell lineage Disease, AHNMD*

In a group of patients with SM, an AHNMD may be diagnosed [65–70]. In these patients, criteria to diagnose an AHNMD as well as SM-criteria must be met [69]. Patients with SM-AHNMD are categorized according to the AHNMD and the type of SM. In most cases, a myeloid neoplasm such as a myeloproliferative disorder (such as idiopathic myelofibrosis, IMF or the hypereosinophilic syndrome, HES), or a myeloid leukemia develops [65–70]. Myelodysplastic syndromes may also be diagnosed in patients with SM-AHNMD. In contrast, the occurrence of a lymphoid neoplasm is a rare event. In all patients, separate treatment plans for SM and the AHNMD should be established. In these patients, SM should be treated as if no AHNMD is present, and AHNMD as if no SM had been diagnosed (Table VII). Likewise, in patients with SM and associated hypereosinophilic syndrome (SM-HES) with FIPL1/PDGFR fusion gene, STI571 has been shown to produce reasonable responses which are similar to that seen in HES patients without SM [106,107]. In patients with SM-AML, polychemotherapy (that would be given in patients with AML without SM) may induce complete hematologic remission of AML [67,108]. An important aspect in SM-AHNMD is that the SM component may present as ISM or ASM, which in turn, has implications for determining the treatment plan. In some patients, cyto-reductive

drugs may show beneficial effects for both ASM and the AHNMD.

#### *Aggressive Systemic Mastocytosis (ASM)*

This rare aggressive subvariant of SM (ASM) is characterized by organopathy caused by pathologic infiltration of various organs by neoplastic MCs and the resulting impairment of organ function [27–30,69,70,92]. In contrast to MCL, the bone marrow smear shows less than 20% MCs [69,92]. In contrast to ISM or SSM, C-Findings which indicate compromising organopathy due to MC infiltration, are detectable in patients with ASM (Table V). In particular, patients show one of the following: (1) significant cytopenia(s); (2) impairment of liver function due to MC infiltration, often with ascites; (3) osteolyses with pathologic fractures; (4) malabsorption with weight loss; (5) splenomegaly with hypersplenism; or (6) life-threatening impairment of organ function in other organ systems [69,70,92]. The most commonly affected organs are the liver, bone marrow, and the skeletal system. UP-like skin lesions are usually absent [69,70,92]. The histology of the bone marrow in ASM shows a variable degree of infiltration. The MC infiltrates are often mixed (dense focal + diffuse) [52,53]. The bone marrow cytology may disclose major MC atypia with occurrence of promastocytes and metachromatic blasts [69,79]. Serum tryptase levels are elevated, and in some cases, are quite high. Patients with ASM are candidates for treatment with cytoreductive drugs (Table VII). Patients with a relatively slow progression are usually treated with glucocorticoids (prednisone) and interferon alpha (IFN $\alpha$ ) [92,109–113]. Prednisone (50–75 mg p.o. daily) may be initiated a few days before IFN- $\alpha$  is administered (3 million I.U. s.c. three times a week) [34,92,97,113]. During the first days of treatment, the patient should be carefully monitored. After a few weeks, the interferon dosage can usually be escalated to 3–5 million units per day, and prednisone tapered to a low maintenance dose (12.5 mg/day or less) or even discontinued. In patients with severe osteoporosis, IFN- $\alpha$  can be administered without glucocorticoids [92,97]. In these patients, the use of bisphosphonates is also recommended. Patients with ASM with rapid disease progression, signs of progression to MCL, or failure to respond to interferon-alpha, are candidates for 2CdA or other chemotherapy (Table VII) [34,92,94,114–116]. The use of targeted drugs in ASM has also been considered. Imatinib (STI571) has been described to be effective in some of these patients. In fact, several SM patients with wild type *c-kit* or *c-kit* mutations other than D816V appear to respond to Imatinib [38,107]. However, most patients with ASM have the D816V *c-kit* mutation

which appears to confer relative resistance against STI571 [117–119]. Therefore, it can be expected that Imatinib will not show significant beneficial effects in the majority of patients with ASM or MCL, at least when used as a single agent. Currently, a number of drugs are being examined for their potential to overcome D816V-based resistance of *c-kit* against STI571.

#### *Mast Cell Leukemia (MCL) and Mast Cell Sarcoma (MCS)*

Mast cell leukemia (MCL) is a rare aggressive MC neoplasm defined by increased numbers of MCs in bone marrow smears ( $\geq 20\%$ ) and by circulating MCs [27–30,92–94]. Patients typically suffer from rapidly progressive organopathy involving the liver, bone marrow and other organs. The bone marrow typically shows a diffuse plus dense infiltration with MCs [69,70,79,92–94]. MCs are often immature, show a blast-like morphology, or/and have polylobed nuclei (promastocytes) [69,79]. In typical MCL, MCs account for more than 10% of blood leukocytes [69,79,94]. In a smaller group of patients, pancytopenia occurs and MCs account for less than 10% (aleukemic variant of MCL) [69,79,94]. In many patients, MCs express CD2 and CD25. The *c-kit* mutation D816V may be detected. The prognosis in MCL is poor. Most patients survive less than 1 year and respond poorly to cytoreductive drugs or chemotherapy [69,79,92,94]. A curative therapy for MCL is currently not available. Chemotherapy regimens employing substances otherwise used for treatment of AML (with or without 2CdA) may be considered (Table VII) [94]. Another experimental option is bone marrow transplantation, although no experience exists concerning responses and mortality.

Mast cell sarcoma (MCS) is an extremely rare form of mastocytosis. To date, the authors are aware of only 3 well-documented cases [120–122]. The disease is defined by a local destructive sarcoma-like growth of a tumor consisting of highly atypical MCs [120–122]. At initial diagnosis, no systemic involvement is found. However, secondary generalization with involvement of visceral organs and hematopoietic tissues has been described [120–122]. The terminal phase may be indistinguishable from ASM or MCL [120,122]. The prognosis in patients with MC sarcoma is grave. Mast cell sarcoma should not be confused with extracutaneous mastocytoma, a rare benign MC tumor without destructive growth.

#### **Concluding remarks**

During the last few years, major advances in mastocytosis research have been made including

the identification of molecular markers and potential drug targets in neoplastic mast cells and the formulation of diagnostic criteria. An important aim for the near future will be to standardize diagnostic techniques, response criteria, and outcomes in order to establish a useful basis for the design of clinical trials. There is also the expectation that some of the newly described molecular and genetic findings in patients with mastocytosis will form the basis of novel therapeutic approaches.

## References

- [1] Galli, S.J. (1990) "Biology of disease: New insights into "the riddle of the mast cells": microenvironmental regulation of mast cell development and phenotypic heterogeneity", *Lab. Invest.*, **62**, 5–33.
- [2] Valent, P., Sillaber, C. and Bettelheim, P. (1991) "The growth and differentiation of mast cells", *Prog. Growth Factor Res.*, **3**, 27–41.
- [3] Schwartz, L.B. (1985) The mast cell. In *Allergy, vol 1*, edited by A.P. Kaplan. Pp 53–92. Edinburgh: Churchill Livingstone.
- [4] Schwartz, L.B., Sakai, K., Bradford, T.R., Ren, S., Zweiman, B., Worobec, A.S., *et al.* (1995) "The alpha form of human tryptase is the predominant type present in blood at baseline in normal subjects and is elevated in those with systemic mastocytosis", *J. Clin. Invest.*, **96**, 2702–2710.
- [5] Akin, C. and Metcalfe, D.D. "Surrogate markers of disease in mastocytosis", *Int. Arch. Allergy Immunol.*, **127**, 133–136.
- [6] Sperr, W.R., Jordan, J.H., Fiegl, M., Escribano, L., Dirnhofer, S., *et al.* (2002) "Serum tryptase levels in patients with mastocytosis: correlation with mast cell burden and implication for defining the category of disease", *Int. Arch. Allergy Immunol.*, **128**, 136–141.
- [7] Kitamura, Y., Yokoyama, M., Matsuda, H., Ohno, T. and Mori, K.J. (1981) "Spleen colony forming cell as common precursor for tissue mast cells and granulocytes", *Nature*, **291**, 159–160.
- [8] Kirshenbaum, A.S., Goff, J.P., Kessler, S.W., Mican, J.M., Zsebo, K.M. and Metcalfe, D.D. (1992) "Effects of IL-3 and stem cell factor on the appearance of human basophils and mast cells from CD34+ pluripotent progenitor cells", *J. Immunol.*, **148**, 772–777.
- [9] Kirshenbaum, A.S., Goff, J.P., Semere, T., Foster, B., Scott, L.M. and Metcalfe, D.D. (1999) "Demonstration that human mast cells arise from a progenitor cell population that is CD34+, c-kit+, and expresses aminopeptidase N (CD13)", *Blood*, **94**, 2333–2342.
- [10] Agis, H., Willheim, M., Sperr, W.R., Wilfing, A., Krömer, E., Kabrna, E., *et al.* (1993) "Monocytes do not make mast cells when cultured in the presence of SCF. Characterization of the circulating mast cell progenitor as a c-kit+, CD34+, Ly-, CD14-, CD17-, colony forming cell", *J. Immunol.*, **151**, 4221–4227.
- [11] Rottem, M., Okada, T., Goff, J.P. and Metcalfe, D.D. (1994) "Mast cells cultured from peripheral blood of normal donors and patients with mastocytosis originate from a CD34+/FceRI<sup>-</sup> cell population", *Blood*, **84**, 2489–2496.
- [12] Valent, P. (1994) "The riddle of the mast cell: c-kit Ligand as Missing Link?", *Immunol. Today*, **15**, 111–114.
- [13] Mitsui, H., Furitsu, T., Dvorak, A.M., Irani, A.M., Schwartz, L.B., Inagaki, N., *et al.* (1990) "Development of human mast cells from umbilical cord blood cells by recombinant human and murine c-kit ligand", *Proc. Natl. Acad. Sci. (USA)*, **90**, 735–739.
- [14] Irani, A.M., Nilsson, G., Miettinen, U., Craig, S.S., Ashman, L.K., Ishizaka, T., *et al.* (1992) "Recombinant human stem cell factor stimulates differentiation of human mast cells from dispersed fetal liver cells", *Blood*, **80**, 3009–3016.
- [15] Valent, P., Spanblöchl, E., Sperr, W.R., Sillaber, Ch., Agis, H., Zsebo, K., *et al.* (1992) "Induction of differentiation of human mast cells from bone marrow and peripheral blood mononuclear cells by recombinant human stem cell factor (SCF)/kit ligand (KL) in long term culture", *Blood*, **80**, 2237–2245.
- [16] Galli, S.J., Tsai, M. and Wershil, B.K. (1993) "The c-kit receptor, stem cell factor, and mast cells. what each is teaching us about the others", *Am. J. Pathol.*, **142**, 965–974.
- [17] Kitamura, Y., Go, S. and Hatanaka, S. (1978) "Decrease of mast cells in *W/W<sup>v</sup>* mice and their increase by bone marrow transplantation", *Blood*, **52**, 447–452.
- [18] Kitamura, Y. and Go, S. (1979) "Decreased production of mast cells in *Sl/Sl<sup>d</sup>* mice", *Blood*, **53**, 492–497.
- [19] Furitsu, T., Tsujimura, T., Tono, T., Ikeda, H., Kitayama, H., Koshimizu, U., *et al.* (1993) "Identification of mutations in the coding sequence of the proto-oncogene c-kit in a human mast cell leukemia cell line causing ligand-independent activation of the c-kit product", *J. Clin. Invest.*, **92**, 1736–1744.
- [20] Feger, F., Ribadeau Dumas, A., Leriche, L., Valent, P. and Arock, M. (2002) "Kit and *c-kit* mutations in mastocytosis: a short overview with special reference to novel molecular and diagnostic concepts", *Int. Arch. Allergy Immunol.*, **127**, 110–114.
- [21] Nagata, H., Worobec, A.S., Oh, C.K., Chowdhury, B.A., Tannenbaum, S., Suzuki, Y., *et al.* (1995) "Identification of a point mutation in the catalytic domain of the proto-oncogene *c-kit* in peripheral blood mononuclear cells of patients who have mastocytosis with an associated hematologic disorder", *Proc. Natl. Acad. Sci. (USA)*, **92**, 10560–10564.
- [22] Longley, B.J., Tyrrell, L., Lu, S.Z., Ma, Y.S., Langley, K., Ding, T.G., *et al.* (1996) "Somatic *c-kit* activating mutation in urticaria pigmentosa and aggressive mastocytosis: establishment of clonality in a human mast cell neoplasm", *Nat. Genet.*, **12**, 312–314.
- [23] Longley, B.J., Metcalfe, D.D., Tharp, M., Wang, X., Tyrrell, L., Lu, S.-Z., *et al.* (1999) "Activating and dominant inactivating *c-kit* catalytic domain mutations in distinct forms of human mastocytosis", *Proc. Natl. Acad. Sci. (USA)*, **96**, 1609–1614.
- [24] Büttner, C., Henz, B.M., Welker, P., Sepp, N.T. and Grabbe, J. (1998) "Identification of activating *c-kit* mutations in adult-, but not childhood-onset indolent mastocytosis: a possible explanation for divergent clinical behaviour". *J. Invest. Dermatol.*, **111**, 1227–1231.
- [25] Akin, C., Kirshenbaum, A.S., Semere, T., Worobec, A.S., Scott, L.M. and Metcalfe, D.D. (2000) "Analysis of the surface expression of c-kit and occurrence of the c-kit Asp816Val activating mutation in T cells, B cells, and myelomonocytic cells in patients with mastocytosis", *Exp. Hematol.*, **28**, 140–147.
- [26] Yavuz, A.S., Lipsky, P.E., Yavuz, S., Metcalfe, D.D. and Akin, C. (2002) "Evidence for the involvement of a hematopoietic progenitor cell in systemic mastocytosis from single cell analysis of mutations in the *c-kit* gene", *Blood*, **100**, 661–665.
- [27] Lennert, K. and Parwaresch, M.R. (1979) "Mast cells and mast cell neoplasia: a review", *Histopathology*, **3**, 349–365.



- [28] Parwaresch, M.R., Horny, H.-P. and Lennert, K. (1985) "Tissue mast cells in health and disease", *Path. Res. Pract.*, **179**, 439–461.
- [29] Metcalfe, D.D. (1991) "Classification and diagnosis of mastocytosis: current status", *J. Invest. Dermatol.*, **96**, 2S–4S.
- [30] Valent, P. (1996) "Biology, classification and treatment of human mastocytosis", *Wien. Klin. Wschr.*, **108**, 385–397.
- [31] Sotlar, K., Escribano, L., Landt, O., Mohrle, S., Herrero, S., Torrelo, A., et al. (2003) "One-step detection of *c-kit* point mutations using peptide nucleic acid-mediated polymerase chain reaction clamping and hybridization probes", *Am. J. Pathol.*, **162**, 737–746.
- [32] Valent, P., Escribano, L., Parwaresch, M.R., Schemmel, V., Schwartz, L.B., Sotlar, K., et al. (1999) "Recent advances in mastocytosis research", *Int. Arch. Allergy Immunol.*, **120**, 1–7.
- [33] Tefferi, A. and Pardanani, A. (2004) "Clinical, genetic, and therapeutic insights into systemic mast cell disease", *Curr. Opin. Hematol.*, **11**, 58–64.
- [34] Valent, P., Akin, C., Sperr, W.R., Horny, H.P., Arock, M., Lechner, K., et al. (2003) "Diagnosis and treatment of systemic mastocytosis: state of the art", *Br. J. Haematol.*, **122**, 695–717.
- [35] Fritsche-Polanz, R., Jordan, J.H., Feix, A., Sperr, W.R., Sunder-Plassmann, G., Valent, P., et al. (2001) "Mutation analysis of *c-kit* in patients with myelodysplastic syndromes without mastocytosis and cases of systemic mastocytosis", *Br. J. Haematol.*, **113**, 357–364.
- [36] Ferrao, P.T., Gonda, T.J. and Ashman, L.K. (2003) "Constitutively active mutant D816VKit induces megakaryocyte and mast cell differentiation of early haemopoietic cells from murine foetal liver", *Leuk. Res.*, **27**, 547–555.
- [37] Pignon, J.M., Giraudier, S., Duquesnoy, P., Jouault, H., Imbert, M., Vainchenker, W., et al. (1997) "A new *c-kit* mutation in a case of aggressive mast cell disease", *Br. J. Haematol.*, **96**, 374–376.
- [38] Akin, C., Fumo, G., Yavuz, A.S., Lipsky, P.E., Neckers, L. and Metcalfe, D.D. (2003) "A novel form of mastocytosis associated with a transmembrane *c-Kit* mutation and response to imatinib", *Blood*, **103**, 3222–3225.
- [39] Pullarkat, V.A., Pullarkat, S.T., Calverley, D.C. and Brynes, R.K. (2000) "Mast cell disease associated with acute myeloid leukemia: detection of a new *c-kit* mutation Asp816His", *Am. J. Hematol.*, **65**, 307–309.
- [40] Pardanani, A., Ketterling, R.P., Brockman, S.R., Flynn, H.C., Paternoster, S.F., Shearer, B.M., et al. (2003) "CHIC2 deletion, a surrogate for FIP1L1-PDGFRA fusion, occurs in systemic mastocytosis associated with eosinophilia and predicts response to imatinib mesylate therapy", *Blood*, **102**, 3093–3096.
- [41] Swolin, B., Rodjer, S. and Roupe, G. (1987) "Cytogenetic studies and in vitro colony growth in patients with mastocytosis", *Blood*, **70**, 1928–1932.
- [42] Swolin, B., Rodjer, S. and Roupe, G. (2000) "Cytogenetic studies in patients with mastocytosis", *Cancer Genet. Cytogenet.*, **120**, 131–135.
- [43] Lishner, M., Confino-Cohen, R., Mekori, Y.A., Feigin, M., Manor, Y., Goldberg, A., et al. (1996) "Trisomies 9 and 8 detected by fluorescence in situ hybridization in patients with systemic mastocytosis", *J. Allergy Clin. Immunol.*, **98**, 199–204.
- [44] Daley, T., Metcalfe, D.D. and Akin, C. (2001) "Association of the Q576R polymorphism in the interleukin-4 receptor alpha chain with indolent mastocytosis limited to the skin", *Blood*, **98**, 880–882.
- [45] Escribano, L., Orfao, A., Diaz-Agustin, B., Villarrubia, J., Cervero, C., Lopez, A., et al. (1998) "Indolent systemic mast cell disease in adults: immunophenotypic characterization of bone marrow mast cells and its diagnostic implication", *Blood*, **91**, 2731–2736.
- [46] Scherthaner, G.H., Jordan, J.H., Ghannadan, M., Agis, H., Bevec, D., Nuñez, R., et al. (2001) "Expression, epitope analysis, and functional role of the LFA-2 antigen detectable on neoplastic mast cells", *Blood*, **98**, 3784–3792.
- [47] Escribano, L., Diaz-Agustin, B., Bellas, C., Navalón, R., Nuñez, R., Sperr, W.R., et al. (2001) "Utility of flow cytometric analysis of mast cells in the diagnosis and classification of adult mastocytosis", *Leuk. Res.*, **25**, 563–570.
- [48] Valent, P. and Bettelheim, P. (1992) "Cell surface structures on human basophils and mast cells: biochemical and functional characterization", *Adv. Immunol.*, **52**, 333–423.
- [49] Valent, P., Scherthaner, G.H., Sperr, W.R., Fritsch, G., Agis, H., Willheim, M., et al. (2001) "Variable expression of activation-linked surface antigens on human mast cells in health and disease", *Immunol. Rev.*, **179**, 74–81.
- [50] Ghannadan, M., Hauswirth, A., Scherthaner, G.-H., Müller, M.R., Klepetko, W., Schatzl, G., et al. (2002) "Detection of novel CD antigens on the surface of human mast cells and basophils", *Int. Arch. Allergy Immunol.*, **127**, 299–307.
- [51] Wolff, K., Komar, M. and Petzelbauer, P. (2001) "Clinical and histopathological aspects of cutaneous mastocytosis", *Leuk. Res.*, **25**, 519–528.
- [52] Horny, H.-P., Parwaresch, M.R. and Lennert, K. (1985) "Bone marrow findings in systemic mastocytosis", *Human Pathology*, **16**, 808–814.
- [53] Horny, H.-P. and Valent, P. (2001) "Diagnosis of mastocytosis: General histopathological aspects, morphological criteria, and immunohistochemical findings", *Leuk. Res.*, **25**, 543–551.
- [54] Horny, H.-P., Kaiserling, E., Parwaresch, M.R. and Lennert, K. (1992) "Lymph node findings in generalized mastocytosis", *Histopathology*, **21**, 439–446.
- [55] Horny, H.-P., Ruck, M. and Kaiserling, E. (1992) "Spleen findings in generalized mastocytosis. A clinicopathologic study", *Cancer*, **70**, 459–468.
- [56] Horny, H.-P., Kaiserling, E., Campbell, M., Parwaresch, M.R. and Lennert, K. (1989) "Liver findings in generalized mastocytosis. A clinicopathologic study", *Cancer*, **63**, 532–538.
- [57] Metcalfe, D.D. (1991) "The liver, spleen, and lymph nodes in mastocytosis", *J. Invest. Dermatol.*, **96**, 45S–46S.
- [58] Travis, W.D. and Li, C.Y. (1988) "Pathology of the lymph node and spleen in systemic mast cell disease", *Mod. Pathol.*, **1**, 4–14.
- [59] Caplan, R.M. (1963) "The natural course of urticaria pigmentosa", *Arch. Dermatol.*, **87**, 146–157.
- [60] Jordan, J.H., Fritsche-Polanz, R., Sperr, W.R., Mitterbauer, G., Födinger, M., Scherthaner, G.H., et al. (2001) "A case of smouldering mastocytosis with high mast cell burden, monoclonal myeloid cells, and *C-KIT* mutation Asp-816-Val", *Leuk. Res.*, **25**, 627–634.
- [61] Akin, C., Scott, L.M. and Metcalfe, D.D. (2001) "Slowly progressing mastocytosis with high mast cell burden and no evidence of a non-mast cell hematologic disorder: an example of a smoldering case?", *Leuk. Res.*, **25**, 635–638.
- [62] Hauswirth, A., Sperr, W.R., Ghannadan, M., Scherthaner, G.-H., Jordan, J.H., Fritsche-Polanz, R. et al. (2002) "A case of smouldering mastocytosis with peripheral blood eosinophilia and lymphadenopathy", *Leuk. Res.*, **26**, 601–606.



- [63] Sotlar, K., Marafioti, T., Griesser, H., Theil, J., Aepinus, C., *et al.* (2000) "Detection of *c-kit* mutation Asp-816-Val in microdissected bone marrow infiltrates in a case of systemic mastocytosis associated with chronic myelomonocytic leukemia", *Mol. Pathol.*, **53**, 188–193.
- [64] Valent, P., Akin, C., Sperr, W.R., Horny, H.-P. and Metcalfe, D.D. (2002) "Smouldering mastocytosis: a new type of systemic mastocytosis with slow progression", *Int. Arch. Allergy Immunol.*, **127**, 137–139.
- [65] Horny, H.-P., Ruck, M., Wehrmann, M. and Kaiserling, E. (1990) "Blood findings in generalized mastocytosis: evidence of frequent simultaneous occurrence of myeloproliferative disorders", *Br. J. Haematol.*, **76**, 186–193.
- [66] Lawrence, J.B., Friedman, B.S., Travis, W.D., Chinchilli, V.M., Metcalfe, D.D. and Gralnick, H.R. (1991) "Hematologic manifestation of systemic mast cell disease: a prospective study of laboratory and morphologic features and their relation to prognosis", *Am. J. Med.*, **91**, 612–624.
- [67] Sperr, W.R., Horny, H.-P., Lechner, K. and Valent, P. (2000) "Clinical and biologic diversity of leukemias occurring in patients with mastocytosis", *Leukemia & Lymphoma*, **37**, 473–486.
- [68] Travis, W.D., Li, C.Y., Yam, L.T., Bergstralh, E.J. and Sweet, R.G. (1988) "Significance of systemic mast cell disease with associated hematologic disorders", *Cancer*, **62**, 965–972.
- [69] Valent, P., Horny, H.-P., Escribano, L., Longley, J.B., Li, C.Y., Schwartz, L.B., *et al.* (2001) "Diagnostic criteria and classification of mastocytosis: a consensus proposal. Conference Report of "Year 2000 Working Conference on Mastocytosis"", *Leuk. Res.*, **25**, 603–625.
- [70] Valent, P., Horny, H.-P., Li, C.Y., Longley, J.B., Metcalfe, D.D., Parwaresch, R.M., *et al.* (2001) *Mastocytosis (Mast cell disease). World Health Organization (WHO) Classification of Tumours. Pathology & Genetics. Tumours of Haematopoietic and Lymphoid Tissues*, edited by E.S. Jaffe, N.L. Harris, H. Stein and J.W. Vardiman. Vol 1. Pp 291–302.
- [71] Horny, H.-P., Sillaber, C., Menke, D., Kaiserling, E., Wehrmann, M., Stehberger, B., *et al.* (1998) "Diagnostic utility of staining for tryptase in patients with mastocytosis", *Am. J. Surg. Pathol.*, **22**, 1132–1140.
- [72] Fukuda, T., Kamashima, T., Tsuura, Y., Suzuki, T., Kakiyama, T., Naito, M., *et al.* (1995) "Expression of the *c-kit* gene product in normal and neoplastic mast cells but not in neoplastic basophil/mast cell precursors from chronic myelogenous leukaemia", *J. Pathol.*, **177**, 139–146.
- [73] Li, W.V., Kapadia, S.B., Sonmez-Alpan, E. and Swerdlow, S.H. (1996) "Immunohistochemical characterization of mast cell disease in paraffin sections using tryptase, CD68, myeloperoxidase, lysozym, and CD20 antibodies", *Mod. Pathol.*, **9**, 982–988.
- [74] Li, C.-Y. (2001) "Diagnosis of mastocytosis: Value of cytochemistry and immunohistochemistry", *Leuk. Res.*, **25**, 537–541.
- [75] Prokocimer, M. and Polliack, A. (1981) "Increased bone marrow mast cells in preleukemic syndromes, acute leukemia, and lymphoproliferative disorders", *Am. J. Clin. Pathol.*, **75**, 34–38.
- [76] Valent, P., Sperr, W.R., Samorapoompichit, P., Geissler, K., Lechner, K., Horny, H.P., *et al.* (2001) "Myelomastocytic overlap syndromes: Biology, criteria, and relationship to mastocytosis", *Leuk. Res.*, **25**, 595–602.
- [77] Jordan, J.H., Sperr, W.R., Lechner, K., Geissler, K., Scherthaner, G.-H., Fritsche-Polanz, R., *et al.* (2002) "Stem cell factor-induced bone marrow mast cell hyperplasia mimicking systemic mastocytosis (SM): histopathologic and morphologic evaluation with special reference to novel SM-criteria", *Leuk. Lymphoma*, **43**, 575–582.
- [78] Valent, P., Samorapoompichit, P., Sperr, W.R., Horny, H.-P. and Lechner, K. (2002) "Myelomastocytic leukemia: myeloid neoplasm characterized by partial differentiation of mast cell-lineage cells", *Hematol. J.*, **3**, 90–94.
- [79] Sperr, W.R., Escribano, L., Jordan, J.H., Scherthaner, G.H., Kundi, M., Horny, H.-P., *et al.* (2001) "Morphologic properties of neoplastic mast cells: delineation of stages of maturation and implication for cytological grading of mastocytosis", *Leuk. Res.*, **25**, 529–536.
- [80] Jordan, J.H., Walchshofer, S., Jurecka, W., Mosberger, I., Sperr, W.R., Wolff, K., *et al.* (2001) "Immunohistochemical properties of bone marrow mast cells in systemic mastocytosis: evidence for expression of CD2, CD117/Kit, and bcl-x<sub>L</sub>", *Hum. Pathol.*, **32**, 545–552.
- [81] Sotlar, K., Horny, H.P., Simonitsch, I., Krokowski, H., Aichberger, K.J., Mayerhofer, M., Printz, D., *et al.* (2004) "CD25 indicates the neoplastic phenotype of mast cells: a novel immunohistochemical marker for the diagnosis of systemic mastocytosis (SM) on routinely processed bone marrow biopsy specimens", *Am. J. Surg. Pathol.*, **28**, 1319–1325.
- [82] Sperr, W.R., Stehberger, B., Wimazal, F., Baghestanian, M., Schwartz, L.B., Kundi, M., *et al.* (2002) "Serum tryptase measurements in patients with myelodysplastic syndromes", *Leuk. Lymphoma*, **43**, 1097–1105.
- [83] Sperr, W.R., Jordan, J.H., Baghestanian, M., Kiener, H.P., Samorapoompichit, P., Semper, H., *et al.* (2001) "Expression of mast cell tryptase by myeloblasts in a group of patients with acute myeloid leukemia", *Blood*, **98**, 2200–2209.
- [84] Sperr, W.R., Hauswirth, A.W. and Valent, P. (2002) "Tryptase a novel biochemical marker of acute myeloid leukemia", *Leuk. Lymphoma*, **43**, 2257–2261.
- [85] Schwartz, L.B. (2001) "Clinical utility of tryptase levels in systemic mastocytosis and associated hematologic disorders", *Leuk. Res.*, **25**, 553–562.
- [86] Schwartz, L.B., Metcalfe, D.D., Miller, J.S., Earl, H. and Sullivan, T. (1987) "Tryptase levels as an indicator of mast-cell activation in systemic anaphylaxis and mastocytosis", *N. Engl. J. Med.*, **316**, 1622–1626.
- [87] Valent, P., Sperr, W.R., Schwartz, L.B. and Horny, H.P. (2004) "Classification of systemic mast cell disorders: delineation from immunologic diseases and non-mast cell lineage hematopoietic neoplasms", *J. Allergy Clin. Immunol.*, **114**, 3–11.
- [88] Jordan, J.H., Jäger, E., Sperr, W.R., Schwarzinger, I., Födinger, M., Fritsche-Polanz, R., *et al.* (2003) "Numbers of colony-forming progenitors in patients with systemic mastocytosis: potential diagnostic implications and comparison with myeloproliferative disorders", *Eur. J. Clin. Invest.*, **33**, 611–618.
- [89] Topar, G., Staudacher, C., Geisen, F., Gabl, C., Fend, F., Herold, M., *et al.* (1998) "Urticaria pigmentosa: a clinical, hematopathologic, and serologic study of 30 adults", *Am. J. Clin. Pathol.*, **109**, 279–285.
- [90] Hartmann, K. and Henz, B.M. (2002) "Cutaneous mastocytosis – clinical heterogeneity", *Int. Arch. Allergy Immunol.*, **127**, 143–146.
- [91] Willemze, R., Ruiters, D.J., Scheffer, E. and van Vloten, W.A. (1980) "Diffuse cutaneous mastocytosis with multiple cutaneous mastocytomas. Report of a case with clinical, histopathological and ultrastructural aspects", *Br. J. Dermatol.*, **102**, 601–607.
- [92] Valent, P., Akin, C., Sperr, W.R., Escribano, L., Arock, M., Horny, H.P., *et al.* (2003) "Aggressive systemic mastocytosis and related mast cell disorders: current treatment options and proposed response criteria", *Leuk. Res.*, **27**, 635–641.

- [93] Dalton, R., Chan, L., Batten, E. and Eridani, S. (1986) "Mast cell leukemia: evidence for bone marrow origin of the pathological clone", *Br. J. Haematol.*, **64**, 397–406.
- [94] Travis, W.D., Li, C.Y., Hogaland, H.C., Travis, L.B. and Banks, P.M. (1986) "Mast cell leukemia: Report of a case and review of the literature", *Mayo Clin. Proc.*, **61**, 957–966.
- [95] Austen, K.F. (1992) "Systemic mastocytosis", *N. Engl. J. Med.*, **326**, 639–640.
- [96] Castells, M. and Austen, K.F. (2002) "Mastocytosis: mediator-related signs and symptoms", *Int. Arch. Allergy Immunol.*, **127**, 147–152.
- [97] Escribano, L., Akin, C., Castells, M., Orfao, A. and Metcalfe, D.D. (2002) "Mastocytosis: current concepts in diagnosis and treatment", *Ann. Hematol.*, **81**, 677–690.
- [98] Beltrani, G. and Carlesimo, O.A. (1966) "Telangiectasia macularis eruptiva perstans with mastocytosis", *Minerva Dermatol.*, **41**, 436–442.
- [99] Cohn, M.S. and Mahon, M.J. (1994) "Telangiectasia macularis eruptiva perstans", *J. Am. Osteopath Assoc.*, **94**, 246–248.
- [100] Wolff, K. (2002) "Treatment of cutaneous mastocytosis", *Int. Arch. Allergy Immunol.*, **127**, 156–159.
- [101] Verbov, J.L. and Borrie, P.F. (1971) "Diffuse cutaneous mastocytosis", *Br. J. Dermatol.*, **84**, 190–191.
- [102] Requena, L. (1992) "Erythrodermic mastocytosis", *Cutis*, **49**, 189–192.
- [103] McDermott, W.V. and Topol, B.M. (1985) "Systemic mastocytosis with extensive large cutaneous mastocytomas: surgical management", *J. Surg. Oncol.*, **30**, 221–225.
- [104] Worobec, A.S. (2000) "Treatment of systemic mast cell disorders", *Hematol. Oncol. North Am.*, **14**, 659–687.
- [105] Godt, O., Proksch, E., Streit, V. and Christophers, E. (1997) "Short- and long-term effectiveness of oral and bath PUVA therapy in urticaria pigmentosa and systemic mastocytosis", *Dermatology*, **195**, 35–39.
- [106] Pardanani, A., Elliott, M., Reeder, T., Li, C.Y., Baxter, E.J., Cross, N.C., et al. (2003) "Imatinib for systemic mast cell disease", *Lancet*, **362**, 535–536.
- [107] Tefferi, A. and Pardanani, A. (2004) "Imatinib therapy in clonal eosinophilic disorders, including systemic mastocytosis", *Int. J. Hematol.*, **79**, 441–447.
- [108] Sperr, W.R., Walchshofer, S., Horny, H.P., Födinger, M., Simonitsch, I., Fritsche-Polanz, R., et al. (1998) "Systemic mastocytosis associated with acute myeloid leukaemia: report of two cases and detection of the *c-kit* mutation Asp-816 to Val", *Br. J. Haematol.*, **103**, 740–749.
- [109] Kluin-Nelemans, H.C., Jansen, J.H., Breukelman, H., Wolthers, B.G., Kluin, P.M., et al. (1992) "Response to interferon alfa-2b in a patient with systemic mastocytosis", *N. Engl. J. Med.*, **326**, 619–623.
- [110] Delaporte, E., Pierard, E., Wolters, B.G., Desreumaux, P., Janin, A., Cortot, A., et al. (1995) "Interferon-alpha in combination with corticosteroids improves systemic mast cell disease", *Br. J. Dermatol.*, **132**, 479–482.
- [111] Worobec, A.S., Kirshenbaum, A.S., Schwartz, L.B. and Metcalfe, D.D. (1996) "Treatment of three patients with systemic mastocytosis with interferon alpha-2b", *Leuk. Lymphoma*, **22**, 501–508.
- [112] Weide, R., Ehlenz, K., Lorenz, W., Walthers, E., Klausmann, M. and Pfluger, K.H. (1996) "Successful treatment of osteoporosis in systemic mastocytosis with interferon alpha-2b", *Ann. Hematol.*, **72**, 41–43.
- [113] Hauswirth, A.W., Simonitsch-Klupp, I., Uffmann, M., Koller, E., Sperr, W.R., Lechner, K., et al. (2004) "Response to therapy with interferon alpha-2b and prednisolone in aggressive systemic mastocytosis: report of five cases and review of the literature", *Leuk. Res.*, **28**, 249–257.
- [114] Tefferi, A., Li, C.Y., Butterfield, J.H. and Hoagland, H.C. (2001) "Treatment of systemic mast-cell disease with cladribine", *N. Engl. J. Med.*, **344**, 307–309.
- [115] Kluin-Nelemans, H.C., Oldhoff, J.M., Van Doormaal, J.J., Van 't Wout, J.W., Verhoef, G., Gerrits, W.B., et al. (2003) "Cladribine therapy for systemic mastocytosis", *Blood*, **102**, 4270–4276.
- [116] Pardanani, A., Hoffbrand, A.V., Butterfield, J.H. and Tefferi, A. (2004) "Treatment of systemic mast cell disease with 2-chlorodeoxyadenosine", *Leuk. Res.*, **28**, 127–131.
- [117] Akin, C., Brockow, K., D'Ambrosio, C., Kirshenbaum, A., Ma, Y., Longley, J.B., et al. (2003) "Effects of tyrosine kinase inhibitor STI571 on human mast cells bearing wild-type or mutated forms of *c-kit*", *Exp. Hematol.*, **31**, 686–692.
- [118] Ma, Y., Zeng, S., Metcalfe, D.D., Akin, C., Dimitrijevic, S., et al. (2002) "The *c-kit* mutation causing human mastocytosis is resistant to STI571 and other KIT kinase inhibitors; kinases with enzymatic site mutations show different inhibitor sensitivity profiles than wild-type kinases and those with regulatory type mutations", *Blood*, **99**, 1741–1744.
- [119] Frost, M.J., Ferrao, P.T., Hughes, T.P. and Ashman, L.K. (2002) "Juxtamembrane mutant V560GKit is more sensitive to Imatinib (STI571) compared with wild-type *c-kit* whereas the kinase domain mutant D816VKit is resistant", *Mol. Cancer Ther.*, **1**, 1115–1124.
- [120] Horny, H.-P., Parwaresch, M.R., Kaiserling, E., Müller, K., Olbermann, M., Mainzer, K., et al. (1986) "Mast cell sarcoma of the larynx", *J. Clin. Pathol.*, **39**, 596–602.
- [121] Kojima, M., Nakamura, S., Itoh, H., Ohno, Y., Masawa, N., Joshita, T., et al. (1999) "Mast cell sarcoma with tissue eosinophilia arising in the ascending colon", *Modern Pathology*, **12**, 739–743.
- [122] Guenther, P.P., Huebner, A., Sobottka, S.B., Neumeister, V., Weissbach, G., Todt, H., et al. (2001) "Temporary response of localized intracranial mast cell sarcoma to combination chemotherapy", *J. Pediatr. Hematol. Oncol.*, **23**, 134–138.