

## Use of Nano Hydroxyapatite Bone Graft in Immediate Dental Implants

R. AARTHI<sup>1</sup>, VIJAY EBENEZER<sup>2</sup>, R. BALAKRISHNAN<sup>3</sup>, BANU SARGUNAR<sup>4</sup>,  
MUTHUMANI<sup>5</sup> and SHANMUGA PRIYAN<sup>6</sup>

Department of Oral and Maxillofacial Surgery, Sree Balaji Dental College and Hospital,  
Bharath University, Pallikaranai, Chennai - 600100, India.

DOI: <http://dx.doi.org/10.13005/bpj/689>

(Received: July 25, 2015; accepted: September 10, 2015)

### ABSTRACT

The purpose of this study is to evaluate the advantages in using Nano hydroxyapatite Bone Graft in immediate implants. Replacement of the Nano Hydroxyapatite by new bone, survival of implants, changes in crestal bone level and stability of implants have been discussed

**Key words:** Extraction, Immediate dental implants, Nano Hydroxyapatite bone grafts.

### INTRODUCTION

Implant by definition "means any object or material, such as an alloplastic substance or other tissue, which is partial or completely inserted into the body for therapeutic, diagnostic, prosthetic, or experimental purpose. In Immediate dental implant placement following tooth extraction in appropriately selected cases has been considered the optimal procedure for the following reasons, natural healing process are mobilized to the maximum, no bone resorption has taken place yet, osteotomy is reduced, a number of surgical stages are eliminated, design and construction of prosthesis, and positive psychological effect on the patient has been achieved.<sup>1,2</sup>

Hydroxyapatite is one of the most studied biomaterials in the medical field for its proven biocompatibility and for being the main constituent of the mineral part of bone and teeth.

Because of its unique properties, such as the ability to chemically bond to bone, to not induce toxicity or inflammation and to stimulate bone growth through a direct action on osteoblasts,

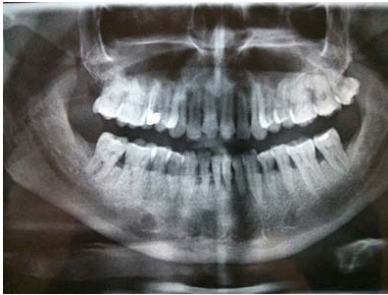Nano-HA has been widely used in oral and maxillofacial surgery. Its use in oral implantology, however, is a widely used practice established for years, as this substance has excellent osteoinductive capacity and improves bone-to-implant integration. Hydroxyapatite is an important source of calcium and phosphate, very important for the remineralization of demineralized enamel areas. The inorganic component of all the mineralized tissues of the human body is, in fact, made up of a large prevalence of calcium phosphate salts. Other inorganic materials such as calcium carbonates and sulphates are present in smaller quantities. This regenerative techniques using combinations of bone grafts have been suggested promoting bone regeneration in localized defects at implants placed into extracted sockets<sup>3</sup>.

### Study of 30 cases

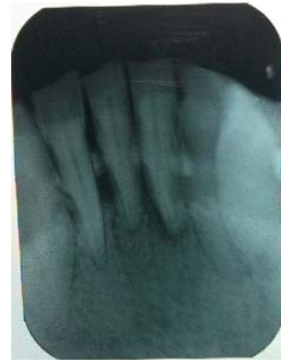This clinical study and design has been carried out on 30 patients presenting to Department of oral and maxillofacial surgery. Both male and female patients aged 20-60 years, anterior and posterior, maxillary and mandibular teeth which needs to be extracted will be included in this study. A through detailed history was taken for any

systemic disorders and routine blood investigations were done. The patient fulfilled the following required criteria before undergoing treatment like patients with grossly decayed teeth, root stumps which needs to be extracted, non salvageable root canal treated teeth, fractured teeth are selected for immediate implants. Patients with uncontrolled diabetes mellitus, medically compromised, steroid therapy, endocarditis, bleeding disorders, osteoporosis, pregnant patients, endocrine disorders and other immune disorders are excluded from this study. Patient was informed about the procedure and placement of nano hydroxyapatite bone graft (synthetic bone particles) in detail and informed consent was taken. Pre operative OPG and IOPA (fig 1,2,3) was taken and

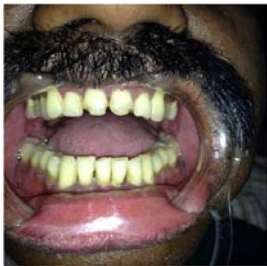crestal bone level, Inferior alveolar nerve were assessed, sinus level was noted. Atraumatic extraction (fig 4) was done with care in preserving the buccal bone. Lidocaine (2%) with 1:200000 adrenaline would be used as a local anaesthetic solution. Sequential osteotomy of the extracted socket was done with copious saline irrigation drill bits of sizes 2.0, 2.50, 2.80, 3.2, 3.65mm. Implant placement done in prepared socket and primary stability achieved using torque wrench of 40 Ncm, perimplant defect was filled with nano hydroxyapatite bone graft mixed with blood (fig 5,6), cover screw was placed, wound closure was done with black silk. Post operative



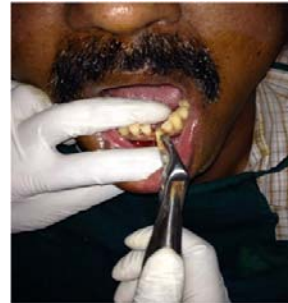
**Fig. 1: Pre Operative Radiograph(OPG)**



**Fig. 2: Pre Operative IOPA**



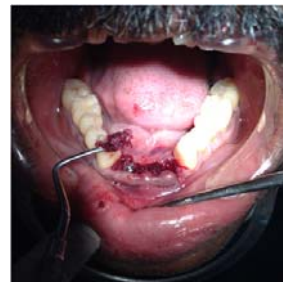**Fig. 3: Pre Operative intra oral**



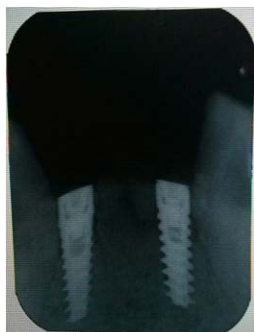**Fig. 4: Atraumatic Extraction**



**Fig. 5: Nano Hydroxyapatite Bone Graft Mixed with Blood**



**Fig. 6: Placement of bone graft**



**Fig. 7: 3 Months Post Operative**

instructions were given, medication was advised. Immediate post-operative radiograph of the implants reveals bone-like mass surrounding the implant. Suture removal was done after a week. Clinical review and radiographical review was done on first month, third month (Fig. 7) and sixth month. Radiographs of each month reveal the bone level around the implants.

### DISCUSSION

Atraumatic extraction in immediate placement type will decrease the risk of bone necrosis and permit bone remodeling process to occur, thus the healing period is rapid and allows the woven bone to be transformed into lamellar bone<sup>4</sup>. In immediate implant placement there is minimal use of surgical drills because the socket is already found except for slight increase of the length of the socket to provide primary stability<sup>5</sup>.

Hydroxyapatite represents 60-70% and 90% in weight of bone and enamel respectively. Nano-Hydroxyapatite, which presents crystals ranging in size between 50 and 1000 nm. The crystals used in this study as 150-700 nm. The Nano-Hydroxyapatite has a strong ability to bond with proteins. This ability is due to the size of nanoparticles, which considerably increase the

surface area to which proteins can bind. Besides, Nano-Hydroxyapatite also acts as filler because it repairs small holes and depressions on enamel surface, a function enhanced by the small size of the particles that compose it. Studies on biocompatibility have shown that hydroxyapatite chemically binds to bone and induces no phenomena of toxicity nor inflammatory, local or systemic. The mechanism of osseointegration with faster and stronger bone formation, for better stability during the healing process, thus allowing more rapid loading of the implant<sup>6,7</sup>. In the natural socket is rich in periodontal cells and matrix, which makes the healing faster and more predictable<sup>8</sup>. Some researches show that the hydroxyapatite, unlike tricalcium phosphate, doesn't undergo resorption. Other authors have instead found resorption of hydroxyapatite. In this study the hydroxyapatite nano bone grafted around implants had a crystallographic affinity with inorganic components that constitute the bone, hydroxyapatite is able to establish chemical bonds and to ensure a more rapid integration of titanium implants to bone and surrounding tissues. Muller-Mai et al tested nanoapatite and from their results, it was seen that both materials were suitable for bone replacement and for drug release such as antibiotics, growth factors or other substances. In addition, the organic component can be used to control physical properties in the bone implantation bed<sup>9</sup>. Nanocrystalline hydroxyapatite binds bone and stimulates bone healing encouraging osteoblastic activity<sup>10</sup>.

### CONCLUSION

In our short term study in a limited population the use of nano hydroxyapatite as graft material around immediate implant placement has yielded promising results. Perhaps a larger population group with a prolonged post-operative follow up would throw more light on the subject.

### REFERENCE

1. Zahnmed SM: Prevention of alveolar ridge resorption after teeth extraction. *Int J Oral Maxillofac Surg.* **114**: 328, (2004).
2. Esposito M, Grusovin MG, Kwan S, Worthington H V, Coulthard P: Intervention for replacing missing teeth: bone augmentation techniques for dental implant treatment. *Aust Dent J.* **70**: 54, (2009).
3. Schwartz-Arad D, & Chaushu G. The ways and wherefores of immediate placement of

- implants into fresh extraction sites: a literature review. *J Periodontol* **68**: 915-23 (1997).
4. Hansson, HA, Albrektsson, T, & Branemark, PI. Structural aspects of the interface between tissue and titanium implants. *J Prosth Dent* **50**:108-113 (1983).
  5. Barzilay, I, Graser, GN, & Iranpour, B. Immediate implantation of pure titanium implant into an extraction socket: Report of a pilot procedure. *Int J Oral Maxillofac Implants* **6**: 277-284 (1991).
  6. Wennerberg A, Albrektsson T. Effects of titanium surface topography on bone integration: a systematic review. *Clin Oral Implants Res*; **20**:172-184 (2009).
  7. Beutner R, Michael J, Schwenzer B, Scharnweber D. Biological nano-functionalization of titanium-based biomaterial surfaces: a flexible toolbox. *J R Soc Interface*; **7**:S93-S105 (2010).
  8. Peñarrocha M, Uribe R, & Balaguer J. Immediate implants after extraction. a review of the current situation *Med Oral* **9**: 234-42 (2004).
  9. Muller-Mai CM, Stupp SI, Voigt C, Gross KA. Nanoapatite and organoapatite implants in bone: Histology and ultrastructure of the interface. *J Biomed Mater Res*; **29**: 9-18 (1995).
  10. Singh VP, Nayak DG, Shah D. Clinical and radiographic evaluation of Nano-crystalline hydroxyapatite bone graft (Sybografit) in combination with bioresorbable collagen membrane (Periocol) in periodontal intrabony defects. *Dent Res J (Isfahan)* **9**(1):60-7 (2012).