

CORE DECOMPRESSION FOR EARLY ATRAUMATIC OSTEONECROSIS OF THE FEMORAL HEAD

I. D. LEARMONTH, S. MALOON, G. DALL

From Princess Alice Orthopaedic Hospital and the University of Cape Town

We performed 41 core decompressions in 32 patients for stage I or stage II osteonecrosis of the femoral head. The intra-osseous pressure at the intertrochanteric level was raised in 28 (68%) and there was histological confirmation of necrosis in 36 hips (88%).

After a follow-up of 10 to 84 months (mean 31) nine of the 12 stage I hips (75%) showed significant clinical or radiological deterioration; no evidence of necrosis had been found in the core specimens of the other three hips. Of the 29 hips in stage II, 25 (86%) showed significant radiological deterioration, and only five (17%) had improved clinically.

We believe that once necrosis has occurred, core decompression will not significantly influence the subsequent course of the disease.

In 1962 a review of the English literature by Mankin and Brower revealed only 24 reported cases of 'idiopathic necrosis' of the femoral head. The large number reported since then suggests that the incidence of osteonecrosis is increasing. Many conditions have been cited as aetiological agents. These include trauma, steroid therapy, alcohol abuse, haemoglobinopathies, exposure to a dysbaric environment and Gaucher's disease. No cause is found in approximately 20% of cases.

The pathogenesis of non-traumatic osteonecrosis of the femoral head remains obscure. Both extravascular and intravascular factors, which may be either extra-osseous or intra-osseous, have been implicated. Solomon (1981) suggested that lipocyte hypertrophy could initiate compression of vascular sinusoids with resultant venous stasis and hypertension. Cruess, Ross and Crawshaw (1975), impressed with the similarity to the pathology of caisson disease, implicated fat embolism of end arteries, and this theory was supported by Jones (1985). Irrespective of the cause, the effect of ischaemia is likely to be further potentiated by the compartmental nature of blood flow in bone.

The aim of treatment of avascular necrosis must be

to preserve, not to replace, the femoral head. Early diagnosis is therefore important if it can allow successful treatment of a potentially reversible lesion. A high index of suspicion is essential, as in the early stages, radiology is often normal. However, Merle D'Aubigné et al (1965) reviewing 139 cases of osteonecrosis of the femoral head, reported that both hips were affected in 52% of cases.

With bilateral involvement it is difficult to interpret positive scintigraphy. Both Ficat (1985) and Zizic et al (1986) have suggested that measurement of the intra-osseous pressure is a valuable aid to early diagnosis. The normal mean pressure in the femoral neck adjacent to a non-arthritic joint has been reported by Lempberg and Arnoldi (1978) to be 18.7 mmHg (range 12.9 to 23.5) while in the greater trochanter it was 17.2 mmHg (range 12 to 26).

Core decompression for osseous hypertension has been likened to fasciotomy for compartmental syndrome in the forearm and has been recommended as a successful form of treatment for the early stages of osteonecrosis. Ficat (1985) reviewed 133 hips treated by core decompression and reported good clinical results in 94% of stage I and 82% of stage II lesions, and Hungerford and Zizic (1980) reported similar results in 41 cases.

However, Camp and Colwell (1986), reviewing 40 core decompressions performed for stage I or stage II osteonecrosis, reported that 60% had deteriorated clinically or radiologically; Hopson and Siverhus (1988) reported similar findings. All these authors found a poor correlation between the presence of osteonecrosis and increased intra-osseous pressure and also reported a 5% to 10% incidence of fracture of the proximal femur related to the core procedure.

I. D. Learmonth, FRCS, FCS(SA) Orth, Head of Rheumatology Surgical Services
S. Maloon, FCS(SA) Orth, Senior Orthopaedic Registrar
G. Dall, MCh, Dean of the Faculty of Medicine
Princess Alice Orthopaedic Hospital, Private Bag, Plumstead 7800, Cape Town, Republic of South Africa.

Correspondence should be sent to Mr I. D. Learmonth.

© 1990 British Editorial Society of Bone and Joint Surgery
0301-620X/90/3051 \$2.00
J Bone Joint Surg [Br] 1990; 72-B: 387-90.

Core decompression is an invasive procedure with a significant potential for morbidity, and the early optimism regarding its use for early osteonecrosis of the femoral head has been tempered by recent adverse reports. We therefore feel it appropriate to report our own results using core decompression for stage I and II lesions.

METHODS AND PATIENTS

The early diagnosis of osteonecrosis in our series was based on a high index of suspicion in patients with known risk factors, and especially where there was proven necrosis of the contralateral femoral head. All patients presented with hip pain and radiographs were staged in accordance with the classification of Arlet and Ficat (1971). Core decompression was performed in the presence of a positive bone scan or early radiological changes (stages I and II).

Before the decompression, a cannulated screw was introduced through the lateral femoral cortex into the intertrochanteric area to give a watertight seal and was attached to a pressure transducer and a manometer. After establishing a zero baseline, resting pressures were measured at 30-second intervals for three minutes. A stress test was then performed by injecting 5 ml of saline into the bone, again recording pressures at 30-second intervals for three minutes.

Decompression was performed with a 10 mm trephine, using an image-intensifier to site the lateral entry to give ready access to the necrotic segment. Radiographic visualisation in both planes was used to guide power reaming of the trephine across the necrotic segment. Care was taken to breach the subchondral bone, and a successful biopsy was capped proximally with articular cartilage (Fig. 1). Postoperatively the hip was protected from weight-bearing for six weeks.

Patients. From 1979 to 1986, 41 patients with suspected stage I and II osteonecrosis had 50 core decompressions at Groote Schuur and Princess Alice Orthopaedic

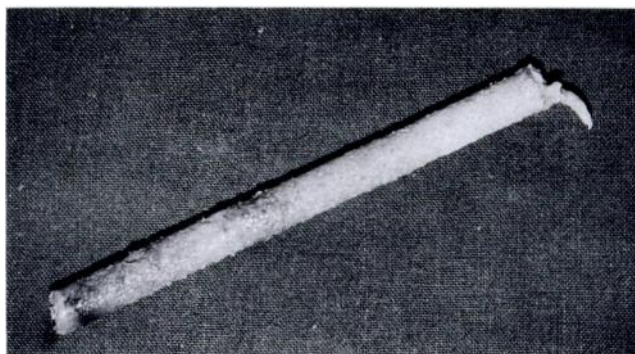


Fig. 1

A typical core biopsy specimen, showing the cartilage-capped necrotic proximal segment.

Hospital. Of these, four had died and five could not be traced, so 41 hips in 32 patients were available for review and radiography. For clinical assessment we recorded pain, function and range of movement on scales of six by the method of Merle D'Aubigné and Postel as modified by Charnley (1979). There were 21 men and 11 women, aged at presentation from 22 to 58 years (mean 37). Follow-up was from 12 to 84 months (mean 32).

The commonest associated aetiological factor was alcohol abuse, noted in 16 patients. Seven patients gave a history of steroid therapy: six of these had lupus erythematosus. One patient had thalassaemia major. In eight patients no aetiological agent could be identified.

RESULTS

From the 12 hips radiographically classified as stage I, three of the core specimens showed no histological evidence of necrosis, but of the 29 stage II hips, 26 had histological confirmation of necrosis.

The clinical and radiological results are shown in Table I: in stage I, 75% had deteriorated radiologically, and 58% had deteriorated clinically. In stage II, 76%

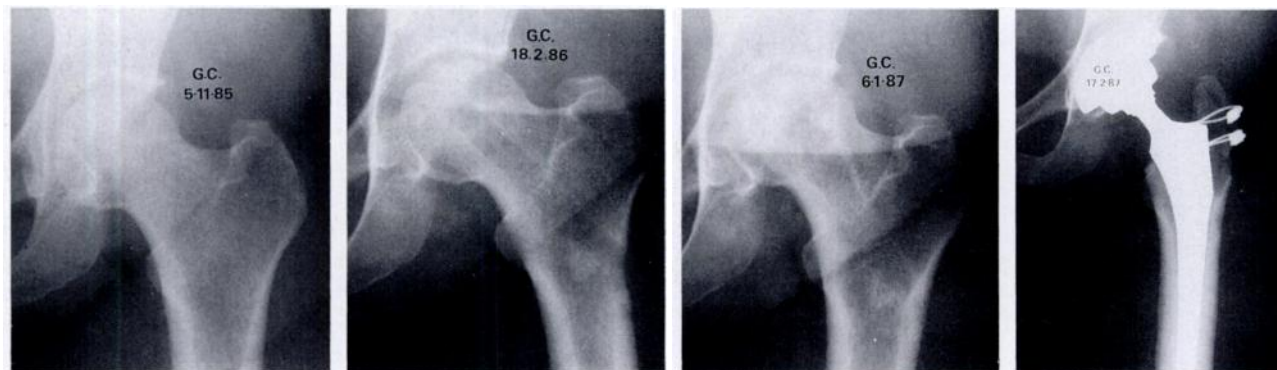


Fig. 2a

Fig. 2b

Fig. 2c

Fig. 2d

The almost inevitable progression of an established lesion: a) early stage II osteonecrosis of the femoral head, b) radiograph after core biopsy, c) collapse of the femoral head with loss of joint space, d) cementless hip replacement.

were worse clinically, and 86% had deteriorated radiologically. Eighteen of the 41 hips (44%) have subsequently required a replacement arthroplasty (Fig. 2).

We accepted 30 mmHg as the upper limit of normal for intra-osseous pressure. The resting metaphyseal pressure was raised in 28 hips (68%), but the stress test was found to be entirely non-contributory.

No major complications were encountered in the patients we reviewed, but one of the four patients who died had sustained an intertrochanteric fracture in the early postoperative period; this was successfully managed with a sliding screw and plate.

DISCUSSION

It is generally agreed that early diagnosis of osteonecrosis is critical if the femoral head is to be salvaged. Conklin et al (1983), comparing the sensitivity of bone scans and radiographs in a prospective study of 36 patients with systemic lupus erythematosus, reported an 89% sensi-

tivity for bone scans compared with 41% for radiographs. They based their assessment on elevation of bone marrow pressure, but this must be suspect: in our series only 68% of the hips showed a raised intramedullary pressure. A similarly poor correlation between the intra-operative diagnostic tests and evidence of necrosis in the core specimen was reported by Hopson and Siverhus (1988). We agree with Camp and Colwell (1986) that magnetic resonance imaging is probably the most sensitive investigation for the early diagnosis of osteonecrosis.

Unfortunately there have been no prospective controlled studies of patients with osteonecrosis of the femoral head, and this ignorance of the natural history complicates the evaluation of early treatment. Therapeutic options range from prolonged joint protection (Herdon and Aufranc 1972) to a combination of bone grafting and electrical stimulation (Steinberg et al 1984).

Wilkes and Visscher (1975) have shown that bone acts as a Starling resistor, so that bone marrow pressure directly affects vascular resistance and therefore bone

Table I. Review of 41 hips after core decompression (number, *per cent*)

	Clinical result			Radiological result		
	Improved	Unchanged	Worse	Improved	Unchanged	Worse
Stage I	3 25	2 17	7 58	0 3	25 25	9 75
Stage II	5 17	2 7	22 76	2 7	2 7	25 86

Table II. Reported clinical results after core decompression (*percentages*)

Author	Stage I		Stage II	
	Improved or unchanged	Worse	Improved or unchanged	Worse
Hungerford 1979	94	6	94	6
Ficat 1985	94	6	18	82
Camp and Colwell 1986	40	60	50	50
Hopson and Siverhus 1988	30	70	50	50
Learmonth, Maloon and Dall 1990	42	58	24	76

Table III. Reported radiological results after core decompression (*percentages*)

Author	Stage I		Stage II	
	Improved or unchanged	Worse	Improved or unchanged	Worse
Hungerford 1979	74	26	74	26
Ficat 1985	87	13	67	33
Camp and Colwell 1986*	47	53	64	36
Learmonth et al 1990	25	75	14	86

* the eight hips classified as stage IV pre-operatively have been excluded

blood flow. It has been suggested that core decompression may arrest the ischaemic cycle which precedes histologically-demonstrable necrosis, the preclinical or preradiological stage 0 of Ficat (1985).

Hungerford (1979) reported that 83% of 41 stage I and II patients were asymptomatic after core decompression, with no radiographic progression after a mean follow-up of approximately 36 months, and Ficat (1985) has reported 92% good results in 156 hips followed up for more than five years. These results contrast sharply with our experience and that reported by Camp and Colwell (1986) and Hopson and Siverhus (1988) as set out in

Tables II and III. Hungerford and Zizic (1980) reported that even in stage III, 70% of the hips were asymptomatic at a mean follow-up of 20 months.

In our whole series of stage I and stage II cases, some 88% of core specimens revealed evidence of necrosis. Enneking (1979) has noted that an established lesion is bordered by a dense sclerotic rim; we suggest that it is highly unlikely that a single breach into the avascular segment will promote revascularisation and repair. The excision of previously decompressed femoral heads at replacement arthroplasty revealed that the cores were filled with relatively avascular fibrous tissue.

It therefore appears that while core biopsy can decompress the osseous compartment in the earliest stages of the disease, once avascular necrosis is established it is irreversible. The discrepancy in the results of core biopsy for stages I and II disease reported in the literature is troubling, but it is recognised that dead bone may function for many years without structural failure. Many of the pathological sequelae of osteonecrosis of the femoral head are consequent upon the revascularisation and repair processes. There is a need for multicentre prospective controlled studies, in the different aetiological subgroups, to evaluate objectively the place of core decompression in the early treatment of osteonecrosis of the femoral head.

No benefits in any form have been received or will be received from a commercial party related directly or indirectly to the subject of this article.

I would like to thank Mrs D. Ward for typing the manuscript, Mr M. Wyeth for preparing the illustrations and the Medical Research Council of South Africa and the Cooper-Lowveld Trust of the University of Cape Town Research for financial assistance.

REFERENCES

- Arlet J, Ficat P. Biopsy drilling as a means of early diagnosis. In: Zinn WM, ed. *Idiopathic necrosis of the femoral head in adults*. Stuttgart: Georg Thieme Publishers, 1971:74-80.
- Camp JF, Colwell CW Jr. Core decompression of the femoral head for osteonecrosis. *J Bone Joint Surg [Am]* 1986; 68-A:1313-9.
- Charnley J. *Low friction arthroplasty of the hip: theory and practice*. Berlin, etc: Springer-Verlag, 1979.
- Conklin JJ, Alderson PO, Zizic TM, et al. Comparison of bone scan and radiograph sensitivity in the detection of steroid-induced ischaemic necrosis of bone. *Radiology* 1983; 147:221-6.
- Cruess RL, Ross D, Crawshaw E. The etiology of steroid-induced avascular necrosis of bone: a laboratory and clinical study. *Clin Orthop* 1975; 113:178-83.
- Enneking WF. The choice of surgical procedures in idiopathic aseptic necrosis. *The Hip: proceedings of the seventh open scientific meeting of the Hip Society*. St. Louis, etc: CV Mosby, 1979:138-43.
- Ficat RP. Idiopathic bone necrosis of the femoral head: early diagnosis and treatment. *J Bone Joint Surg [Br]* 1985; 67-B:3-9.
- Herndon JH, Aufranc OE. Avascular necrosis of the femoral head in the adult: a review of its incidence in a variety of conditions. *Clin Orthop* 1972; 86:43-62.
- Hopson CN, Siverhus SW. Ischaemic necrosis of the femoral head: treatment by core decompression. *J Bone Joint Surg [Am]* 1988; 70-A:1048-51.
- Hungerford DS. Bone marrow pressure, venography and core decompression in ischemic necrosis of the femoral head. *The Hip: proceedings of the seventh open scientific meeting of the Hip Society*. St. Louis, etc: CV Mosby, 1979:218-37.
- Hungerford DS, Zizic TM II. The treatment of ischaemic necrosis of bone in systemic lupus erythematosus. *Medicine (Baltimore)* 1980; 59; 2:143-8.
- Jones JP JR. Fat embolism and osteonecrosis. *Orthop Clin North Am* 1985; 16:595-633.
- Lempberg RK, Arnoldi CC. The significance of intraosseous pressure in normal and diseased states with special reference to the intraosseous engorgement-pain syndrome. *Clin Orthop* 1978; 136:143-56.
- Mankin HJ, Brower TD. Bilateral idiopathic aseptic necrosis of the femoral head in adults: "Chandler's disease". *J Hosp Joint Dis* 1962; 23:42-57.
- Merle d'Aubigné R, Postel M, Mazabraud A, Massias P, Gueguen J. Idiopathic necrosis of the femoral head in adults. *J Bone Joint Surg [Br]* 1965; 47-B:612-33.
- Solomon L. Idiopathic necrosis of the femoral head: pathogenesis and treatment. *Can J Surg* 1981; 24:573-8.
- Steinberg ME, Brighton CT, Steinberg DR, Tooze SE, Hayken GD. Treatment of avascular necrosis of the femoral head by a combination of bone grafting, decompression, and electrical stimulation. *Clin Orthop* 1984; 186:137-53.
- Wilkes CH, Visscher MB. Some physiological aspects of bone marrow pressure. *J Bone Joint Surg [Am]* 1975; 57-A:49-57.
- Zizic TM, Marcoux C, Hungerford DS, Stevens MB. The early diagnosis of ischaemic necrosis of bone. *Arthritis Rheum* 1986; 29:1177-86.