

A New Radiological Classification for Ameloblastoma Based on Analysis of 19 Cases

C Ogunsalu¹, H Daisley², K Henry, S Bedayse¹, K White¹, B Jagdeo, S Baldeo¹

ABSTRACT

Objective: To describe ameloblastoma of the jawbone in young Jamaicans, with special emphasis on radiological findings, and to introduce a radiological classification which could assist in the categorization of these cases according to their biological behaviour and hence their subsequent surgical and medical management.

Subjects and Methods: The series comprised all the 18 cases of ameloblastoma of the jaw seen in patients under the age of 20 years in the two major hospitals in Jamaica with an oral and maxillofacial surgery department from 1980 to 1995. Radiological and histological diagnosis was confirmed in all. A case of maxillary ameloblastoma in a 13-year old girl seen in the year 2000 was also included in this study. This last case had special attributes.

Results: All 19 patients had primary lesions of ameloblastoma. The mean age was 16.1 years with a mode of 18 years and a range of 13 to 19 years. The male to female ratio was 1.1:1. Eighteen cases were seen in the mandible and one case in the maxilla. Of these, 42% were unilocular and 58% were multilocular radiologically. Thirty-two per cent of cases had unerupted teeth associated with the lesions and 32% had root resorption. Based on our new radiological classification, the most predominant radiological type was Ib₂ with root resorption (42%). There was no radiological type classically simulating dentigerous cyst (Ia₂).

Conclusion: Ameloblastoma in young Jamaicans presented more in the adolescent period and are predominantly unicystic and rare in the maxilla. A new classification for ameloblastoma based solely on radiological presentation is adopted.

Nueva Clasificación Radiológica del Ameloblastoma Basada en el Análisis de 19 Casos

C Ogunsalu¹, H Daisley², K Henry, S Bedayse¹, K White¹, B Jagdeo, S Baldeo¹

RESUMEN

Objetivo: Describir el ameloblastoma del hueso maxilar en jóvenes jamaicanos, con énfasis especial en los hallazgos radiológicos, e introducir una clasificación radiológica que pudiera ayudar en la categorización de estos casos, de conformidad con su comportamiento biológico, y por ende su posterior tratamiento médico y quirúrgico.

Sujetos y Métodos: La serie abarcó el total de los 18 casos de ameloblastoma del maxilar vistos en pacientes menores de 20 años de edad en los dos hospitales principales de Jamaica con departamentos de cirugía maxilofacial, de 1980 a 1995. El diagnóstico radiológico e histológico fue confirmado en todos ellos. Un caso de ameloblastoma maxilar en una niña de 13 años, visto en el año 2000, fue incluido también en el estudio. Este último caso tuvo atributos especiales.

Resultado: Los 19 pacientes presentaron todas lesiones primarias de ameloblastoma. La edad media fue de 16.1 años, con una moda de 18 años, y un rango de 13 a 19 años. La proporción varón/hembra fue 1.1:1. A dieciocho casos se les investigó la mandíbula y a uno de los casos el maxilar superior. De estos, el 42% fueron uniloculares y el 58% multiloculares en términos radiológicos. El treinta y dos

From: School of Dentistry¹ and Anatomical Pathology², Faculty of Medical Sciences, The University of the West Indies, St Augustine, Trinidad and Tobago.

Correspondence: Dr C Ogunsalu, Oral Diseases Unit, School of Dentistry, Faculty of Medical Sciences, The University of the West Indies, St Augustine, Trinidad and Tobago. E-mail:chrisogun@yahoo.com

por ciento de los casos tenía dientes retenidos asociados con las lesiones, y el 32% presentaba reabsorción de las raíces. De acuerdo con nuestra nueva clasificación radiológica, el tipo radiológico más predominante fue Hb₂ con reabsorción de la raíz (42%). No hubo tipo radiológico que simulara clásicamente el quiste dentígero (Ia₁).

Conclusión: El ameloblastoma en los jóvenes jamaicanos se presentó más en el período de la adolescencia, y es predominantemente unicístico y de rara ocurrencia en el maxilar superior. Se adopta una nueva clasificación del ameloblastoma, basada solamente en la presentación radiológica.

West Indian Med J 2006; 55 (6): 37

INTRODUCTION

The literature is replete with the clinico-pathologic presentation of ameloblastoma (1–9), a benign epithelial odontogenic tumour that commonly affects the mandible and rarely the maxilla or the soft tissue (peripheral ameloblastoma). Most cases affect the mandibular molar and ramus region. It is the most common odontogenic tumour although it comprises only 1% of all tumours and cysts of the jaw. Six histological subtypes of ameloblastoma have long been identified and comprise the following: 1) follicular 2) plexiform 3) acanthomatous 4) granular 5) basal cell and 6) desmoplastic type. Based on the overall histologic architecture, the tumour can be further divided into four variants: solid ameloblastoma, multicystic ameloblastoma, multicystic plus solid ameloblastoma and unicystic ameloblastoma.

It is well known that ameloblastoma can be radiologically unilocular or multilocular and that unilocular or multilocular ameloblastoma may be histologically unicystic or multicystic, both of which have been shown to recur, particularly following inadequate surgical treatment. It may be wise to categorize ameloblastoma on radiological grounds,

especially in children, with the aim of utilizing this classification to interpret the growth rate and to plan the surgical treatment of these cases. The radiological classification presented in this report is the first to emerge in the world literature on ameloblastoma.

The radiologic presentation of ameloblastoma in the young may vary from unilocular radiolucency to multilocular radiolucency. The multilocular radiolucency is found to be more common than the unilocular type in children. Ameloblastoma is generally considered to be rare in the young and the average age group in most studies appears to be higher than 30 years.

The authors have devised a radiological classification which can assist in the interpretation of tumour biological behaviour and planning for medical and surgical management.

SUBJECTS AND METHODS

All 18 cases of ameloblastoma found in Jamaicans below the age of 20 years (Table 1) from data stored in the “tumour power house” were analyzed for demographic and radio-

Table 1: A Summary of cases of ameloblastoma in young Jamaicans

Case	Age (yrs)	Sex	Site of lesion	Detailed radiographic appearance
1	14	M	Bilateral mandible (anterior and posterior) with RR	Well circumscribed multilocular radiolucency from # 43 to 36, 37 region with root resorption of 35, 36. UE 43 is present
2	15	M	Anterior and posterior mandible on the right with RR	Well circumscribed unilocular radiolucency from #48 to 46 with root resorption at 45 and 46.
3	16	F	Posterior mandible on the right	Multilocular radiolucency of posterior mandible.
4	14	F	Anterior mandible on the left with RR	Multilocular radiolucency in the region of 32 to 35 with evidence of root resorption.
5	14	F	Anterior and posterior mandible from 31 to 36.	Well-defined unilocular radiolucency in the region of 31 to 36
6	15	F	Posterior mandible on the right with RR	Multilocular radiolucency with root resorption
7	18	F	Anterior and posterior mandible (bilateral)	Multilocular radiolucency from #46 to 36 with pathologic fracture of the mandible in this region. UE 31 is associated with lesion
8	13	M	Posterior mandible on the right	Multilocular radiolucency extending from 45 to 48
9	18	F	Posterior mandible on the right	Large radiolucent lesion expanding from 35 to the ascending ramus of the mandible. Unerupted 48 is associated with lesion.
10	17	F	Posterior mandible on the right	Large radiolucency distal to 47, occupying and distorting the shape of the ascending ramus. No evidence of 48 (? follicular cyst)
11	18	M	Posterior mandible on the right	Multilocular radiolucency of the mandible

Case	Age (yrs)	Sex	Site of lesion	Detailed radiographic appearance
12	13	M	Posterior mandible on the left	Unilocular radiolucency of the mandible in the 37, 38 region with unerupted 37, 38 within the radiolucency. The radiolucency extends to the ascending ramus of the mandible.
13	18	M	Posterior mandible on the right	Multilocular radiolucency from the 44, 45 region backwards up to the ascending ramus.
14	18	M	Anterior and posterior mandible on the right with RR	Multilocular radiolucency (extensive) from the 41 to the 48 region with root resorption.
15	18	M	Anterior and posterior mandible on the right	Radiolucency extending from the 43 to the 47 region with evidence of root resorption.
16	18	M	Posterior mandible on the right	Radiolucent area occupying all retromolar area of left mandible and ascending ramus in its entirety with distortion of the coronoid process UE 38 is displaced within the lesion.
17	18	M	Anterior mandible on the right	Unilocular radiolucency of the mandible
18	19	F	Anterior mandible (bilateral)	Multilocular radiolucency extending from 45 to 35
19	13	F	Anterior and posterior maxilla on the left	The CT scan finding was that of a 4.7 x 3 x 4.3 cm hypodense mass filling and expanding the left maxillary antrum. The mass also erodes the bony walls inferiorly through the hard palate and superior alveolar wall/process, medially into the nasal processes and anterolaterally into the subcutaneous tissues. Unerupted tooth is embedded within the multilocular lesion

RR = retained roots UE = unerupted tooth

graphic findings. “Tumor power house” is a programme on a MacIntosh computer specifically designed for documentation of jaw bone tumours with histopathological confirmation from cases seen at the maxillofacial surgery departments of the Cornwall Regional Hospital and Kingston Public Hospital in Jamaica. The period of study was from 1980–1995, a 16-year period, except for the additional case of a 13-year old girl with maxillary ameloblastoma in the year 2000.

The age, gender, site of lesion and radiographic appearance of these lesions were analyzed and compared with what has been previously documented in the literature. All cases studied were radiologically assessed with the use of right and left lateral oblique radiographs of the mandible, except for *case 1* which was assessed by the use of a dental panoramic tomogram (DPT) and the case of maxillary ameloblastoma which was assessed by the use of the DPT and computed tomography scan. We formulated a new classification based on the radiological appearance of the 19 cases (Fig. 1).

RESULTS

The demographics of the 19 cases of ameloblastoma in young Jamaicans are shown in Table 2 and Figure 2. Based on the new radiological classification (Fig. 1), the current series of 19 cases were documented under radiological subgroups (Table 3 and Fig. 3). The most common radiological subgroup was *Iib₂*, of which three cases had root resorption (Fig. 3). Only two cases of *Ila₂* were documented (Fig. 3). One case of *Ila₁* was documented. One must note that in this series of patients from Jamaica no *Ia₁* case was documented *ie* no case simulated the classical dentigerous cyst. One case of ameloblastoma in the maxilla of a 13-year

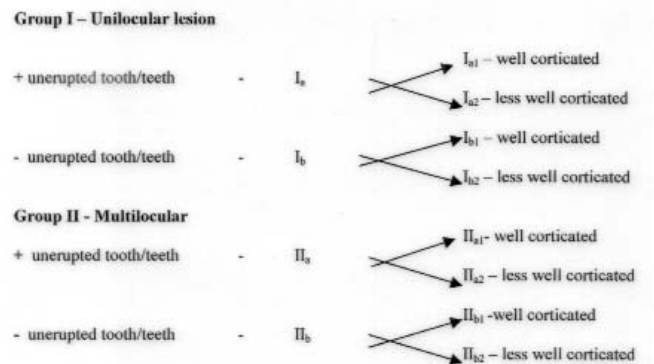


Fig. 1: New classification based on radiological appearance

*St Augustine Classification

* Each group should have ± root resorption added to it as a measure of aggression or longstanding pathology. Buccolingual expansion is not considered because of the lack of uniformity of the buccal and lingual cortical plate along the mandible (re. some thinner/thicker than the other) System was developed at the University of the West Indies, St Augustine Campus by the authors (Lecturers and students)

Table 2: Summary of demographics of ameloblastoma in young Jamaicans.

M:F = 10:9 (1.1:1)
39% of cases of ameloblastoma occurred in the young
Mean age = 16.1 years / age range 13 to 19 years
Mode = 18 years
Multilocular 58% / unilocular 42%
Unerupted teeth association = 31.6%
Root resorption = 31.6%
Maxilla 1 (5.2%) Mandible 18 (94.7%)
Multilocular predominated

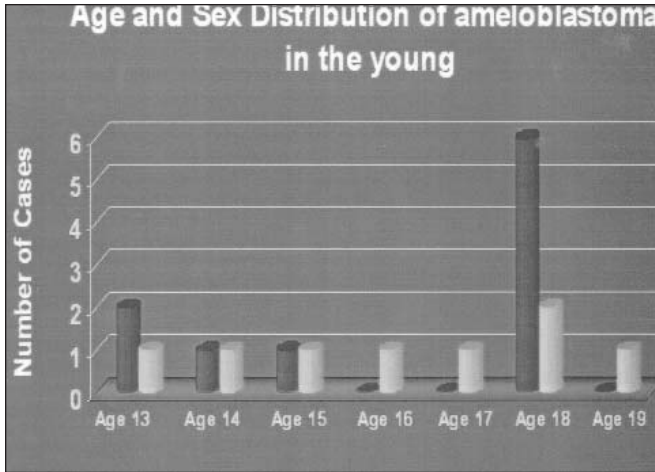


Fig. 2: Age and gender distribution of ameloblastoma in young Jamaicans.

Table 3: Distribution by subgroup (radiological subgroup)

Radiologic type	Number of cases
Ia ₁	0
Ia ₂	4
Ib ₁	2 with 1RR
Ib ₂	2
IIa ₁	1 with 1RR
IIa ₂	2
IIb ₁	0
IIb ₂	8 with 3 RR

IRR = internal root resorption
RR = root resorption

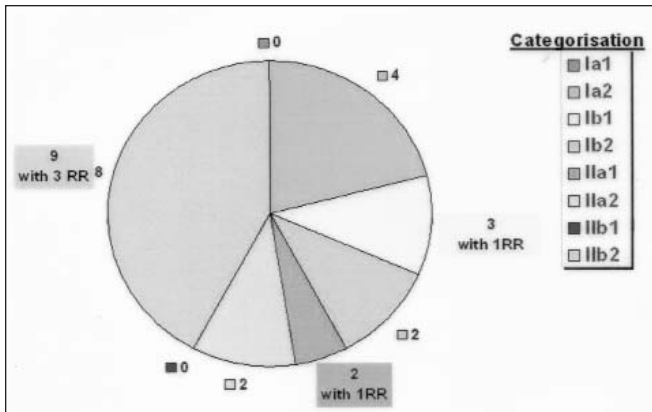


Fig. 3: Distribution of ameloblastoma in young Jamaicans according to our new classification.

old female was documented (Fig. 4); this latter was categorized as IIa₂. Table 4 shows the categorization and the suggested surgical management.

The most predominant category was IIb₂ (less well corticated multilocular radiolucent lesion without unerupted

Table 4: Suggested surgical treatment based on new radiological categorization

Radiological category of ameloblastoma	Suggested surgical management
Ia ₁ Ib ₁ Unilocular well corticated ± UET	Enucleation/curettage for removal of epithelial lining and cryotherapy or enucleation and trimming of the surrounding bone with a bur
Ia ₂ , Ib ₂ Unilocular, less well corticated ± UET	Surgical treatment as for Ia ₁ but with inclusion of 1 cm of apparently normal bone or the resection of the lesion segmentally with 1 cm of apparently normal bone
IIa ₁ IIb ₁	Depending on the size, irrespective of the presence or absence of tooth within the lesion; also dependent on presence of root resorption. Resection (marginal, segmental or hemimaxilloectomy or hemimaxilleectomy with 1cm of apparently normal bone. Liquid nitrogen therapy can be used in conjunction with any of the above mentioned treatment. If enucleation is to be done the liquid nitrogen therapy is mandatory
II a ₂ and II b ₂	Resection with cryosurgery. Re-entry cryosurgery at 6-months is highly recommended for the prevention of recurrence.

UET = unerupted teeth

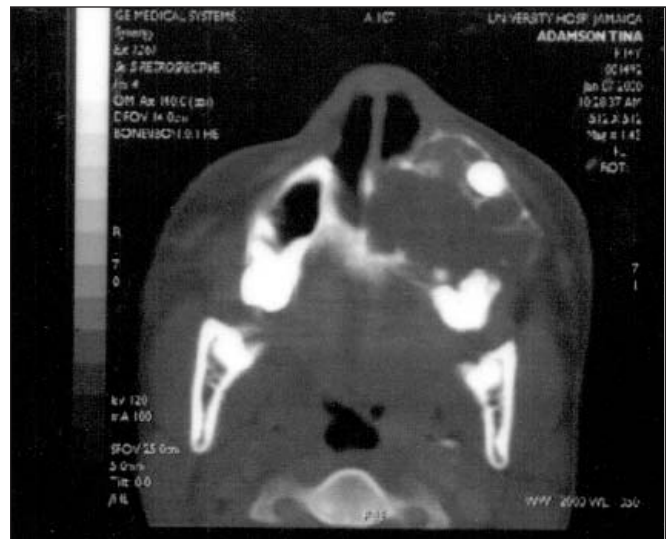

Fig. 4: Traverse slice of the CT scan showing multilocular radiolucency of the left maxilla with an unerupted tooth associated.

teeth associated). One case of IIa₁ (well circumscribed multilocular radiolucency from teeth numbers 43 to 36, 37 region with an unerupted tooth number 43 in the lesion) was reported. This IIa₁ case also had root resorption (Fig. 5).

Root resorption can occur both in unilocular and multilocular cases with or without an unerupted tooth associated with the lesion. It is more commonly found in the

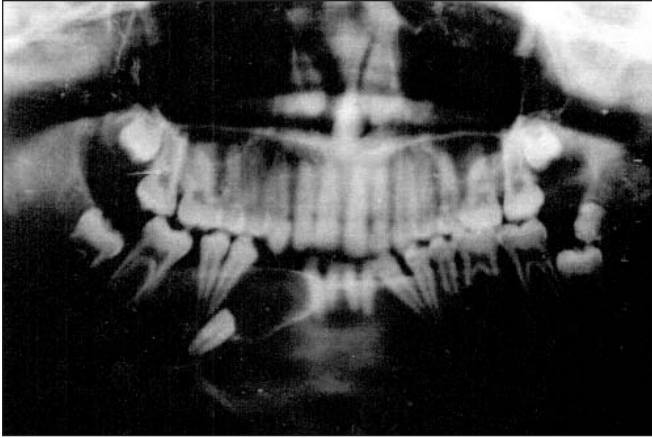


Fig. 5: Dental panoramic tomogram showing multilocular radiolucency in a child with a canine tooth associated. We classified this case as Ia_1 .

Table 5: The M:F ratio, mean age and unilocularity on radiograph from various studies (systematic review)

Series/Authors	Date	M:F ratio	Mean age (yrs)	% Unilocular
Ramanathan <i>et al</i> (8)	1967	NA	NA	NA
Daramola <i>et al</i> (9)	1975	NA	NA	NA
Kessler <i>et al</i> (10)	1986	1:1	NA	100%
Khan (11)	1989	0.9:1	10.4	72%
Chidzonga (12)	1996	1:1	15.5	20%
Olaitan <i>et al</i> (13)	1996	1:1.5	NA	23%
Takahashi <i>et al</i> (14)	1998	1:1	12.3	66%
Ord <i>et al</i> (15)	2002	1:1.8	15.5	NA
Al-Khateab <i>et al</i> (16)	2003	1:1.5	16	50%
Current series (Ogunsalu, Daisley <i>et al</i>)	2006	1.1:1	16.1	42%

NA = Not available

multilocular type without an unerupted tooth associated with the lesion and is usually less well corticated (Table 3, Fig. 3). This is probably the most aggressive type of ameloblastoma in the young. Based on these findings, we suggest a management for ameloblastoma in children, as shown in Table 3, with Ia_1 having the most conservative surgical treatment (excisional biopsy) and Iib_2 having the most aggressive, surgical management.

DISCUSSION

The literature often refers to the paucity of ameloblastoma in children and young adults. Both unilocular and multilocular radiolucent lesions may be associated with ameloblastoma in children which can be histologically unicystic or multicystic, irrespective of the radiological presentation (*ie* unilocular or multilocular). Any histological type has been shown to recur, particularly in adults. As such it should be logical to classify ameloblastoma based on their initial radiological presentation. Hence we utilized the radiological presentation in this

series of 19 cases in young Jamaicans to classify ameloblastoma in children, for the following reasons:

- § To demonstrate similarities to simple dentigerous cysts,
- § To describe at a glance the lesion by way of numbers and letters,
- § To describe the growth and level of aggression of the tumour based on the presence of root resorption (since root resorption is an indication of a more aggressive lesion),
- § To show that less cortication also signifies increased growth rate and
- § To plan and standardize surgical management of ameloblastoma, particularly in the young.

In the literature, much has been said and documented on the demographics of ameloblastoma in children (9–15). The present analysis showed that the male-to-female ratio was 1.1:1, an almost equal sex ratio, consistent with what has been previously documented by Keszlar and Dominguez (10), Khan (11) and Takahashi *et al* (14) who reported male to female ratios of 1:1, 0.9:1 and 1:1 respectively. However it differed from the sex ratio documented by authors from two African studies – Olaitan and Adekeye (13) and Daramola *et al* (9) who recorded a sex ratio of 1:1.5 and 1:1.7 respectively. It almost tallied with the sex ratio documented by the African series of Chidzonga (12), which was 1:1. Jamaica has a population predominantly of African descent.

The mean age (16.1 years) was similar to that documented by Al-Khateab *et al* (16) in a series from Jordan and higher than that reported by Khan (11) and Takahashi *et al* (14). It was slightly higher than the mean age in the series of Chidzonga *et al* (12) from Africa, and Orad and Blanchert (15) from the United States of America (Table 5).

Two cases (11%) occurred unilaterally in the anterior mandible, hence the site distribution was similar to that of reports in the literature. No case radiologically simulating dentigerous cysts (Ia_1) was documented from the present series. This radiological category has been documented in other studies (13). Neither was any Iib_2 category present, indicating that well corticated multilocular radiolucent lesions without unerupted teeth associated were also absent from this series. This made sense if one believes that ameloblastoma in children is progressive in growth and that non-dentigerous lesions with multilocular radiolucency are probably likely to be fast growing (hence less cortication) than to be slow growing (*ie* well corticated).

The implications of these findings to the surgical management of ameloblastoma in young Jamaicans are as follows: 1) the presence of cortication means that the marginal and/or adjacent bone to the lesion may be normal and therefore, the further 1cm is expected to be actually normal bone (and not “probably” normal bone) – hence the need for less aggressive treatment and 2) less well corticated lesions do not have the certainty of normal adjacent bone as

mentioned in (1) and as such would require more aggressive management in terms of the amount of normal bone to be taken along with the lesion.

The authors inferred that unilocular or multilocular lesions in children may require conservative or aggressive management depending on the presence or absence of cortication and root resorption.

The treatment of ameloblastoma is surgical resection of the lesion in continuity with dentoalveolar structures and preservation of the lower border of the mandible or radical resection of the affected bone. The effectiveness of the surgical procedure is dependent on accessibility of the tumour, the skill of the operator and completeness of removal of the disease.

In 1986, Isaacs *et al* suggested that minimal surgical procedures should be employed in the young patient. It is intended that this radiological categorization of ameloblastoma will aid in decision of the extent of surgery to be done, especially in children.

The duration of radiological follow-up for ameloblastoma in children should also be based on this categorization. The large IIa₂ and IIb₂ will require longer and more frequent periods of follow-up radiologically, preferably with magnetic resonance imaging, than with the other categories. The Ia₁ which looks like a dentigerous cyst, will require short duration of follow-up and this can be done with the dental panoramic tomogram of good quality.

The authors' newly adopted classification of ameloblastoma in children should clarify the debate on the extent of the surgical procedure in these patients. It also sets out guidelines for duration of radiological follow-up and imaging modality.

REFERENCES

1. Small IA, Waldron CA. Ameloblastoma of the jaws. *Oral Surg* 1955; **8**: 281–97
2. Posnick JC. Craniofacial and Maxillofacial surgery in children and young adults. Philadelphia, PA: WB Saunders, 2000; 678–689.
3. Aisenberg MS. Histopathology of ameloblastomas. *Oral Surg Oral Med Oral Pathol* 1953; **6**: 1111–28.
4. Eversole LR, Leider AS, Hansen LS. Ameloblastomas with pronounced desmoplasia. *J Oral Maxillofac Surg* 1984; **42**: 735–40
5. Regezi JA, Sciubba JJ. Oral Pathology, Clinical pathologic correlations. Philadelphia, PA: WB Saunders, 1989; 337–348.
6. Farman AG, Ruprecht A, Gibbs SJ, Scarfe WC, eds. *Advances in Maxillofacial Imaging*. Amsterdam, Netherlands: Elsevier Science. 1997; 35–4.
7. Cawson RA, Langdon JD, Eveson JW. *Surgical Pathology of the Mouth and Jaws*. Oxford: Wright, 1996; 279–281.
8. Ramanathan K, Guan LS. Ameloblastoma in children. *Dent J Malaysia Singapore* 1968; **8**: 36–42.
9. Daramola JO, Ajagbe HA, Oluwasanmi JO: Ameloblastoma of the Jaws in Nigerian Children: A review of 16 cases. *J Oral Surg* 1975; **40**: 458.
10. Keszler A, Dominguez FV. Ameloblastoma in childhood. *J Oral Maxillofac Surg* 1986; **44**: 609–13.
11. Khan MA. Ameloblastoma in young persons: a clinicopathologic analysis and etiologic investigation. *Oral Surg Oral Med Oral Path* 1989; **67**: 706–15.
12. Chidzonga MM. Ameloblastoma in children. The Zimbabwean experience. *Oral Surg Oral Med Oral Pathol Radiol Endod* 1996; **81**: 168–70.
13. Olaitan AA, Adekeye EO. Clinical features and management of ameloblastoma of the mandible in children and adolescents. *Br J Oral Maxillofac Surg* 1996; **34**: 248–51.
14. Takahashi K, Miauchi K, Sato K. Treatment of ameloblastoma in children. *Br J Oral Maxillofac Surg* 1998; **36**: 453–6.
15. Ord R, Blanchaert R, Nikitakis NG, Sauk JJ. Ameloblastoma on children. *J Oral Maxillofac Surg* 2002; **60**: 770–1.
16. Al-Khataeb T, Ababneh KT, Ameloblastoma in young Jordanians. A review of the clinicopathologic features and treatment of 10 cases. *J Oral Maxillofac Surg* 2003; **61**: 13–18.
17. Ogunsalu C, Scipio E, William N. Maxillary ameloblastoma: review of 6 cases and a report of re-entry cryosurgery (at press).