

Severe Alveolar Bone Loss Around the Mandibular Incisor Teeth as a Long-Term Effect of Tongue-Piercing

Sir,

The use of oral piercings has become a fashionable practice worldwide. The mean prevalence of oral and peri-oral piercing in general population is 5.2%.¹ It is generally recommended that following healing, such ornaments should be removed daily and cleaned to avoid plaque and calculus accumulation. However, some patients rarely remove their ornaments for cleaning.² Pires *et al.* reported that individuals wearing tongue ornaments are more susceptible to gingival recession in the anterior lingual region as compared to individuals not wearing tongue ornaments.³

This letter describes a unique case of tongue-piercing prolonged wearing, resulting in extensive alveolar bone loss.

The patient was a 23 years old Brazilian female who was referred to the Faculty of Dentistry at the University of Pelotas, Brazil in November 2012 with pain in mandibular anterior sextant. The medical history of the patient was unremarkable and there was no history of habitual tobacco use (such as cigarette smoking and tobacco chewing) reported by the patient. The patient described oral piercing as a simple procedure, which was performed by a non-medical practitioner. She had no difficulties in speech, mastication and/or deglutition.

Upon clinical examination, there was no evidence of any extra-oral pathology and lymph nodes were not tender on palpation. Upon intra-oral examination, a double-ended metal oral piercing transfixing the tongue was observed. Two metal barbells, one on the dorsum and the other at the bottom of the tongue, were fixed at both ends of the transverse fixation (Figure 1a and 1b). There was a midline diastema between teeth No. 31 and No. 41 (Figure 1b). The barbell at the bottom of the piercing was in close contact with the mandibular central incisors. The patient reported that she had been wearing the ornament for nearly 7 years for esthetic reasons. Upon clinical periodontal examination, gingiva on the lingual aspect of the mandibular central incisor region appeared erythematous. The mid-labial and mid-lingual probing depths for teeth No. 31 and No. 41 were 3 millimeters (mm) and 6 mm and 3 mm and 8 mm respectively. All sites (mesial, distal, labial and lingual) on teeth No. 31

and No. 41 demonstrated bleeding on probing. Teeth No. 31 and No. 41 demonstrated Grade-I and Grade-II mobility respectively. The general oral hygiene status of the patient was fair.

Radiological evaluation was performed using a periapical radiograph of the mandibular anterior region and a panoramic radiograph. Both radiographs demonstrated localized yet severe horizontal alveolar bone loss in the mandibular central incisor region. On teeth No. 31 and No. 41, the mean mesial and distal bone loss was 1 mm and 8 mm and 9 mm and 10 mm respectively. The radiographs also demonstrated characteristics of trauma, such as loss of integrity of the duralamina and widening of the periodontal ligament (Figure 2a and 2b).

The proposed treatment was to remove the piercing followed by scaling and root planing of the affected sites (No. 31 and No. 41) using sterile ultrasonic scalers. Oral hygiene instructions were given to the patient and recalled for follow-up after 3 months. Despite the appointment and reminders, the patient elected not to pursue further dental treatment.

Individuals seeking oral and peri-oral piercings generally ignore the fact that piercings are usually performed by non-medical professionals, which in turn increases the possibility of infection transfer.⁴ In this regard, it is highly recommended that a question regarding the presence or absence of intra-oral piercing/s should be included in the

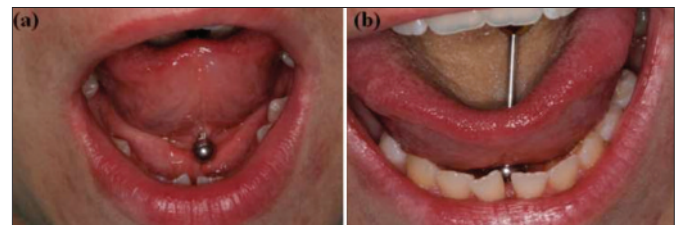

Figure 1 (a,b): (a) Intraoral piercing showing the inferior barbell of the tongue ornament. (b) Inferior component of the piercing in relation to the lingual surface of teeth No. 31 and No. 41.

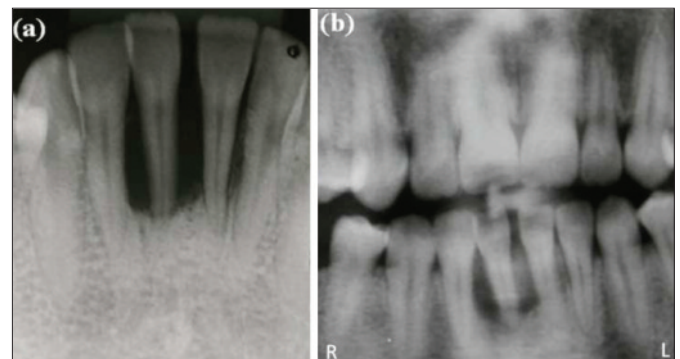


Figure 2 (a,b): (a) Periapical radiograph showing severe horizontal alveolar bone loss in the mandibular central incisor region with loss of integrity of the duralamina and widening of the periodontal ligament. (b) Section of a panoramic radiograph showing severe horizontal alveolar bone loss in the mandibular central incisor area.

questionnaire administered to all new patients in a medical/dental setting.

In the present case, bone loss was localized around where the inferior barbell of the tongue ornament was constantly located in the same region. Alloys when placed in a biological environment undergo some degree of corrosion that leads to the formation of metallic ions which may in turn trigger the immune system by forming complexes with endogenous proteins.⁵ Alloys used in dental implants stimulate bone resorption by inducing differentiation of murine osteoblasts thereby contributing to aseptic loosening of dental implants.⁵ This may be an explanation of the extensive bone loss observed in the case presented here since the tongue-ornament was in contact with the anterior lingual gingivae for approximately 7 years. It seems that this patient was habitually pushing the inferior barbell of the tongue-ornament against the mandibular central incisors which would have most probably caused a mandibular midline diastema.

The oral biofilm harbors a variety of periodontopathogenic bacteria (including *Aggregatibacter actinomycetemcomitans*, *Porphyromonas gingivalis*, *Prevotella intermedia*, *Tannerella forsythia* and *Treponema-denticola*).⁶ Although the overall oral hygiene status of the patient was fair, it is likely that the inferior barbell of the metal piercing would have compromised oral hygiene maintenance on the lingual aspect of the mandibular anterior region. This factor could have contributed to the pre-existing erythema and bleeding on probing as seen in the present scenario.

On the basis of the present findings, we remain confident that removal of tongue piercing ornaments with adjunct scaling and root planing would help stabilize the bony lesions resolve inflammation and eliminate tooth mobility over time.

REFERENCES

1. Hennequin-Hoenderdos NL, Slot DE, Van der Weijden GA. The prevalence of oral and peri-oral piercings in young adults: a systematic review. *Int J Dent Hyg* 2012; **10**:223-8.
2. De Moor RJ, De Witte AM, Delme KI, De Bruyne MA, Hommez GM, Goyvaerts D. Dental and oral complications of lip and tongue piercings. *Br Dent J* 2005; **199**:506-9.
3. Pires IL, Cota LO, Oliveira AC, Costa JE, Costa FO. Association between periodontal condition and use of tongue piercing: a case-control study. *J Clin Periodontol* 2010; **37**:712-8.
4. Stein T, Jordan JD. Health considerations for oral piercing and the policies that influence them. *Tex Dent J* 2012; **129**:687-93.
5. Javed F, Al-Hezaimi K, Almas K, Romanos GE. Is titanium sensitivity associated with allergic reactions in patients with dental implants? A systematic review. *Clin Implant Dent Relat Res* 2013; **15**:47-52.
6. Ziebolz D, Hornecker E, Mausberg RF. Microbiological findings at tongue piercing sites: implications to oral health. *Int J Dent Hyg* 2009; **7**:256-62.

Fernanda Oliveira Bello Correa¹, Marta Silveira da Mota Krüger², Felipe Martins Silveira¹, Thiago Marchi Martins¹, Hameeda Bashir Ahmed³ and Fawad Javed⁴

¹ Department of Semiology and Clinic / Social and Preventive Dentistry², School of Dentistry, Federal University of Pelotas, Pelotas, Brazil.

³ Department of Dentistry, Al-Farabi Dental College, Riyadh, Saudi Arabia.

⁴ Engineer Abdullah Bugshan Research Chair for Growth Factors and Bone Regeneration, 3D Imaging and Biomedical Laboratory, College of Applied Medical Sciences, King Saud University, Riyadh, Saudi Arabia.

Correspondence: Dr. Marta Silveira da Mota Krüger, Universidade Federal de Pelotas, Faculdade de Odontologia, Rua Gonçalves Chaves, 457, Centro-96015-560, Pelotas - RS Brazil.

E-mail: martakruger@gmail.com

Received: November 11, 2013; Accepted: February 03, 2014.

